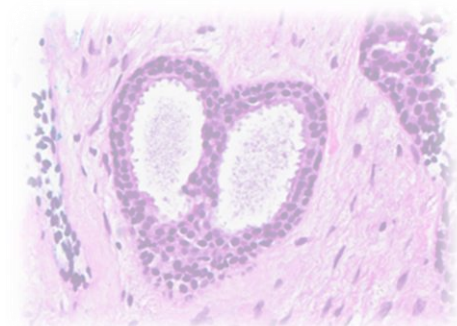
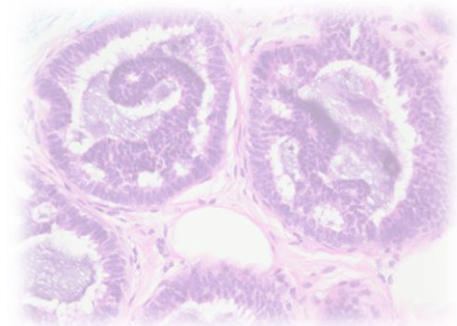
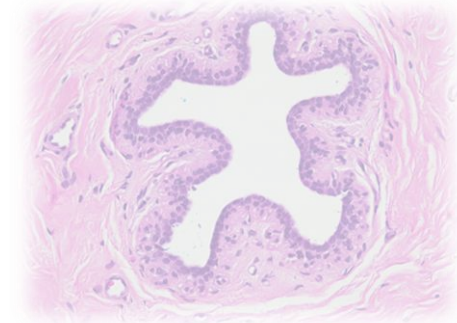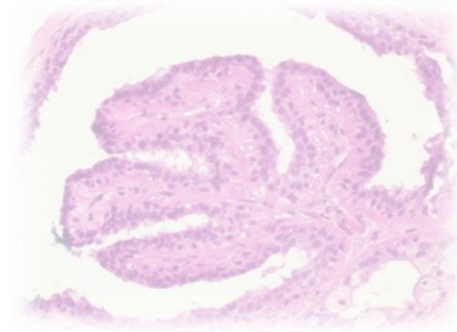
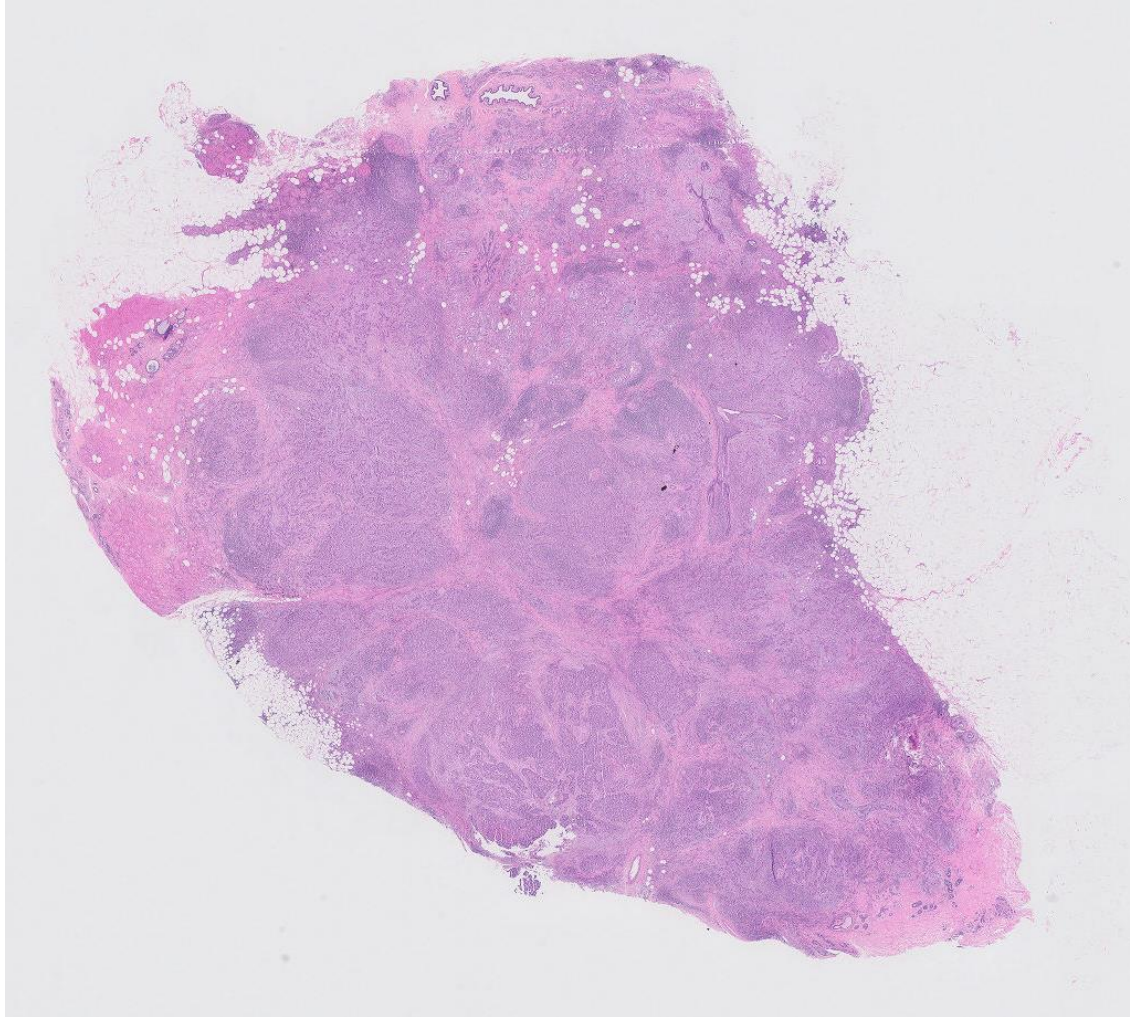


Case 3

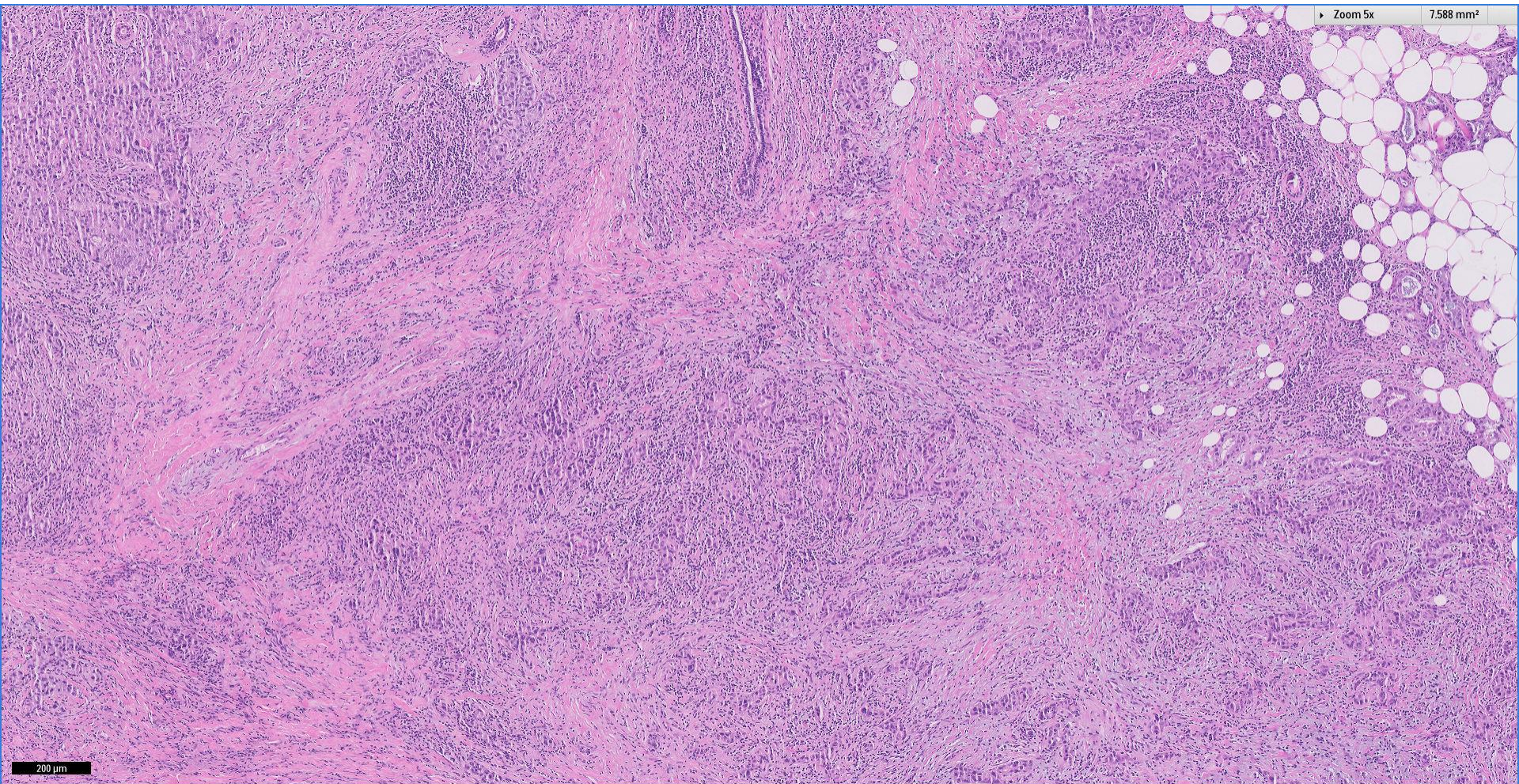
48 year old Indonesian female.
Materials of a breast tumour
submitted for histological review.

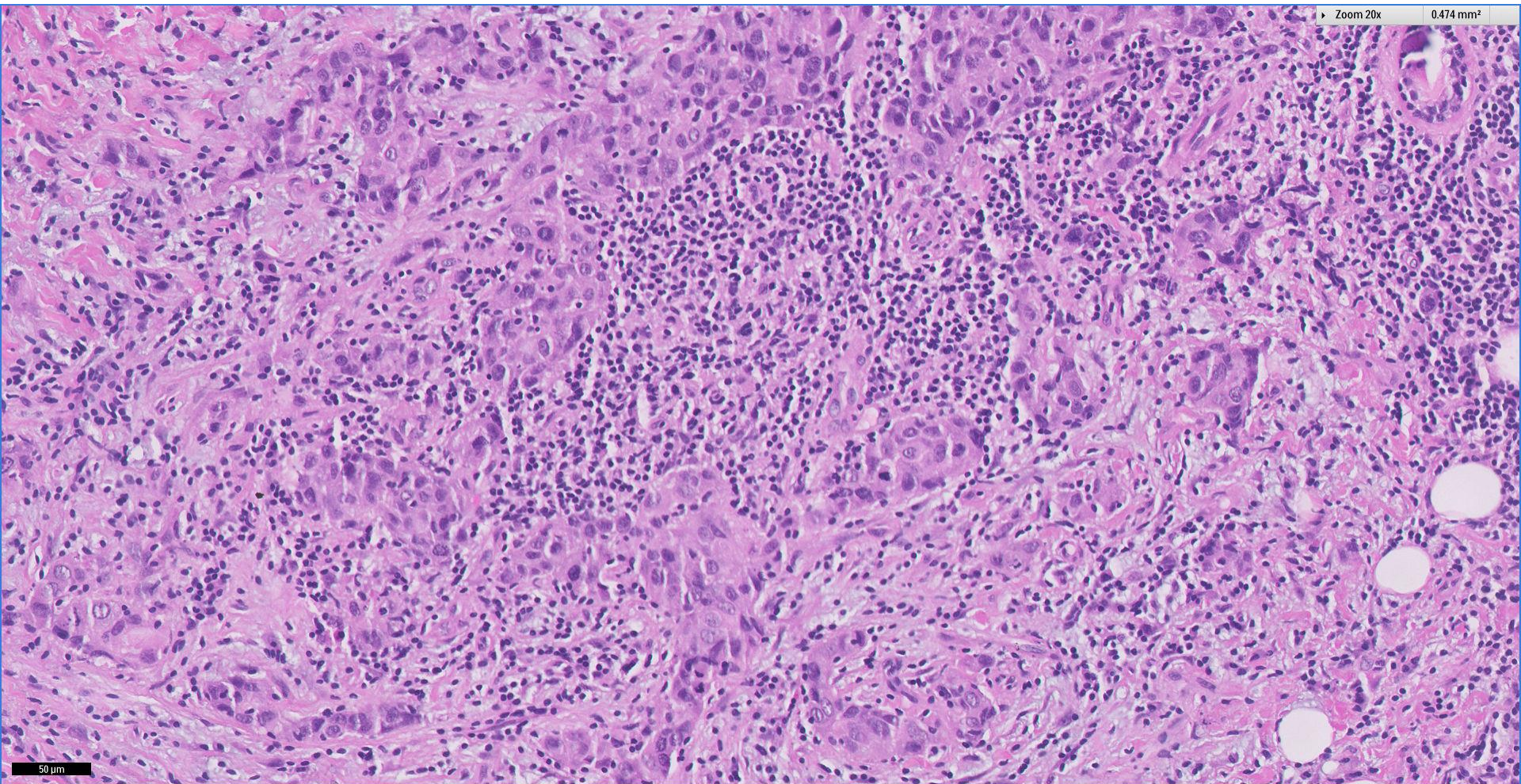


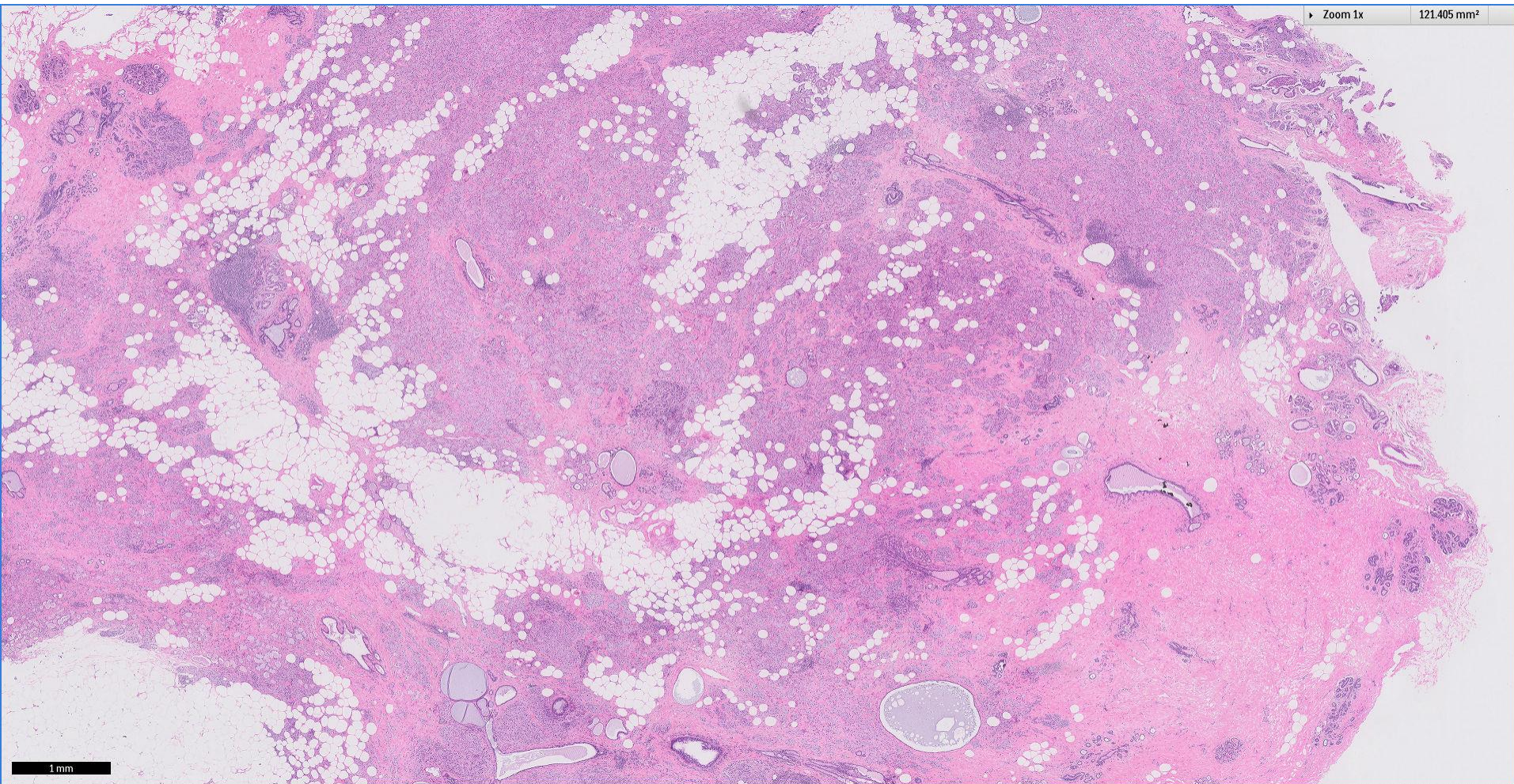


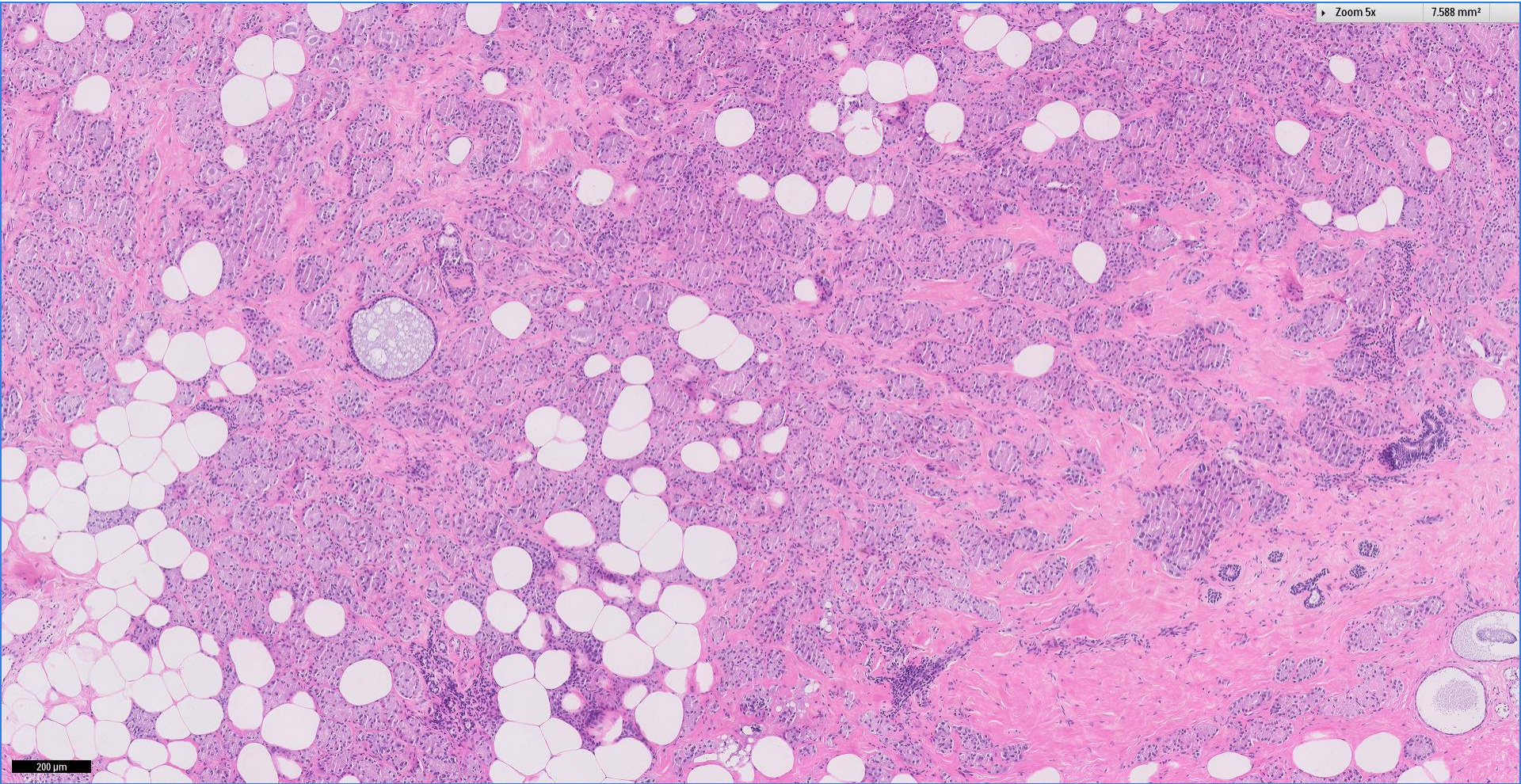
Division of Pathology
Singapore General Hospital









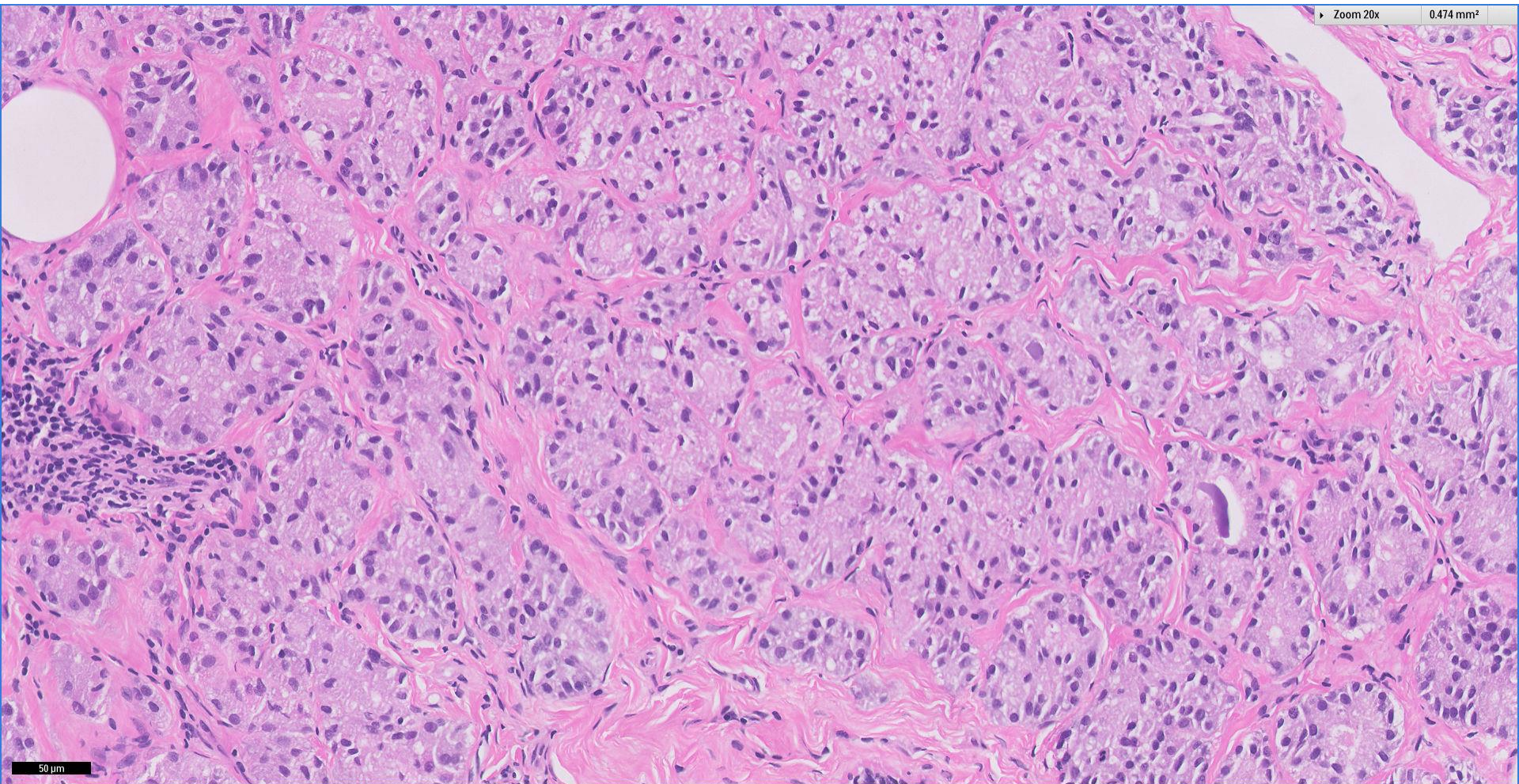


200 µm



Division of Pathology
Singapore General Hospital





Thank You