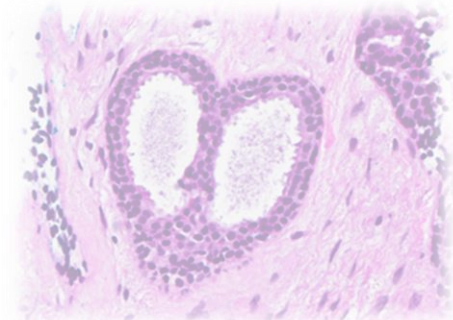
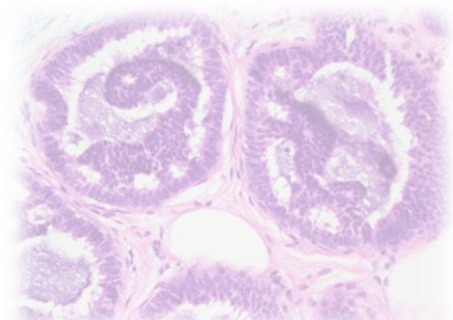
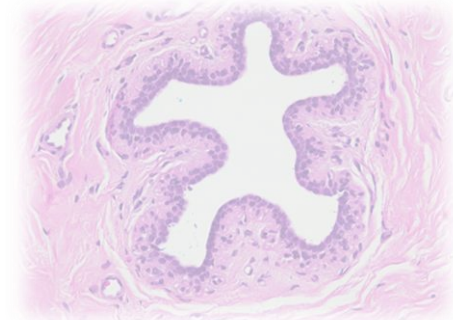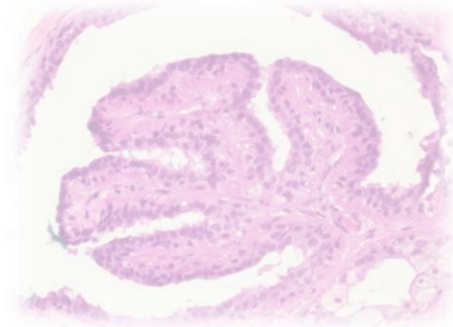
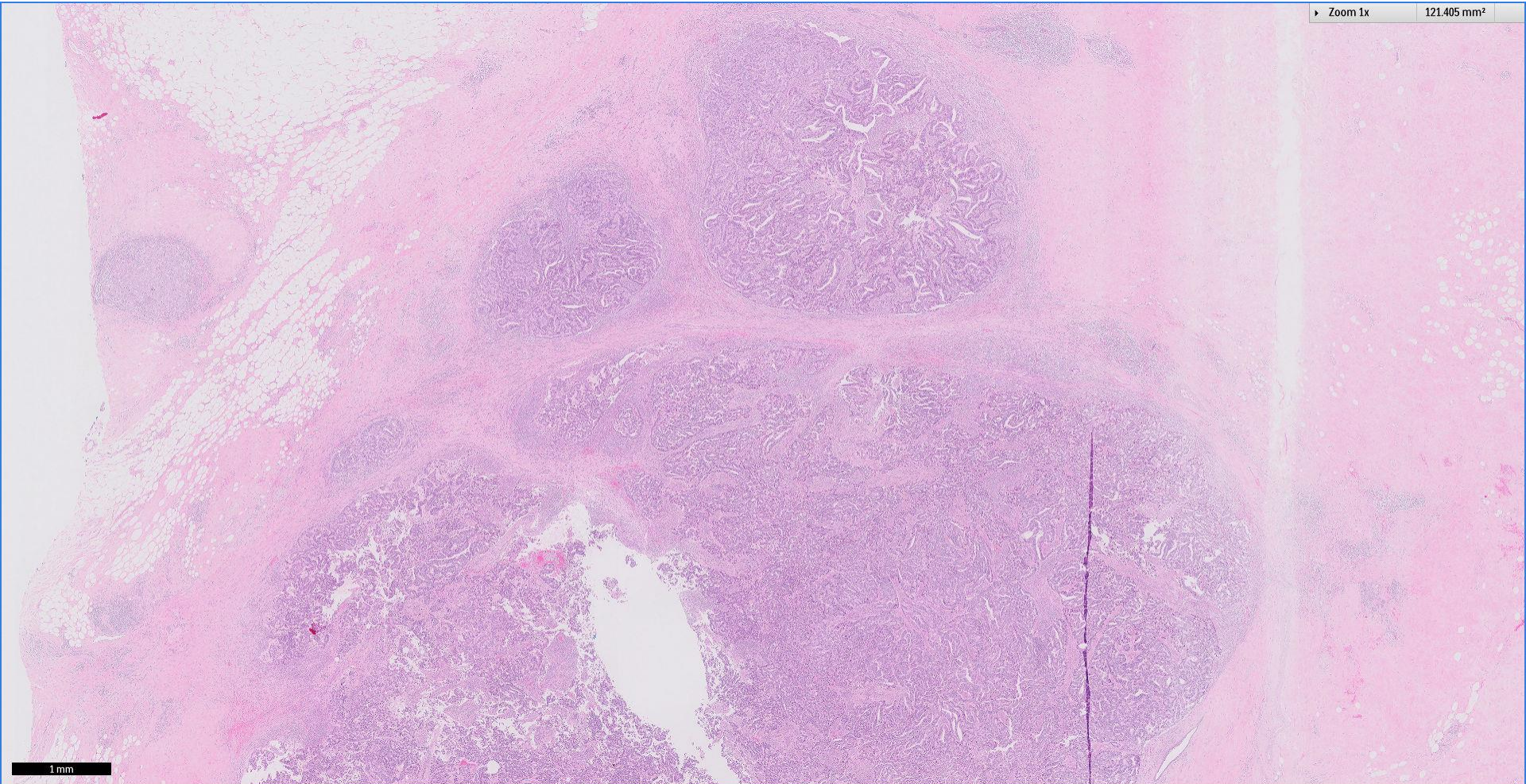


Case 2

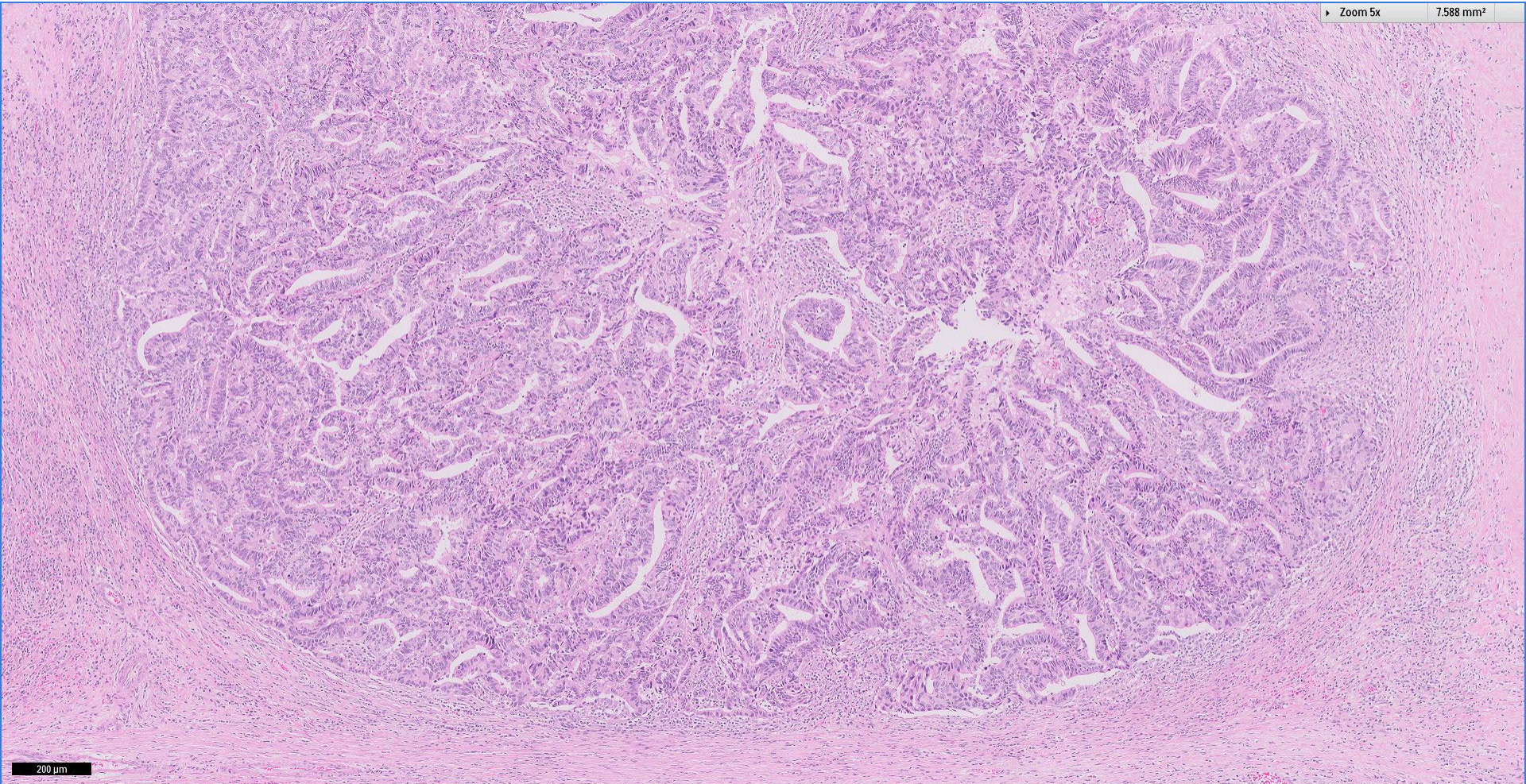
61 year old Chinese female.
Right breast wide excision.
Prior ultrasound (US) guided core biopsy
of a right breast 0600 lesion showed an
'atypical papillary lesion', while US guided
core biopsy of a right axillary node
revealed metastatic carcinoma.



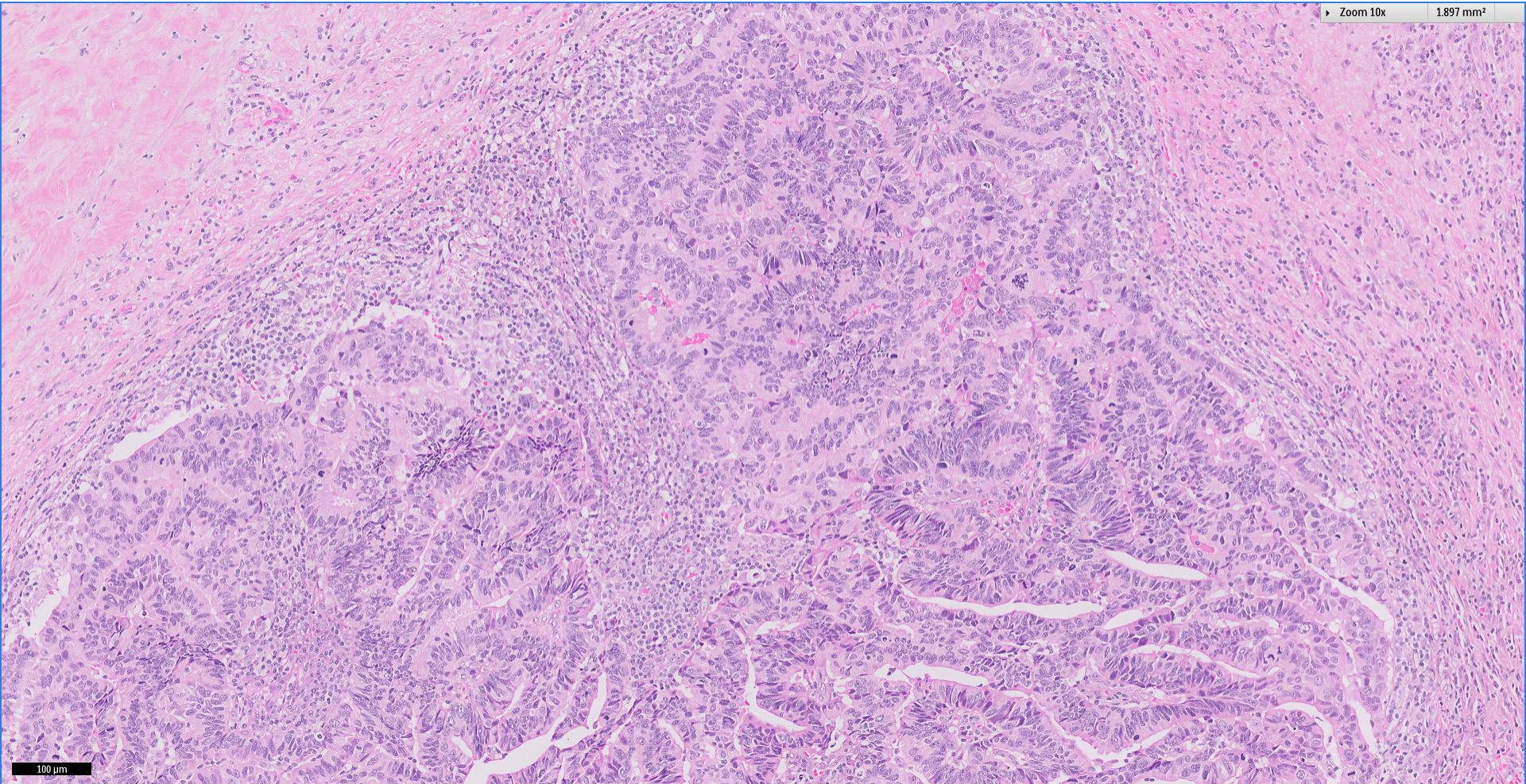
Right breast 0600



Right breast 0600

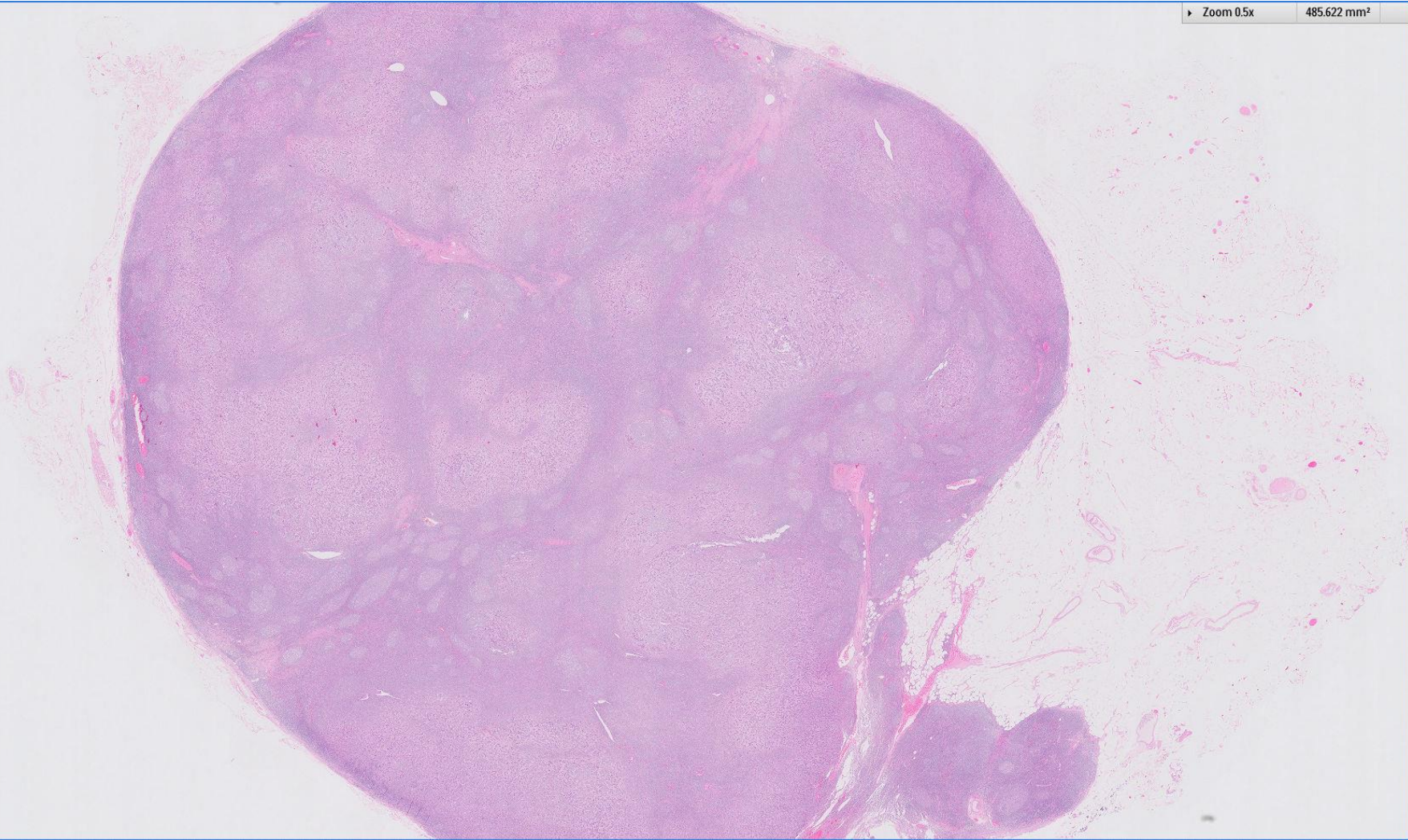


Right breast 0600

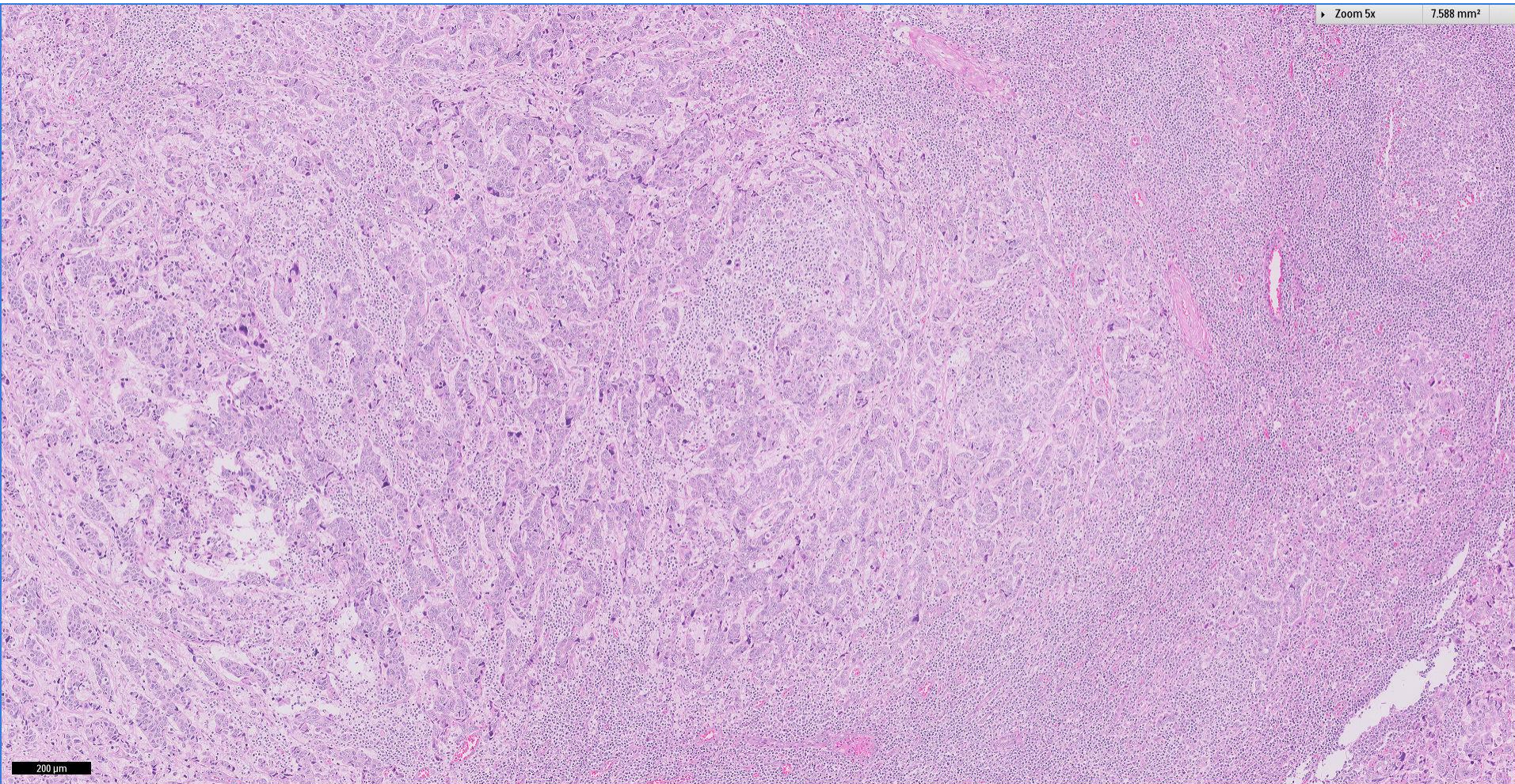


Right axillary LN

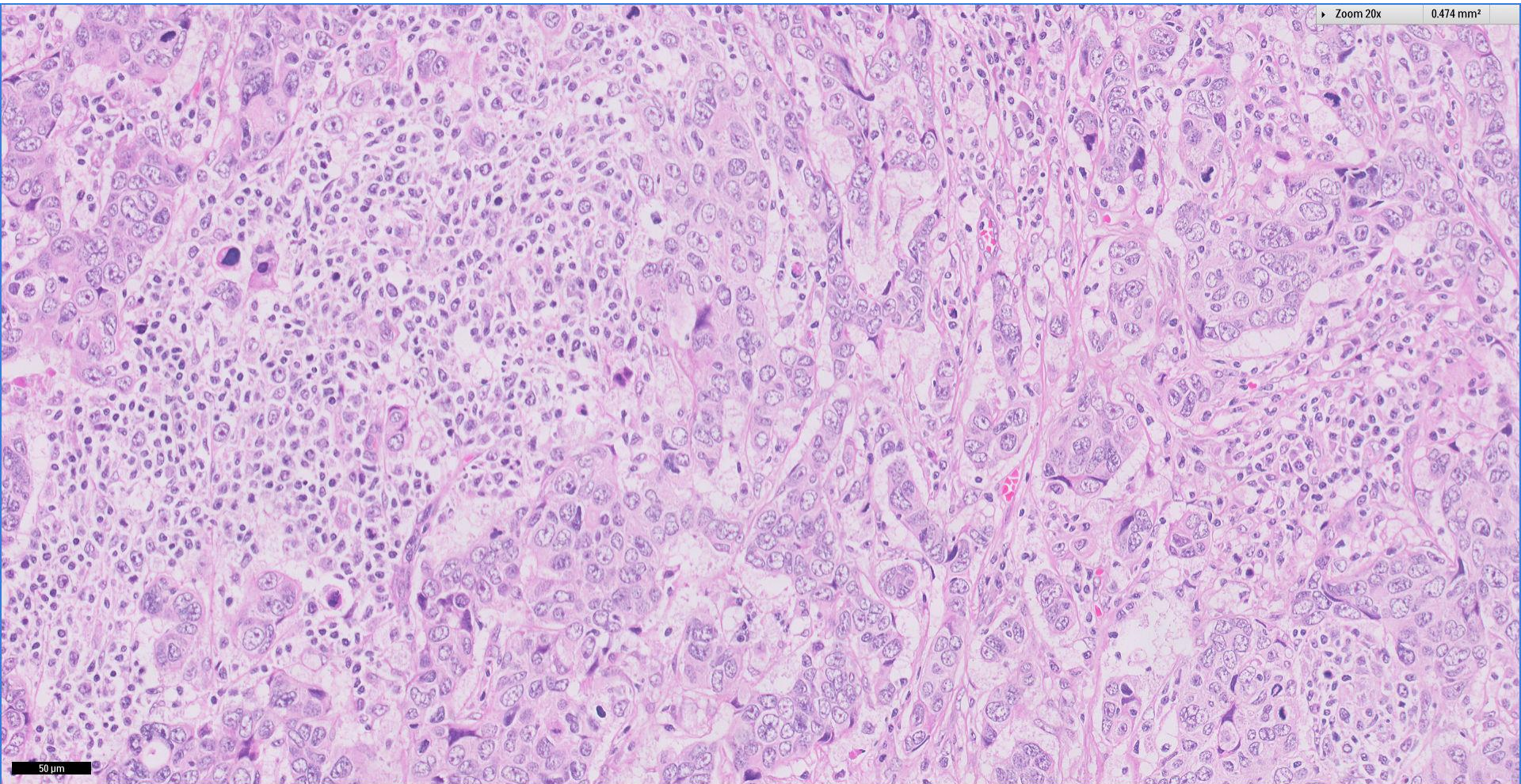
Zoom 0.5x 485.622 mm²



Right axillary LN



Right axillary LN



Thank You