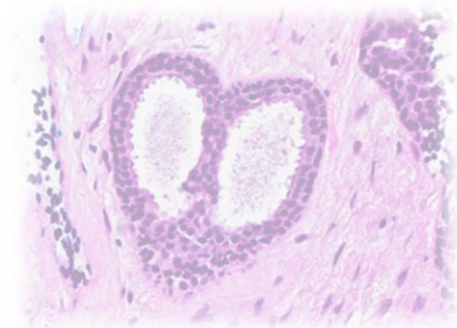
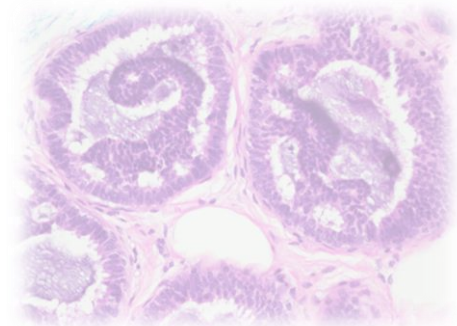
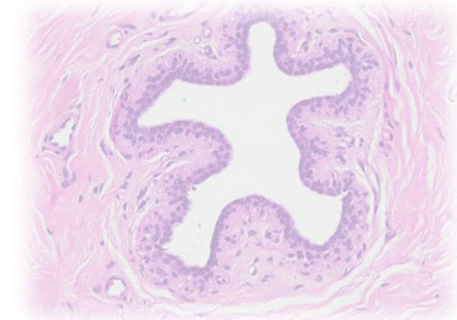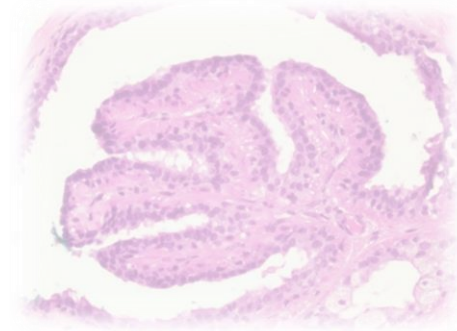
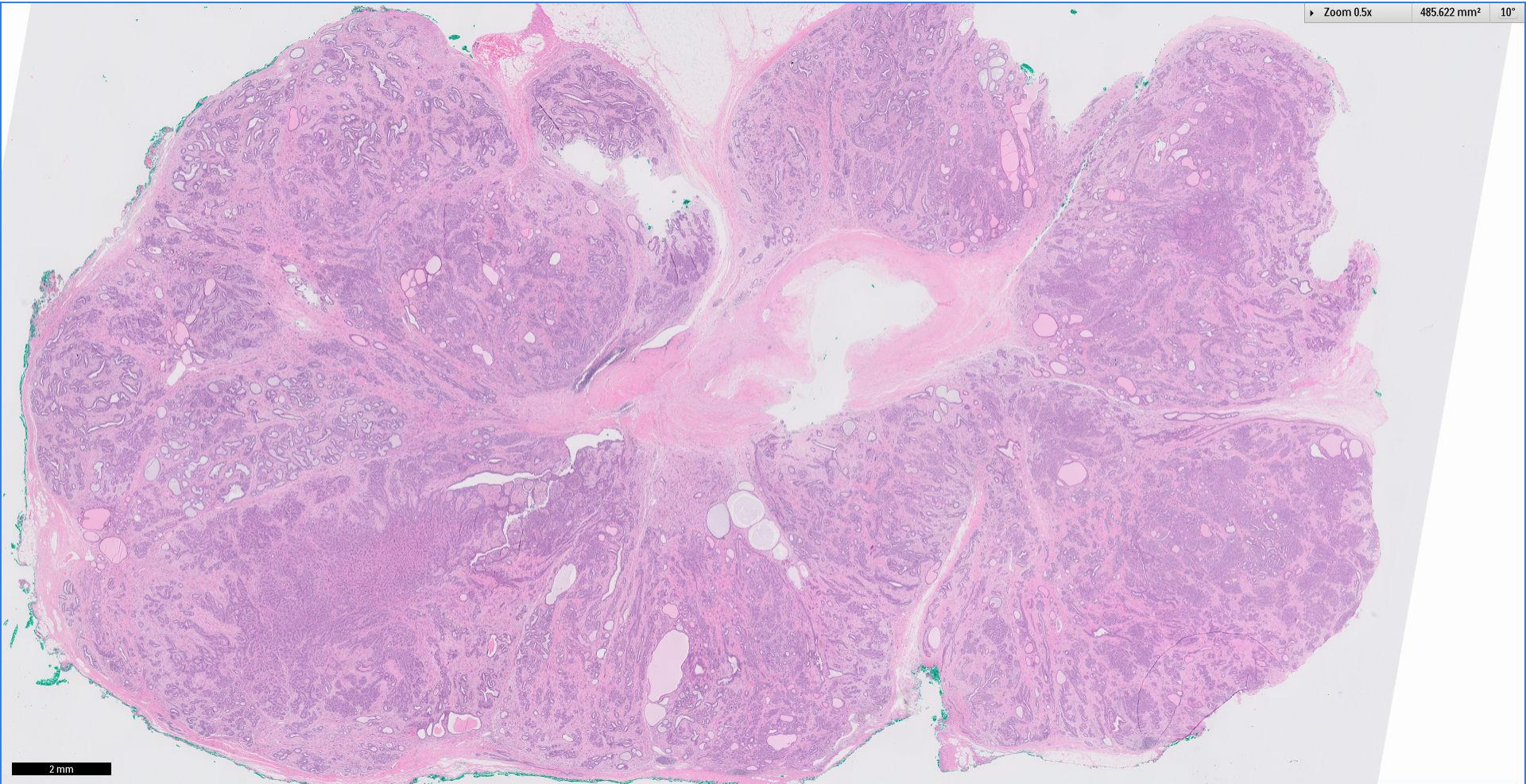


# Case 10

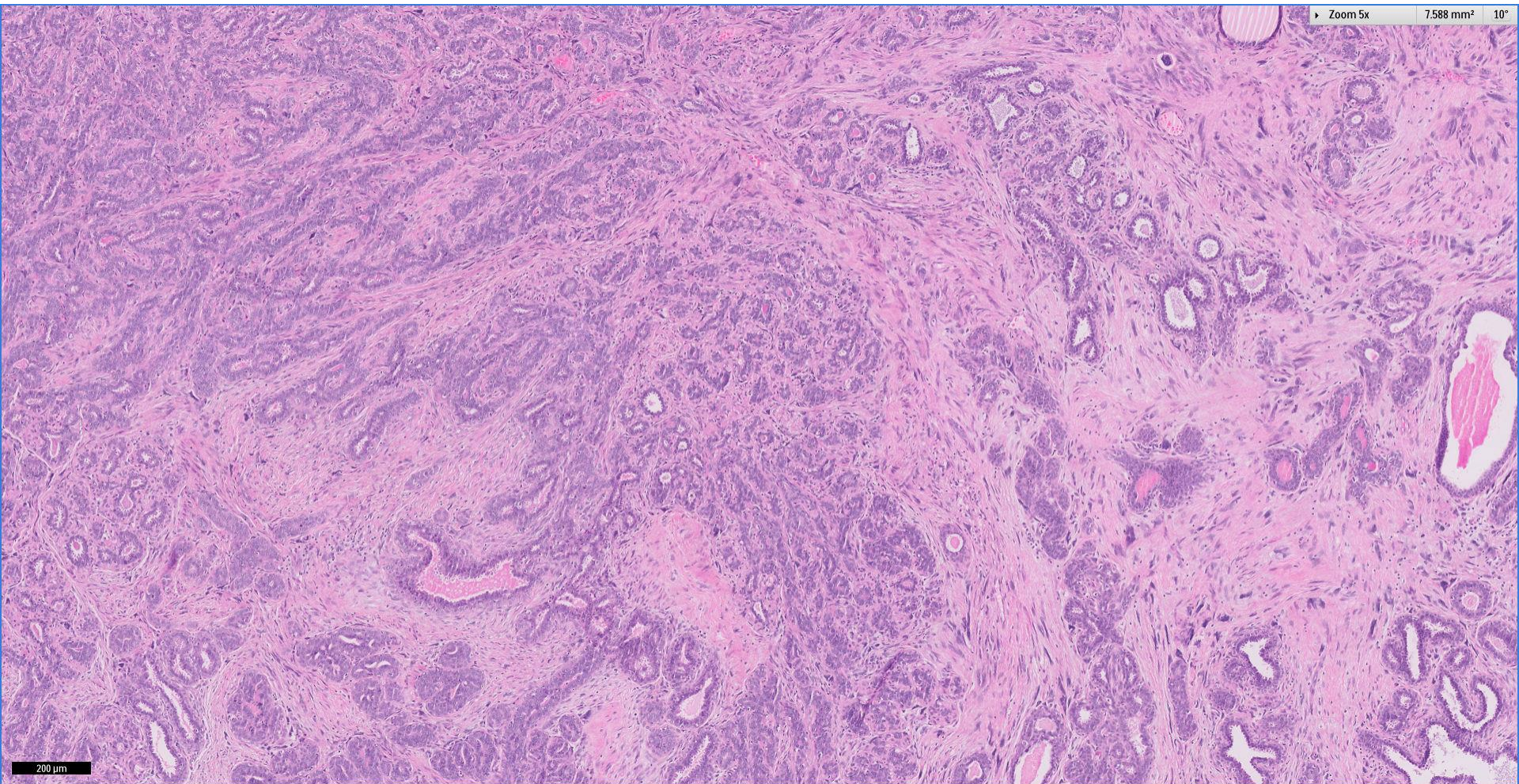
36 year old Malay female.  
Left breast lump, excision biopsy.







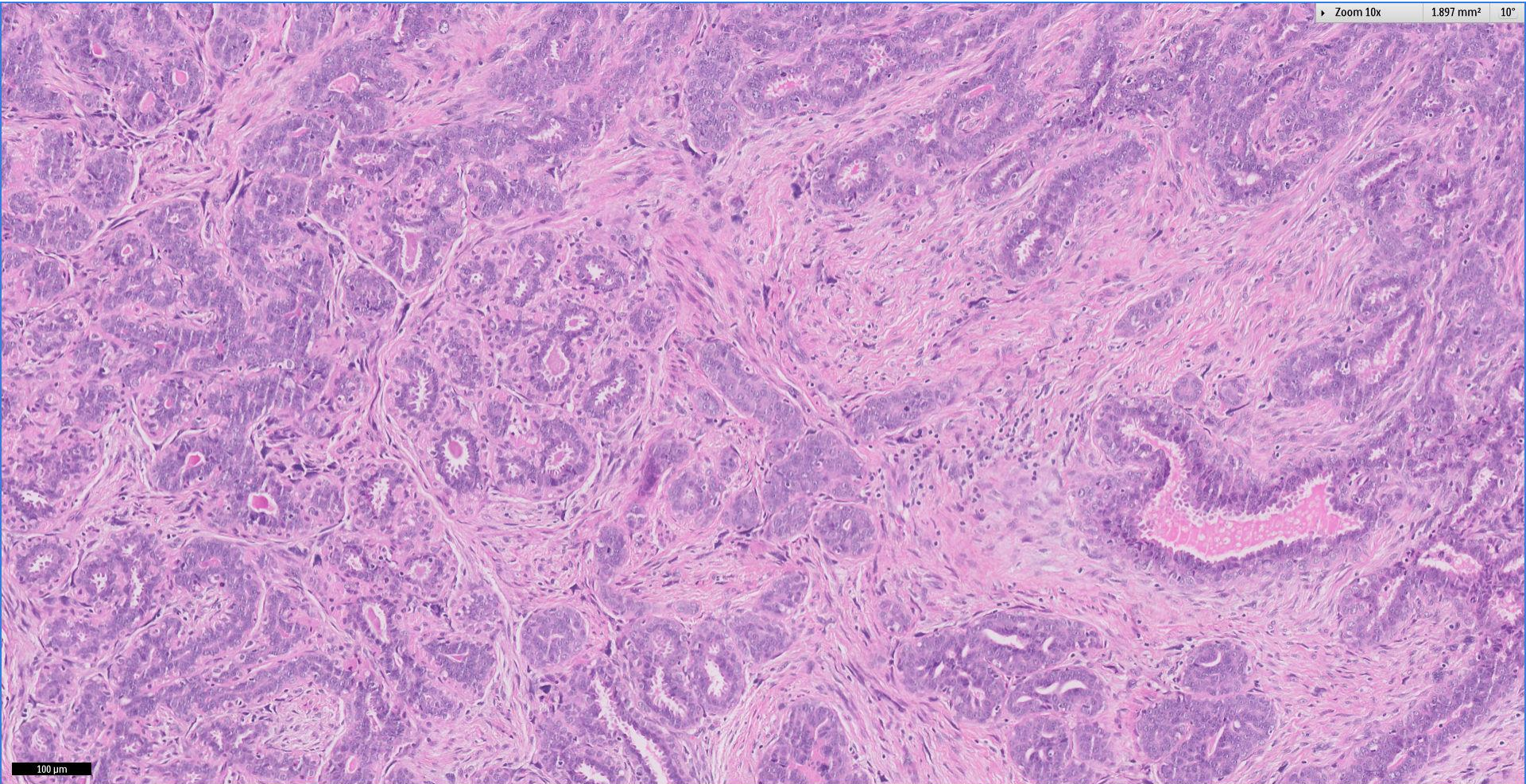




**Division of Pathology**  
**Singapore General Hospital**

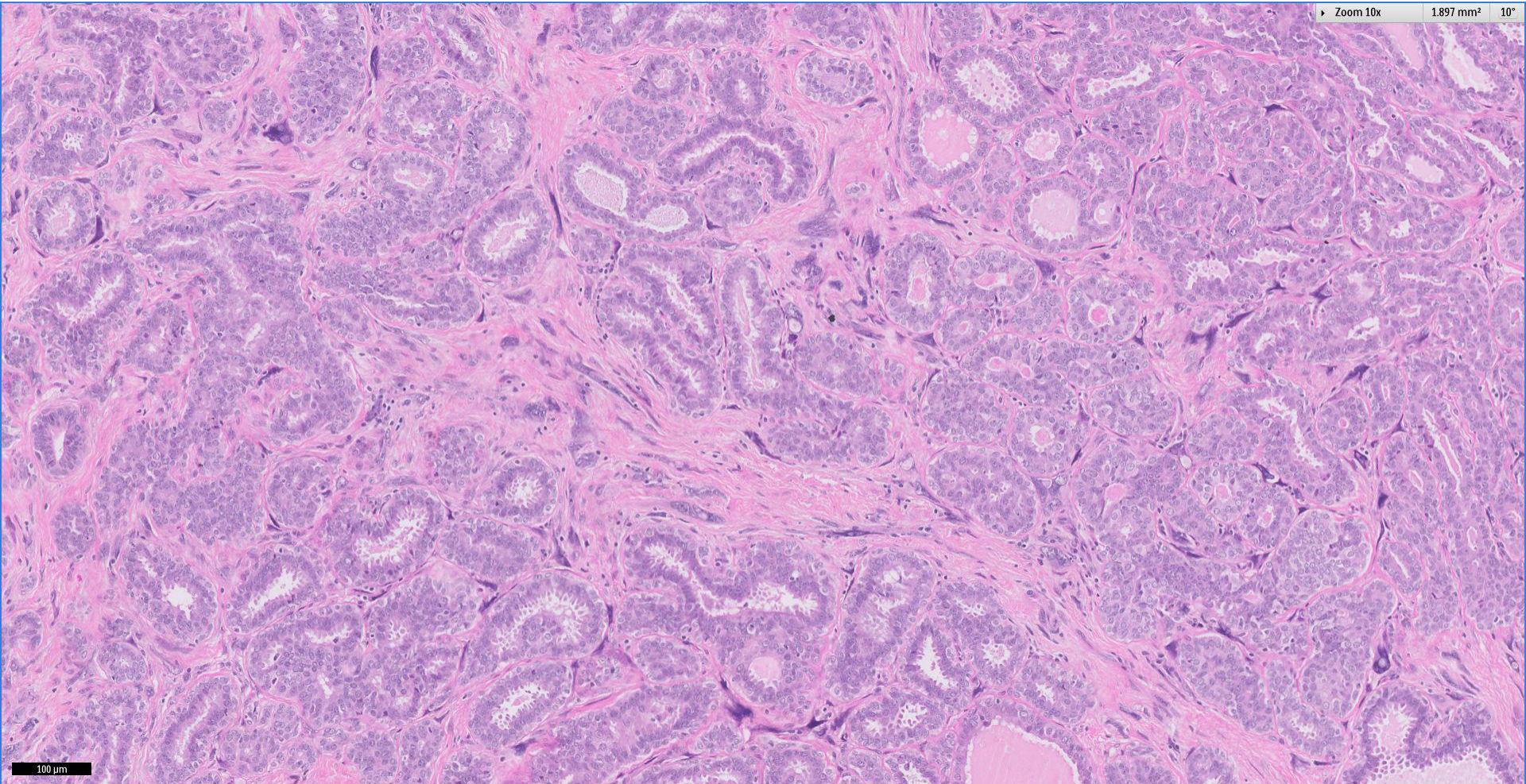






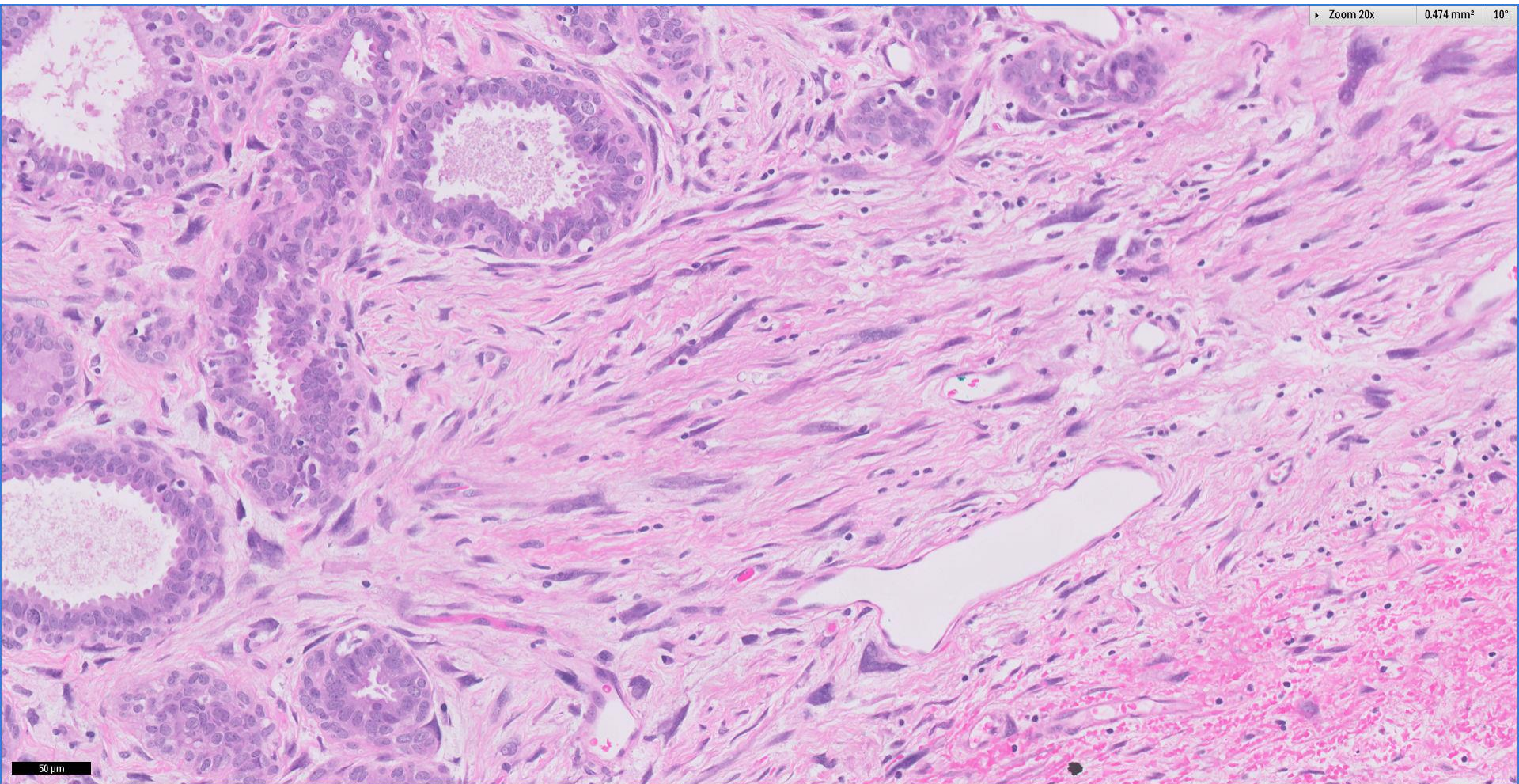
100 µm





100 µm







*Thank You*