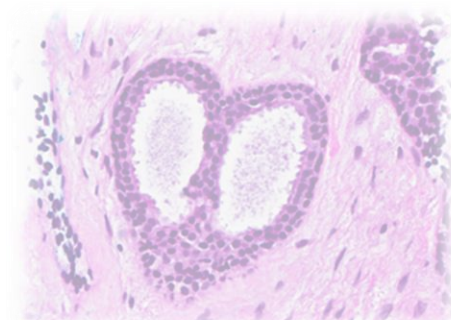
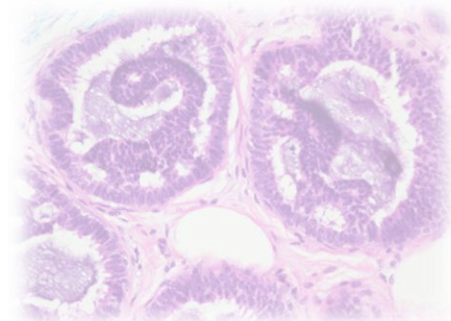
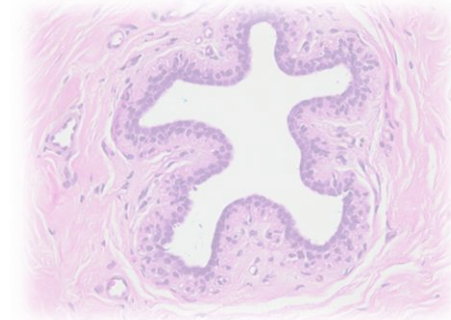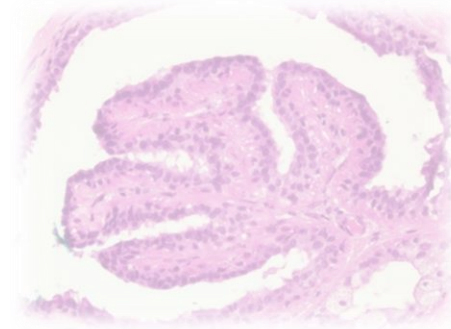
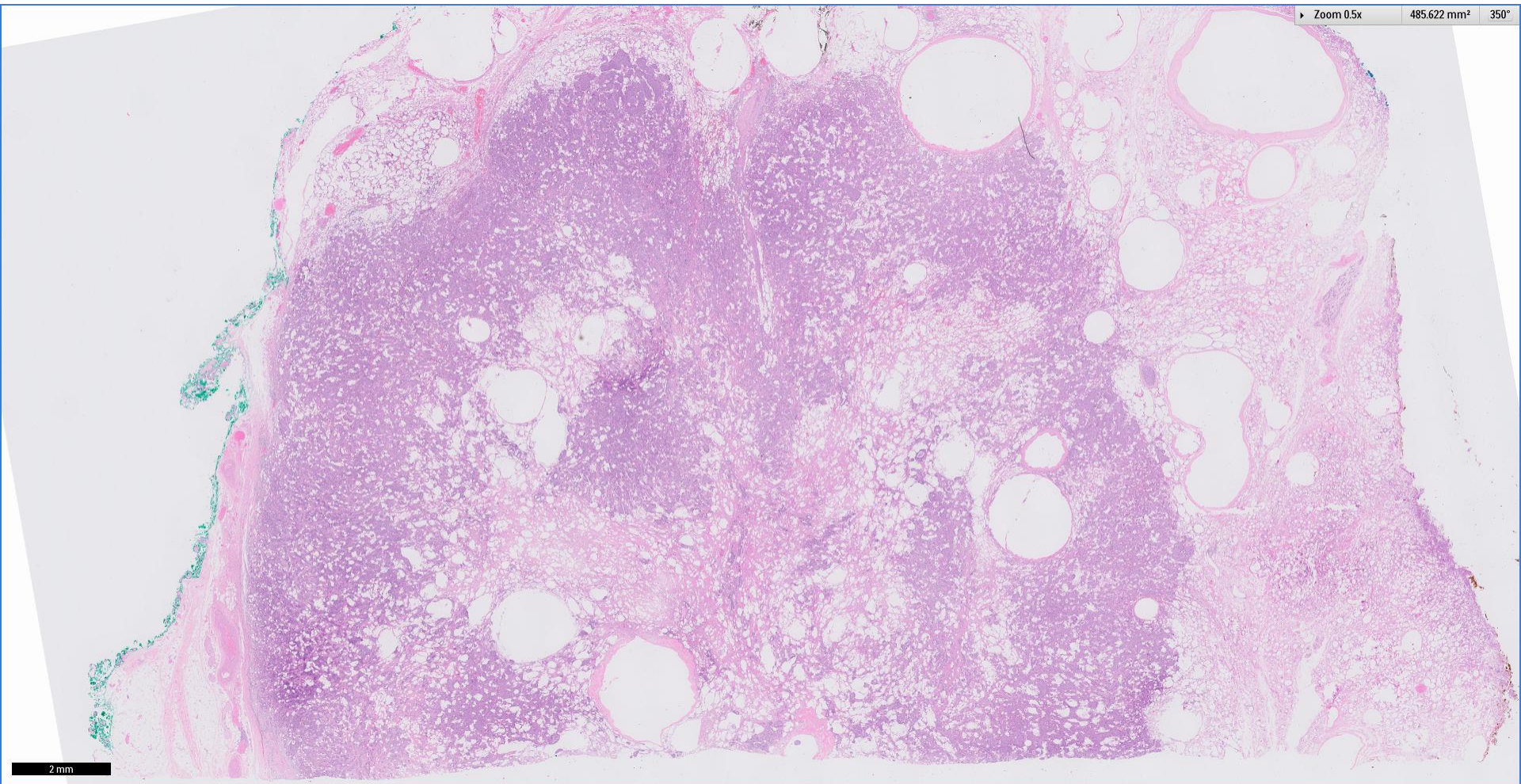


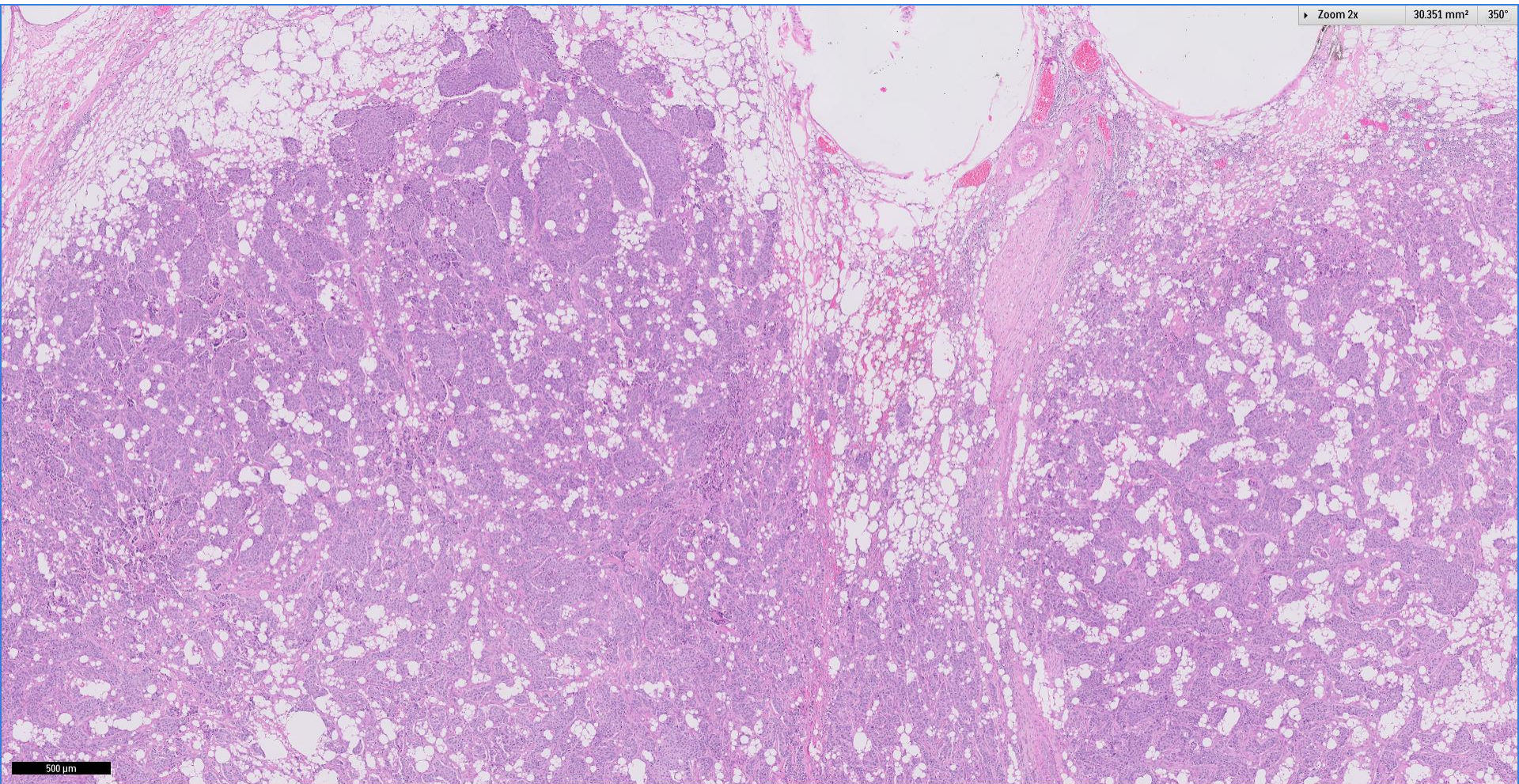
Case 24

37 year old female.

Right breast lump, excision biopsy.

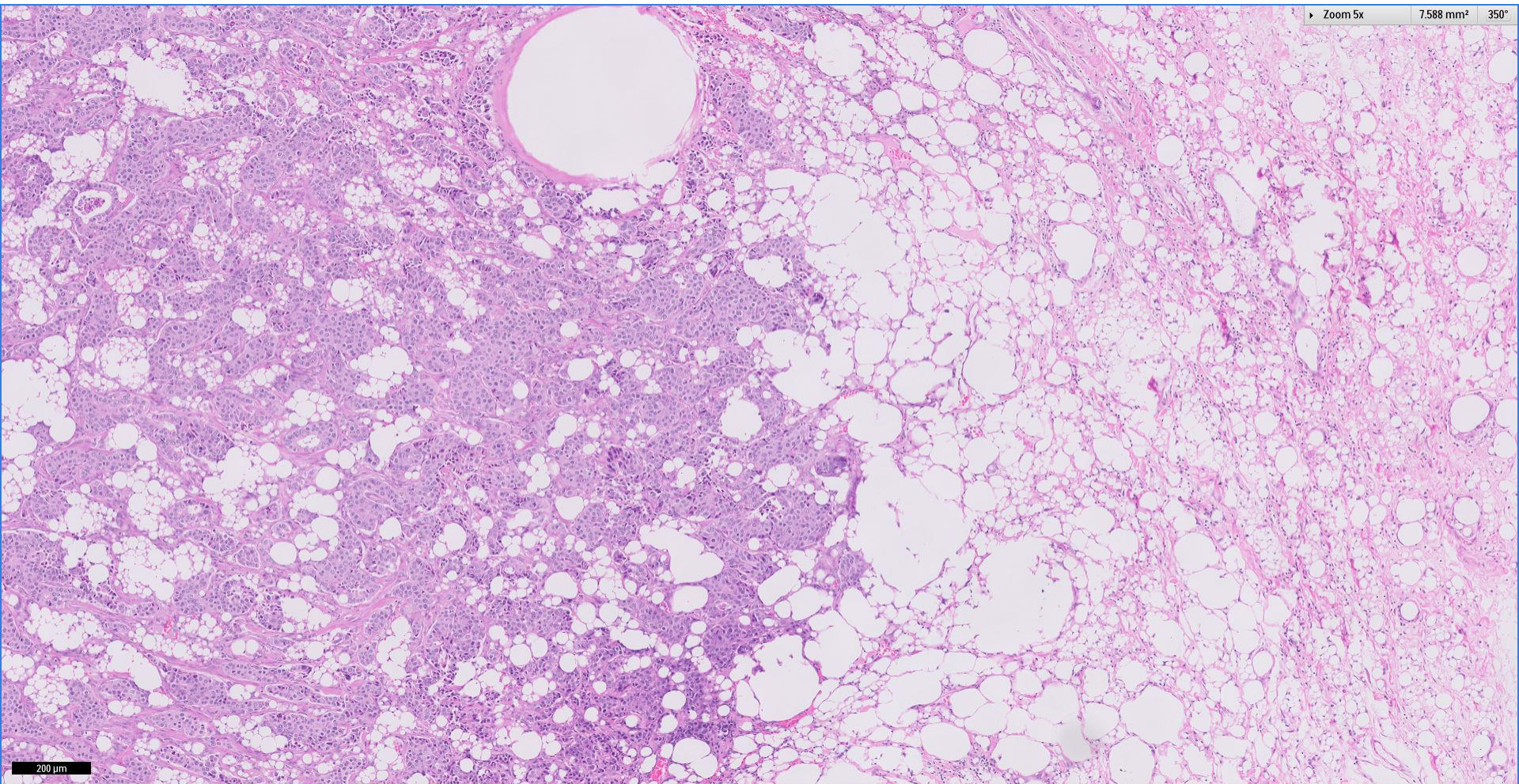






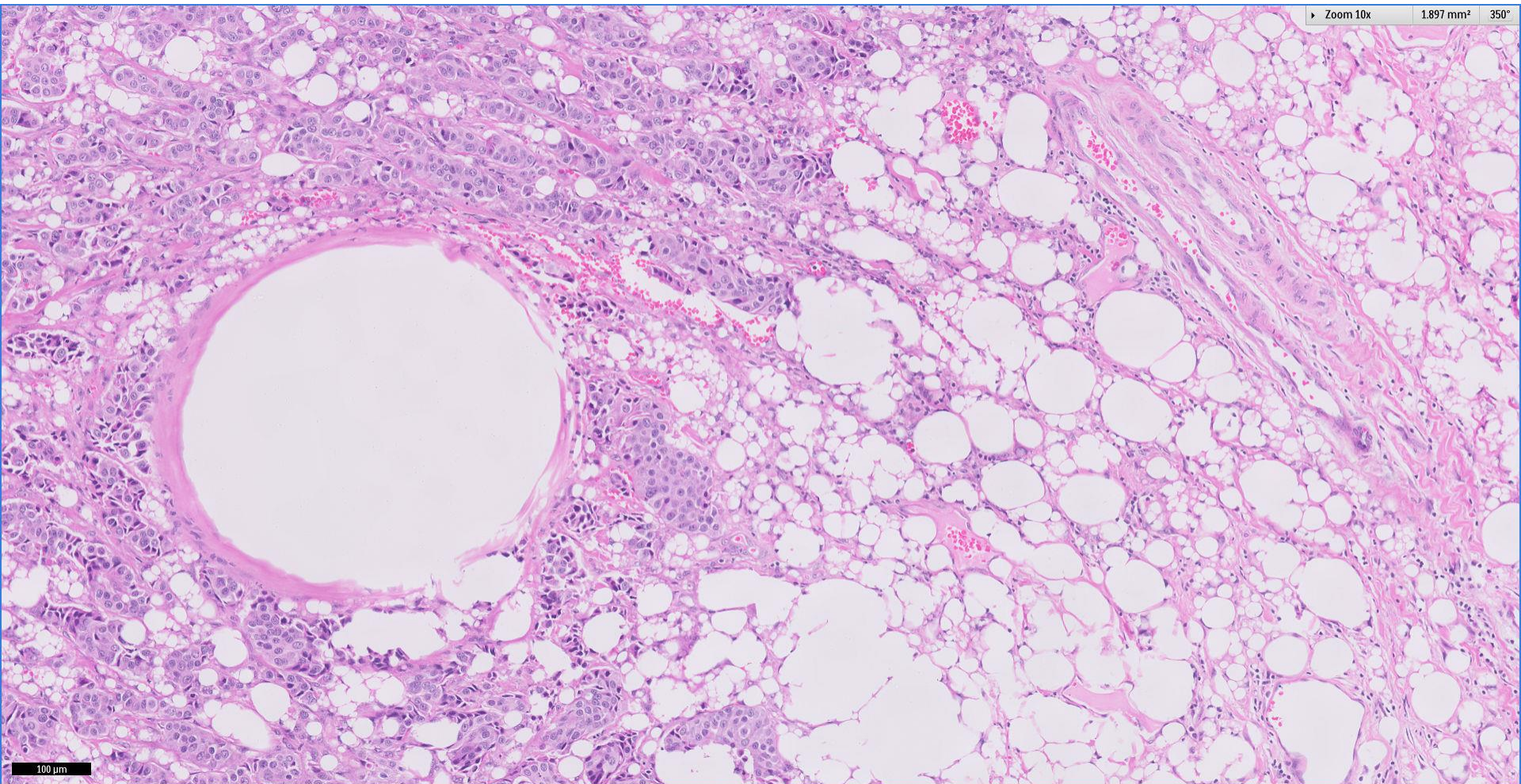
Division of Pathology
Singapore General Hospital

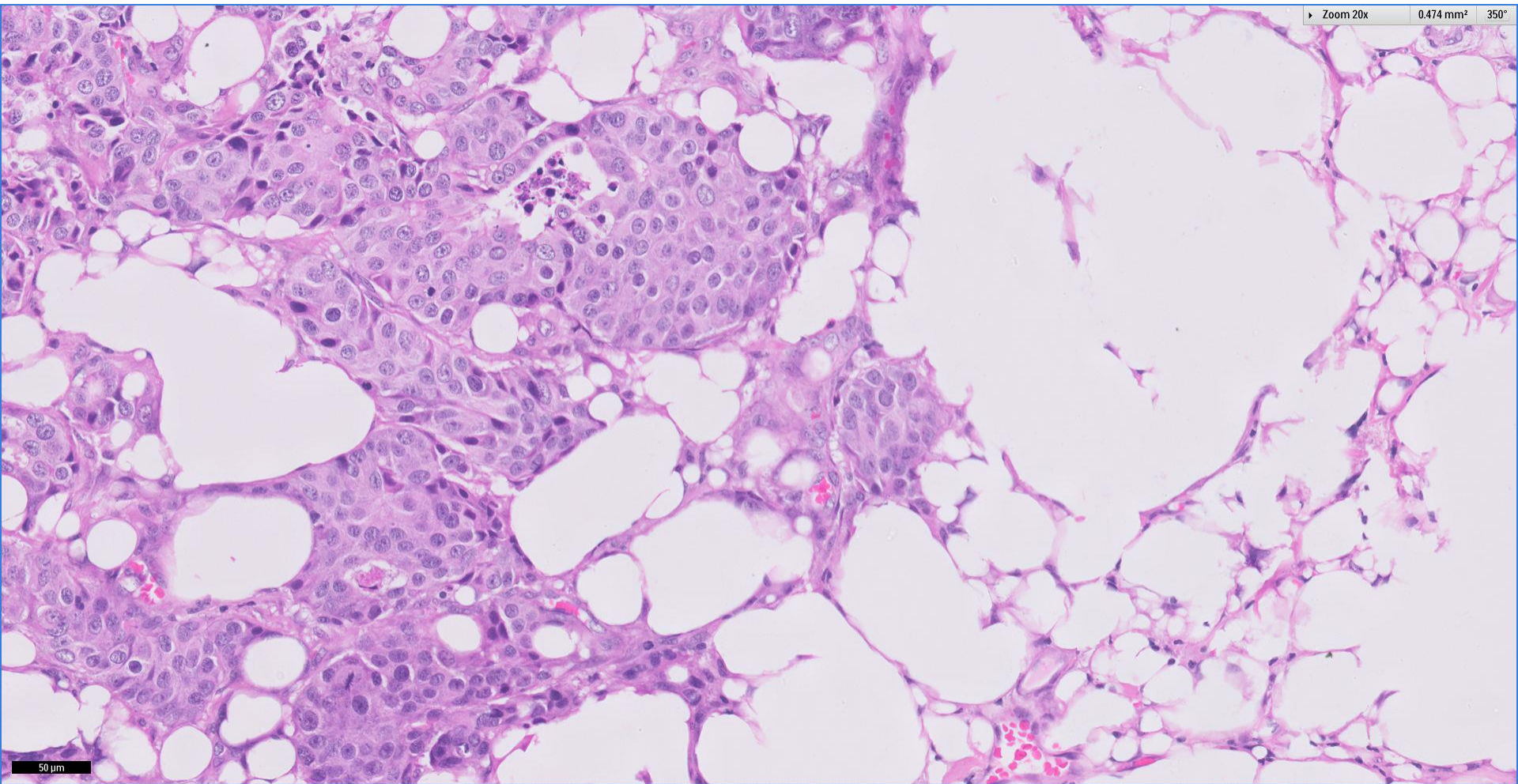




Division of Pathology
Singapore General Hospital





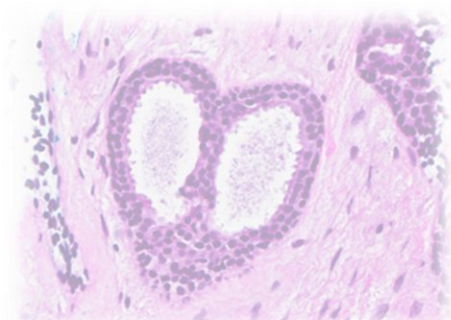
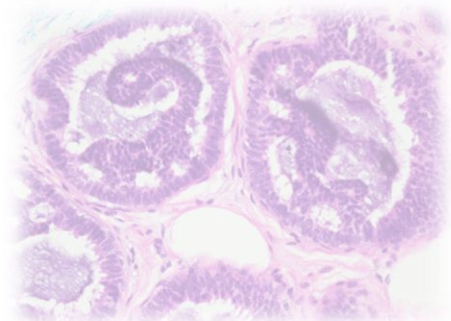
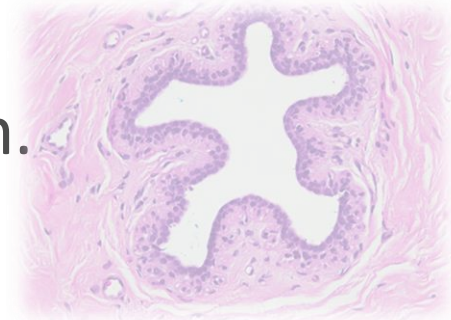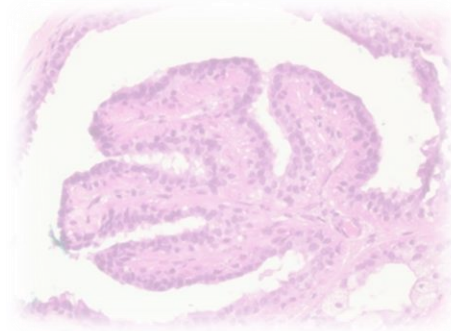


Division of Pathology
Singapore General Hospital



Diagnosis, case 24

- Right breast lump, excision biopsy:
Invasive ductal carcinoma, grade 3, 24mm.
ER+, PR+, cerbB2+ (3+).
Siliconoma.



Silicone and the breast

- Silicone prosthetics are widely used for breast augmentation and reconstruction.
- Free silicone injection into the breast also used in the past for breast augmentation.
- Silicone implants may extrude free silicone into surrounding tissue with attendant foreign body giant cell reaction.
- Signs and symptoms may mimic breast cancer.
- May radiologically (mammogram, US) mask an underlying breast cancer ~ MRI needed for evaluation.
- Migration to contralateral breast and axillary lymph nodes reported (*Cases J. 2009 Mar 10;2:6420*).

Thank You