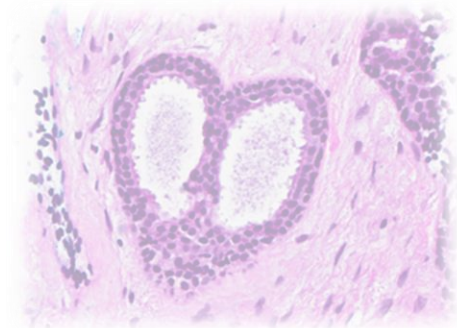
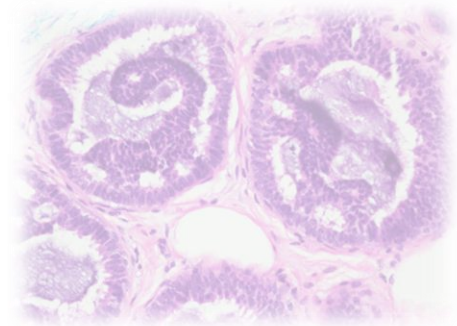
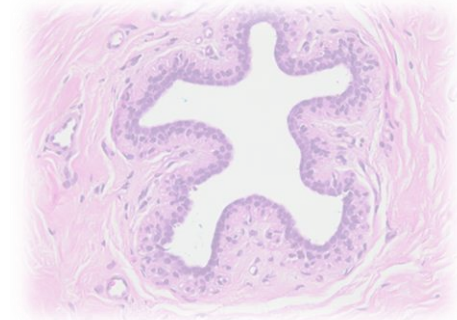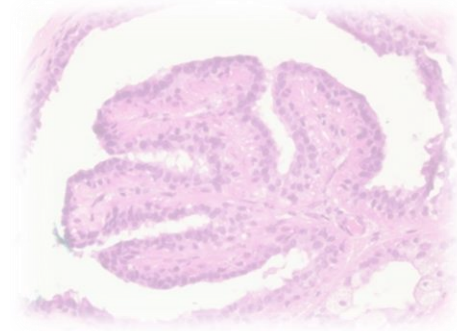
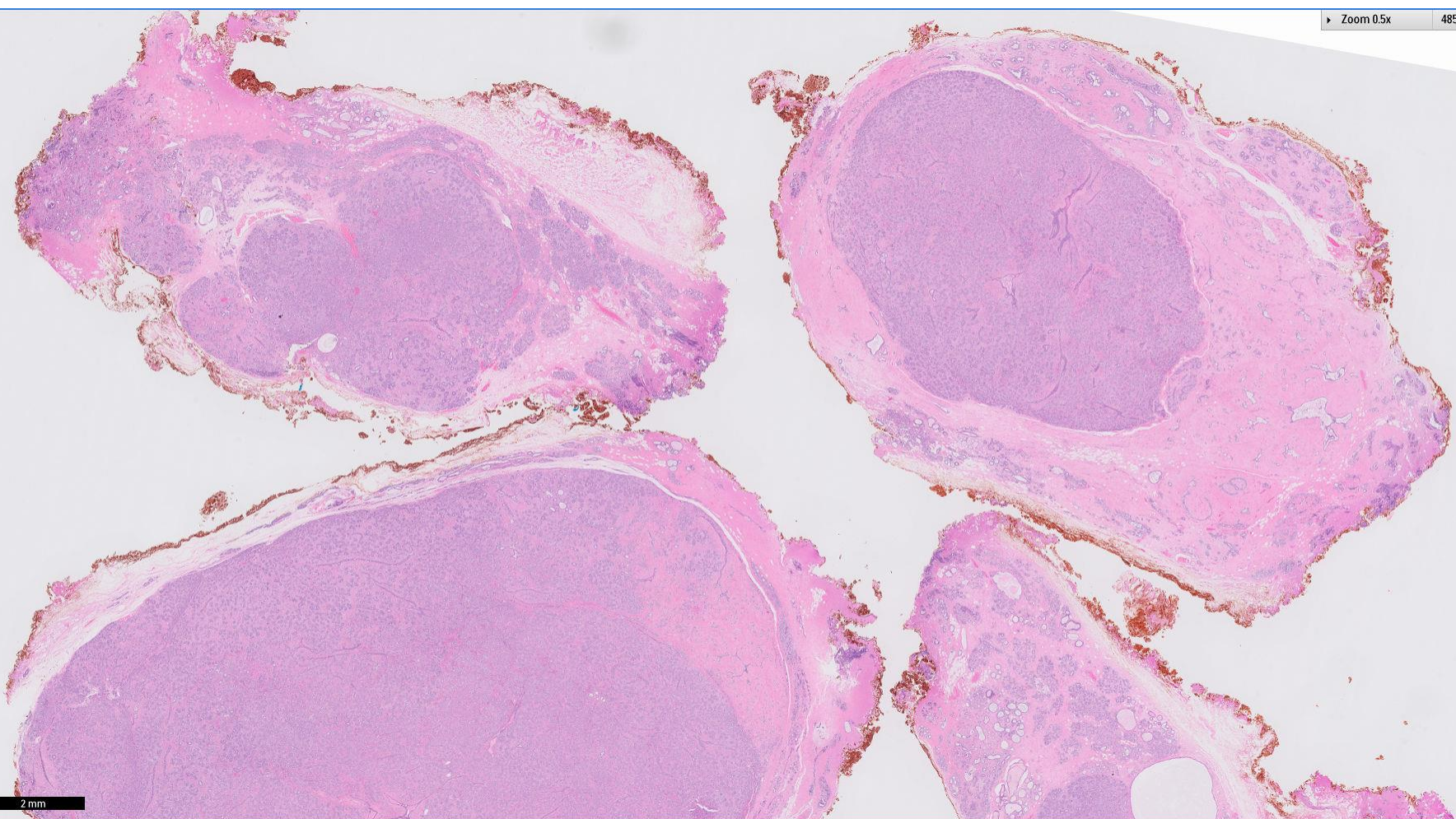


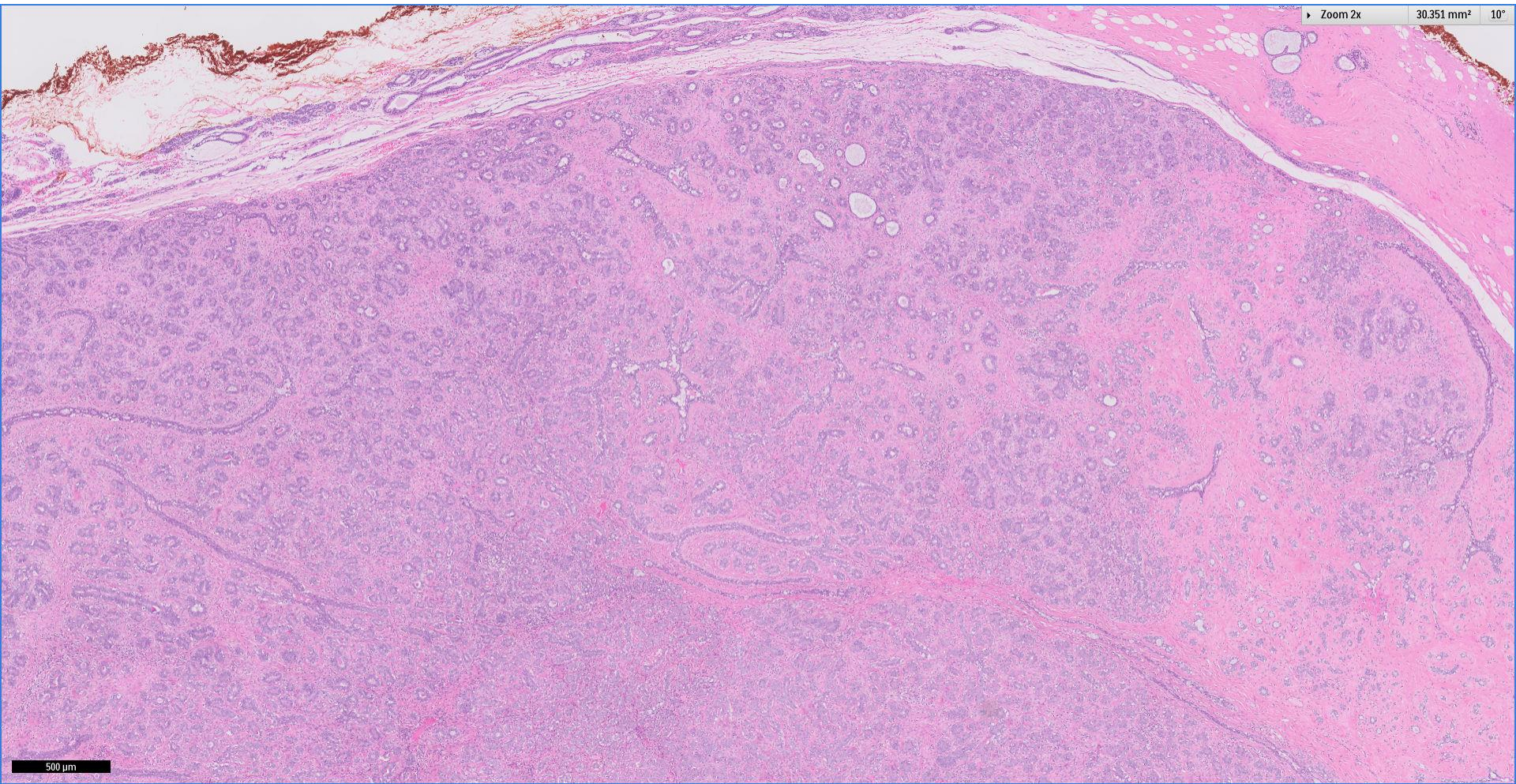
Case 20

29 year old Chinese female.
Right breast 10 o'clock lesion,
lumpectomy.



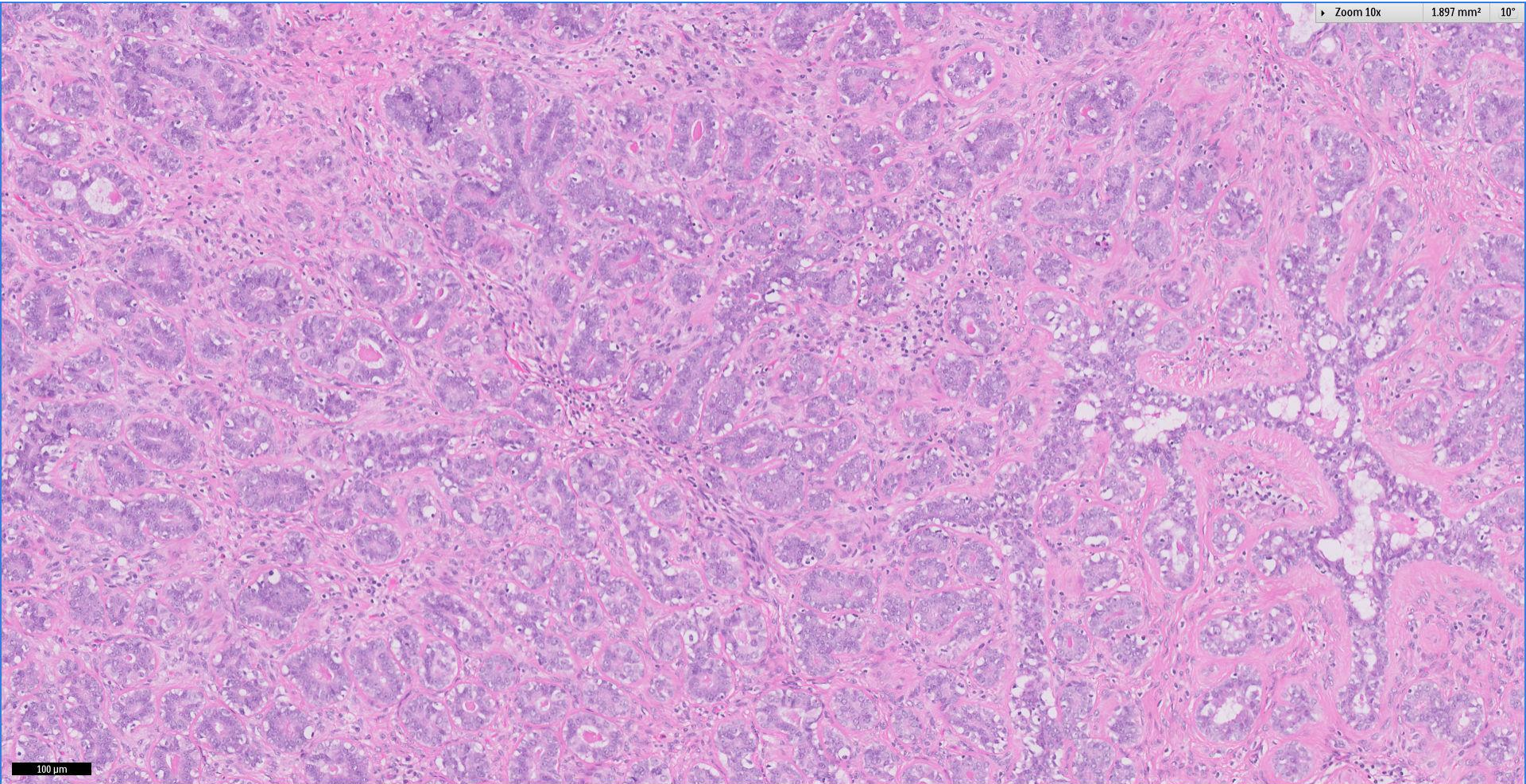


2 mm

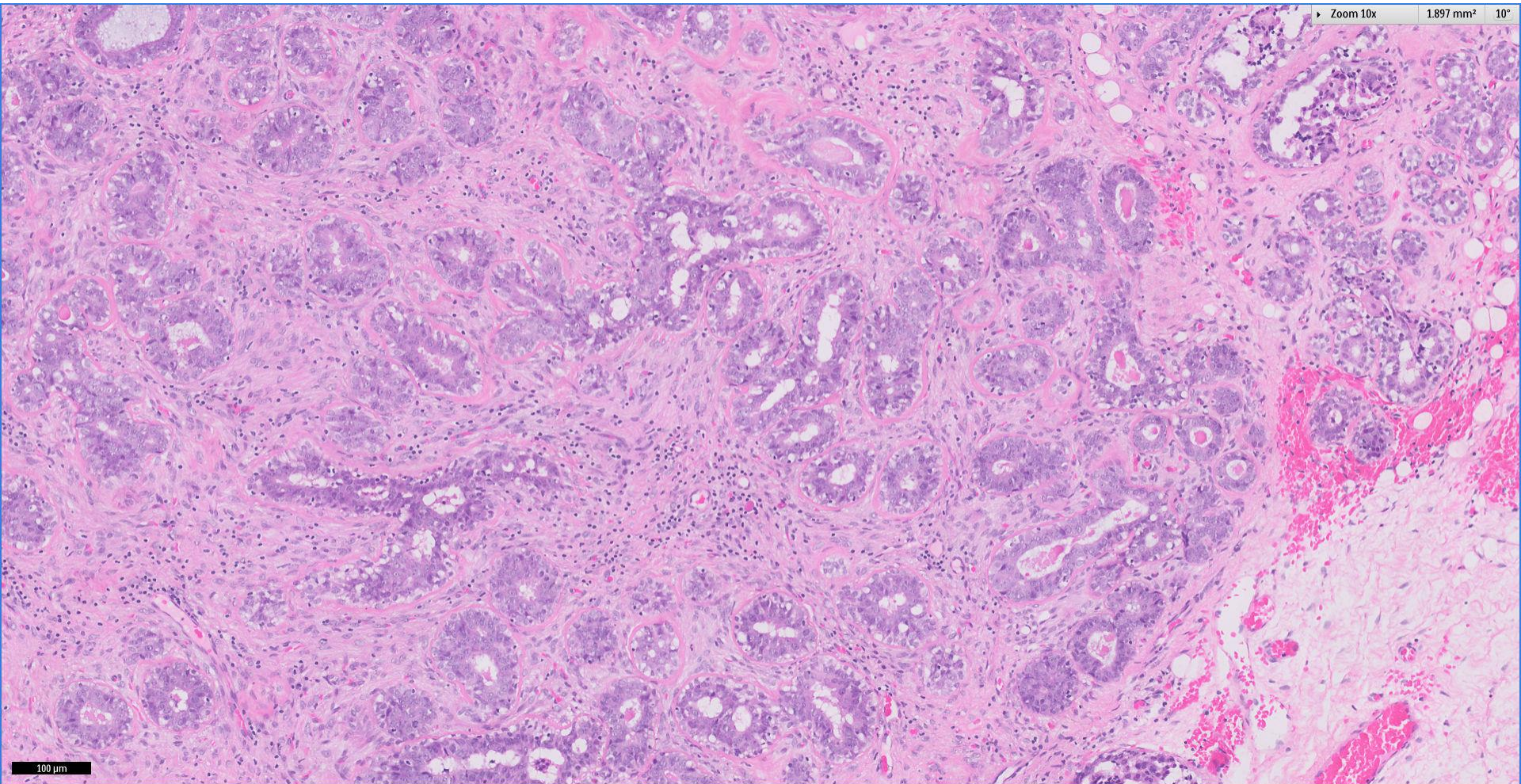


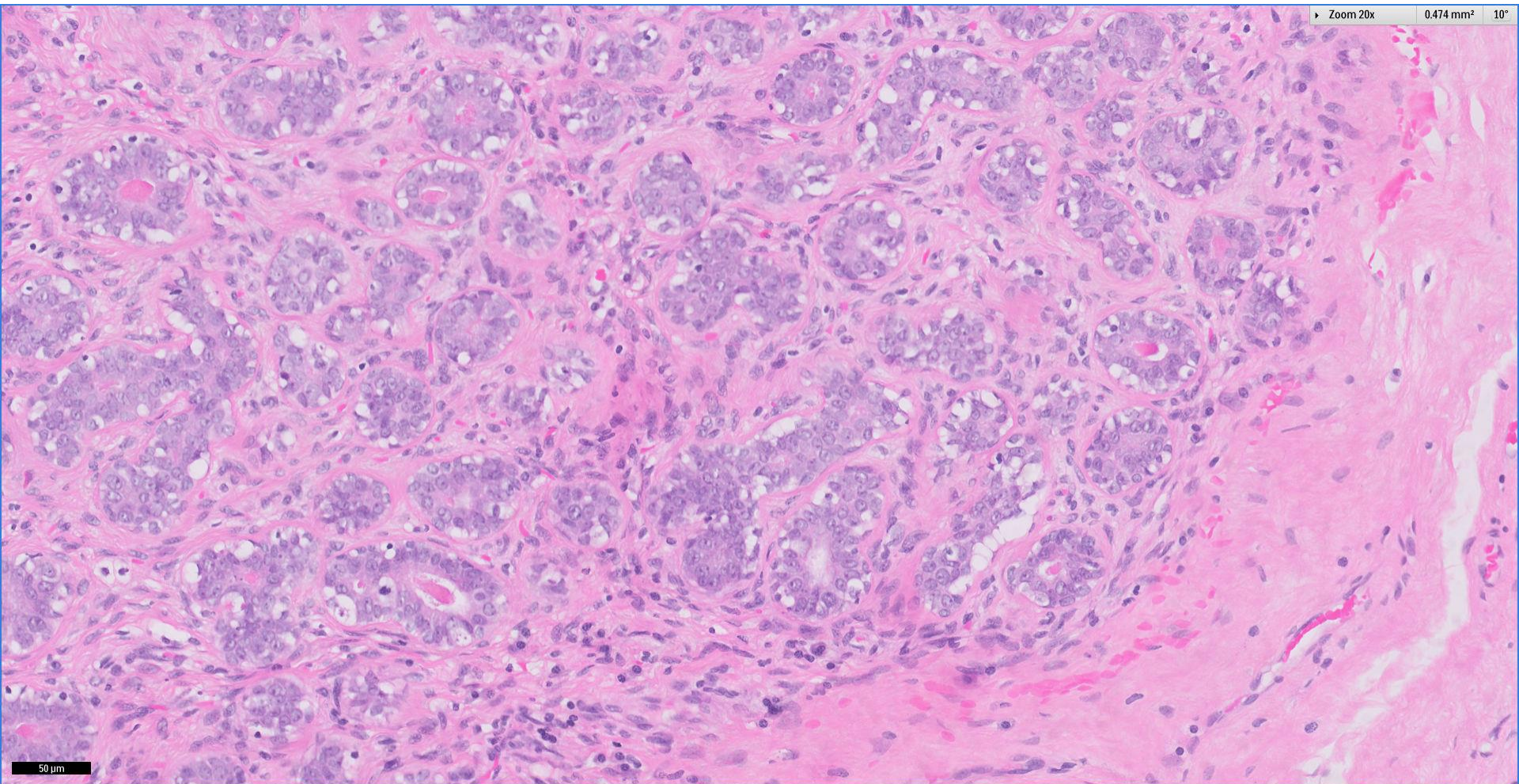
Division of Pathology
Singapore General Hospital





100 µm

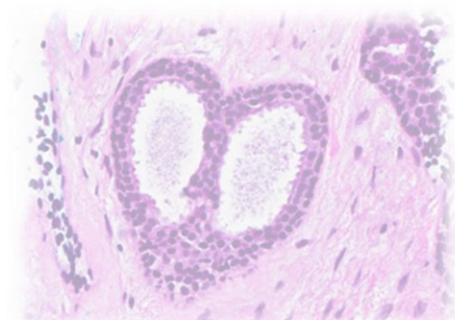
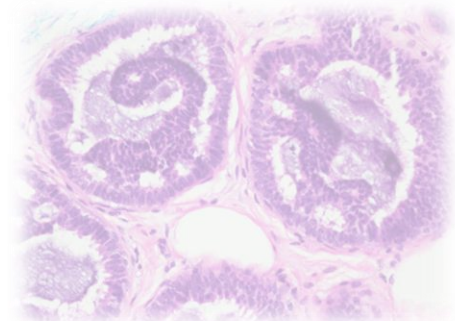
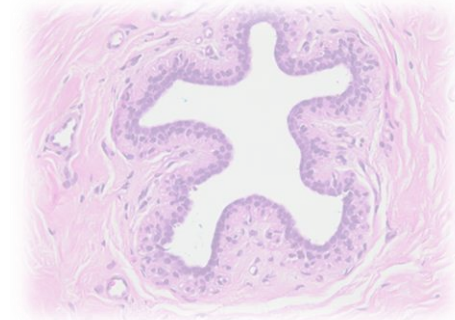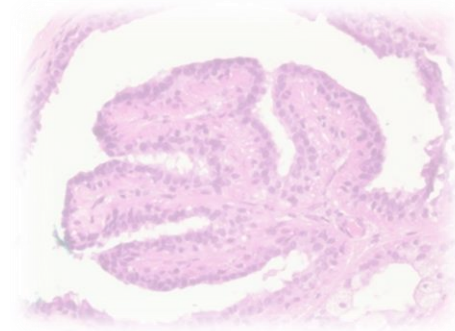




50 μm

Diagnosis, case 20

- Right breast 10 o'clock lesion, lumpectomy:
Tubular adenoma.



Tubular adenoma ~ definition

- Benign well-circumscribed tumour composed of a dense proliferation of closely approximated round and oval tubular structures composed of bilayered ductal and myoepithelial cells, with little background stroma.

Thank You