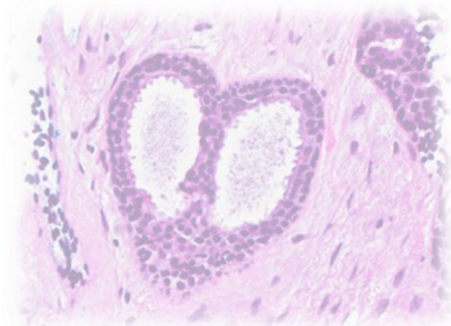
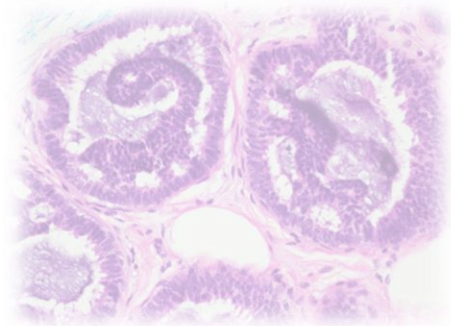
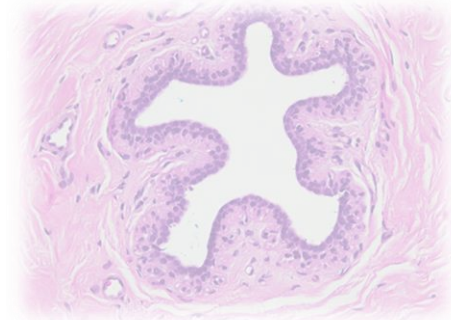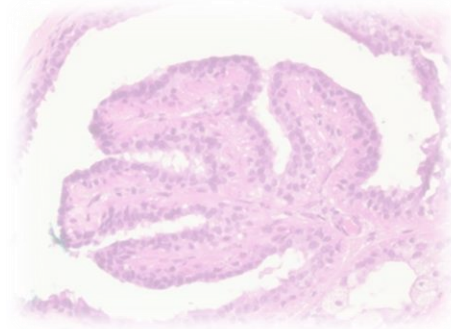
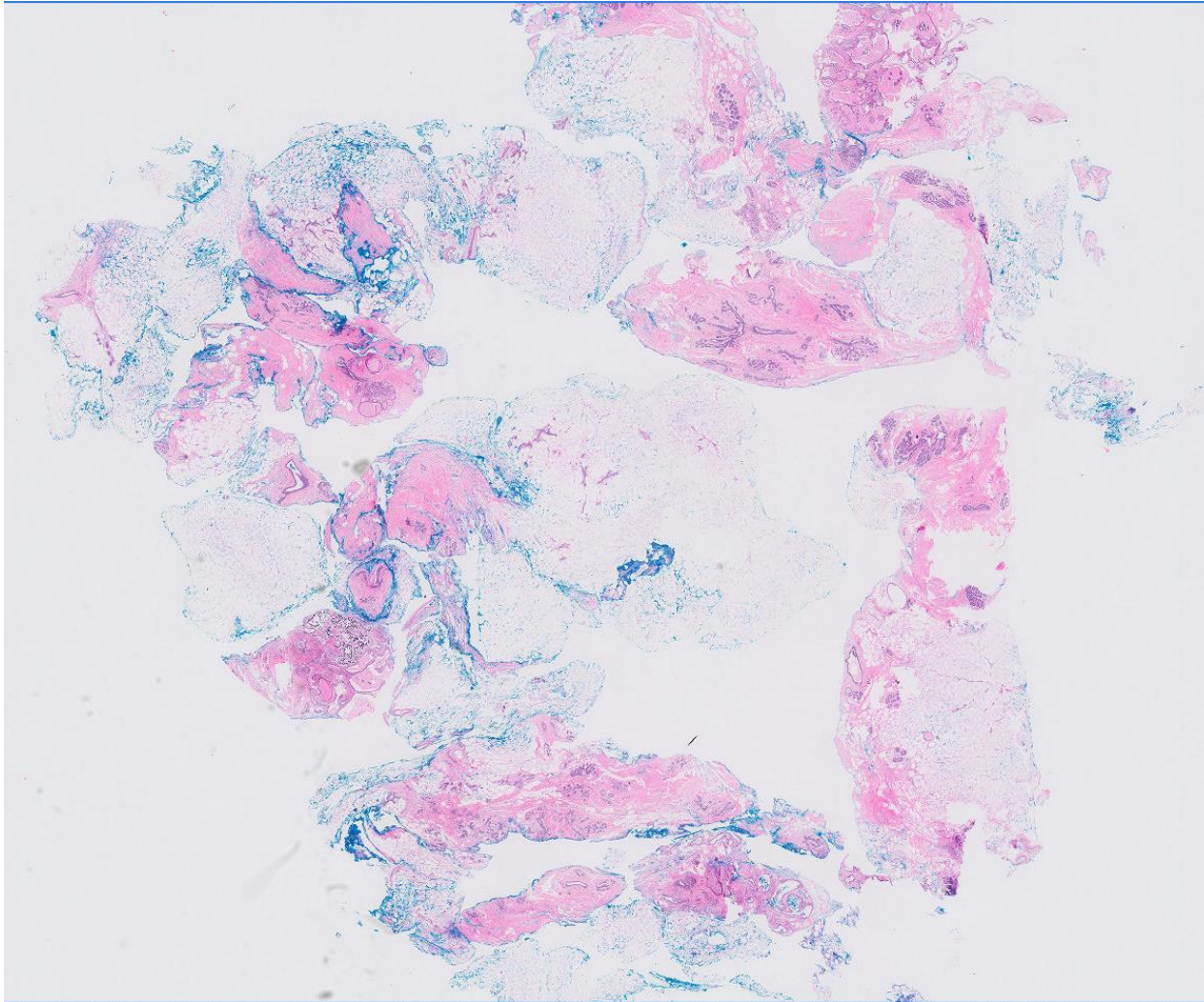


## Case 19

44 year old Chinese female.

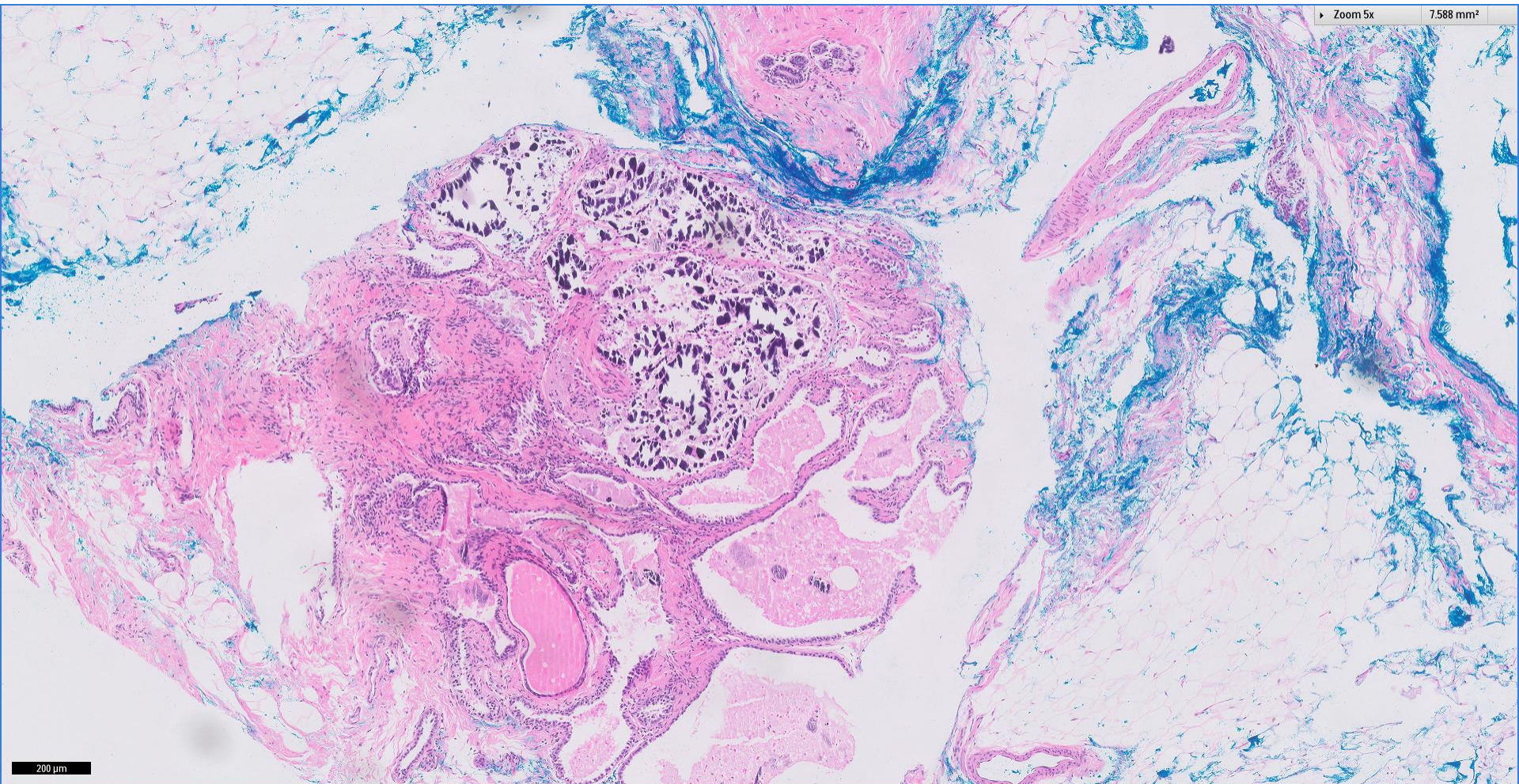
Stereotactic VAB for right breast UOQ  
calcifications.

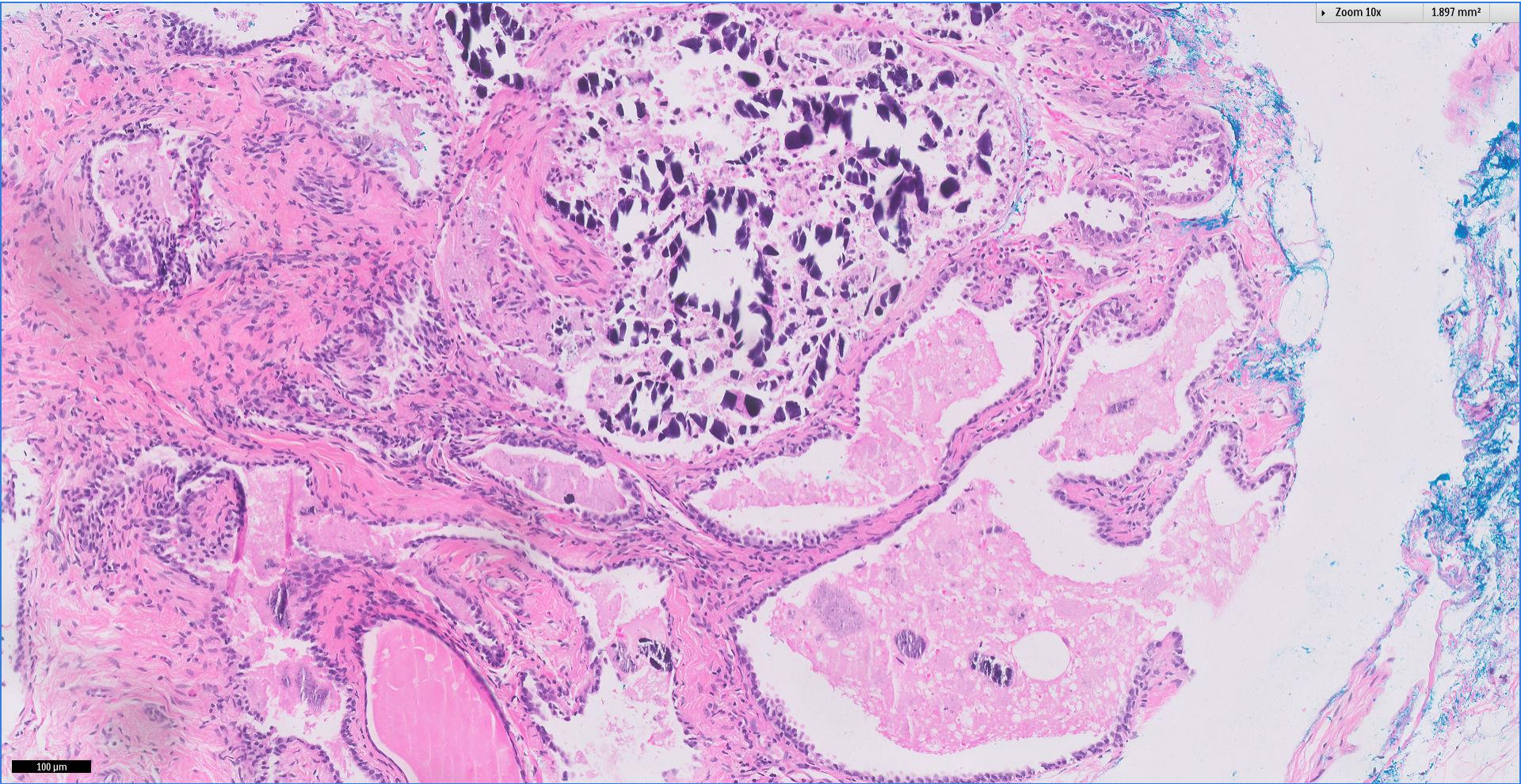




Division of Pathology  
Singapore General Hospital

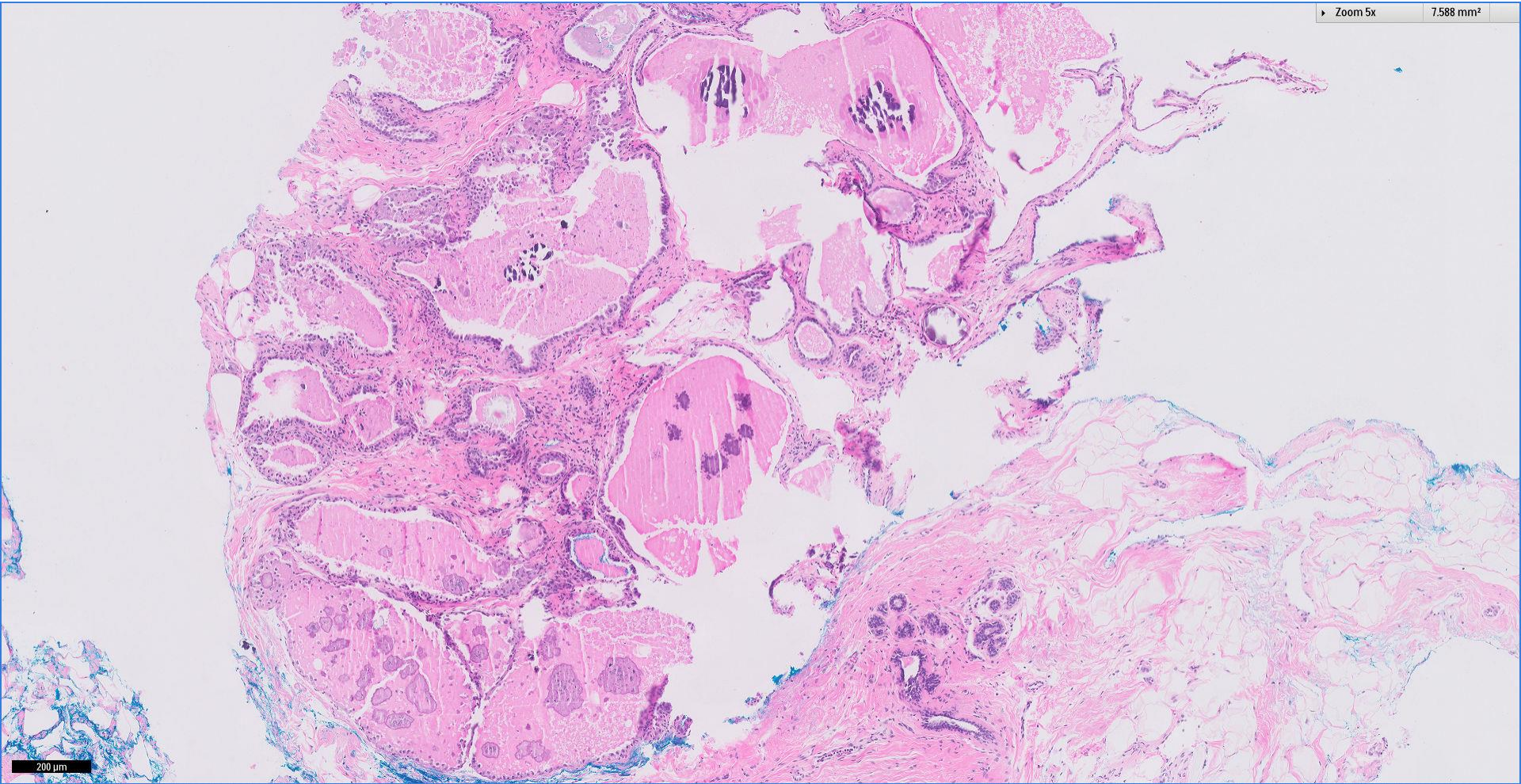


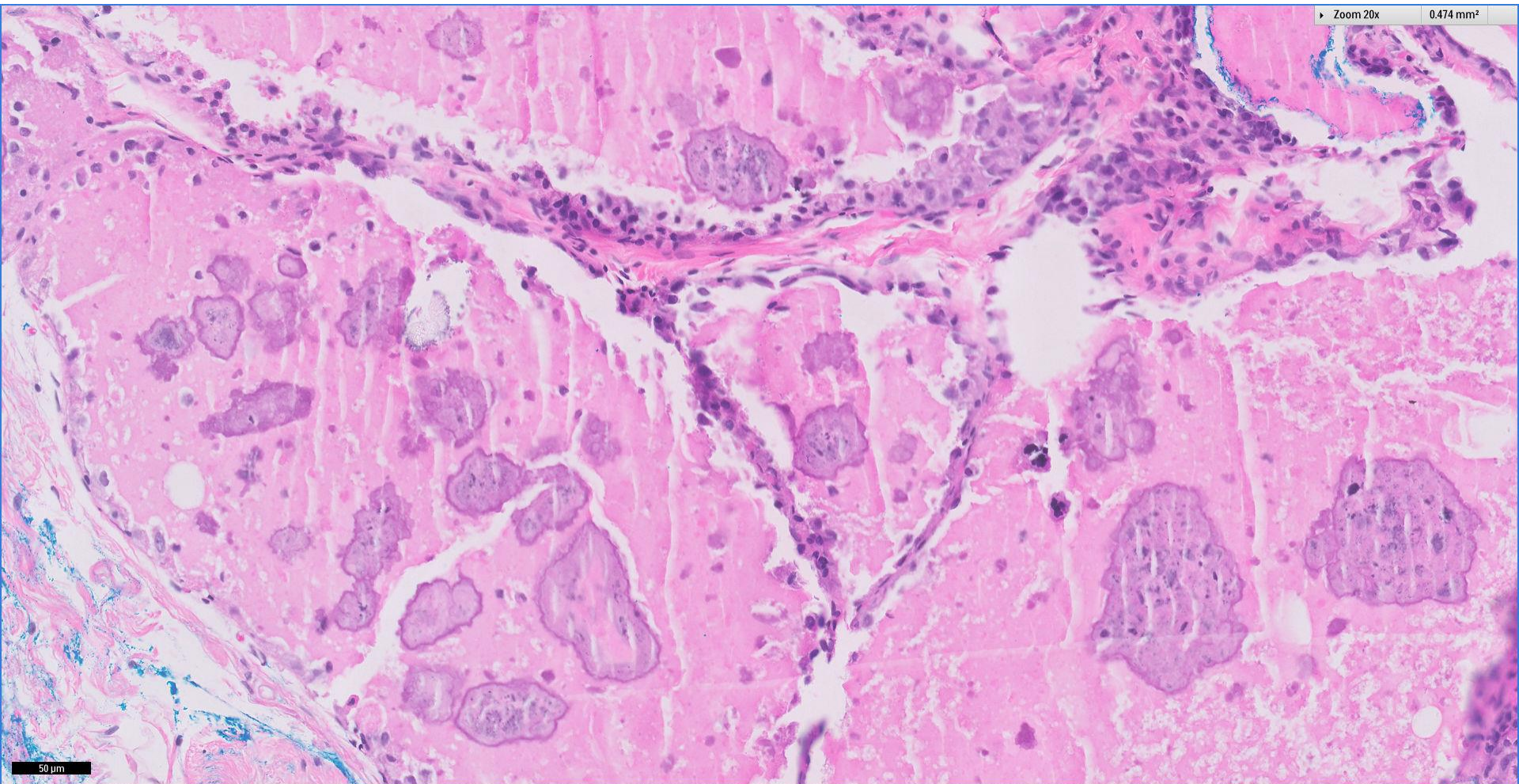




Division of Pathology  
Singapore General Hospital





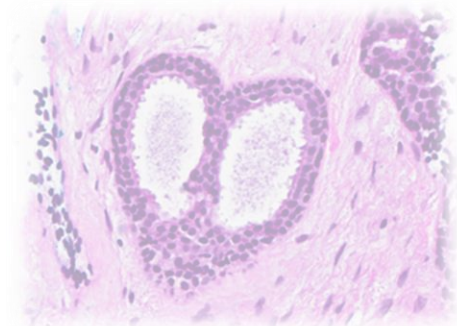
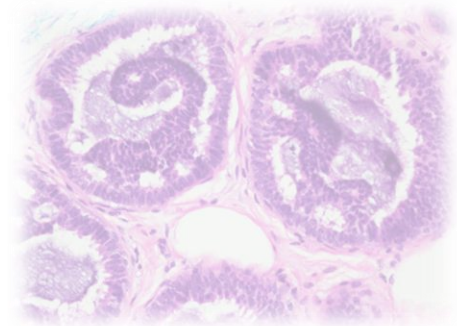
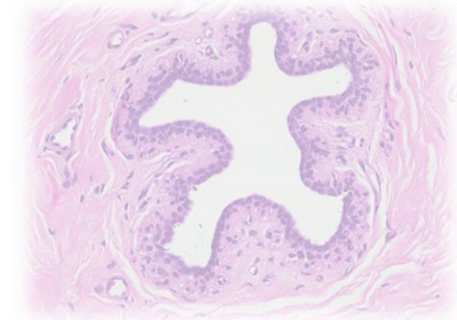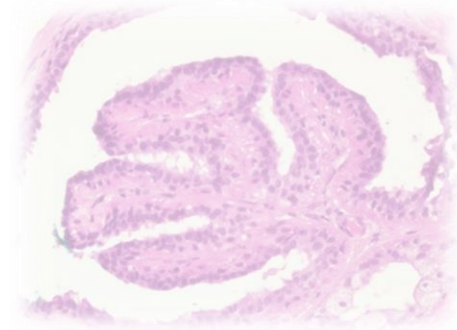


Division of Pathology  
Singapore General Hospital



# Diagnosis, case 19

- Stereotactic VAB for right breast  
UOQ calcifications:  
Fibrocystic changes with pregnancy-like  
changes and calcifications.



*Thank You*