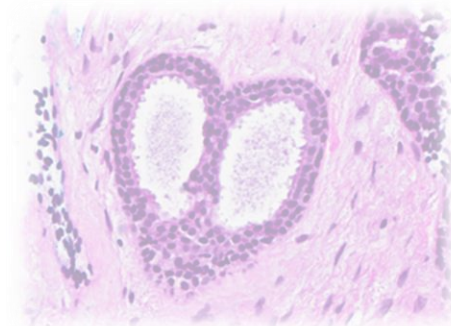
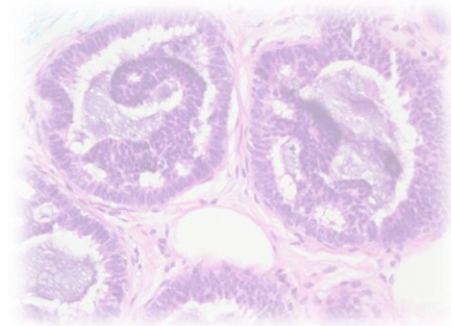
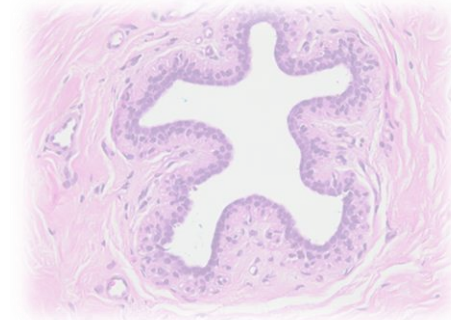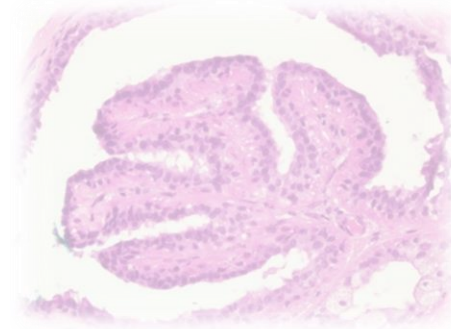
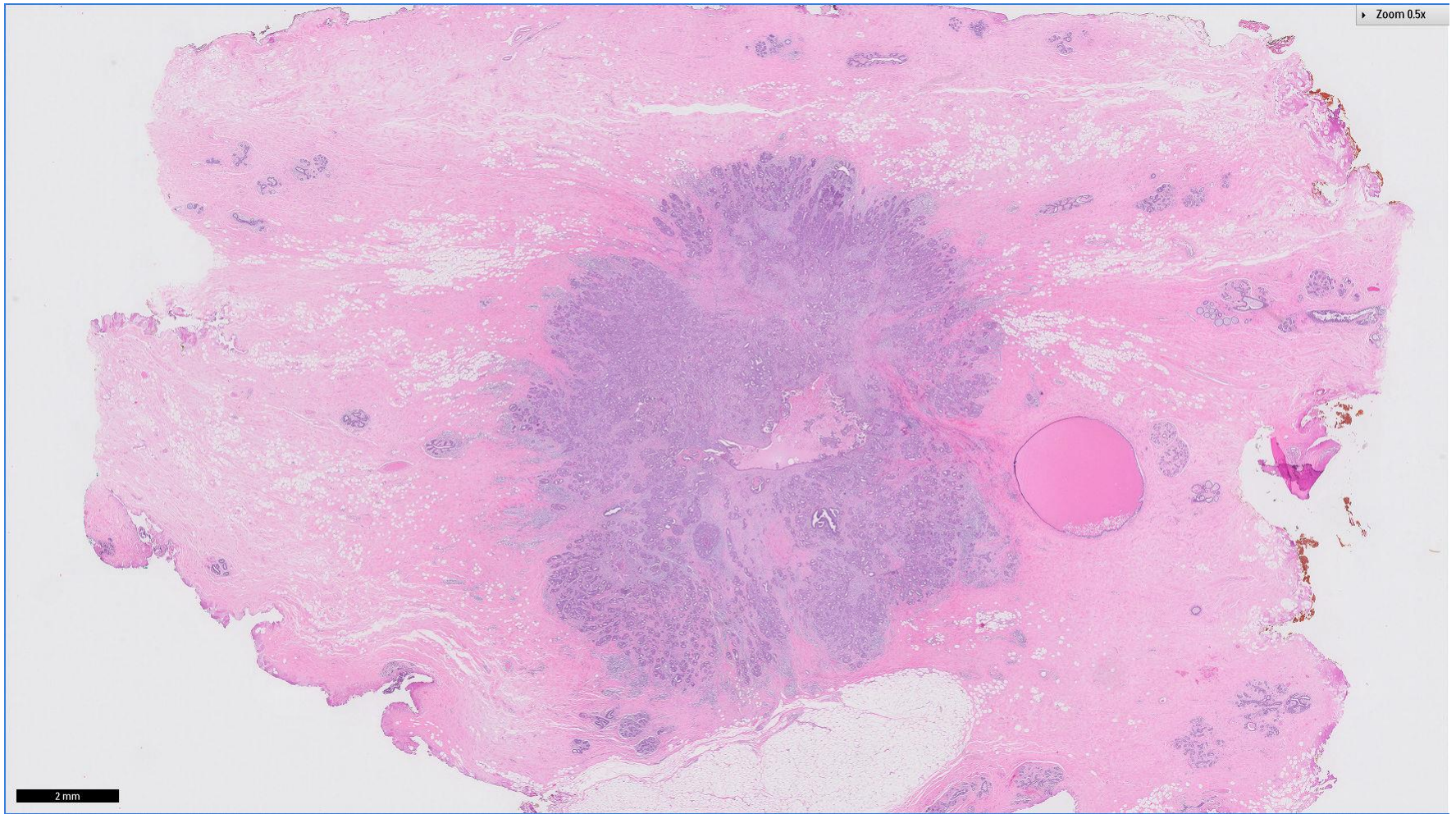


## Case 8

38 year old Chinese female.  
Left breast wide excision.

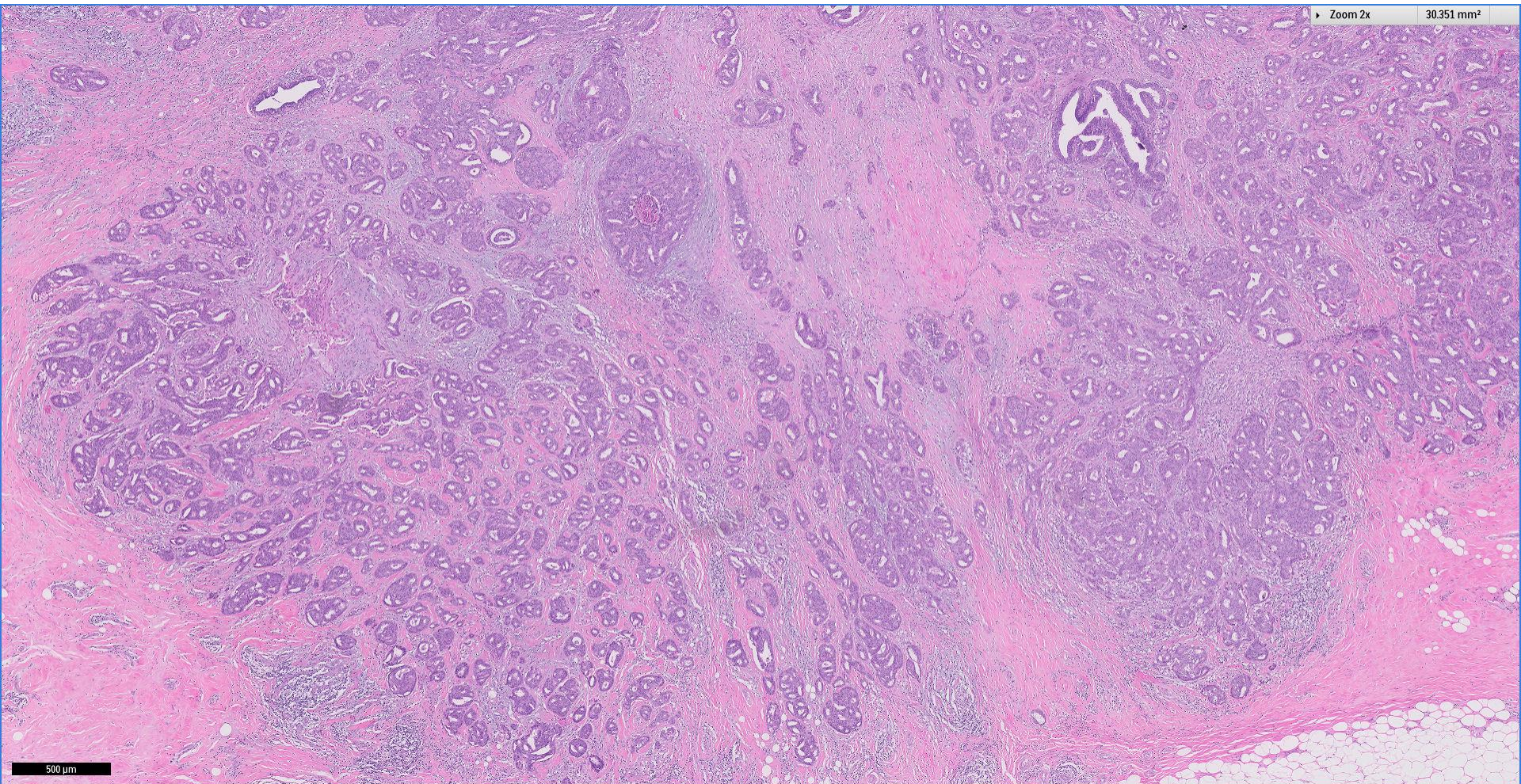




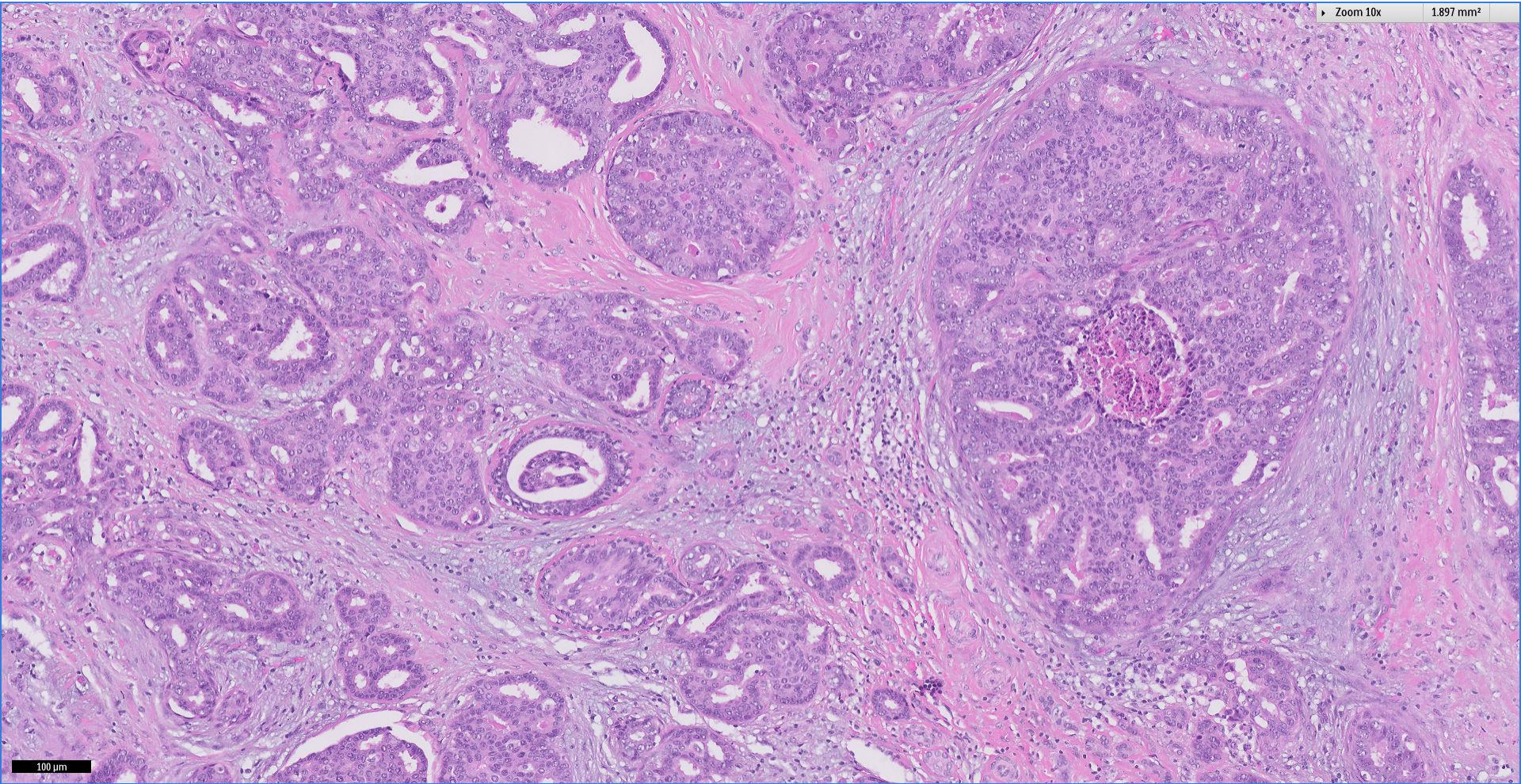
Division of Pathology  
Singapore General Hospital



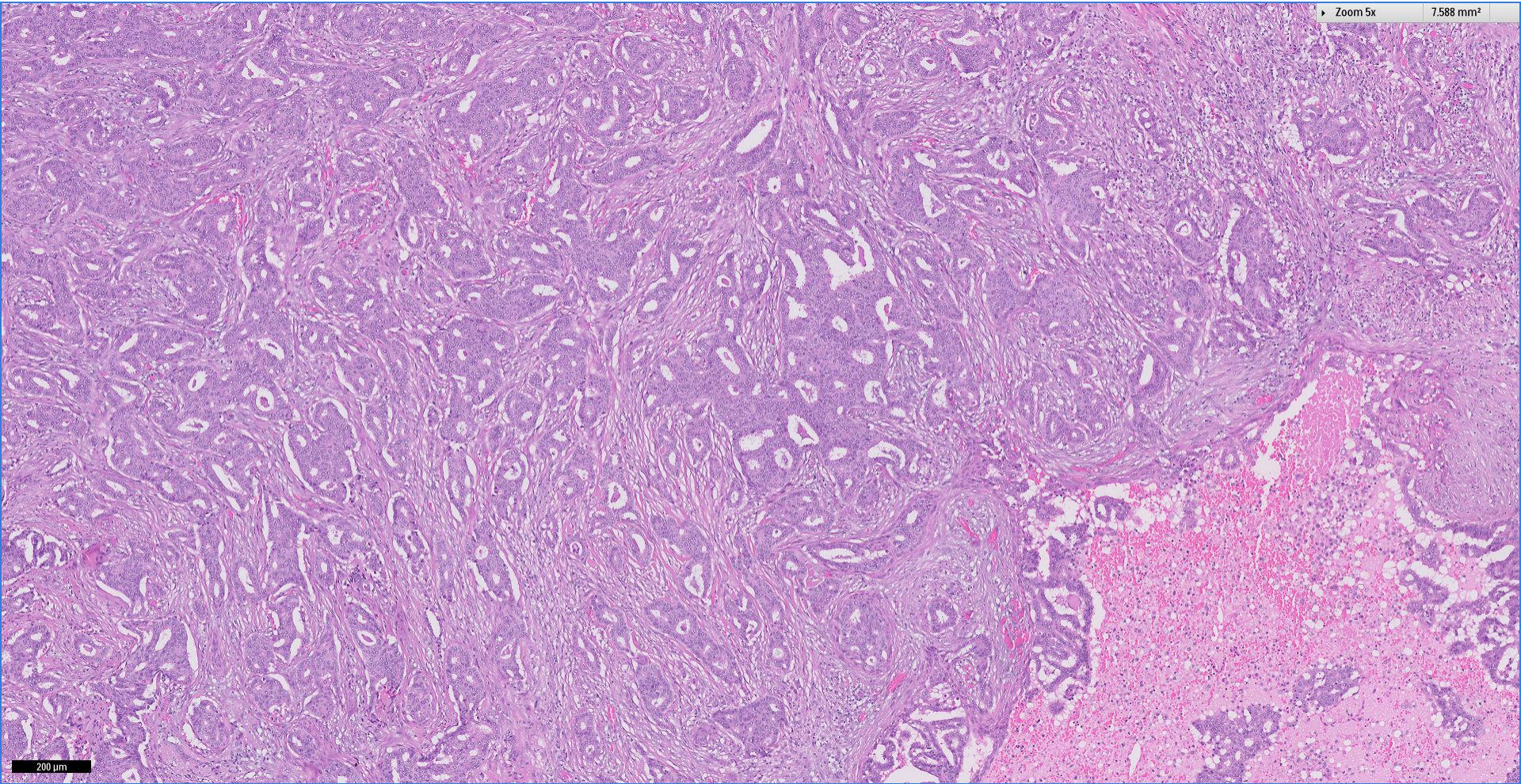








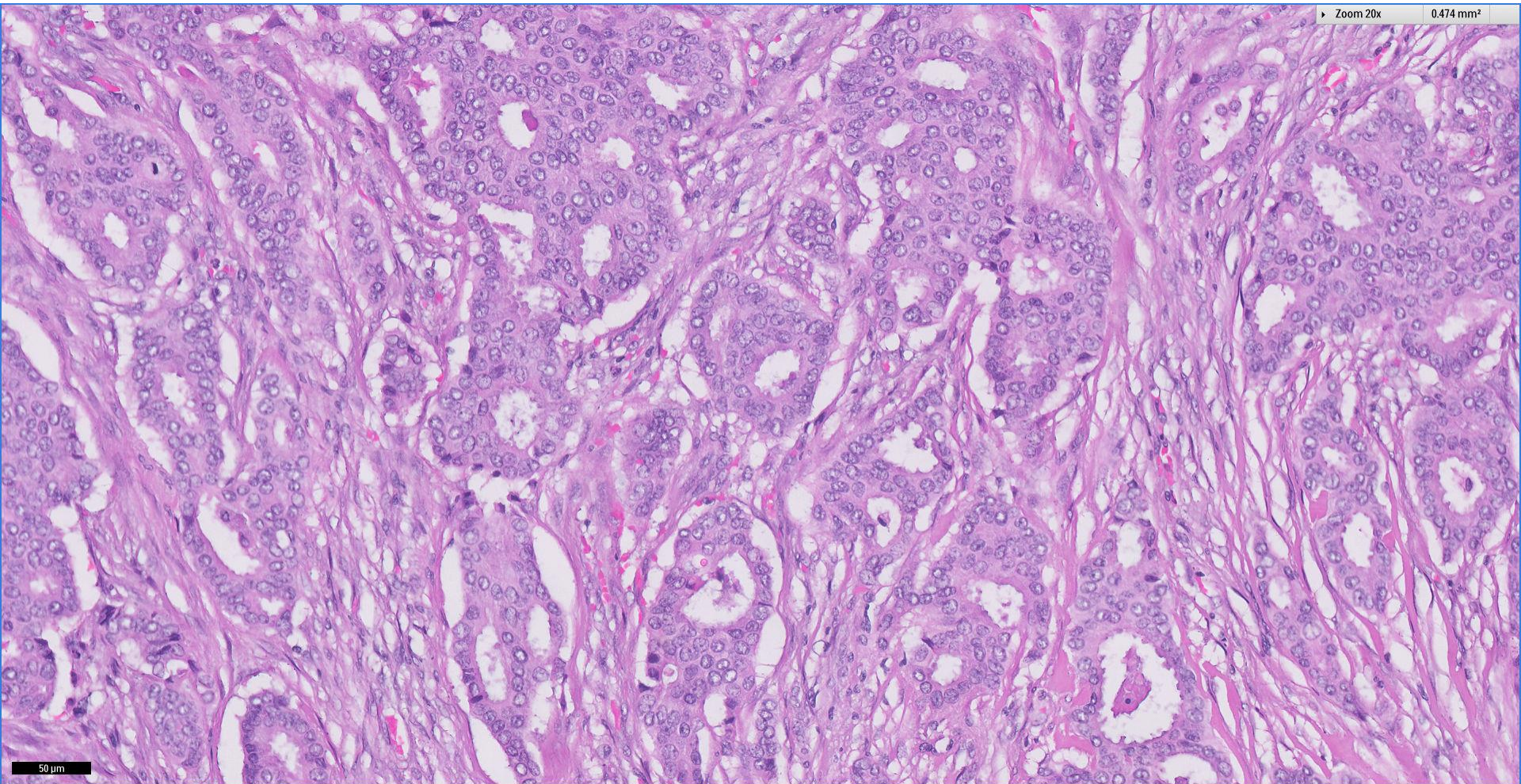




Division of Pathology  
Singapore General Hospital



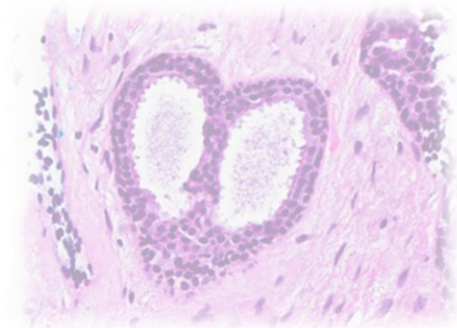
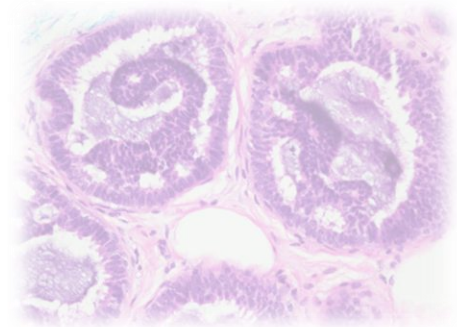
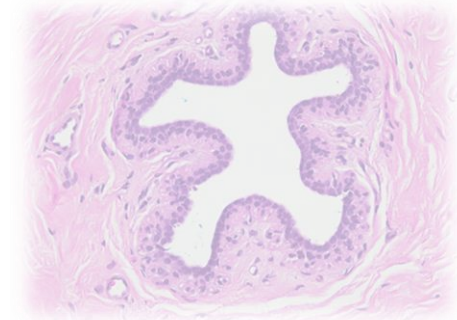
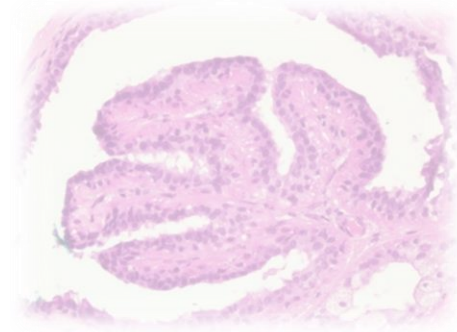




Division of Pathology  
Singapore General Hospital

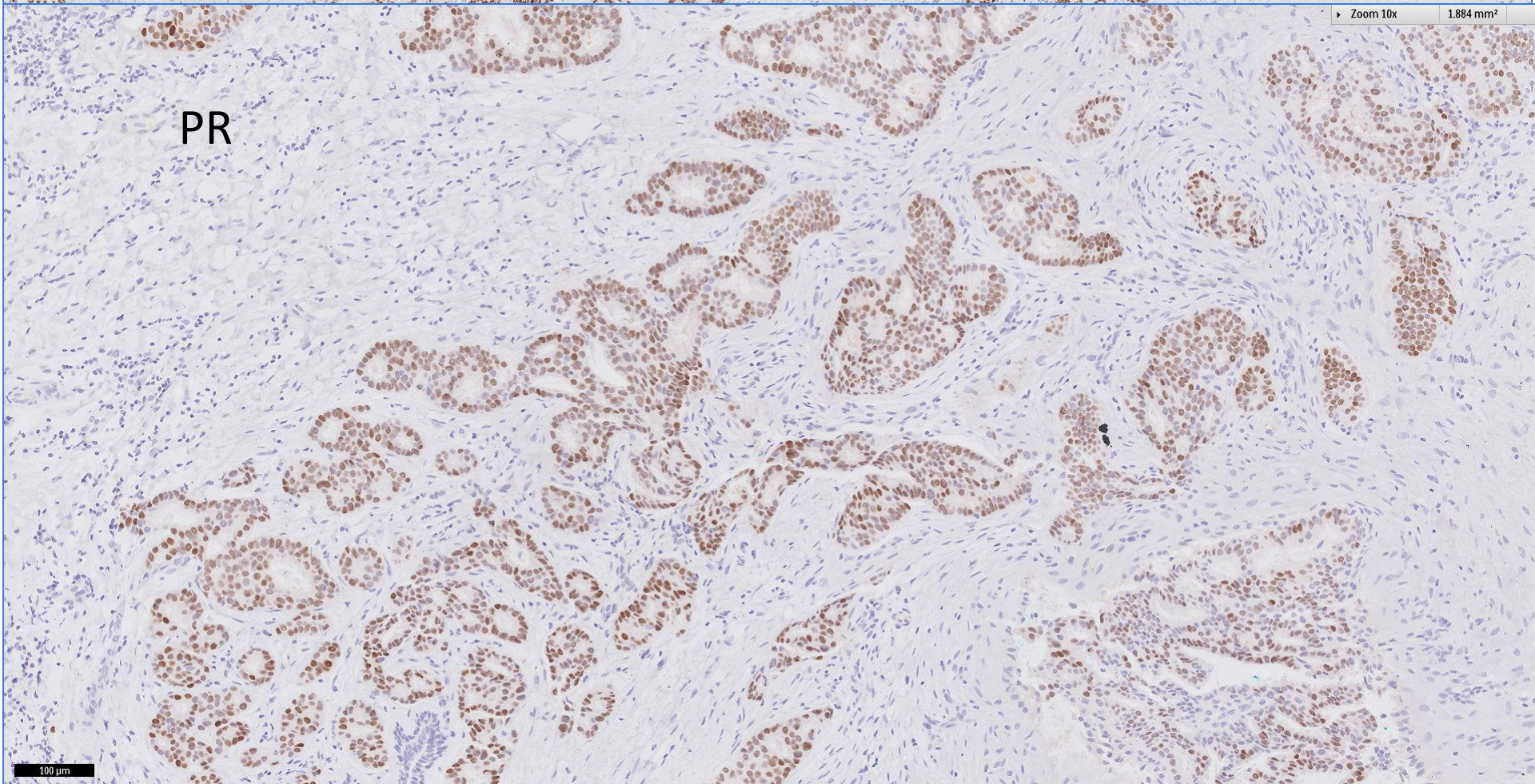
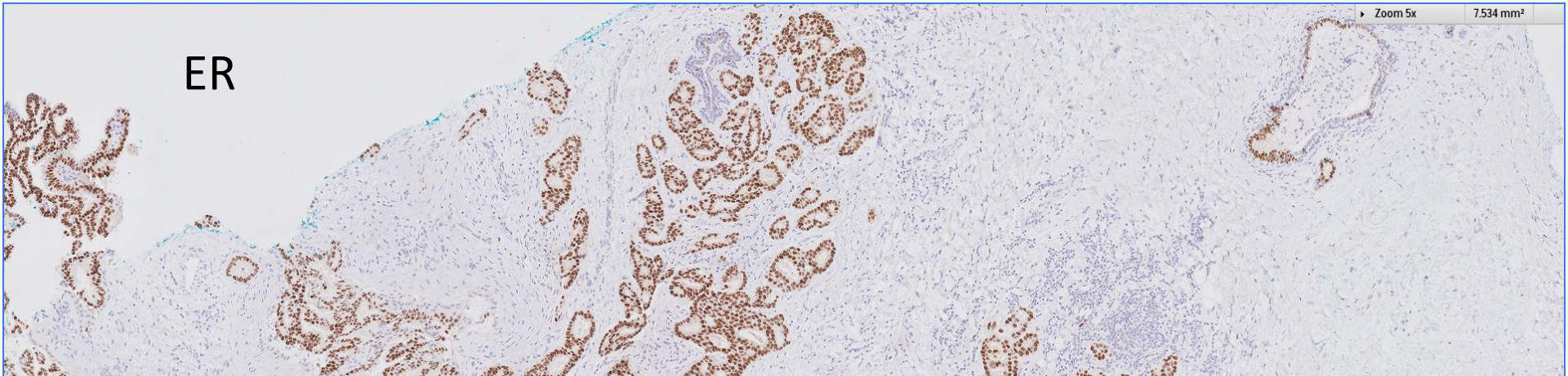






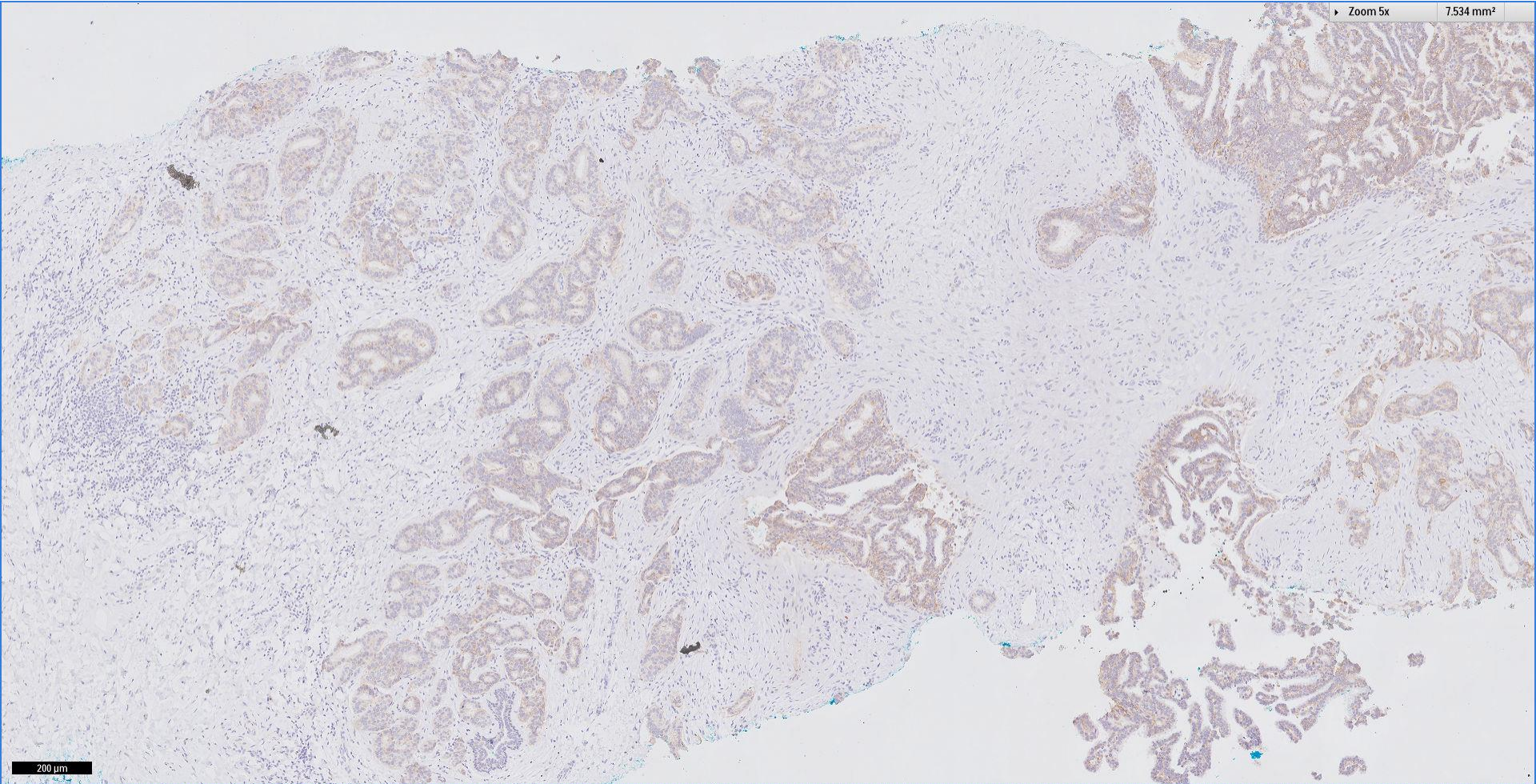
# *Additional pictures*





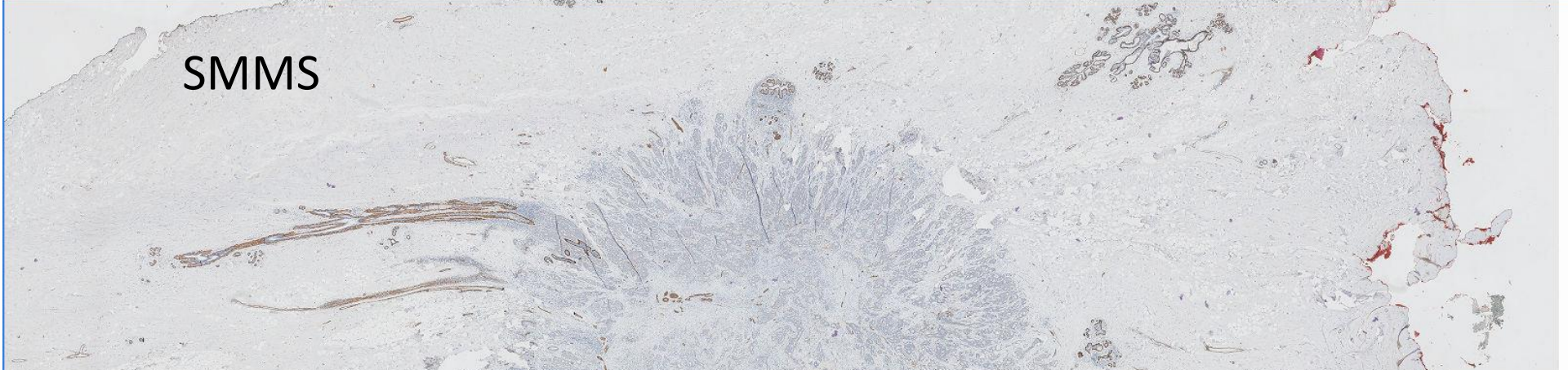

cerbB2

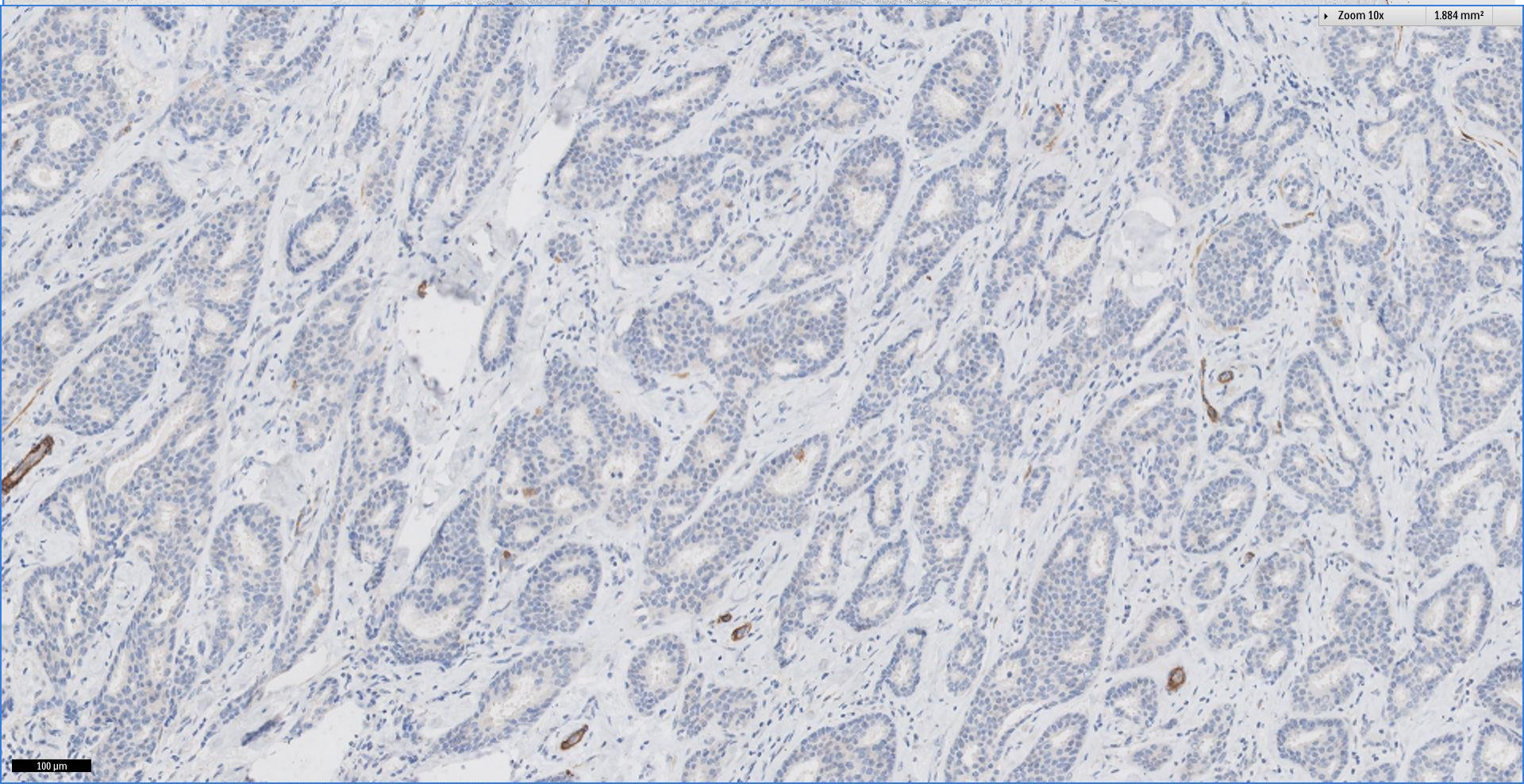




SMMS



Zoom 10x 1.884 mm<sup>2</sup>

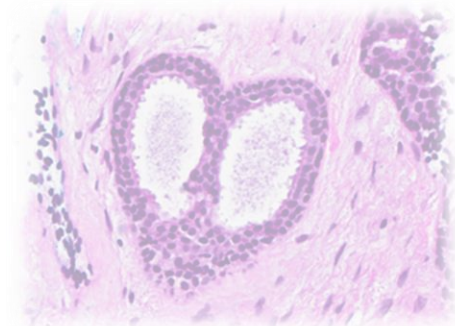
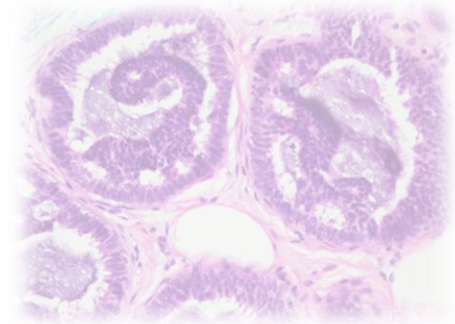
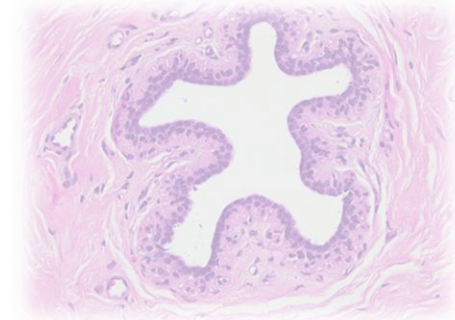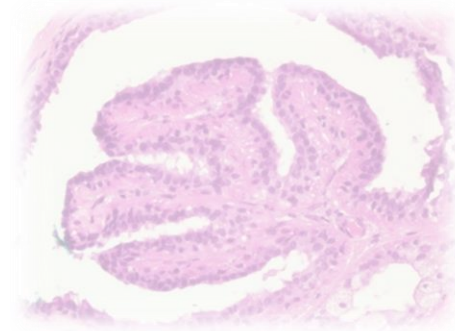


100 μm



# Diagnosis, case 8

- Left breast, wide excision:  
Invasive cribriform carcinoma, grade 1,  
17mm.  
ER+, PR+, cerbB2 negative.  
Four benign sentinel lymph nodes.





# *Invasive cribriform carcinoma*

- Low-grade invasive carcinoma composed of islands of tumour cells with well-defined cribriform spaces.

WHO 2019



# *Invasive cribriform carcinoma ~ clinical features*

WHO 2019

- No specific clinical feature distinguishes invasive cribriform carcinoma (ICC) from other types of breast cancer.
- ICC may present as a mass, but it is frequently clinically occult.
- On mammography, ICC typically forms a spiculated mass, and it may harbour microcalcifications.
- Multifocality is observed in 10–20% of cases.



# *Invasive cribriform carcinoma*

WHO 2019

- **Epidemiology** ~

- Pure ICC is rare, accounting for approximately 0.4% of all invasive breast carcinomas.
- Median patient age at presentation is 63 years, and only 25% of patients are aged < 50 years.

- **Pathogenesis** ~

- ICC has genomic and transcriptomic features similar to those of tubular carcinoma (both belong to the luminal A molecular class), with a similar immunophenotype (consistent expression of hormone receptors and lack of ERBB2 [HER2] overexpression), and both are associated with the same family of low-grade precursor lesions.



# *Invasive cribriform carcinoma*

- **Macroscopic appearance ~**

- No specific macroscopic features differentiate ICC from invasive (ductal) carcinoma of no special type (NST).
- ICC usually consists of a firm/hard spiculated mass, with a mean size of 31 mm.
- ICCs as large as 20 cm have been described.

WHO 2019



# *Invasive cribriform carcinoma*

WHO 2019

- **Histopathology** ~

- Invasive epithelial islands containing well-defined, rounded spaces similar in appearance to cribriform-type (“cribriform” meaning “sieve-like” or “perforated”) ductal carcinoma in situ (DCIS).
- Tumour islands have an ovoid or angular outline and are set within a desmoplastic stroma.
- They comprise multilayered epithelial cells of small to intermediate size forming secondary glandular structures lined by cuboidal to columnar cells.
- Apical secretions are sometimes present and the spaces may contain mucinous secretions with or without calcification.
- Mitotic activity is sparse and there is no substantial nuclear atypia.



# *Invasive cribriform carcinoma*

WHO 2019

- **Histopathology** ~

- If strict grading criteria are applied, ICCs should be Nottingham grade 1 tumours (with cribriform pattern given a score of 1 for tubule formation).
- Stromal osteoclast-like giant cells have been described.
- Low- or intermediate-grade DCIS, usually with cribriform architecture, is present in 80% of cases.
- Immunohistochemistry for myoepithelial markers may be used to distinguish ICC from cribriform DCIS.
- ICCs are typically ER-positive (95–100%) and PR-positive (69–89%), HER2-negative (94%) and form part of the low-grade breast neoplasia pathway.



# *Invasive cribriform carcinoma*

WHO 2019

## • **Cytology ~**

- Diagnosis of ICC on FNA is problematic.
- Direct smears show relatively cohesive sheets and 3D clusters of somewhat bland epithelial cells.
- Groups of cells show a cribriform pattern.
- Naked bipolar nuclei and myoepithelial cells are absent.
- A definitive diagnosis of ICC is rarely (if ever) possible on FNA, and the differentiation from cribriform-type DCIS is not possible by cytology alone.
- For this reason, core needle biopsy is the preferred method of preoperative diagnosis.



# *Invasive cribriform carcinoma*

WHO 2019

- **Essential criteria ~**

- An invasive breast carcinoma with > 90% of the tumour composed of cribriform islands of epithelial cells with low-grade nuclei and sparse mitosis (grade 1).
- ER-positive and HER2-negative.

- **Staging ~**

- ICC usually presents at early stage.
- 76% are T1 and 83% N0 at presentation.

- **Prognosis and prediction ~**

- Outcome for patients with ICC is favourable.
- 10-year overall survival rates are between 90% and 100%.
- Outcome for patients with mixed ICC is less favourable than for patients with the pure form, but better than for patients with invasive breast carcinoma NST.
- Biological behaviour of ICC is similar to that of tubular carcinoma.
- Many tumours have no tubular component.
- Definition of ICC as a distinct clinicopathological entity appears to be justified.



*Thank You*