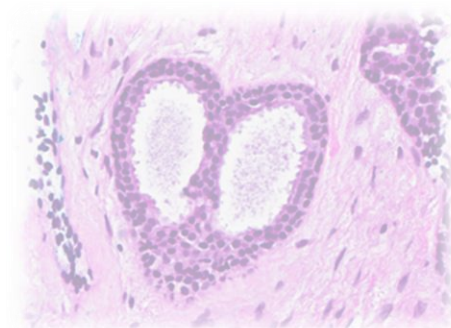
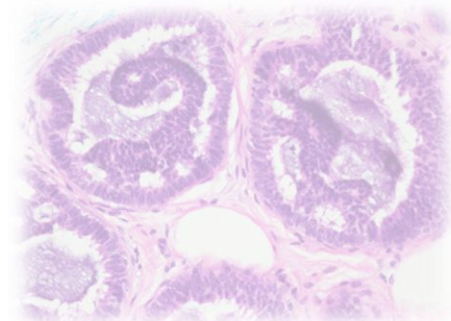
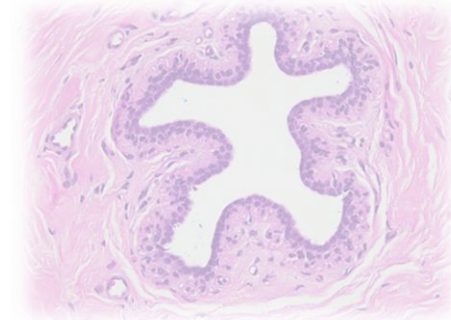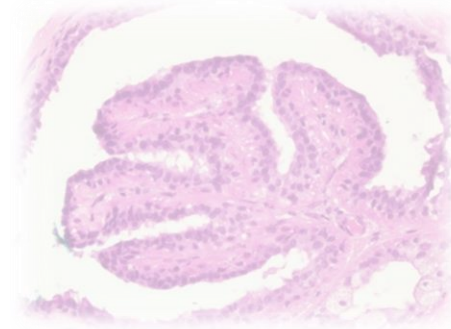
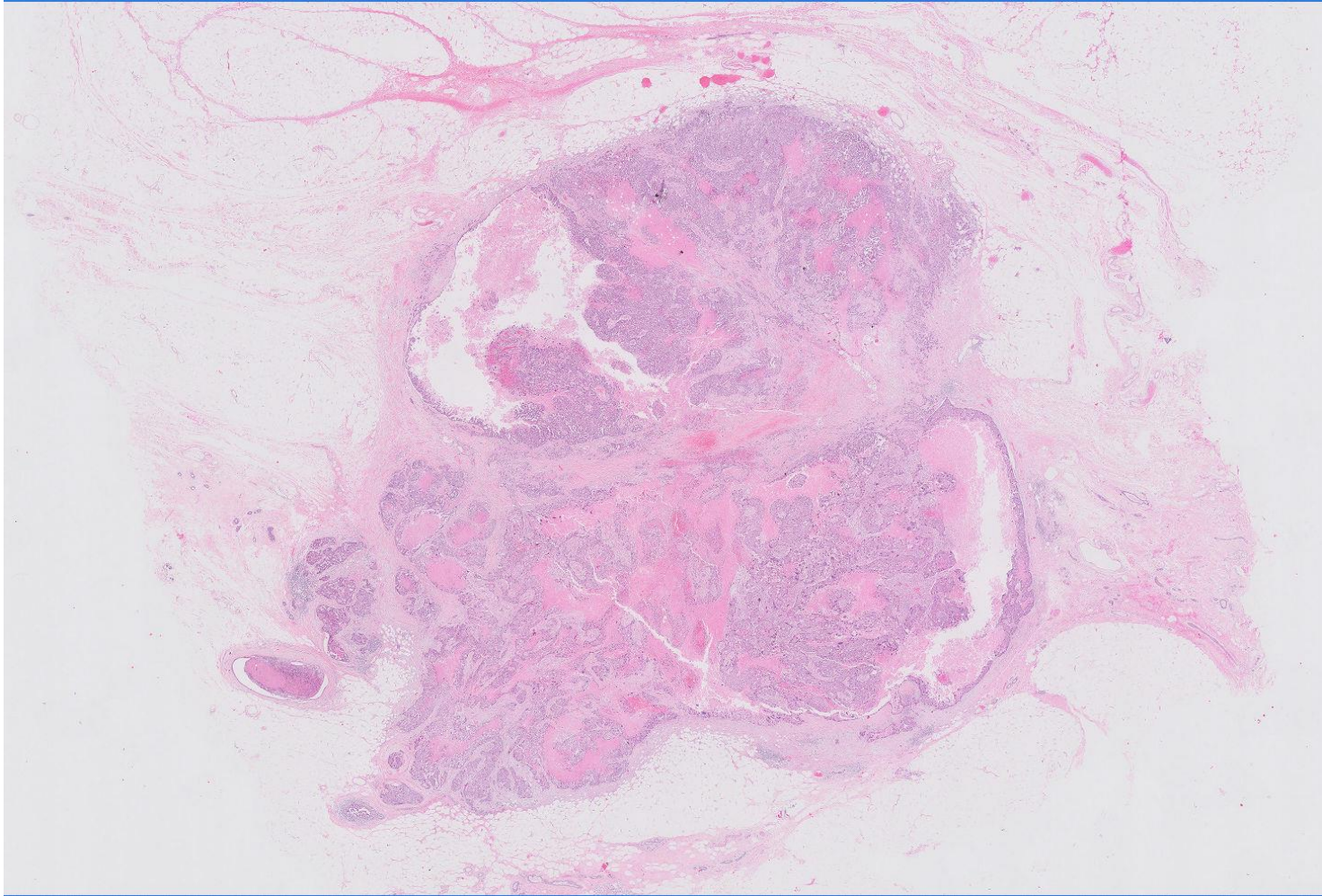
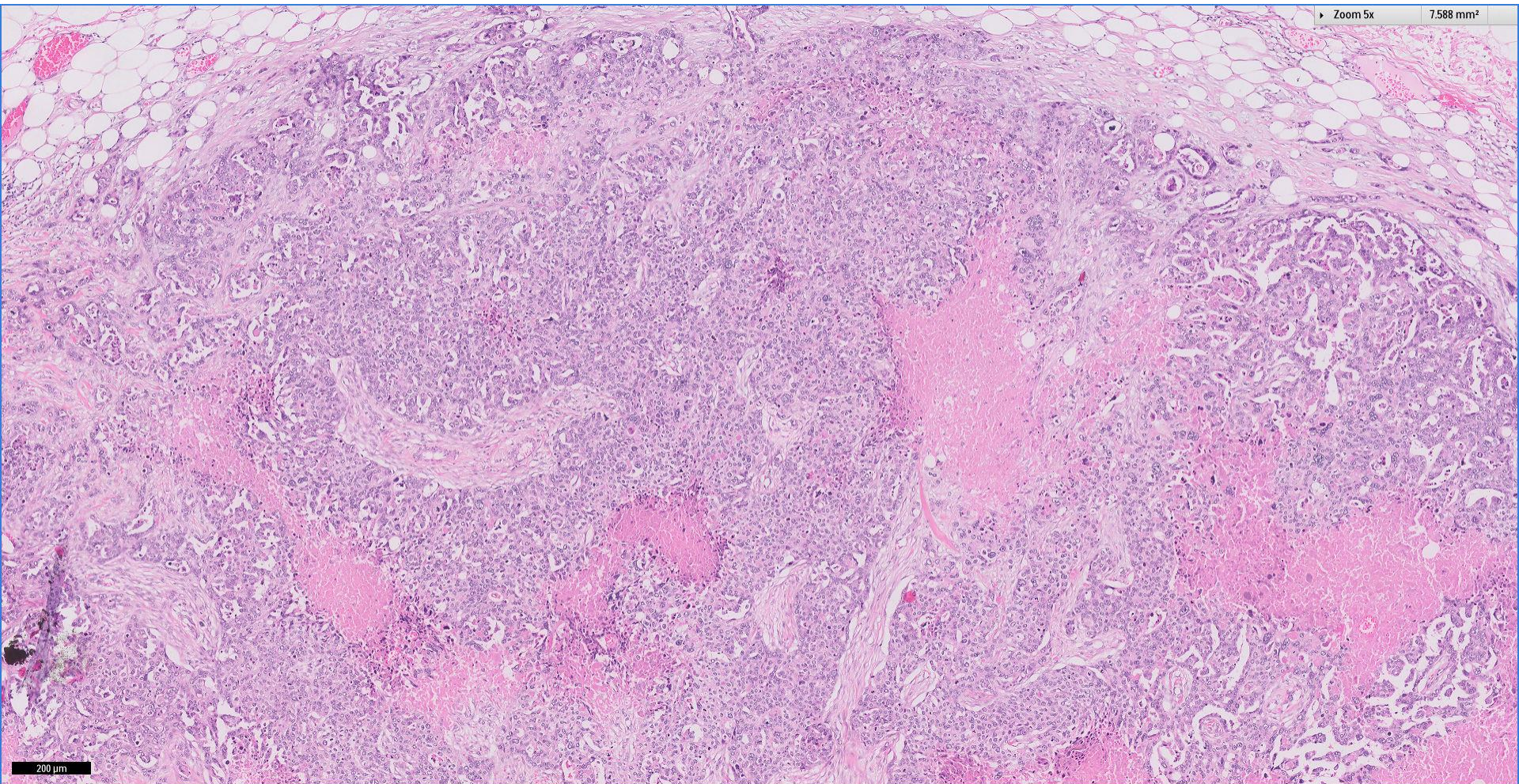


Case 6

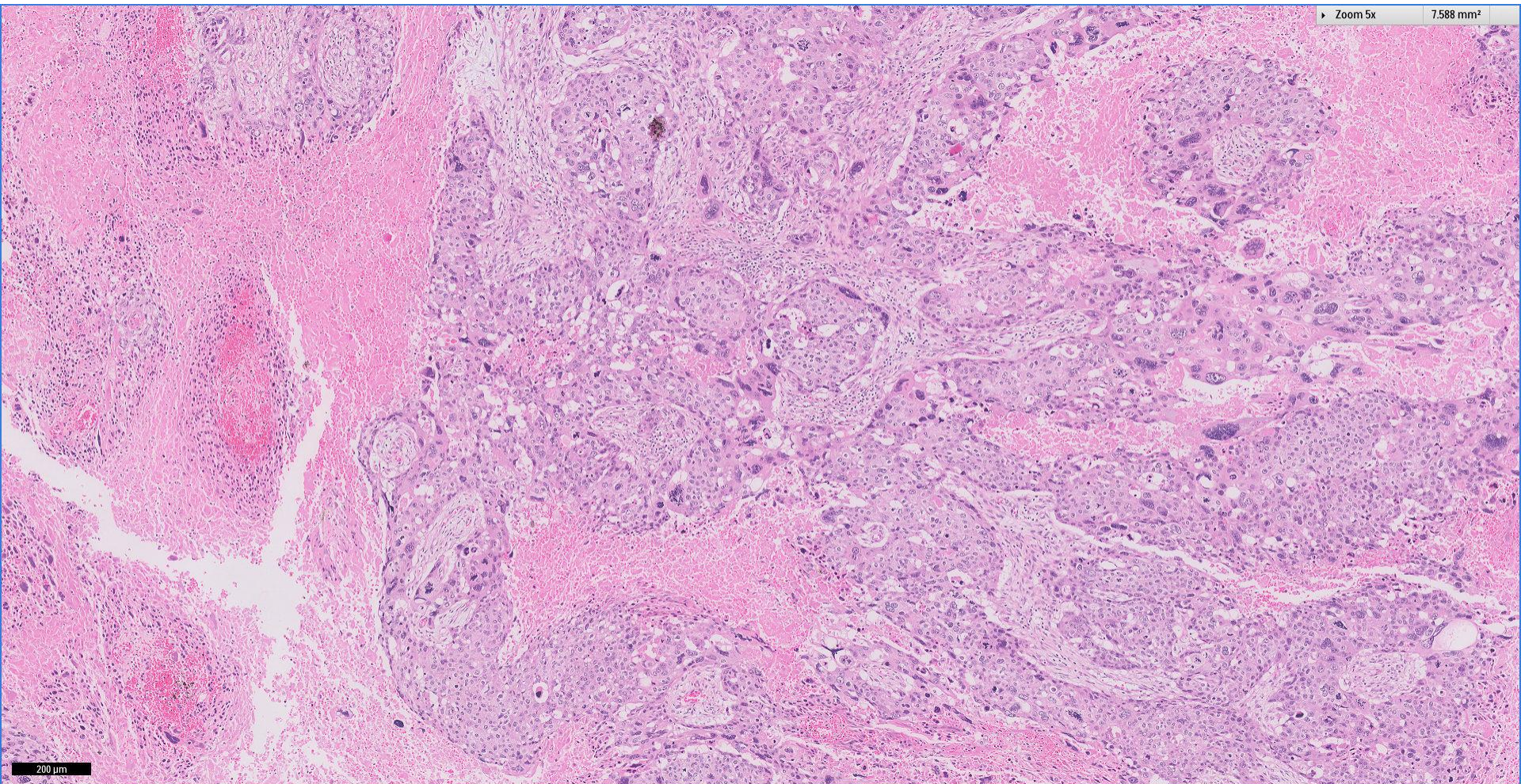
75 year old female.
Left breast mastectomy.

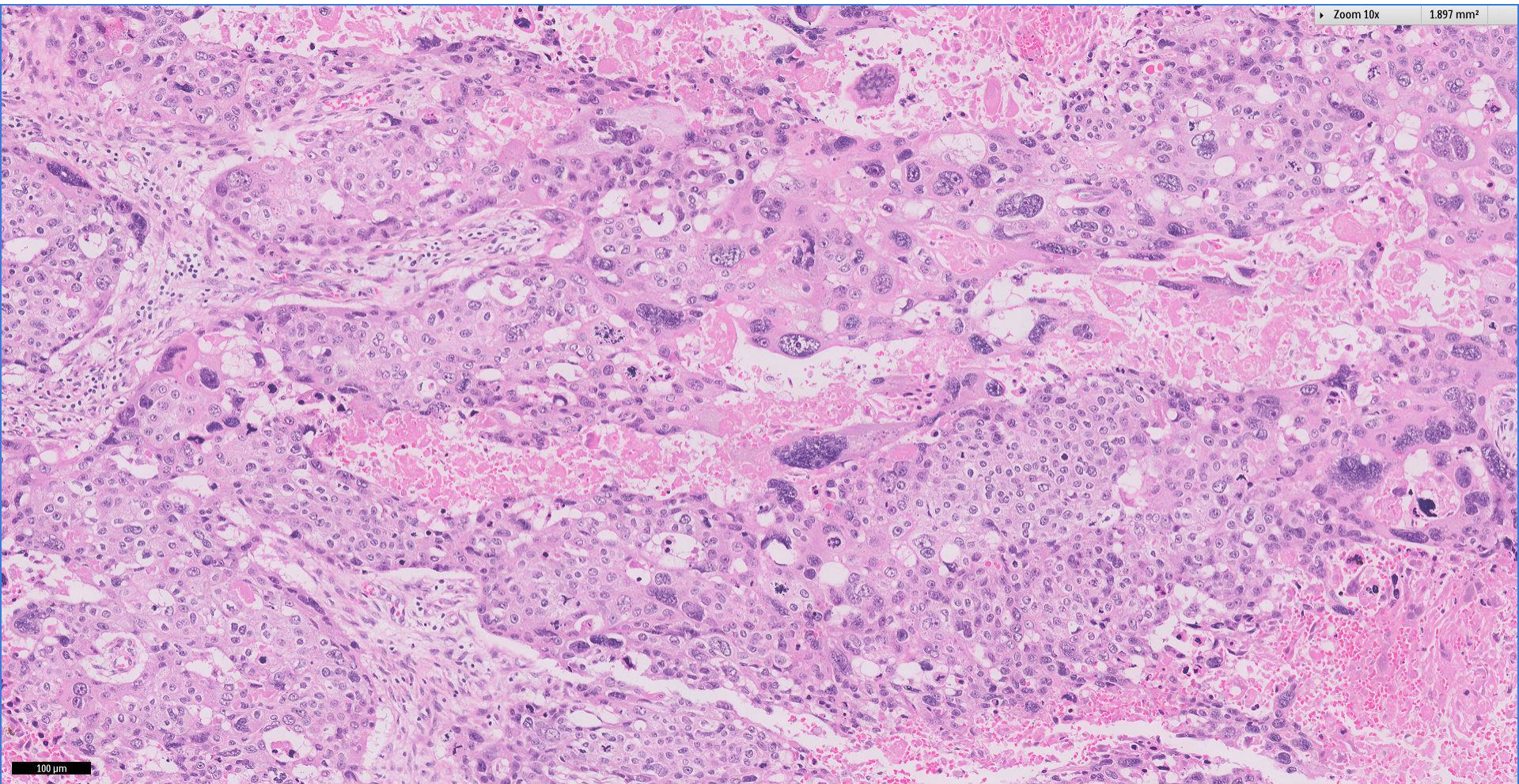


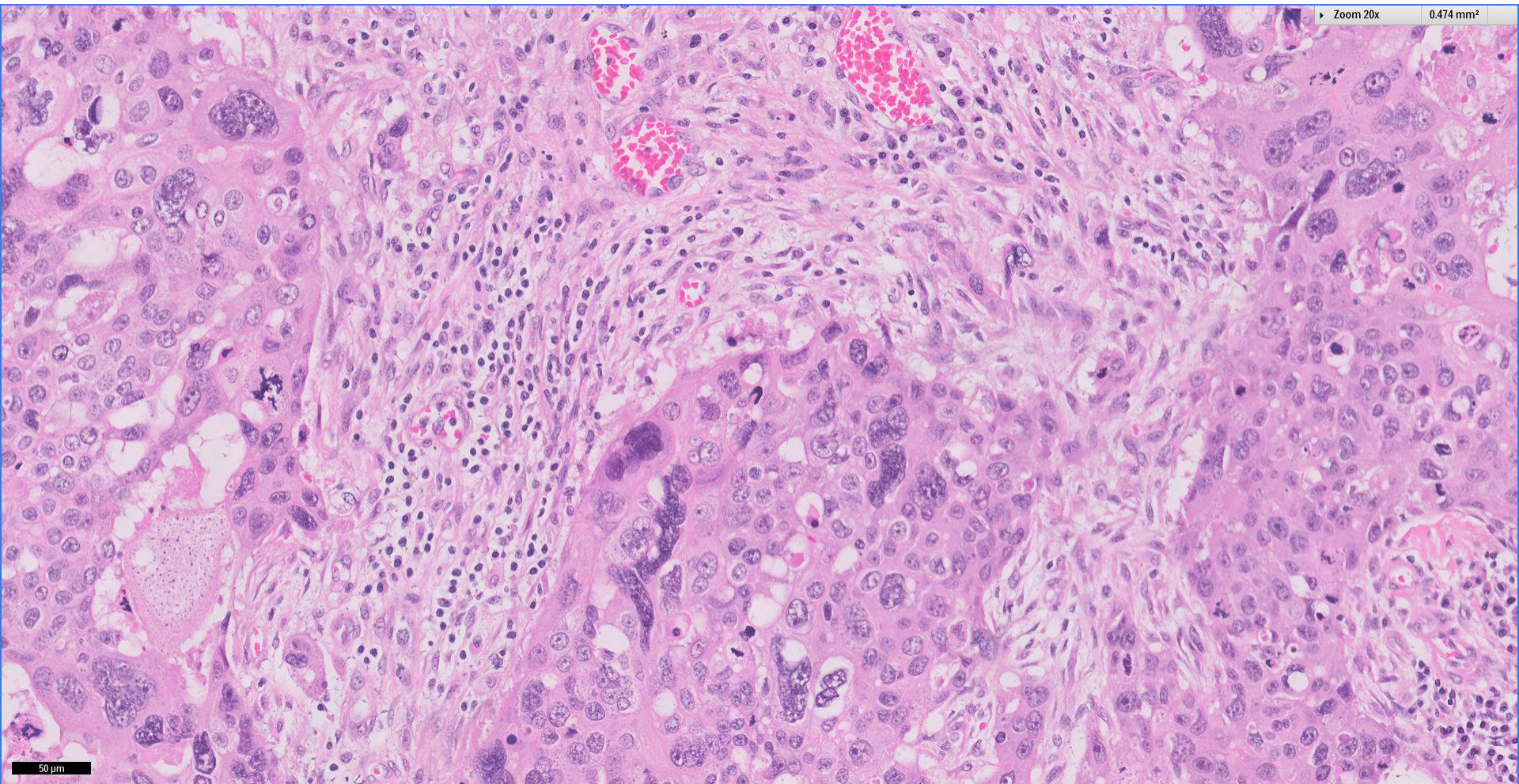




Zoom 5x 7.588 mm²

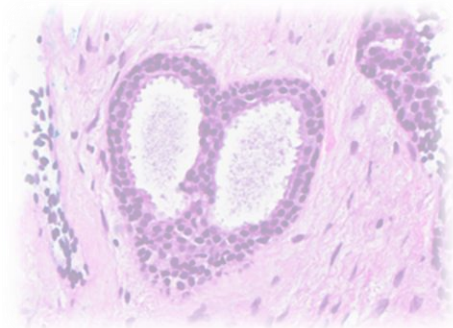
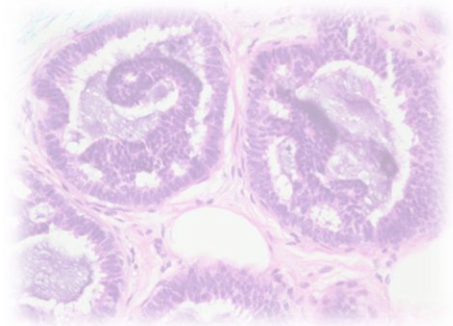
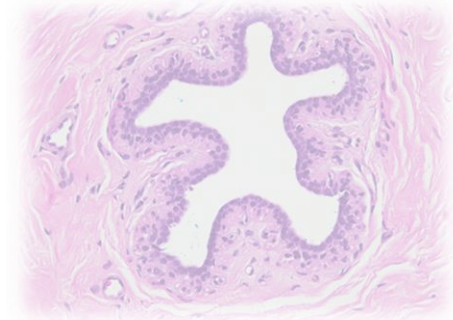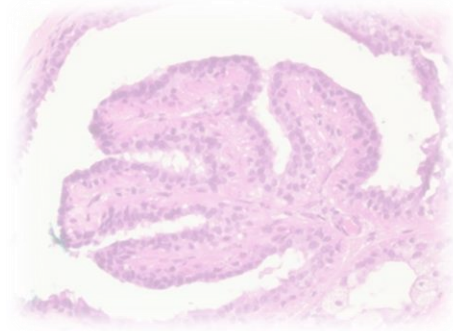






Division of Pathology
Singapore General Hospital

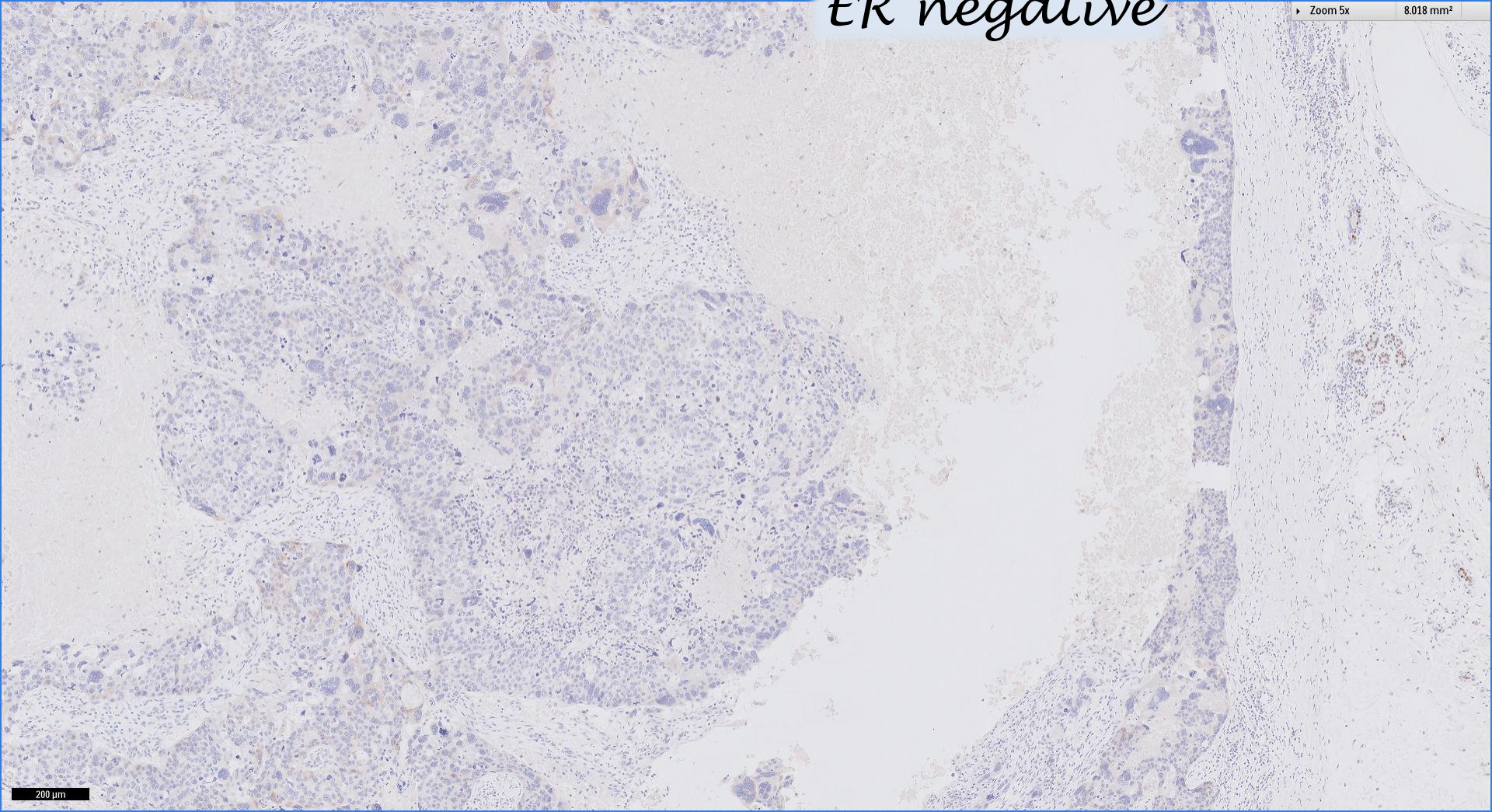




Additional pictures

ER negative

Zoom 5x 8.018 mm²



200 µm



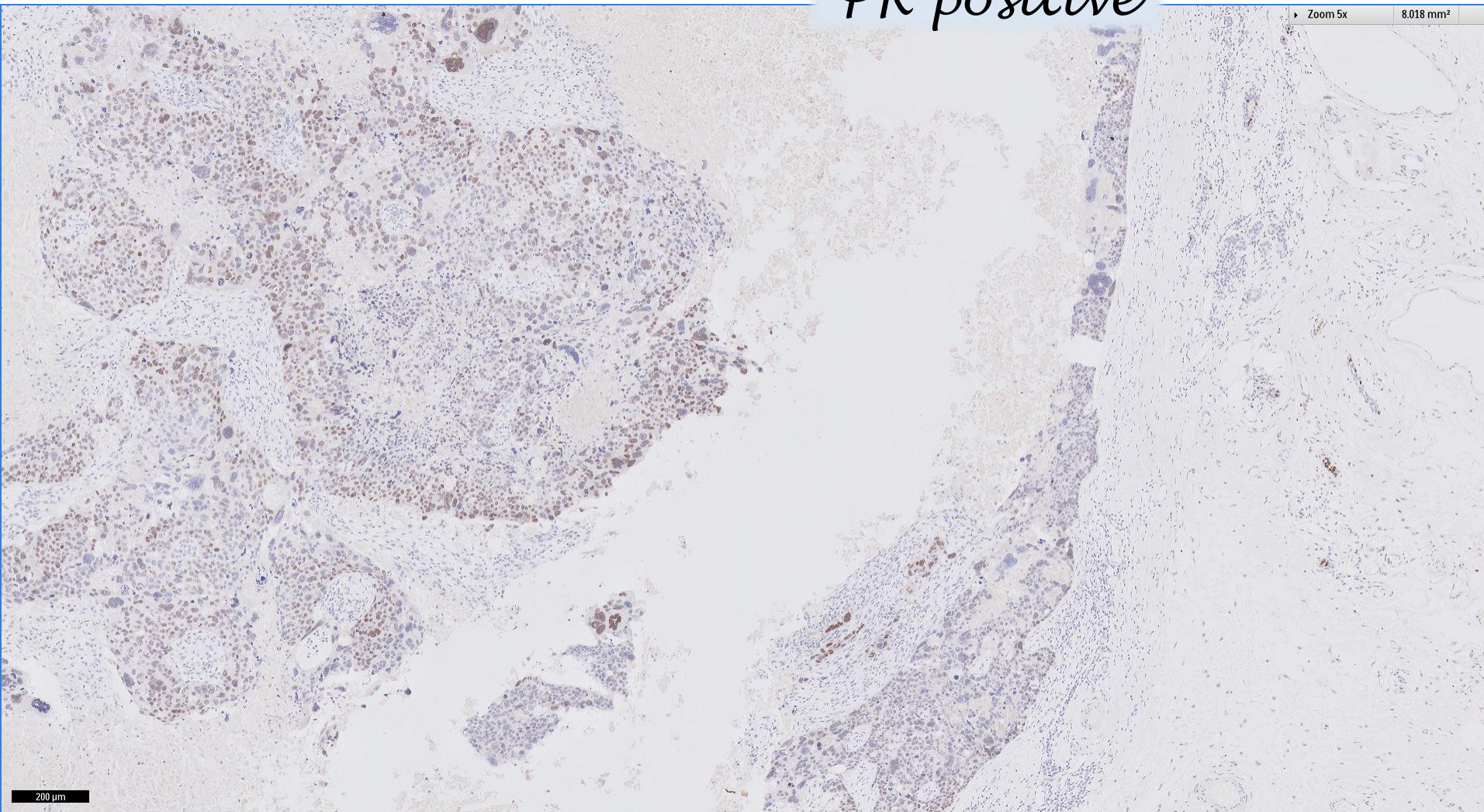
Division of Pathology
Singapore General Hospital



PR positive

Zoom 5x

8.018 mm²

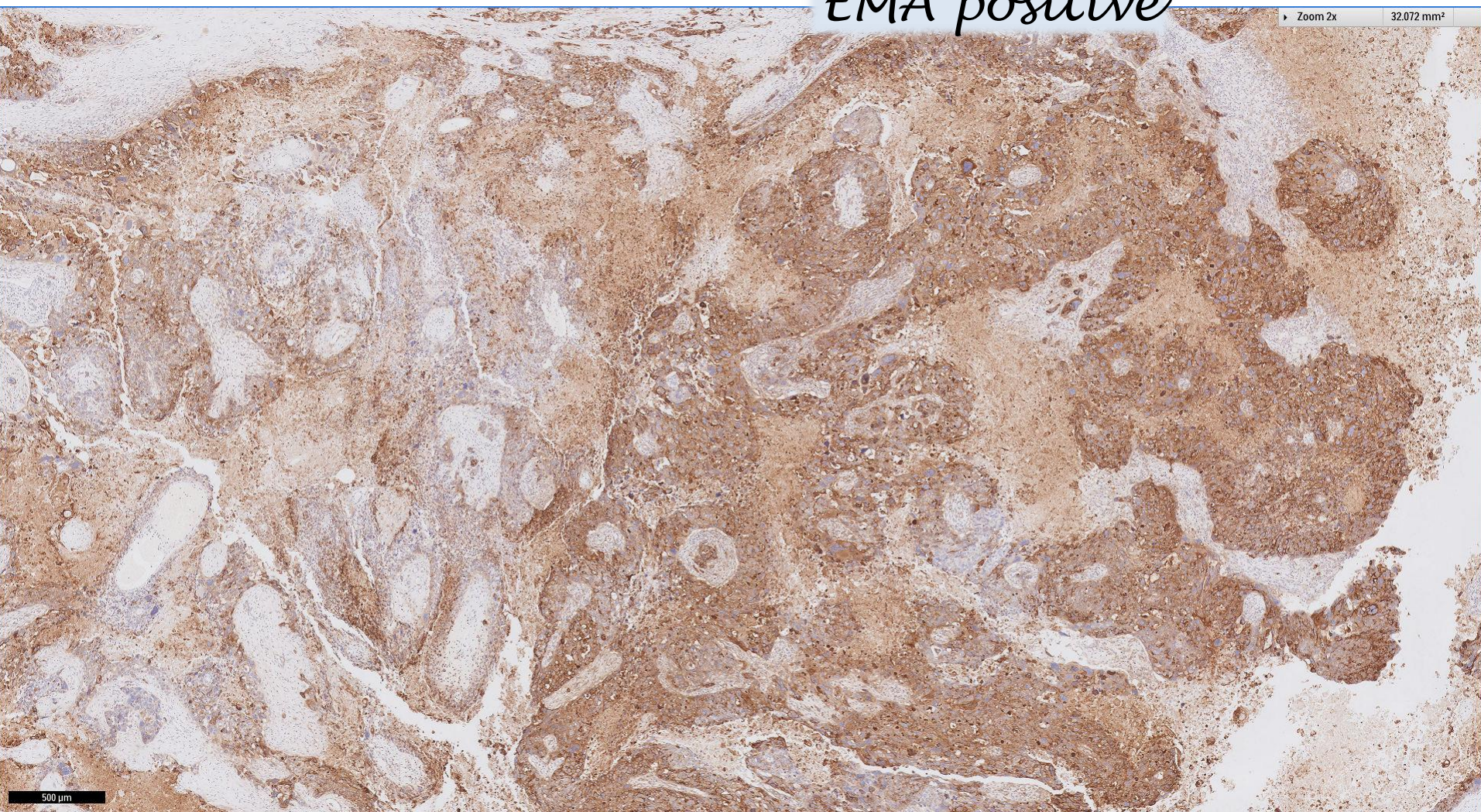


Division of Pathology
Singapore General Hospital



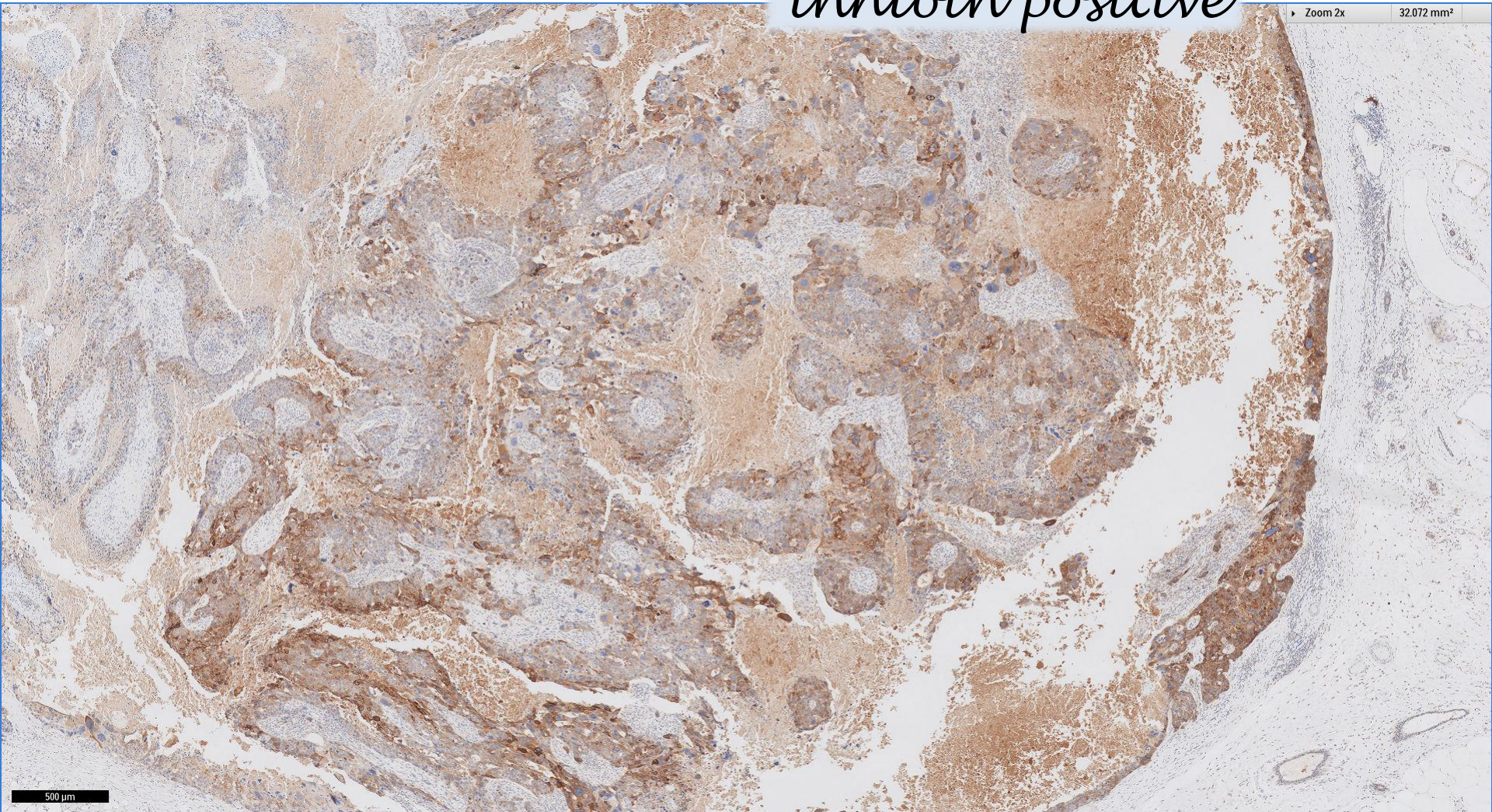
EMA positive

Zoom 2x 32.072 mm²



inhibin positive

Zoom 2x 32.072 mm²



500 µm



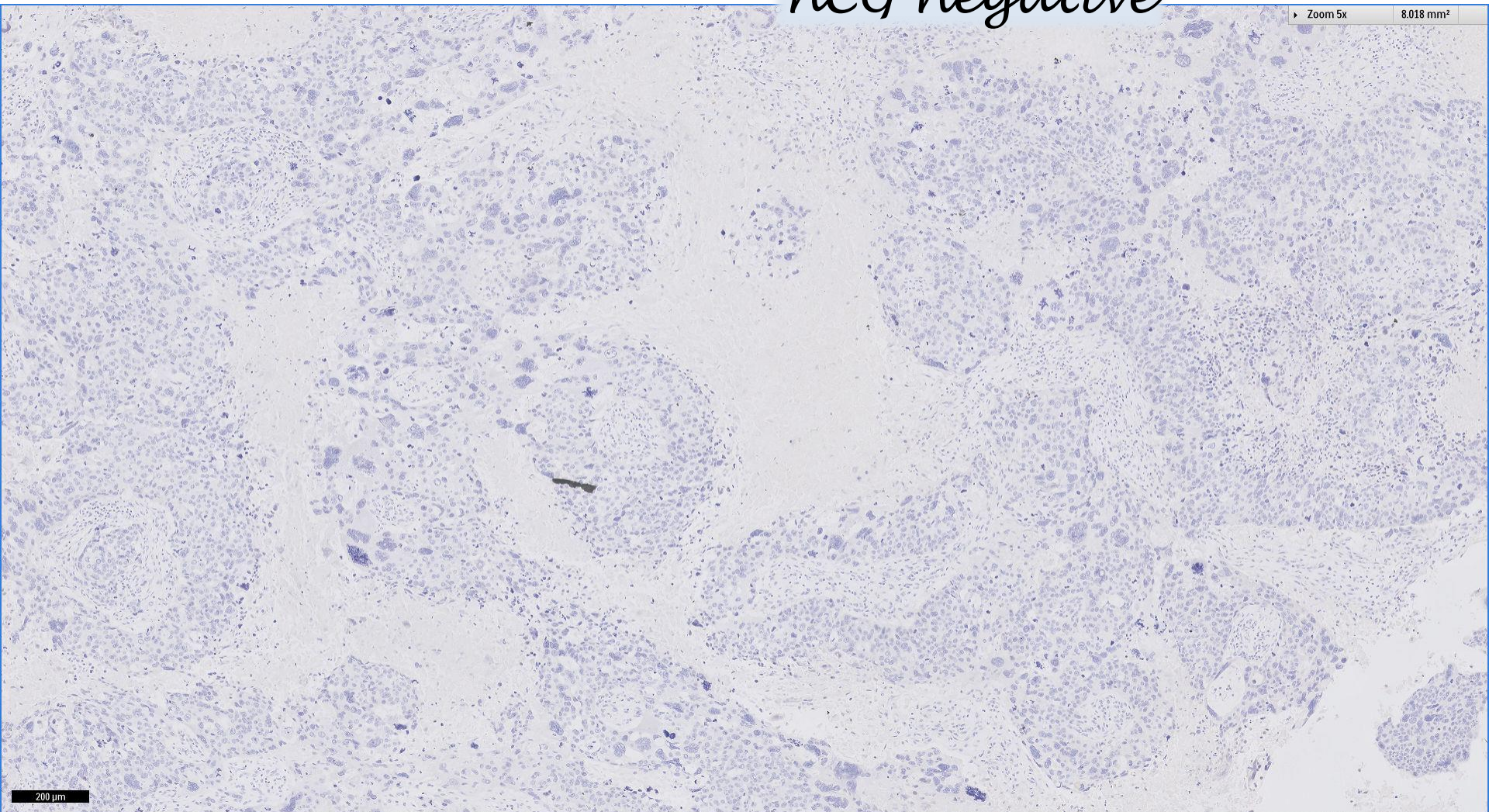
Division of Pathology
Singapore General Hospital



hCG negative

Zoom 5x

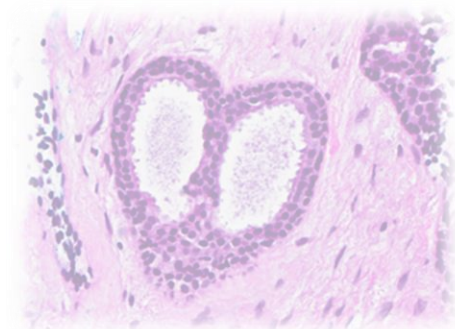
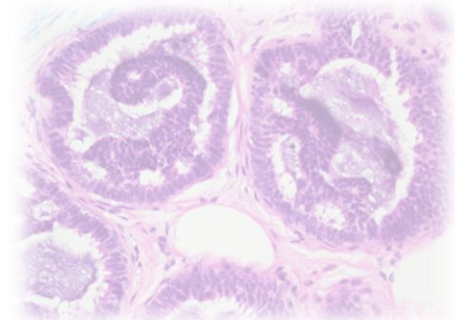
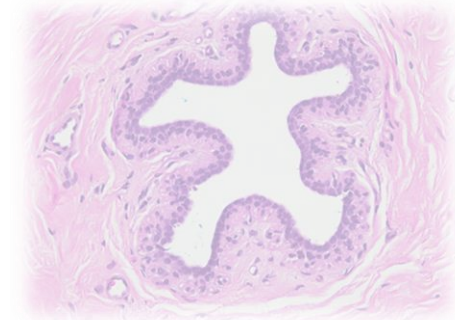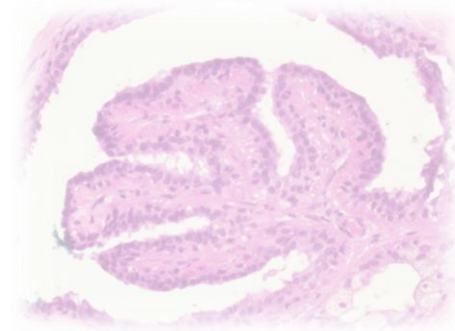
8.018 mm²



200 μ m

Diagnosis, case 6

- Left breast, mastectomy:
Invasive ductal carcinoma with bizarre tumour giant cells, grade 3, 16mm.
ER-, PR+, cerbB2 equivocal.
cerbB2 FISH not amplified.



Invasive breast carcinoma NST with pleomorphic pattern

- Pleomorphic carcinoma is a rare pattern of high-grade IBC-NST.
- Characterized by a proliferation of pleomorphic and bizarre (sometimes multinucleated) tumour giant cells constituting > 50% of the tumour cells in a background of adenocarcinoma or adenocarcinoma with metaplastic spindle and squamous differentiation.

WHO 2019

Invasive breast carcinoma NST with pleomorphic pattern

WHO 2019

- These tumours could represent an extreme end of dedifferentiation of IBC-NST or part of the differentiation of metaplastic spindle cell carcinoma.
- Hormone receptor expression is usually negative.
- A proportion of cases overexpress HER2.
- Axillary lymph node metastases are present in 50% of cases, with involvement of ≥ 3 lymph nodes in most of these.
- Many patients present with advanced disease.
- One study reported that the presence of a spindle cell metaplastic component in these tumours is associated with poor outcome.

Invasive breast carcinoma NST with pleomorphic pattern

WHO 2019

- Differential diagnosis ~ **IBC-NST with choriocarcinomatous pattern**
 - Patients with IBC-NST may have elevated levels of serum hCG.
 - As many as 60% of IBC-NST have been found to contain hCG-positive cells.
 - Histological evidence of choriocarcinomatous differentiation is exceptionally rare, with only a few cases reported.
 - All were in women aged 50–70 years.

Thank You