
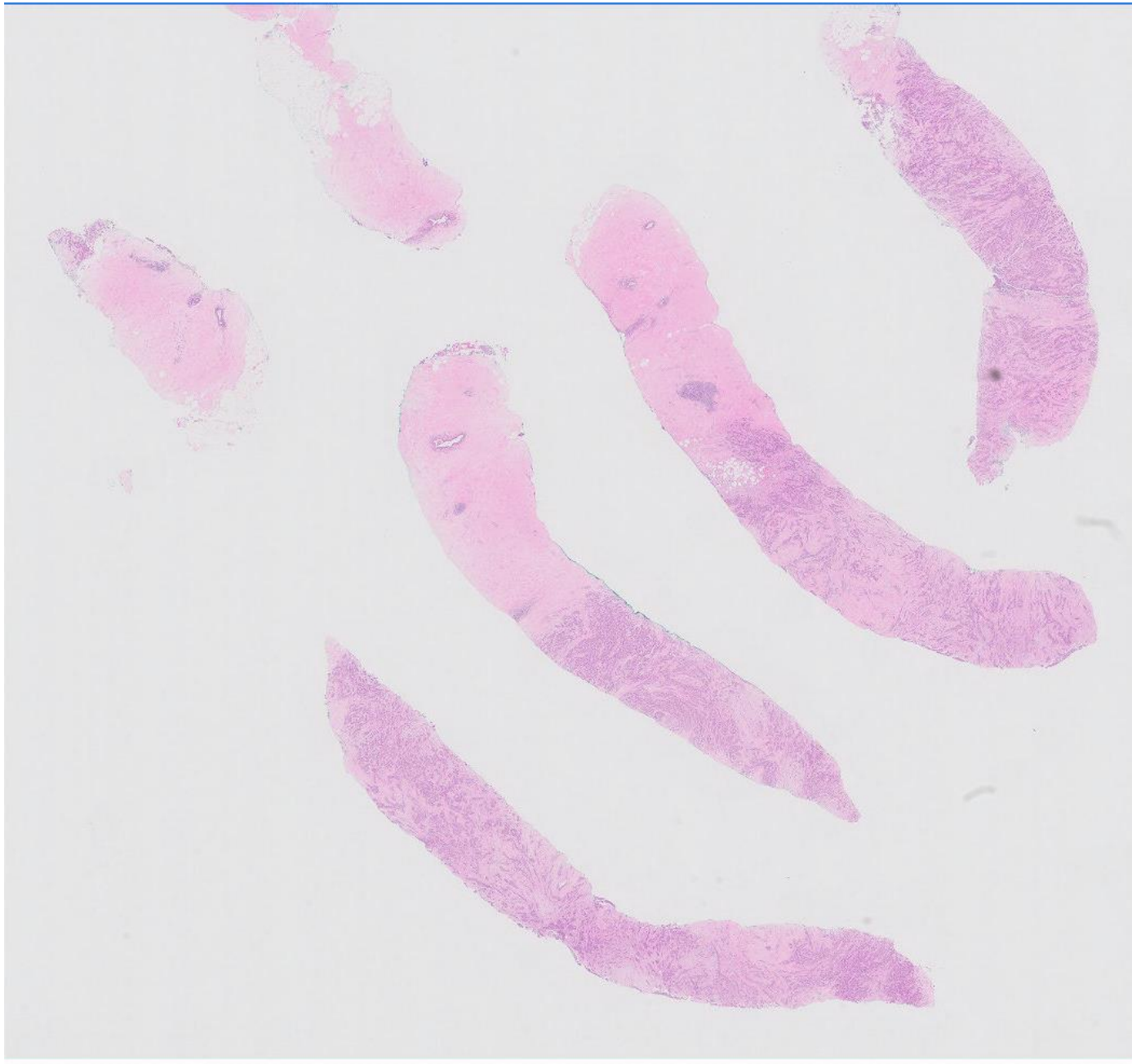


Case 35

60 year old female.

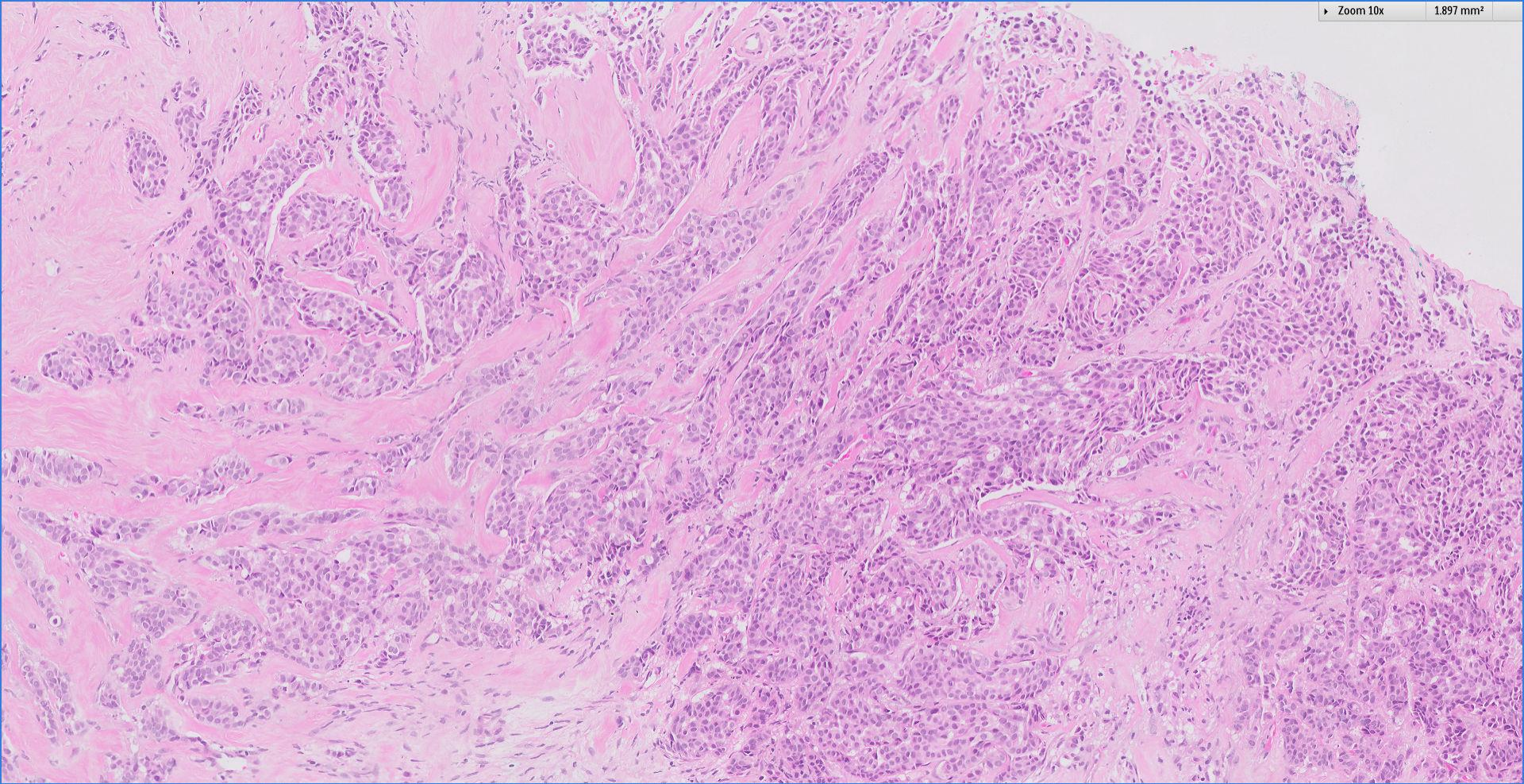
Trucut biopsy, right breast nodule.





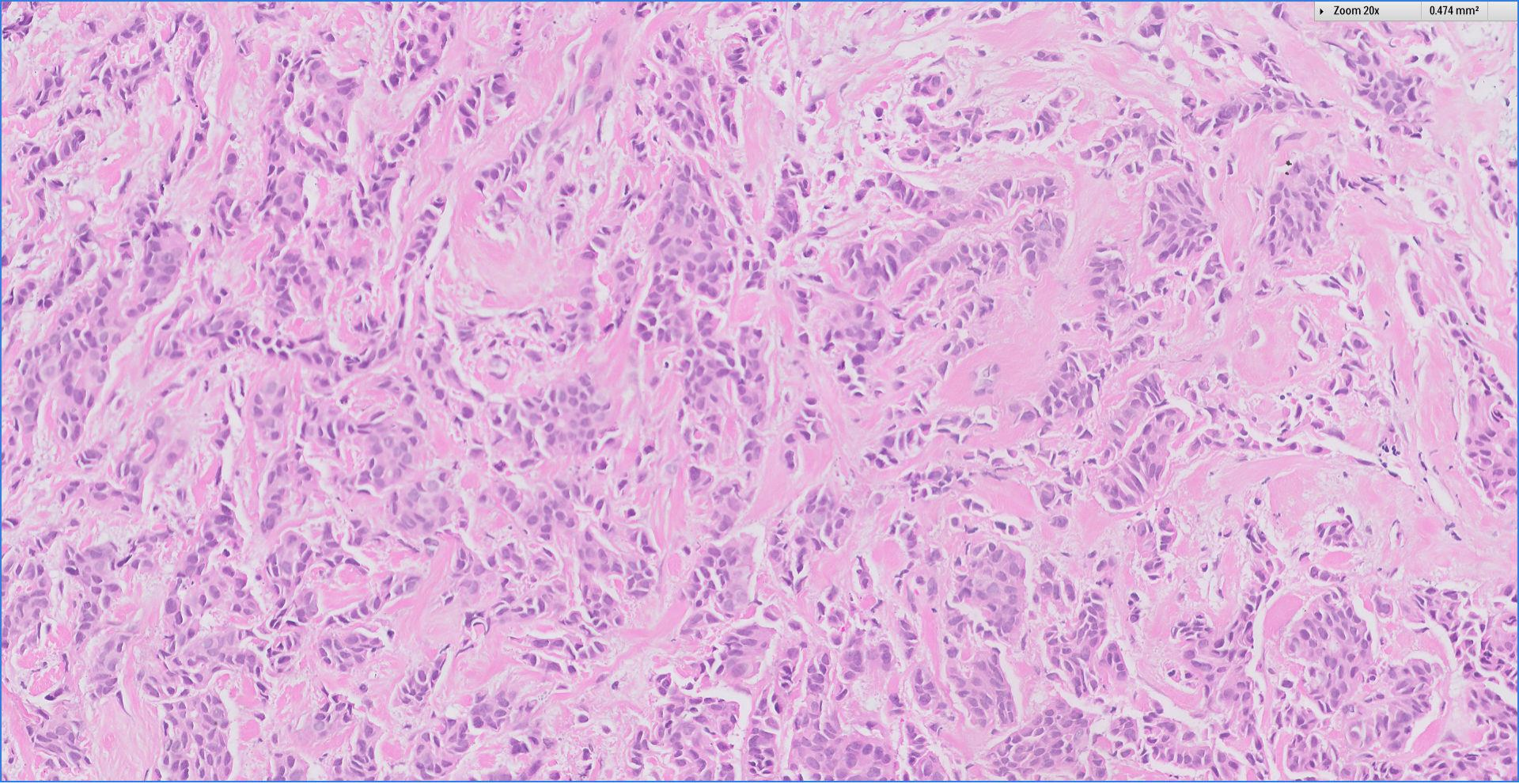
Zoom 10x

1.897 mm²



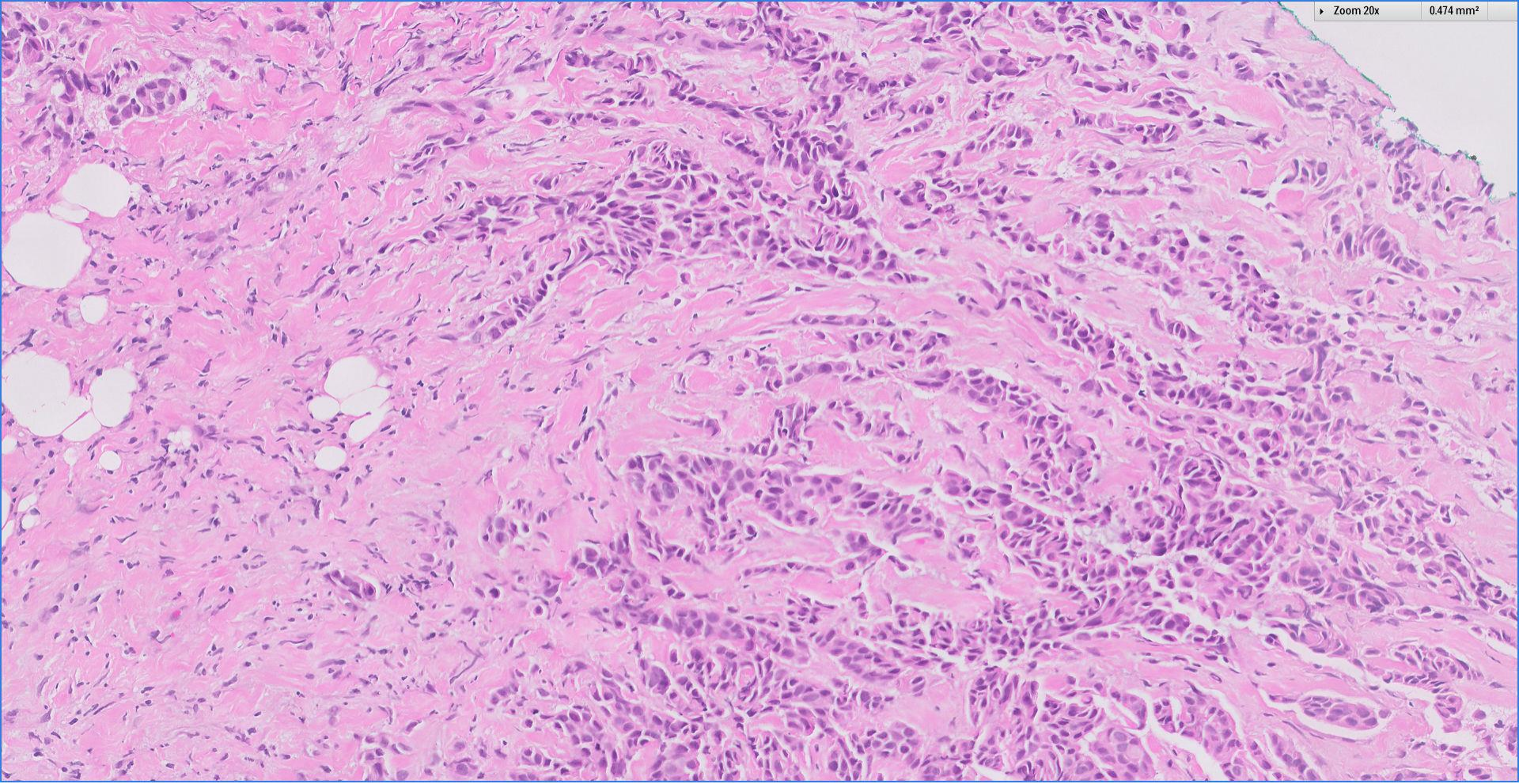
Zoom 20x

0.474 mm²



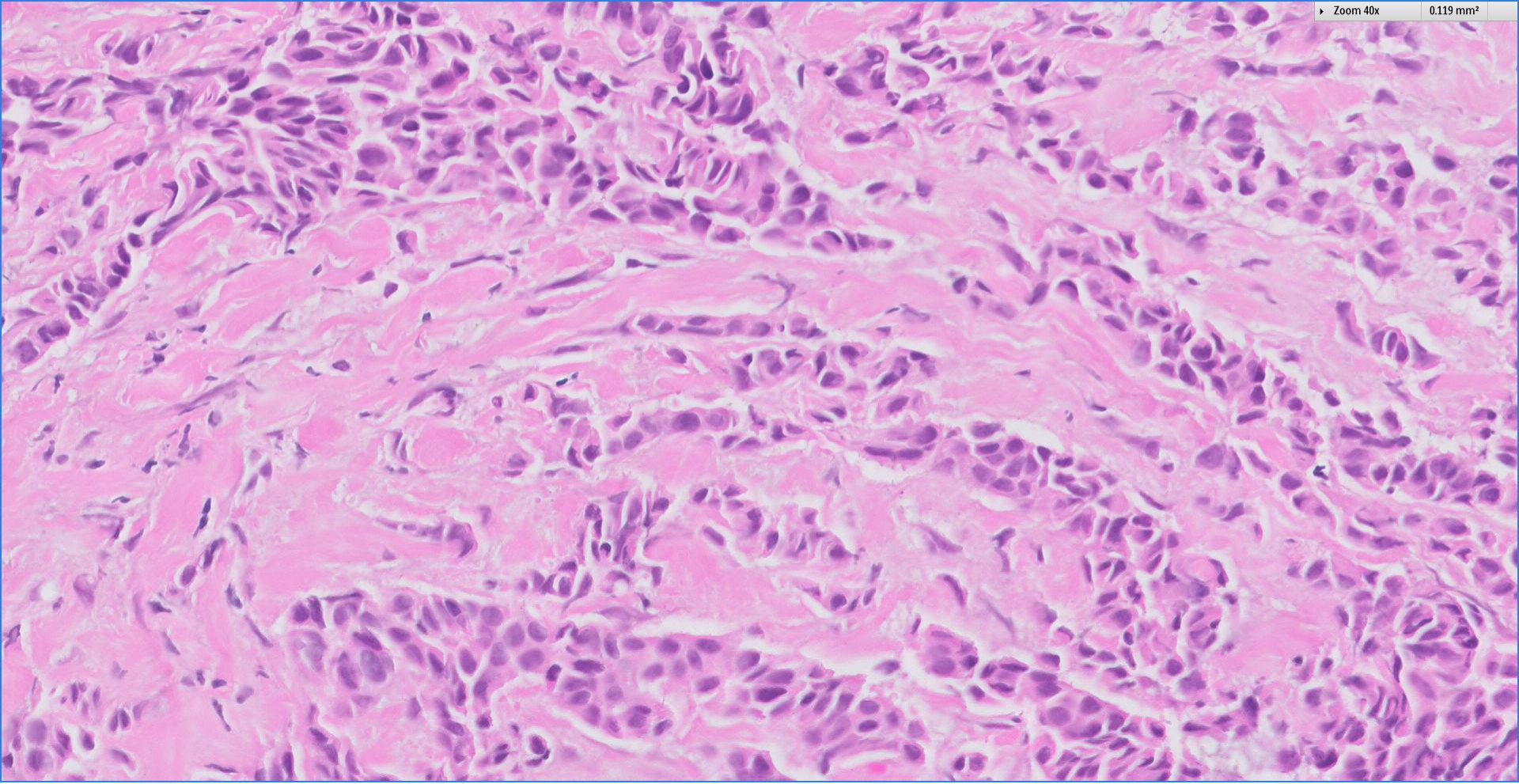
Zoom 20x

0.474 mm²




Zoom 40x

0.119 mm²



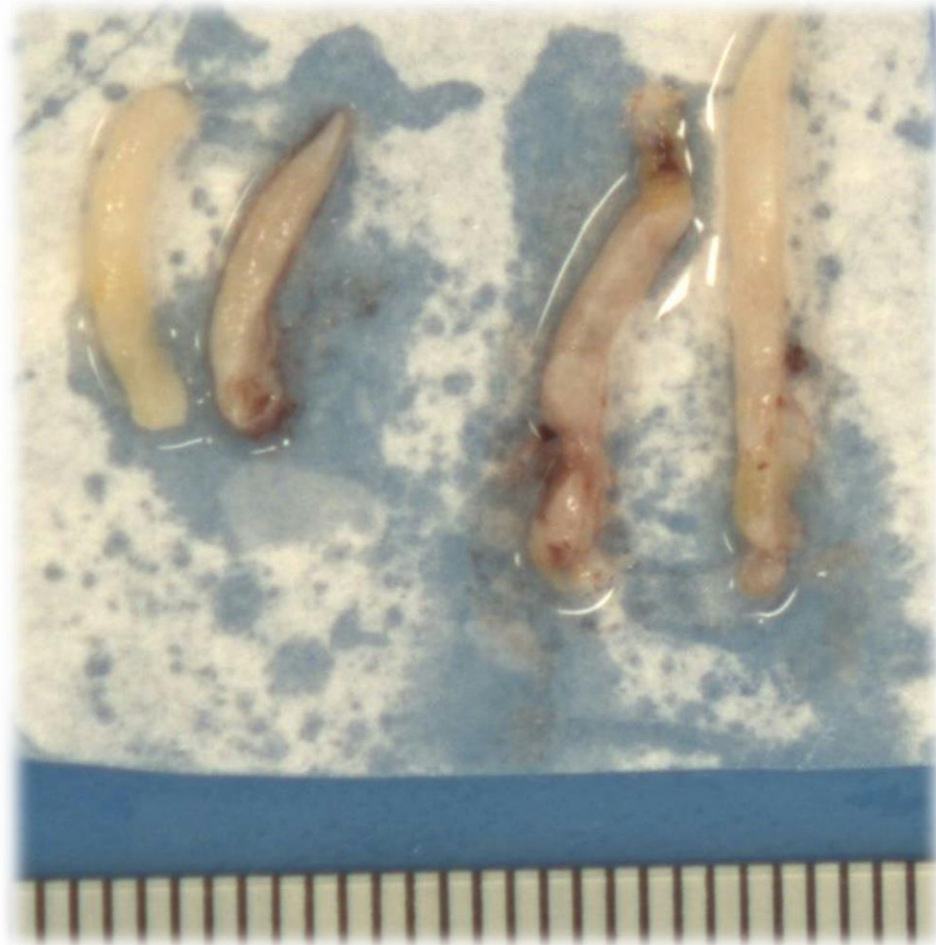
 Breast
Pathology
Course 2018



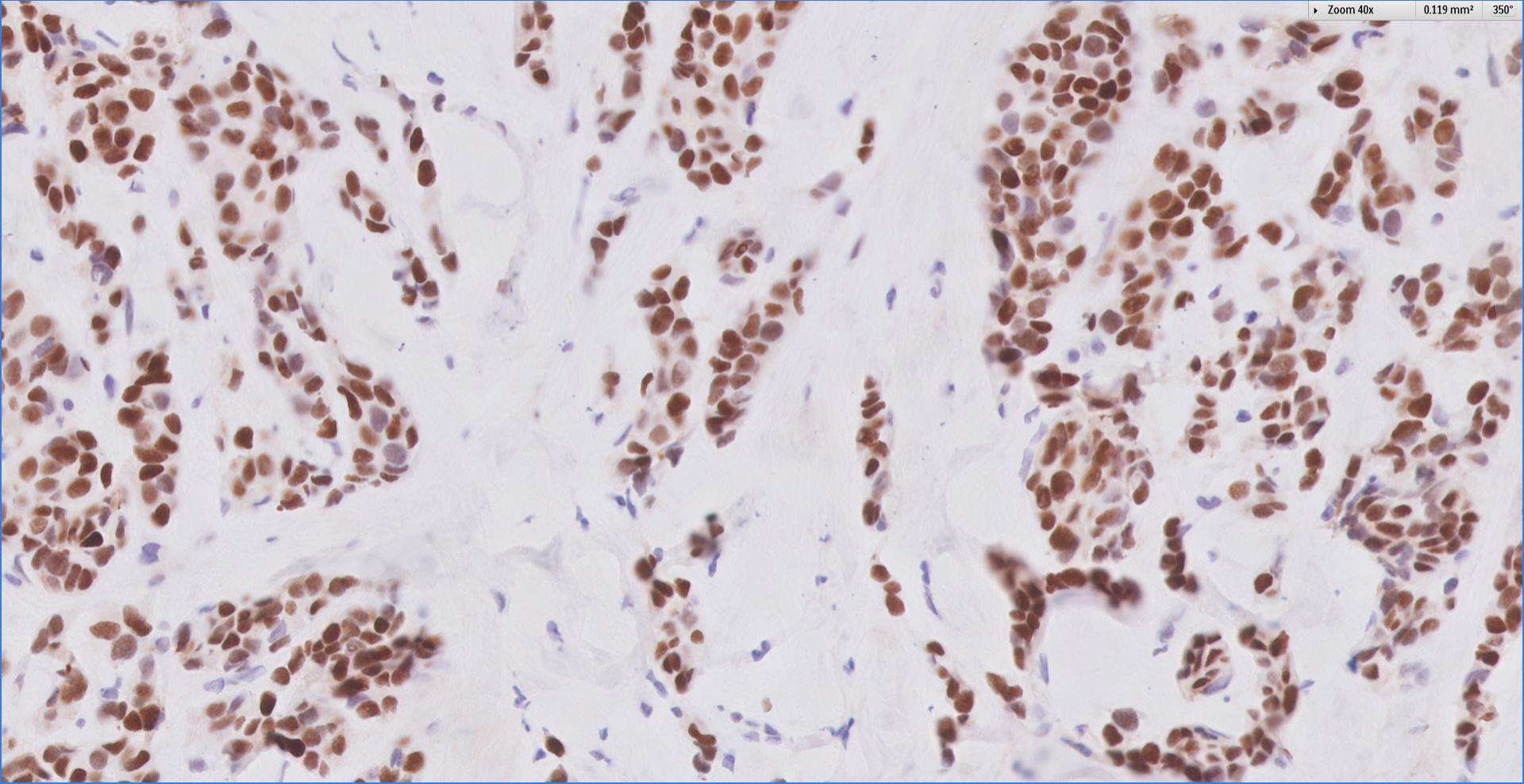
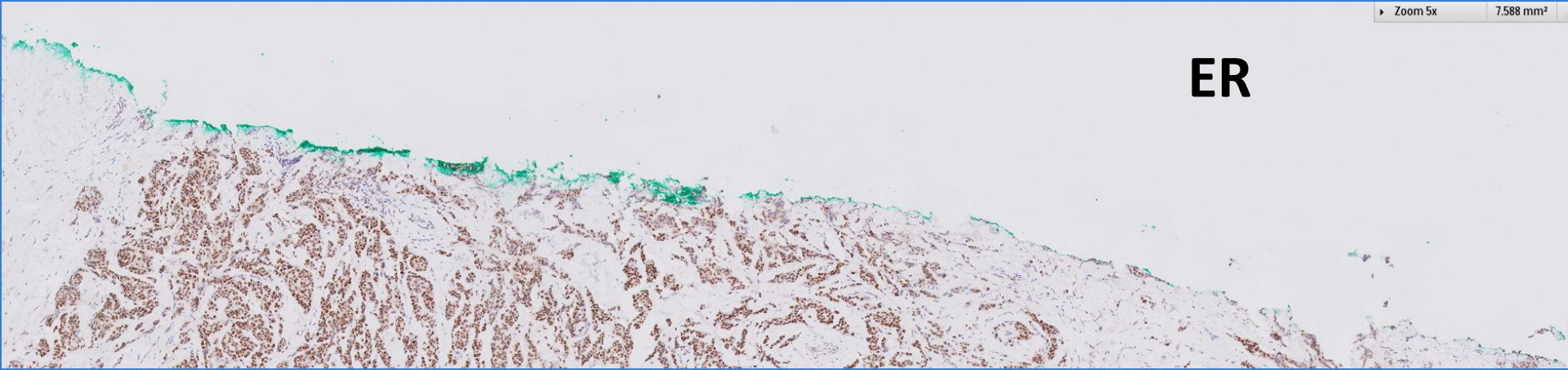
Singapore
General Hospital
SingHealth
Division of Pathology



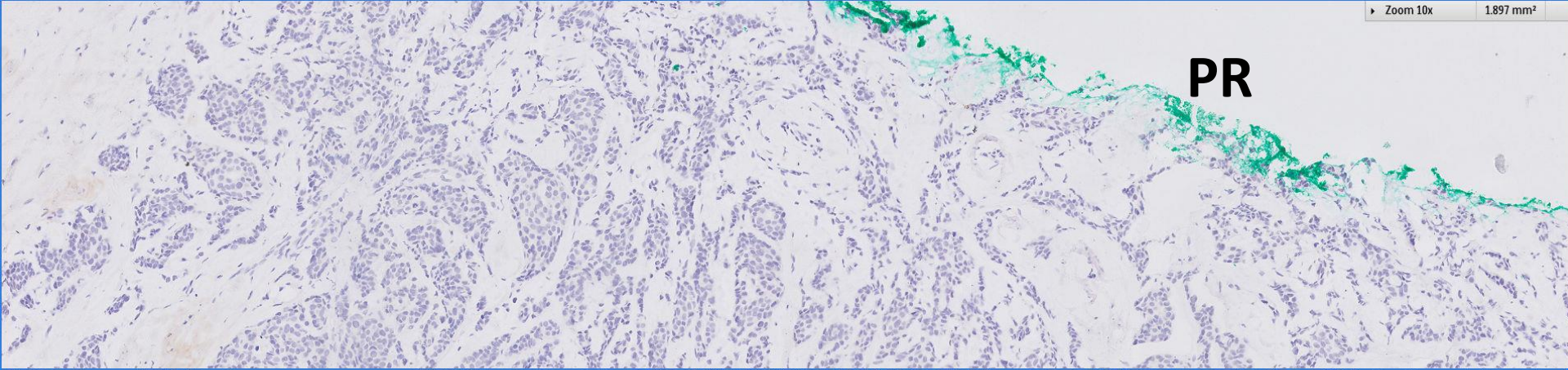
Core biopsies



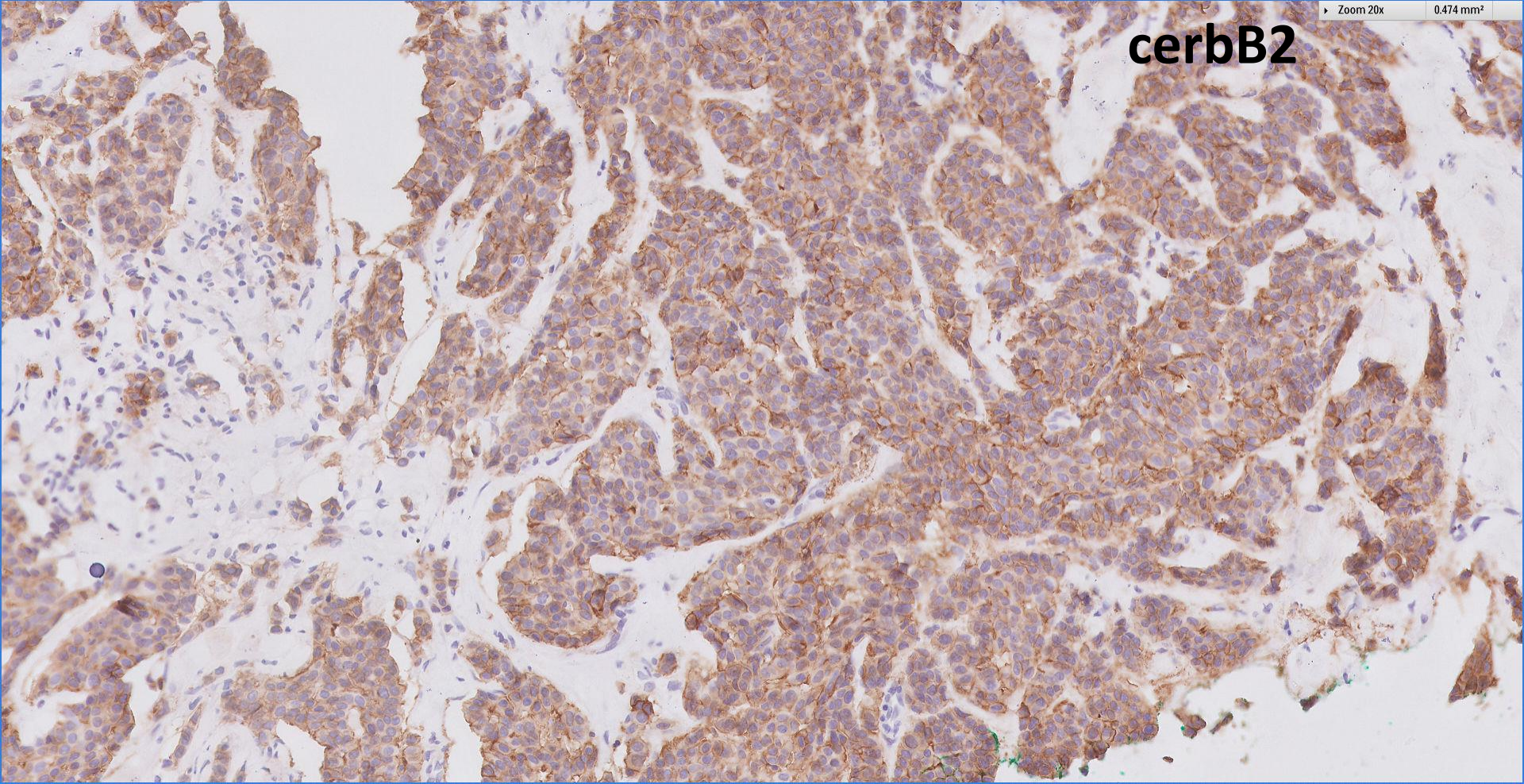
ER



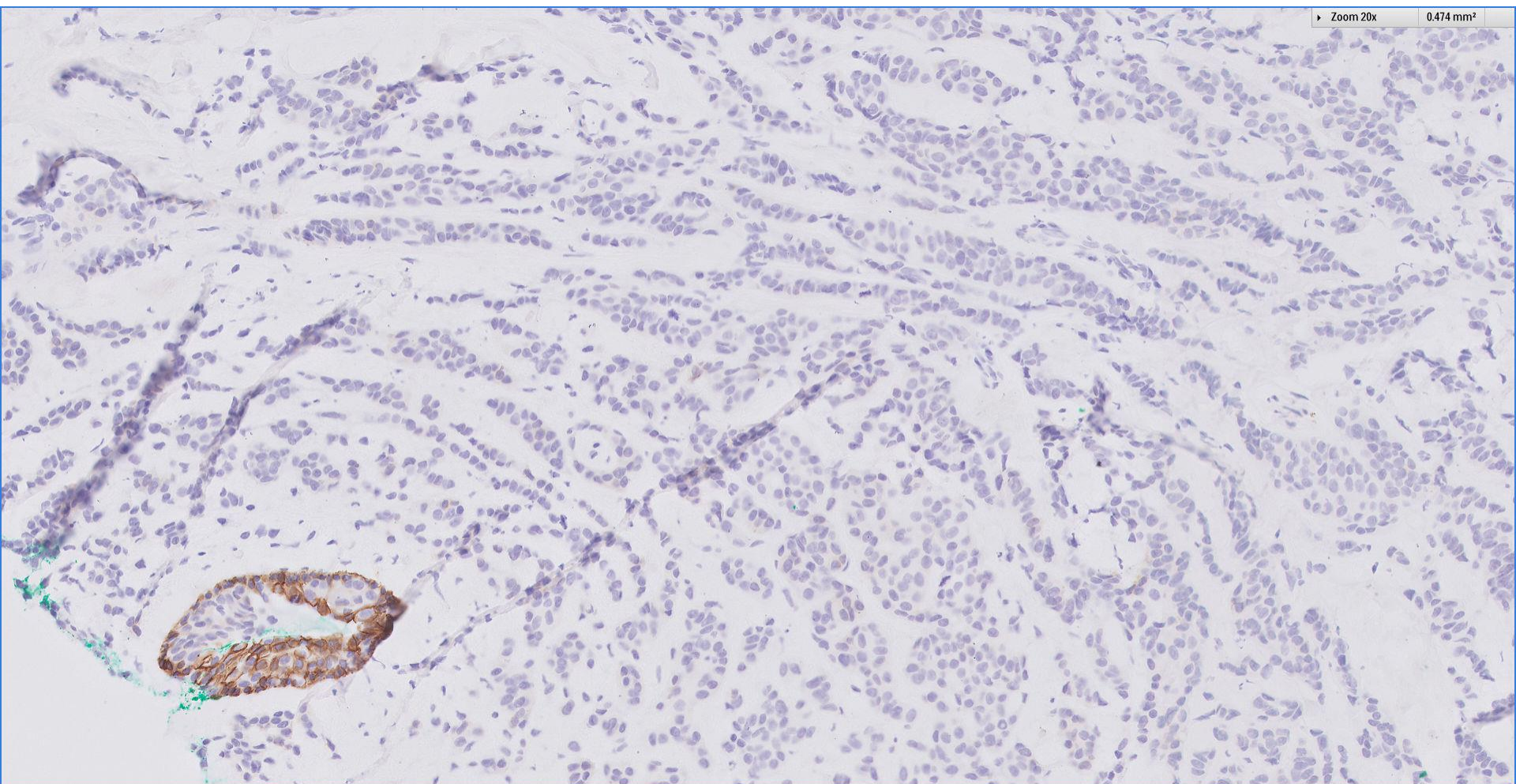
PR



cerbB2

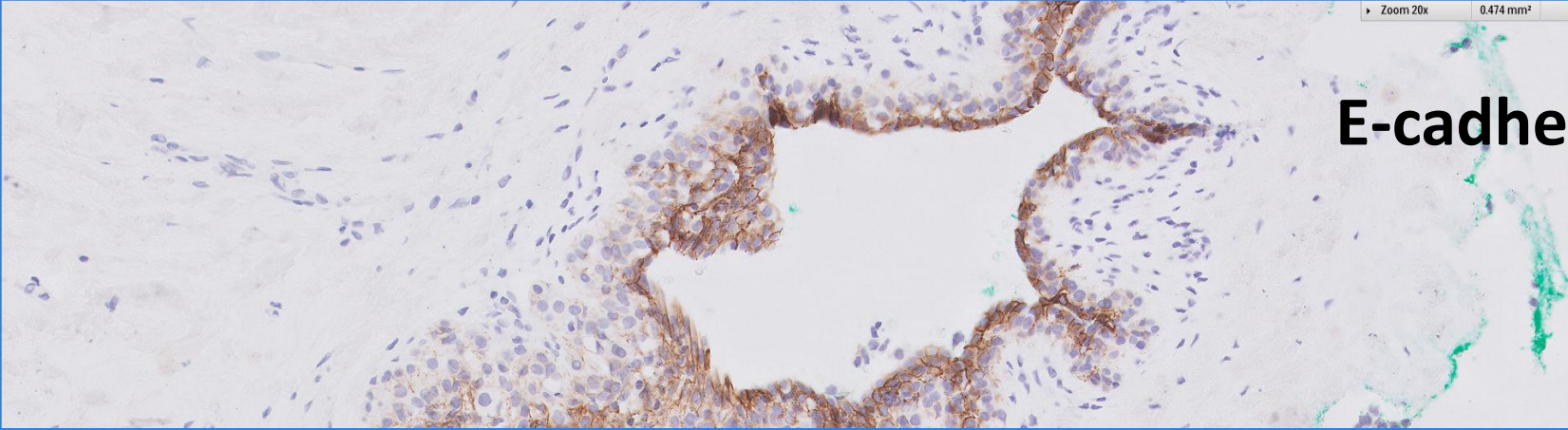


E-cadherin

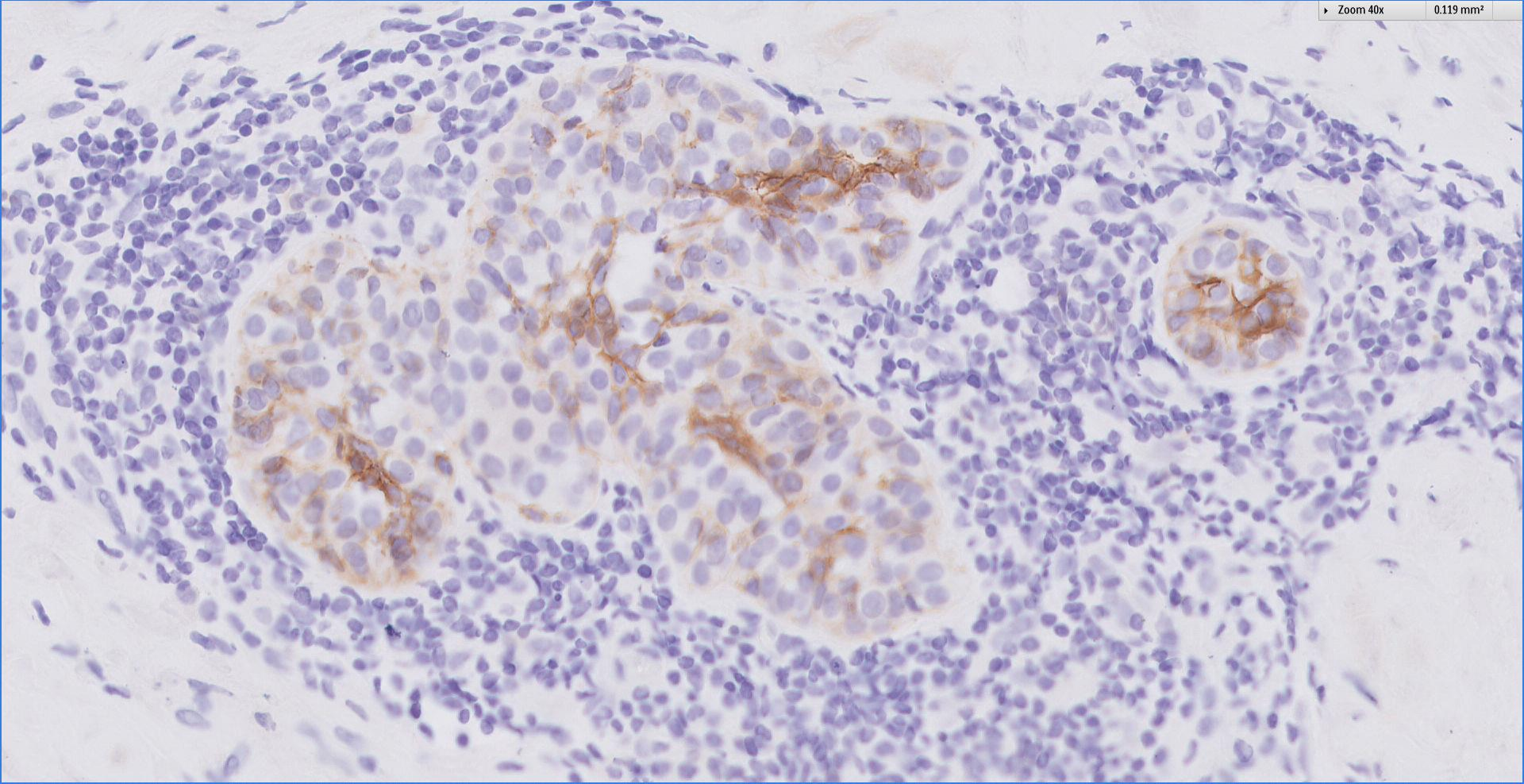


Zoom 20x 0.474 mm²

E-cadherin



Zoom 40x 0.119 mm²




Diagnosis

Trucut biopsy, right breast nodule ~


Invasive carcinoma with predominantly lobular features,
provisional grade 2.

ER positive, PR negative, cerbB2 borderline (2+).




Invasive lobular carcinoma

- Classical
- Variants ~
 - Alveolar
 - Solid
 - Pleomorphic
 - Tubulolobular
 - Mixed lobular
 - ***Trabecular***



Invasive lobular carcinoma ~ trabecular variant

- Trabeculae are one to three cells thick.
- Describes tumours with prominent bands that are more than 2 cells wide.
- Usually found in association with other variants, which will be classified as 'mixed'.



Invasive lobular carcinoma

- Younger age at diagnosis for women with classical ILC as compared with variant forms.
- No other clinical differences.
- Classical ILC ~
 - More frequent ductular extension.
 - Greater likelihood of multicentricity, multifocality and bilaterality.

Rosen's Breast Pathology 2014




Singapore
General Hospital

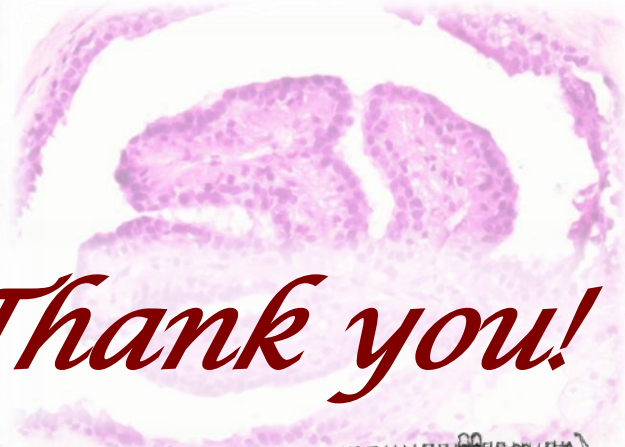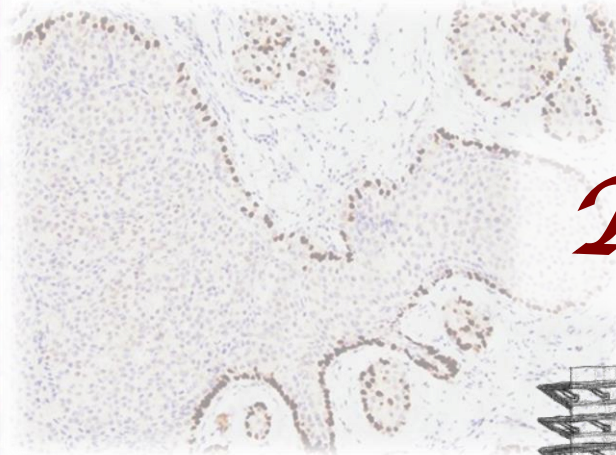
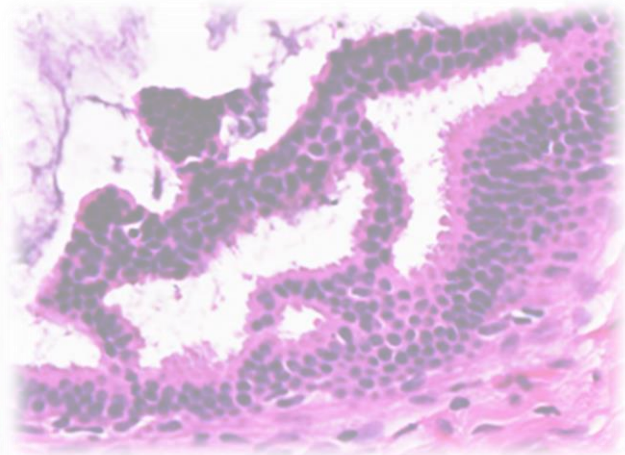
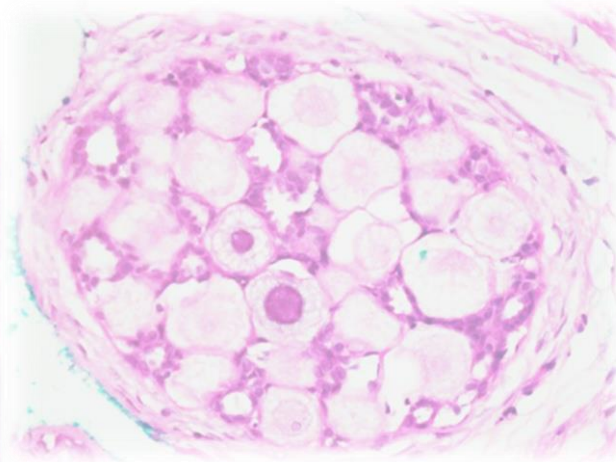
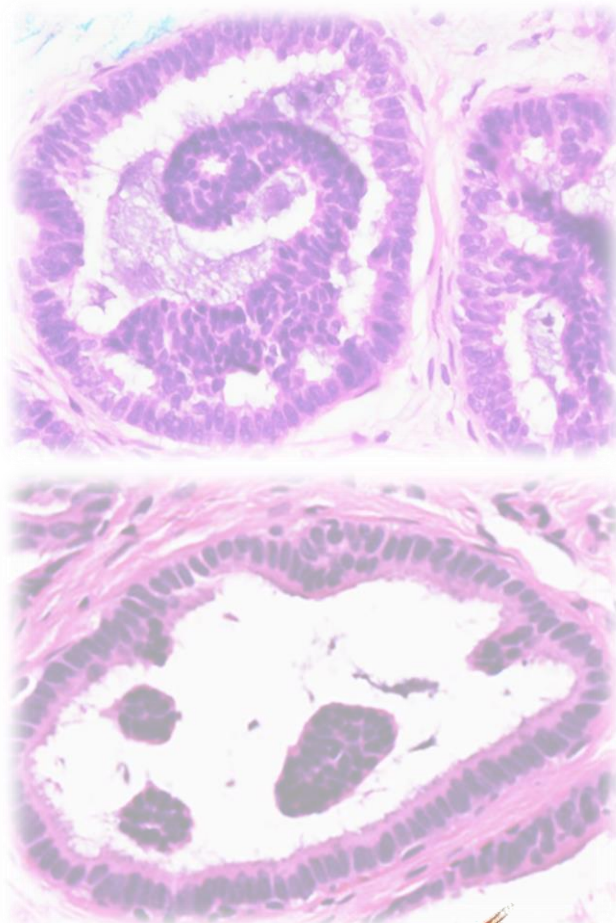
SingHealth
Division of Pathology



*No clinical follow-up
available for this patient.*



 Breast
Pathology
Course 2018



Thank you!

