



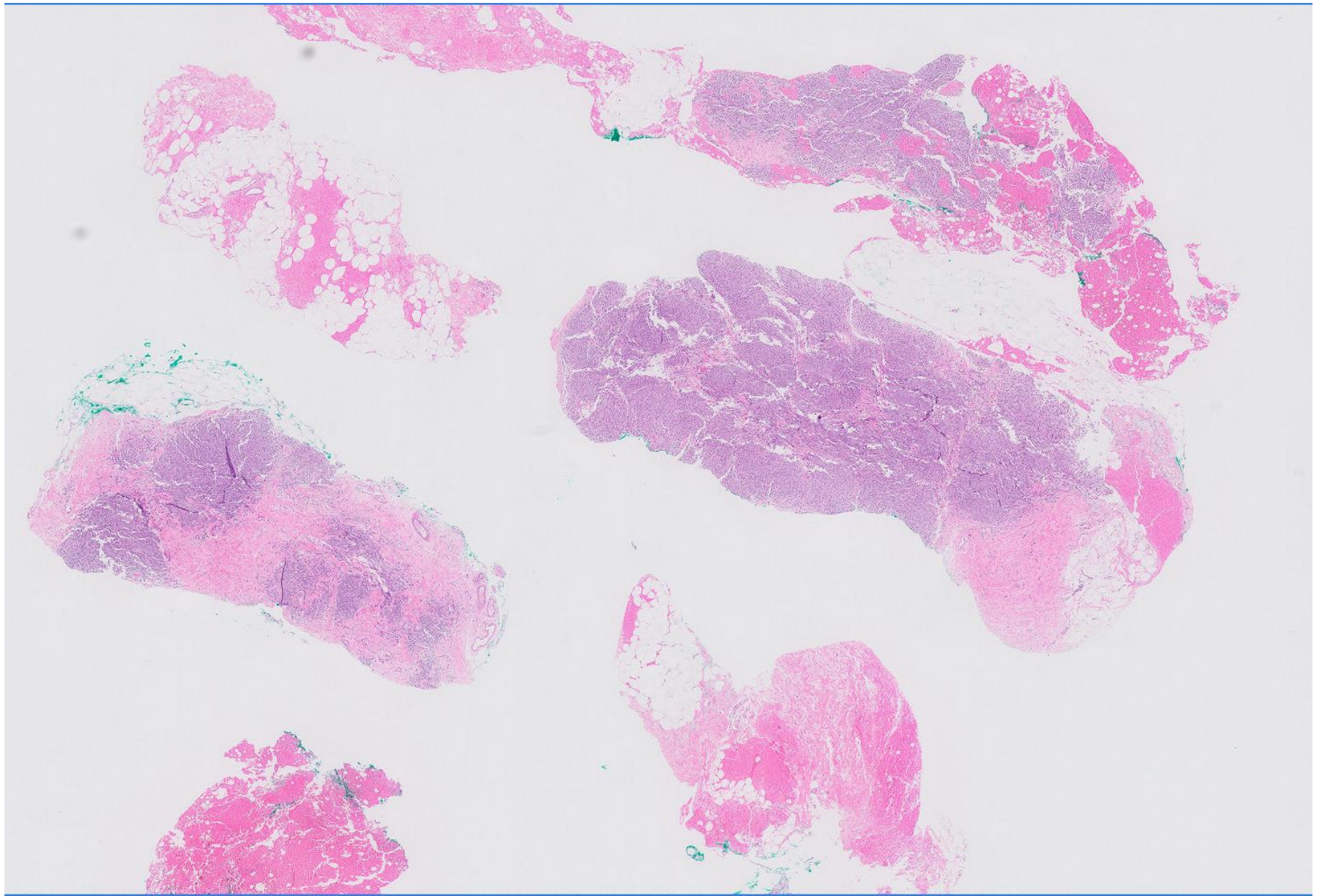
Case 4

93 year old male. Bilateral breast nodules.
Left breast 12 o'clock 17 x 11 x 20mm.
Right breast 2 o'clock 5 x 3 x 9mm.
Ultrasound guided core biopsies of both nodules.



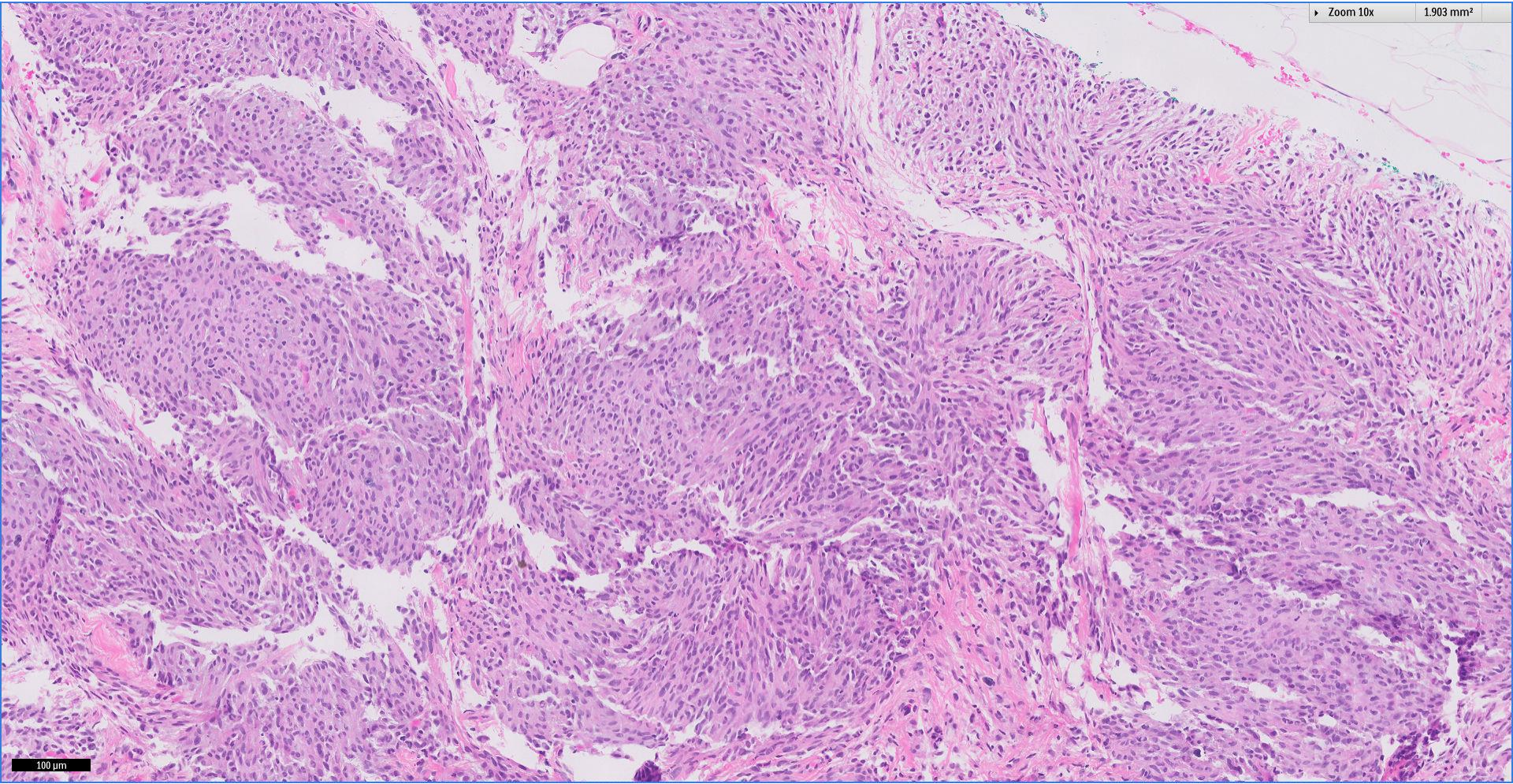
Section from left breast (A).





Zoom 10x

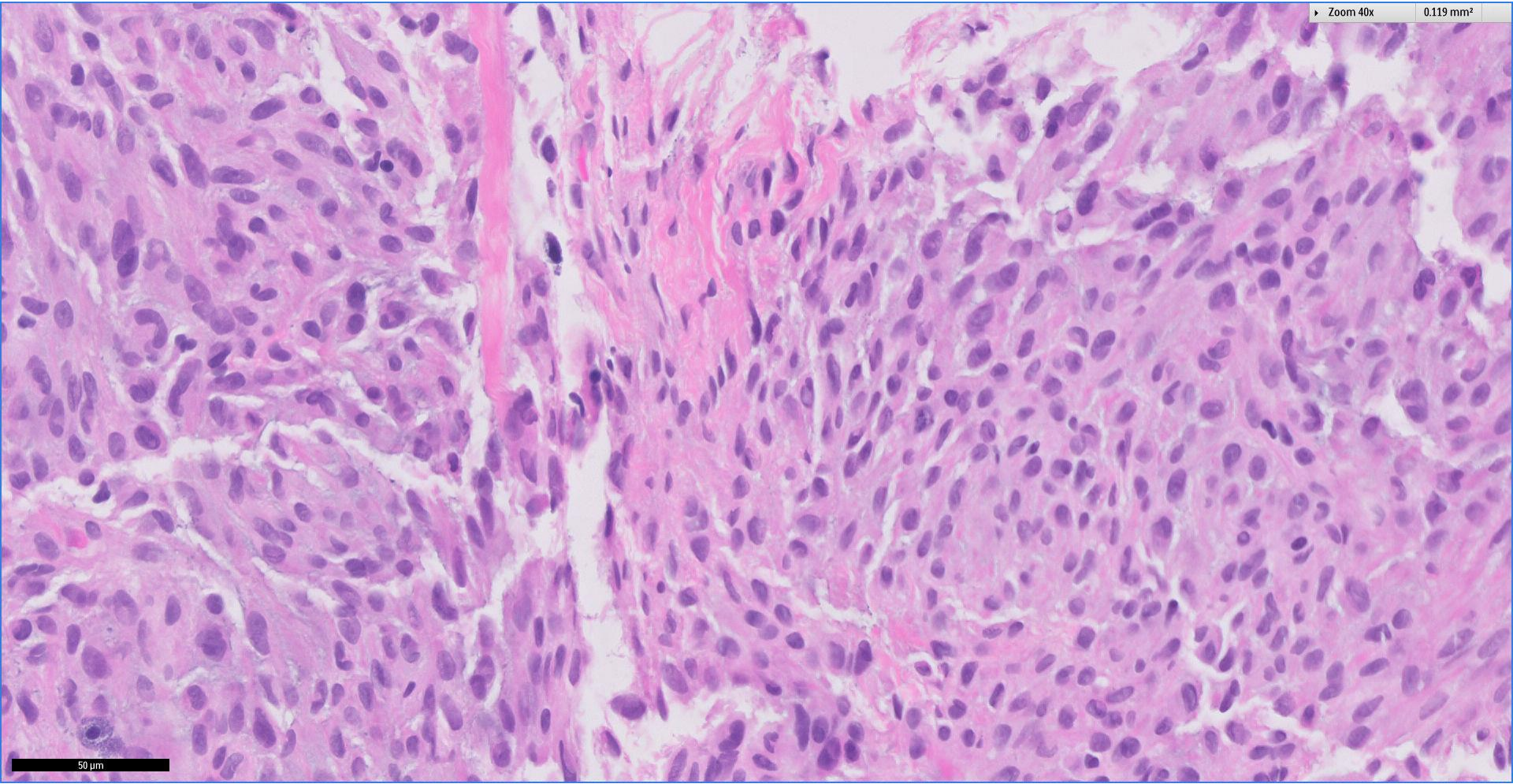
1.903 mm²



100 μ m


Zoom 40x

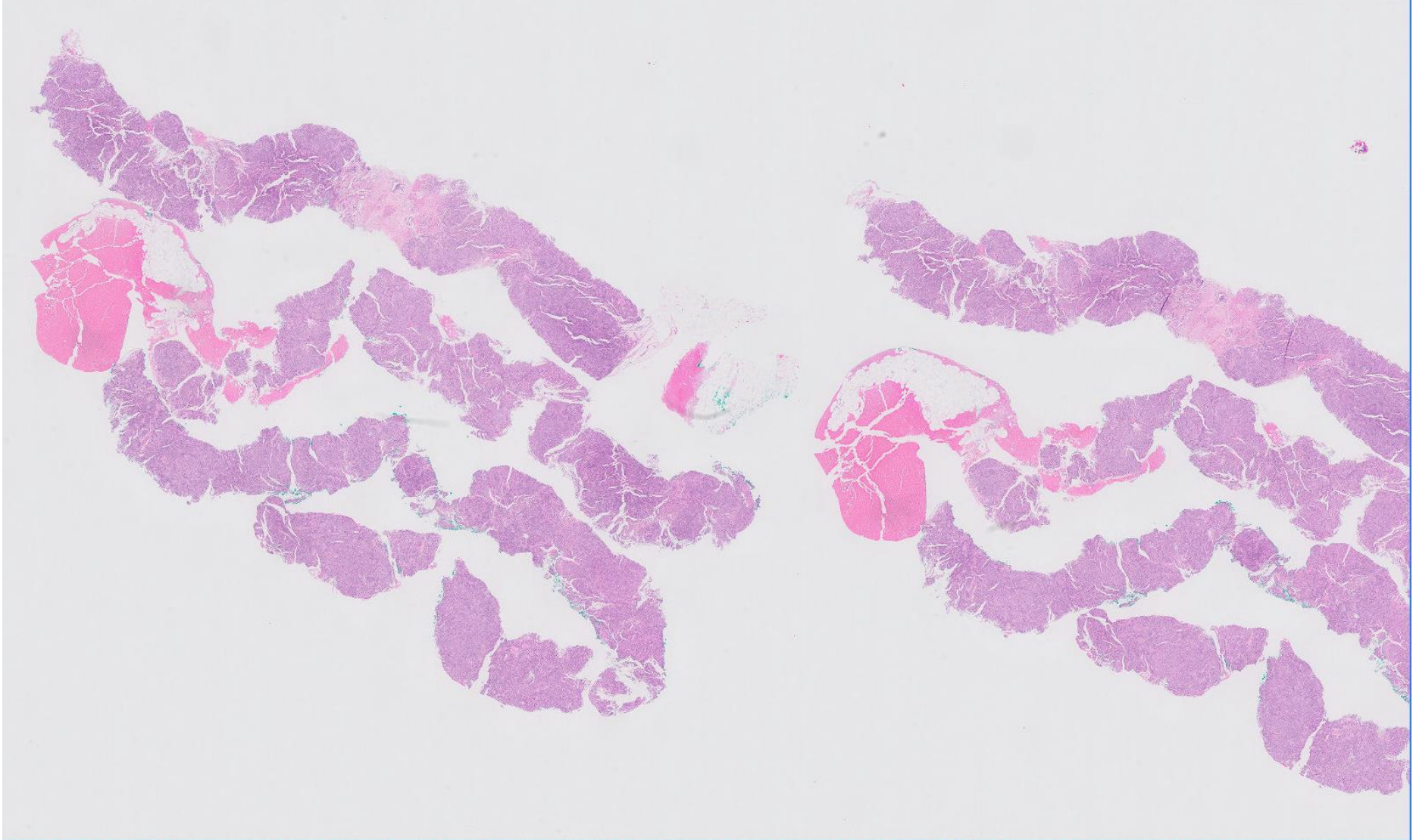
0.119 mm²



50 μ m

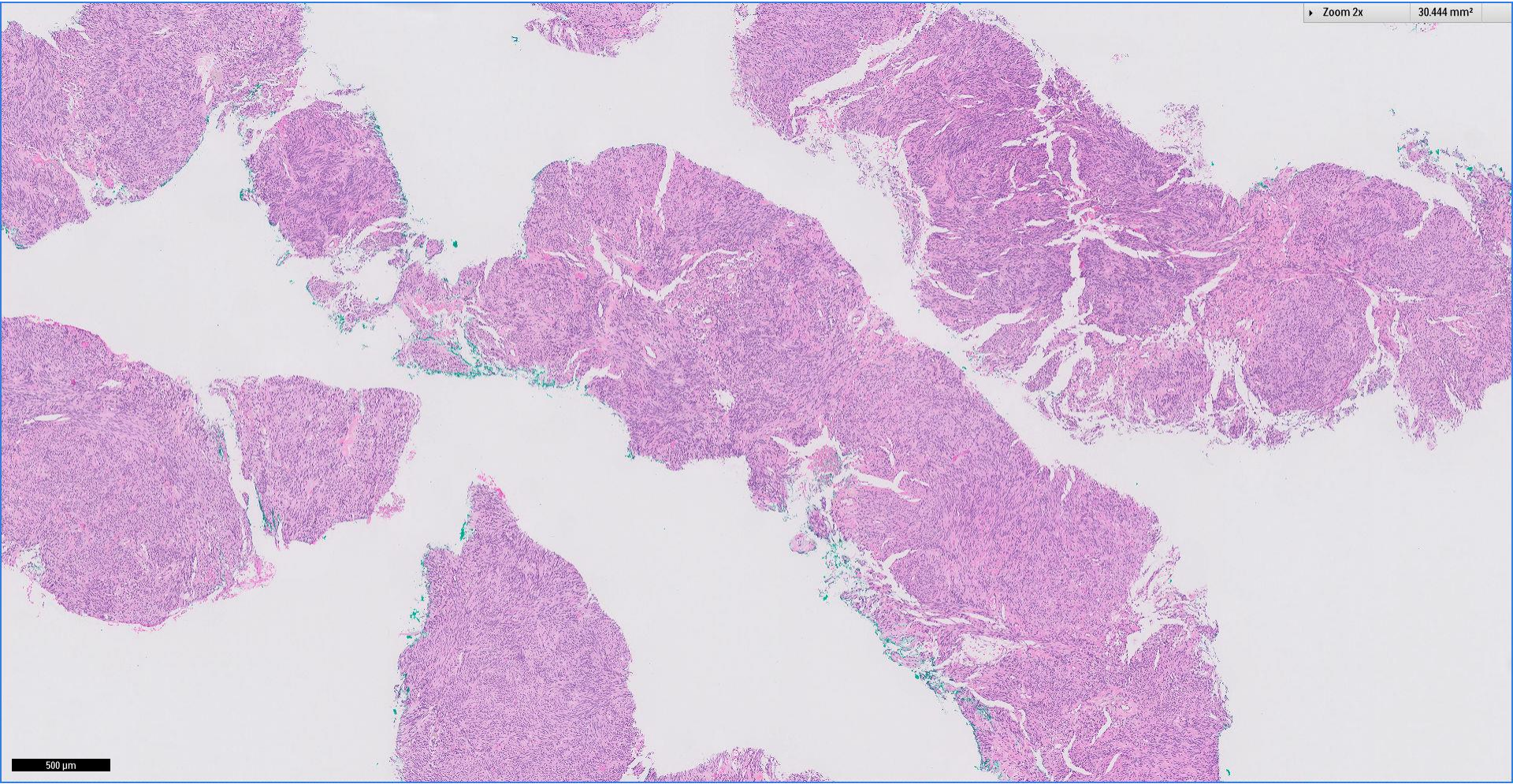
Section from right breast (B).





Zoom 2x

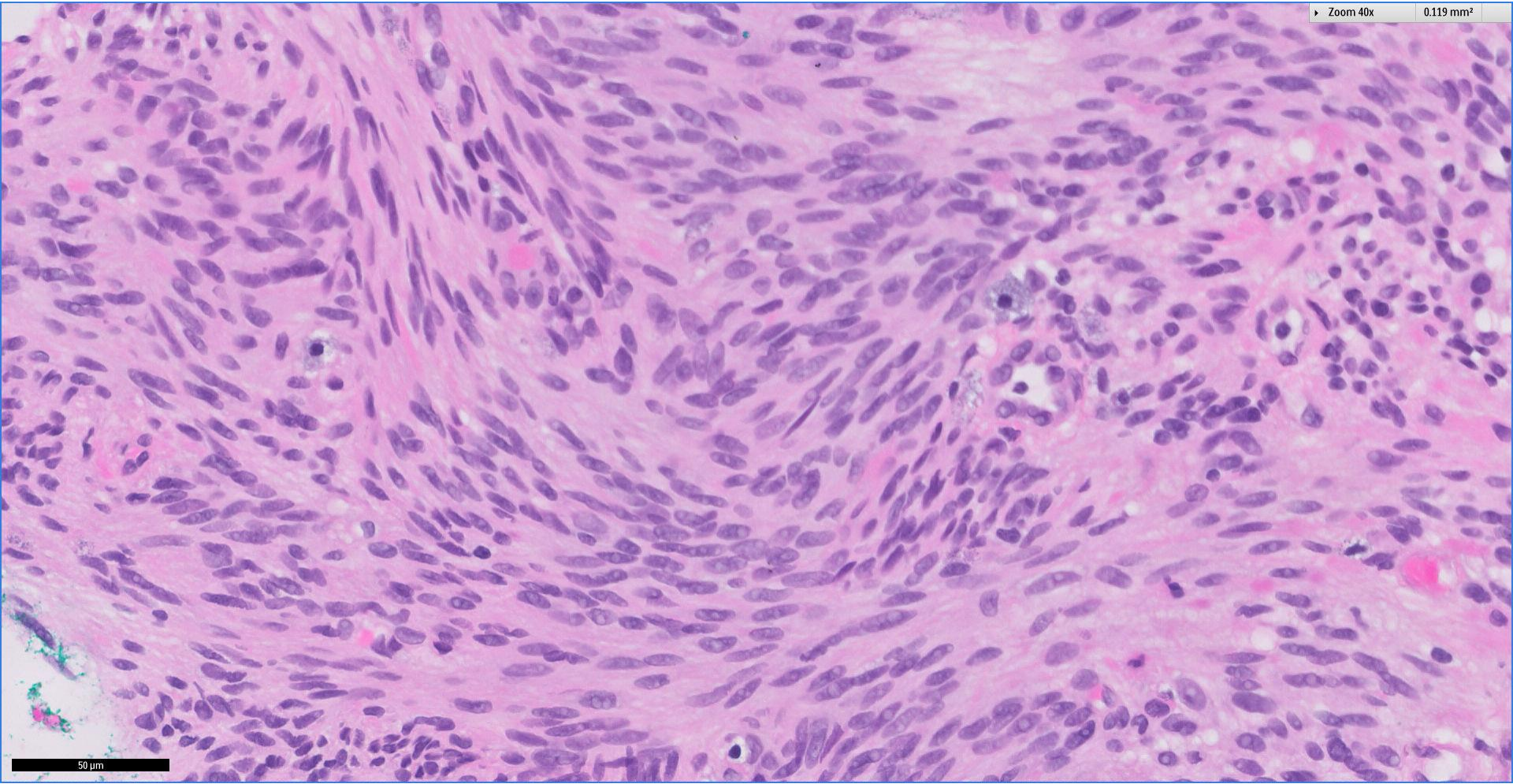
30.444 mm²



500 μ m


Zoom 40x

0.119 mm²



50 μ m

 Breast
Pathology
Course 2018



Singapore
General Hospital

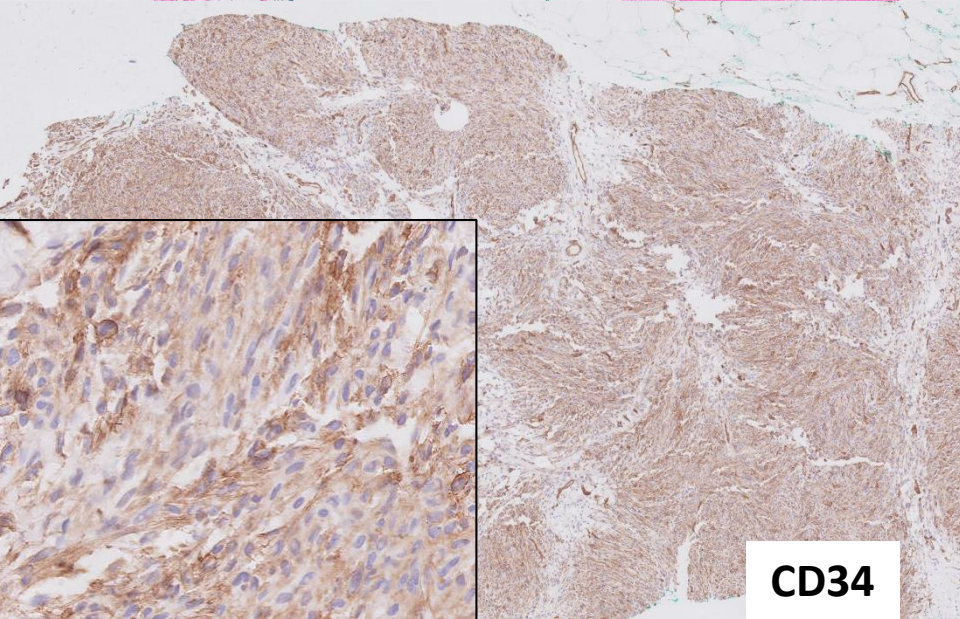
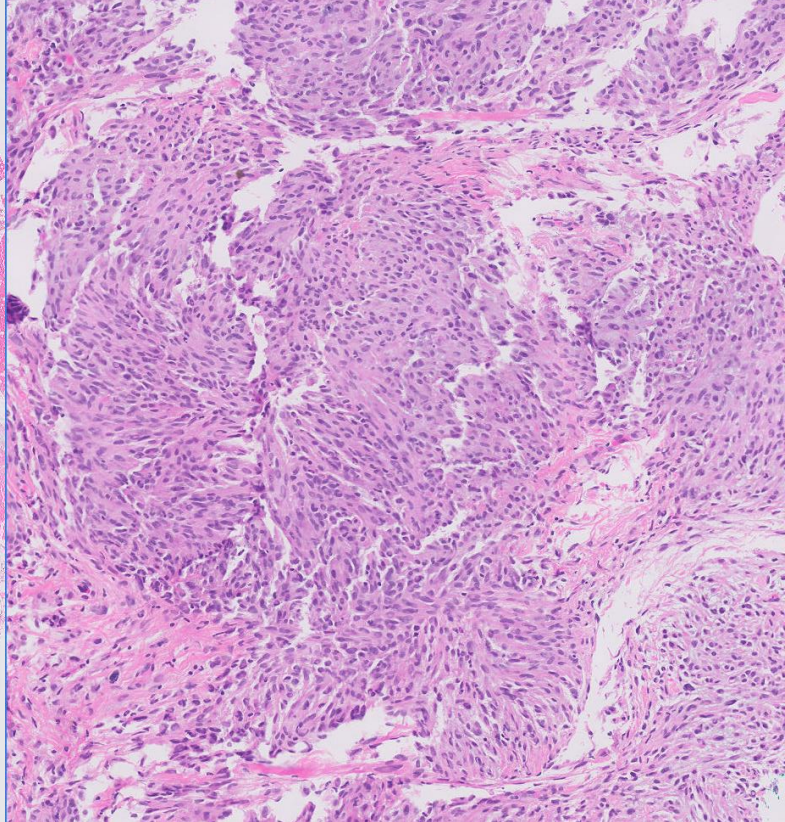
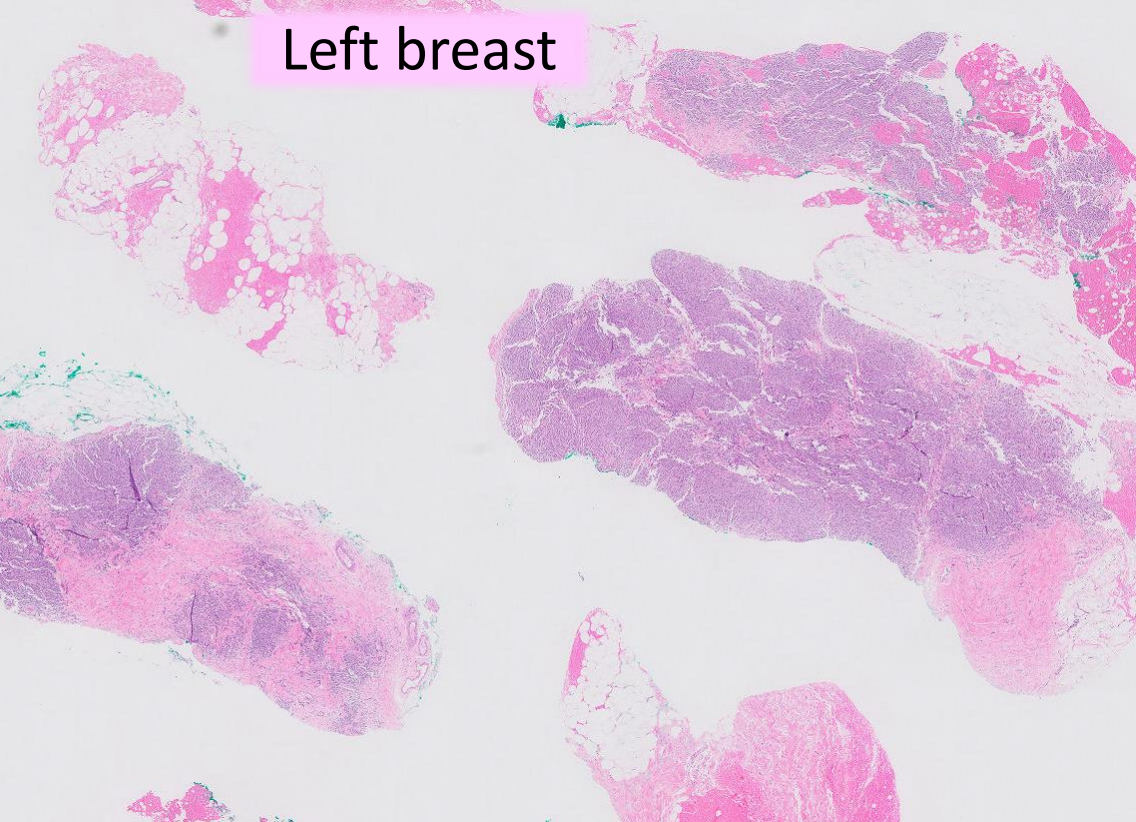SingHealth
Division of Pathology


SingHealth DukeNUS
ACADEMIC MEDICAL CENTRE

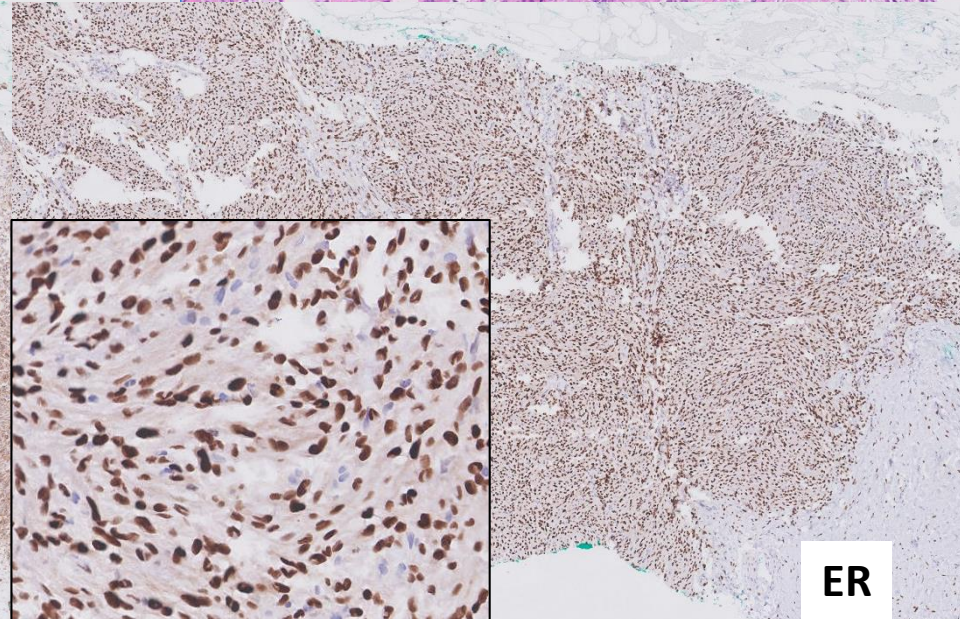
PATHOLOGY



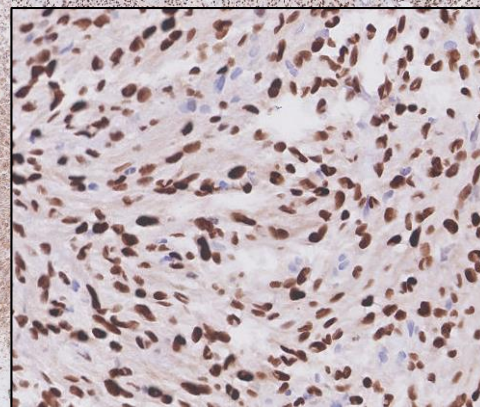
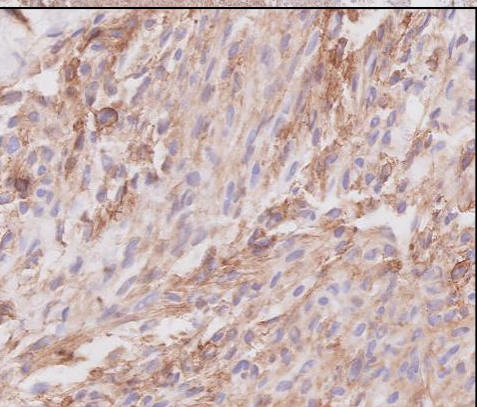
Left breast



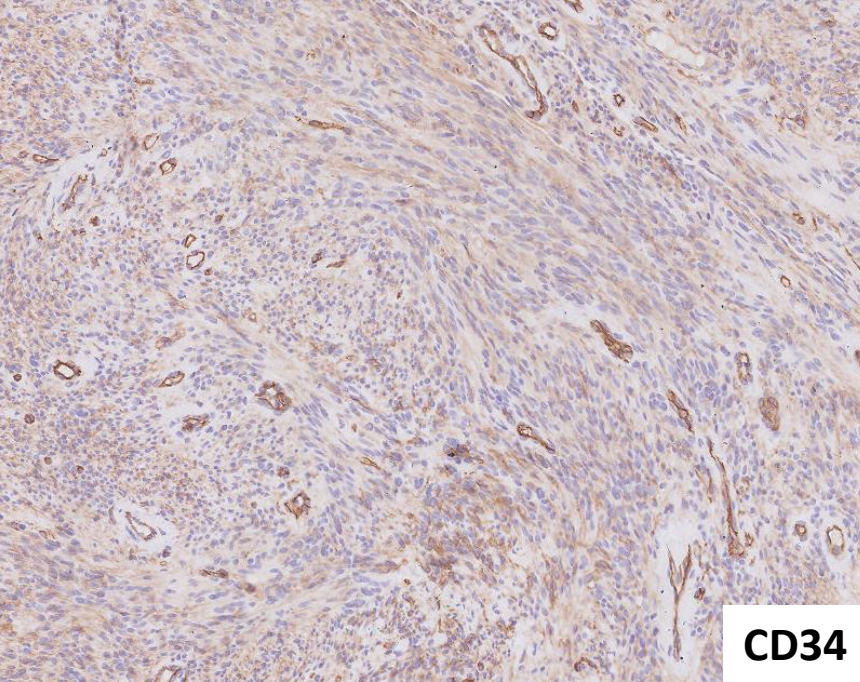
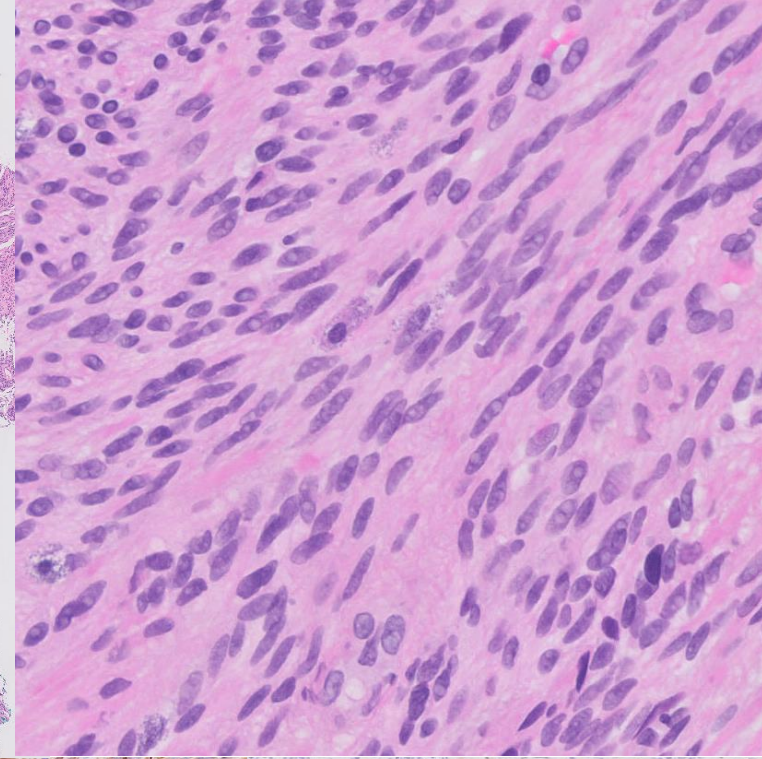
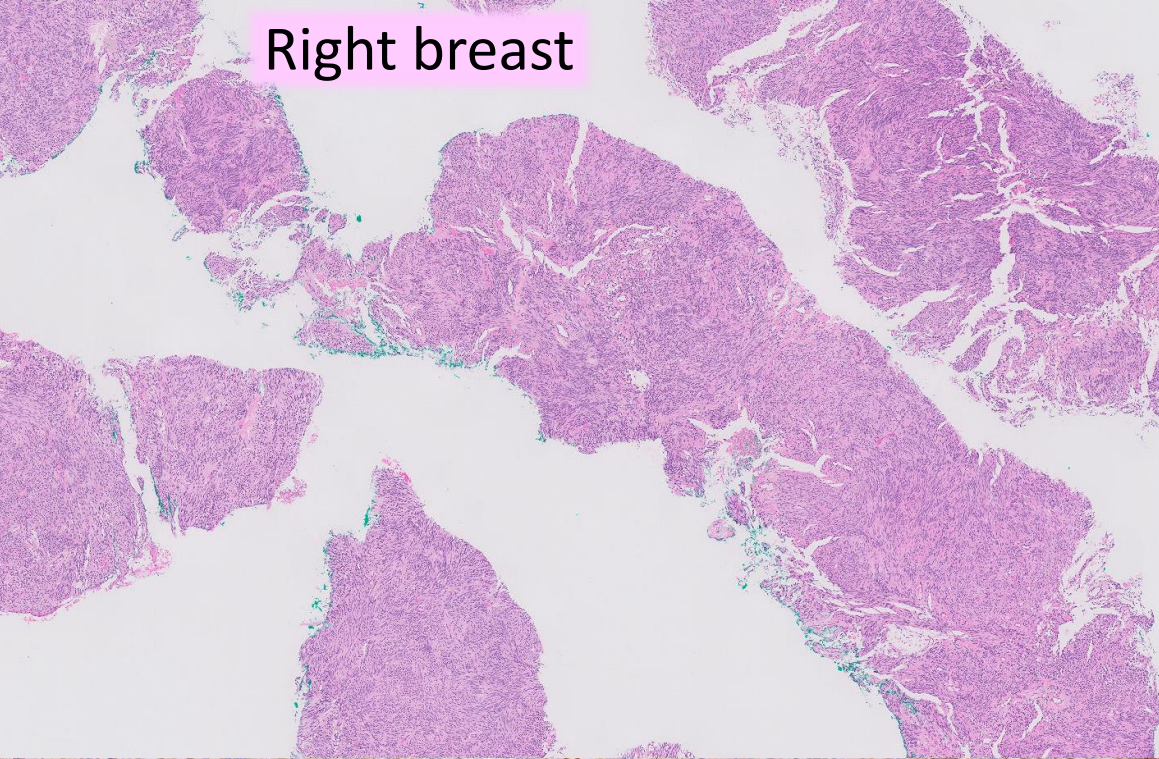
CD34



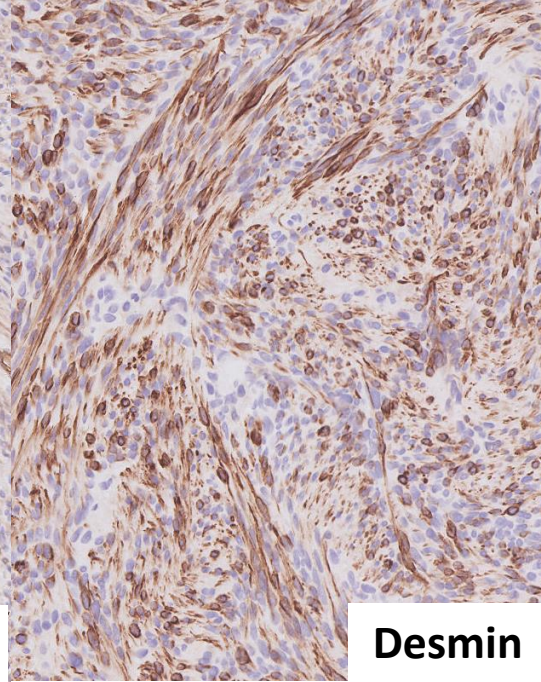
ER



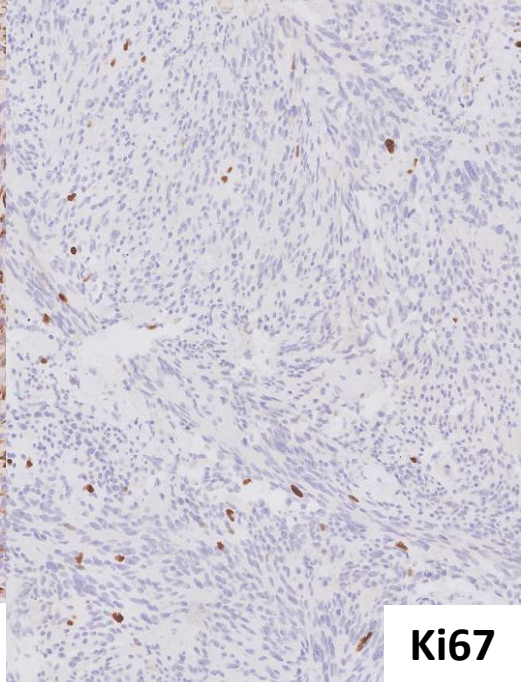
Right breast



CD34



Desmin



Ki67


Diagnosis

Left breast 12 o'clock 17 x 11 x 20mm.

Right breast 2 o'clock 5 x 3 x 9mm.

Ultrasound guided core biopsies of both nodules ~

Myofibroblastomas



Myofibroblastoma

- Rare benign spindle stromal neoplasm arising from the connective tissue of the breast.
- Middle aged to elderly men and women.
- Clinically presents as a unilateral mobile painless lump.
- Bilaterality can occur though uncommon.
- Treatment of choice in symptomatic cases is resection.
- No recurrence has been reported after excision.
- Asymptomatic small tumours can be observed for stability.

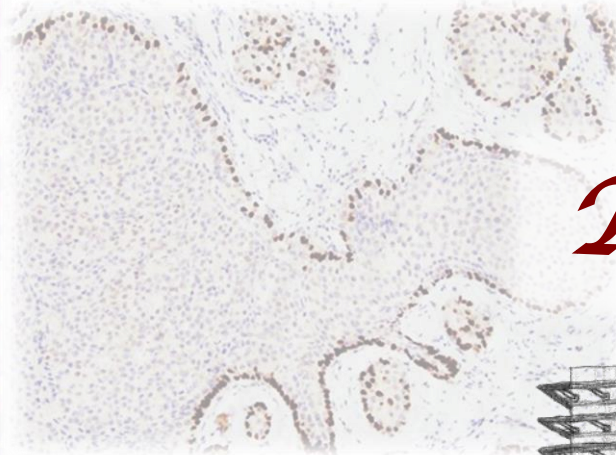
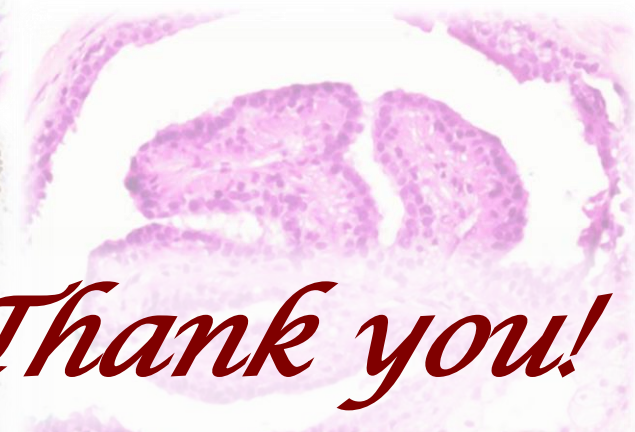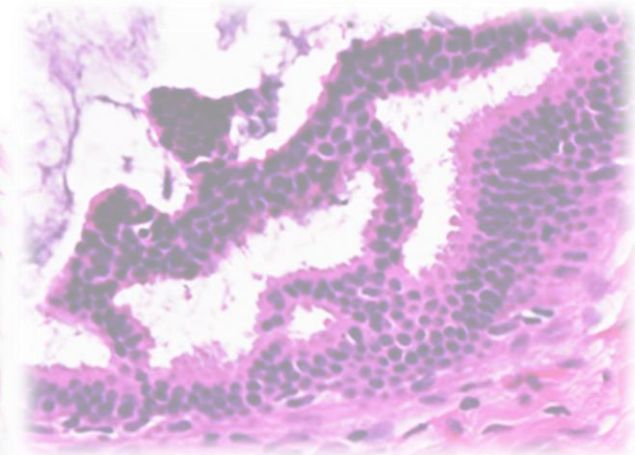
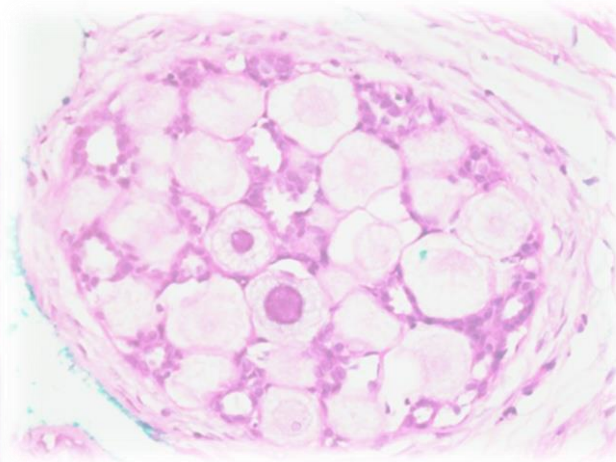
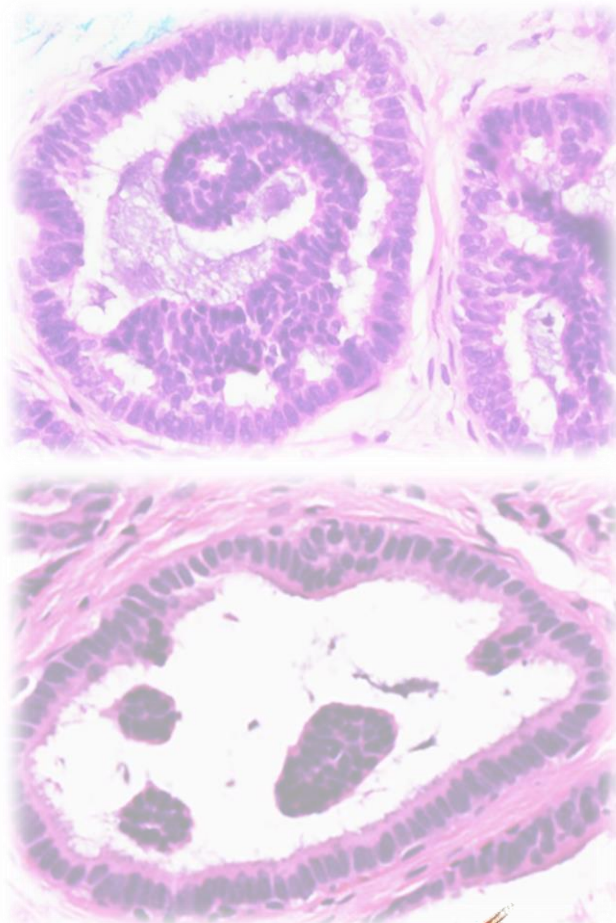


Singapore
General Hospital

SingHealth
Division of Pathology



 Breast
Pathology
Course 2018



Thank you!

 Singapore
General Hospital
SingHealth
Division of Pathology

 SingHealth DukeNUS
ACADEMIC MEDICAL CENTRE
PATHOLOGY

 **IAP**
International Academy of Pathology
Singapore Division

