

Case 27

28 year old Chinese woman.

Bilateral nipple sparing mastectomy.

Sections from the right (A) and left (B) tumours.



Singapore
General Hospital

SingHealth

Division of Pathology



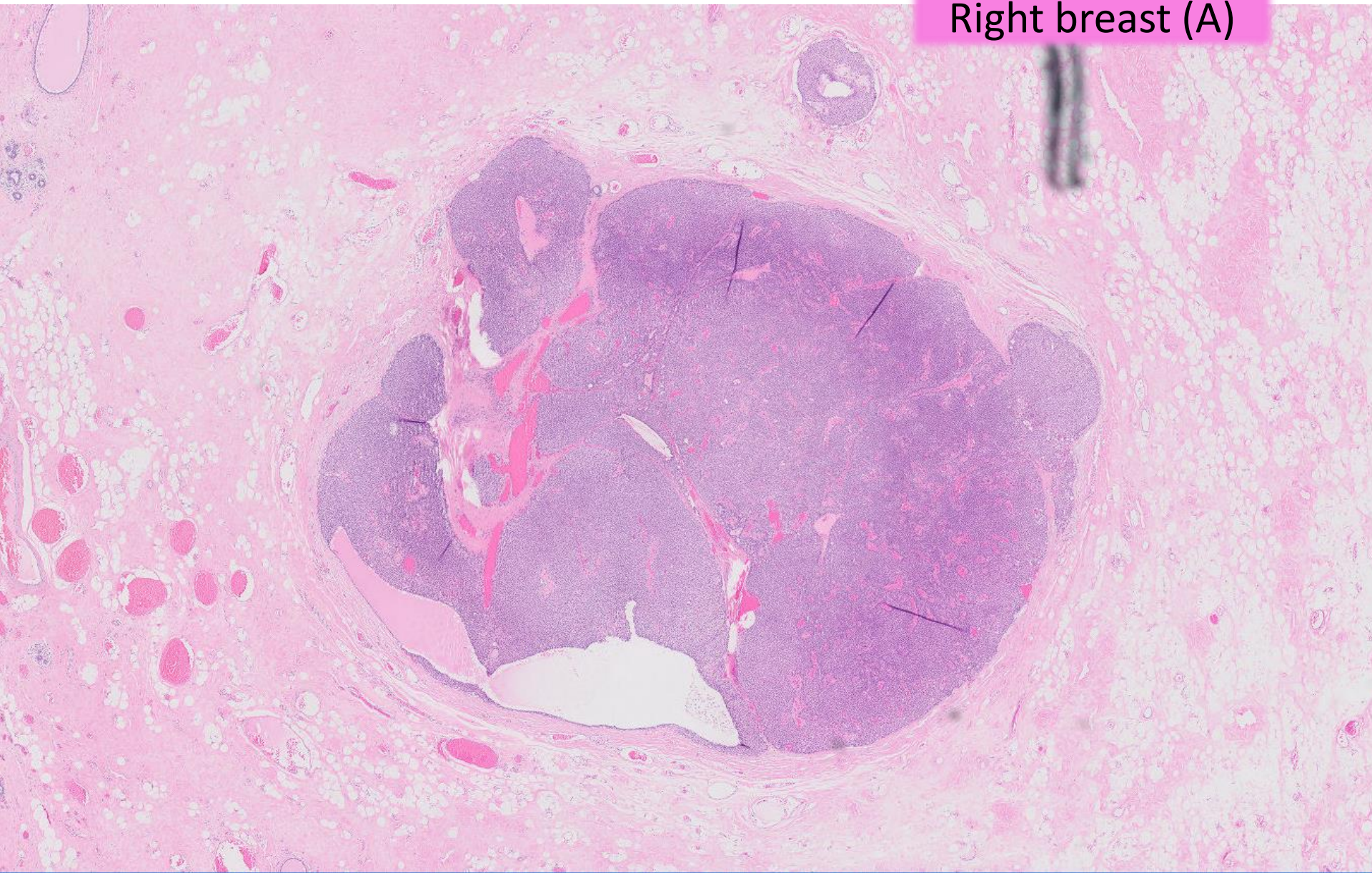PATHOLOGY

IAP

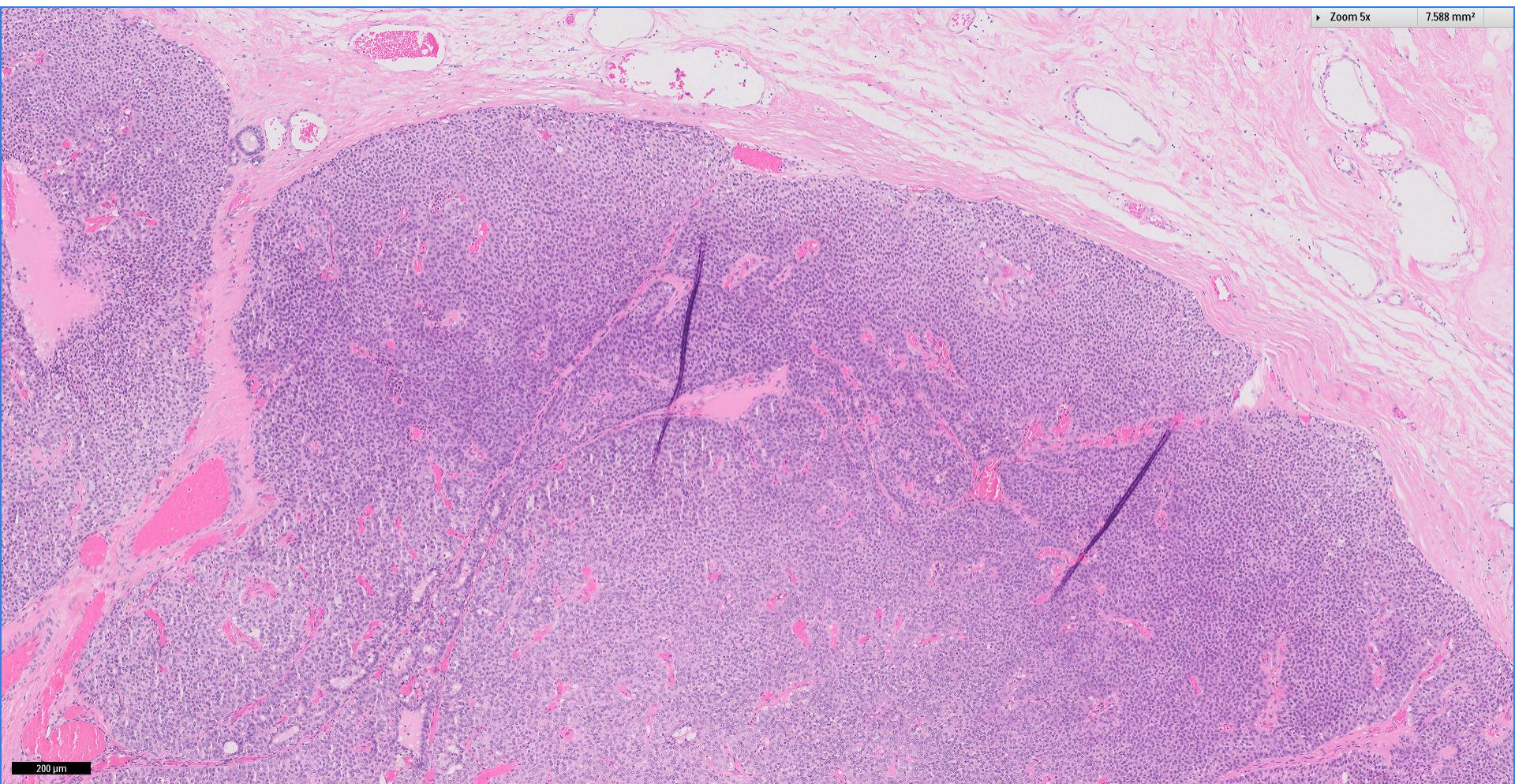
International Academy of Pathology
Singapore Division



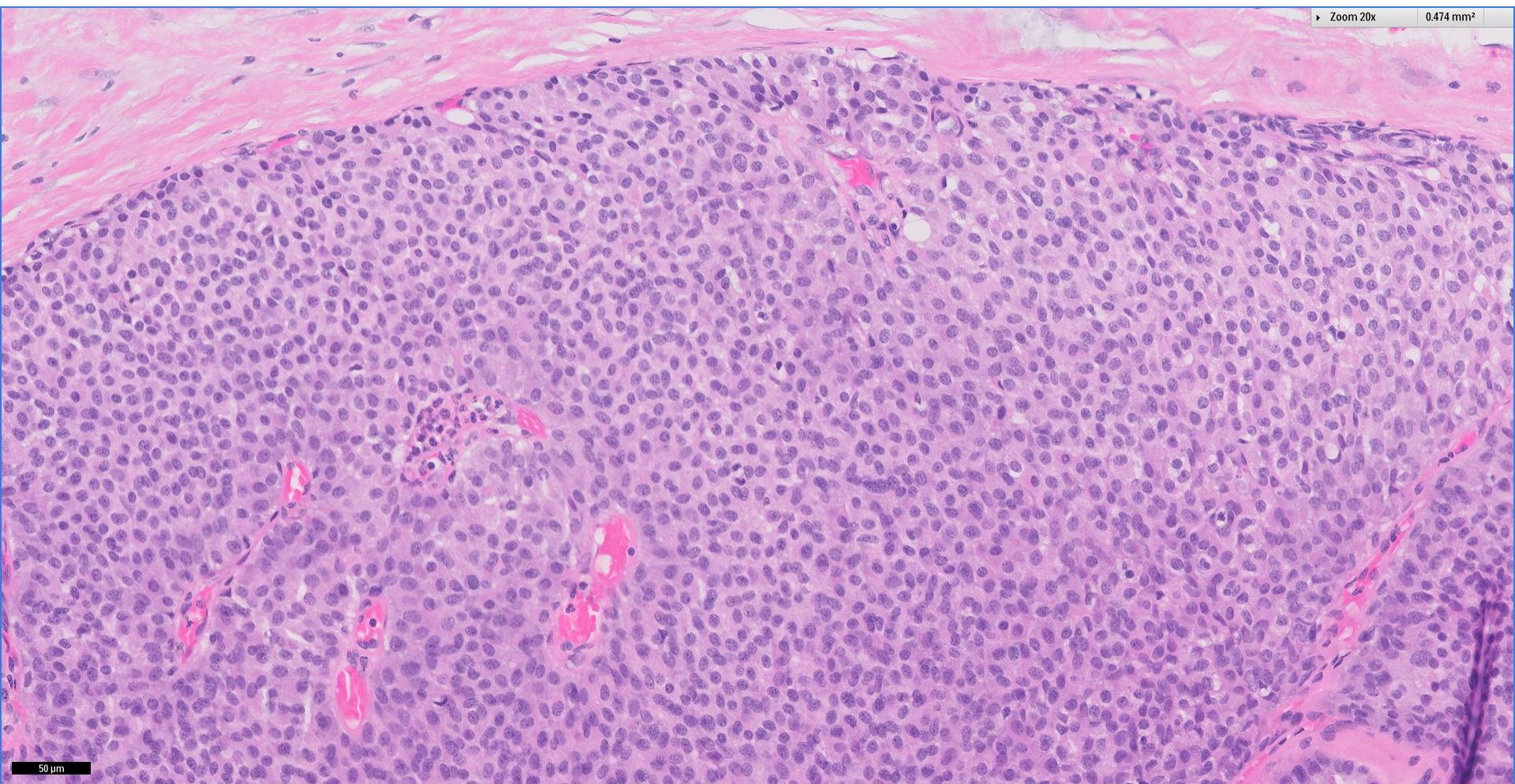
Right breast (A)



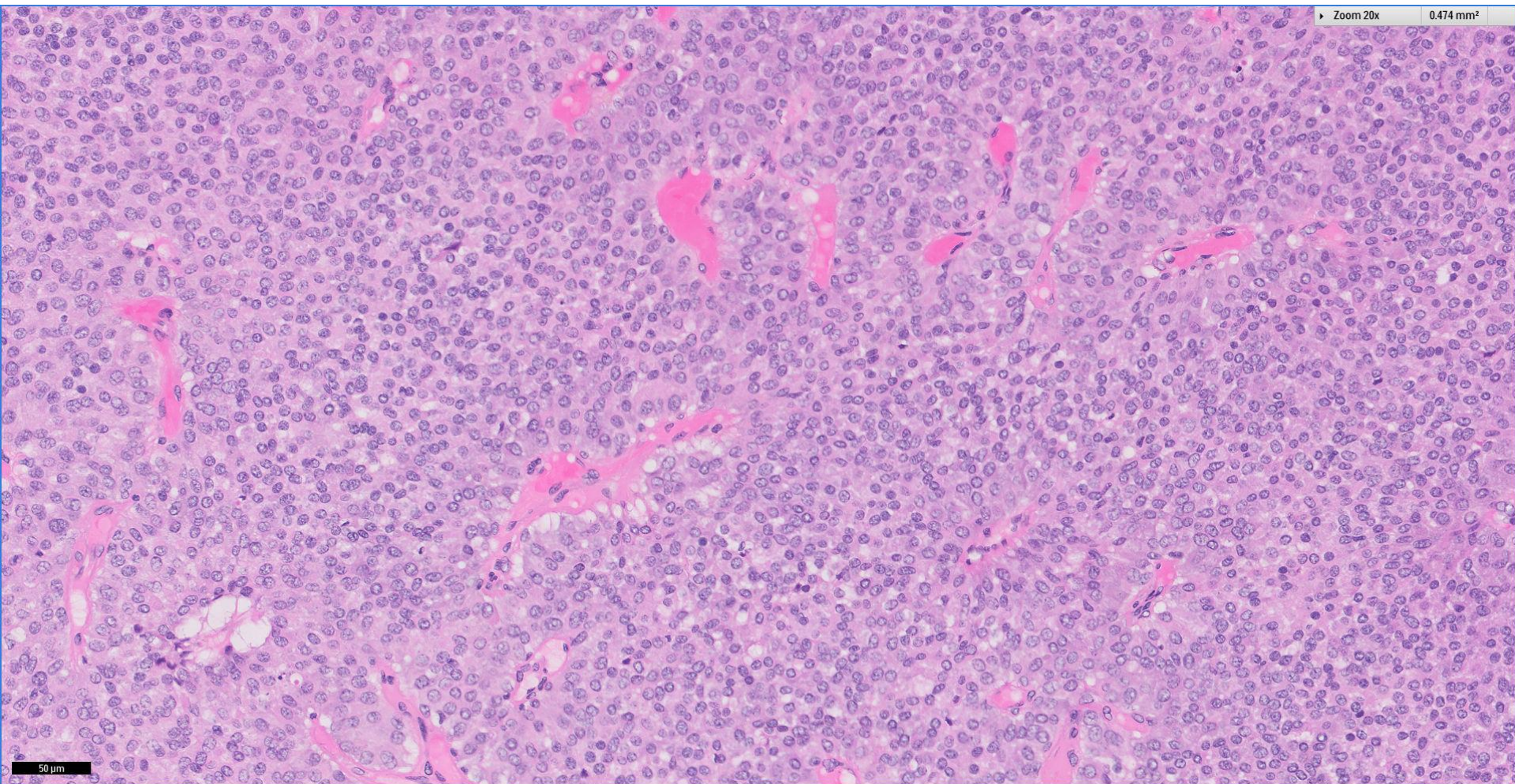
Right breast (A)



Right breast (A)



Right breast (A)

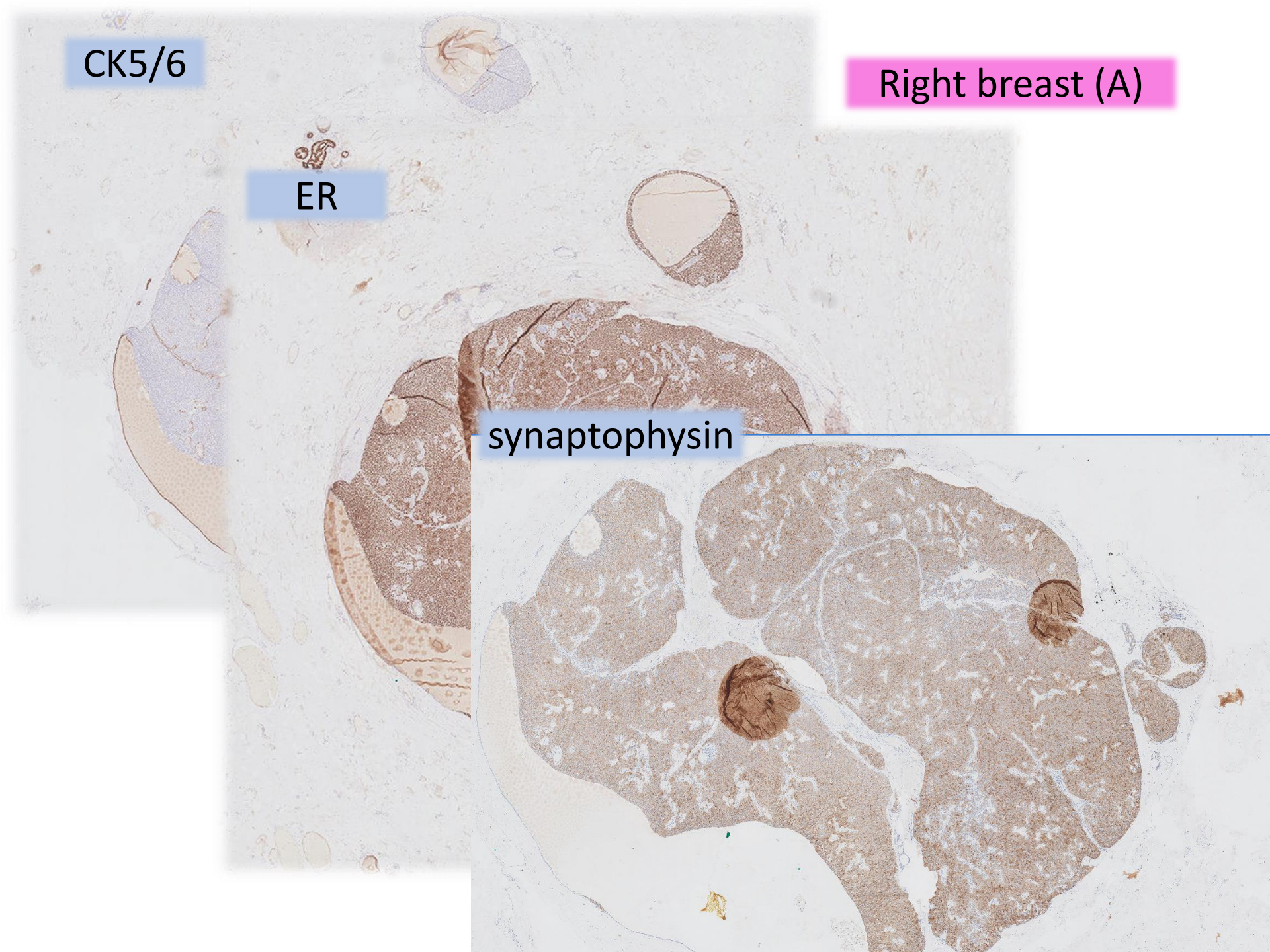


Right breast (A)

CK5/6

ER

synaptophysin

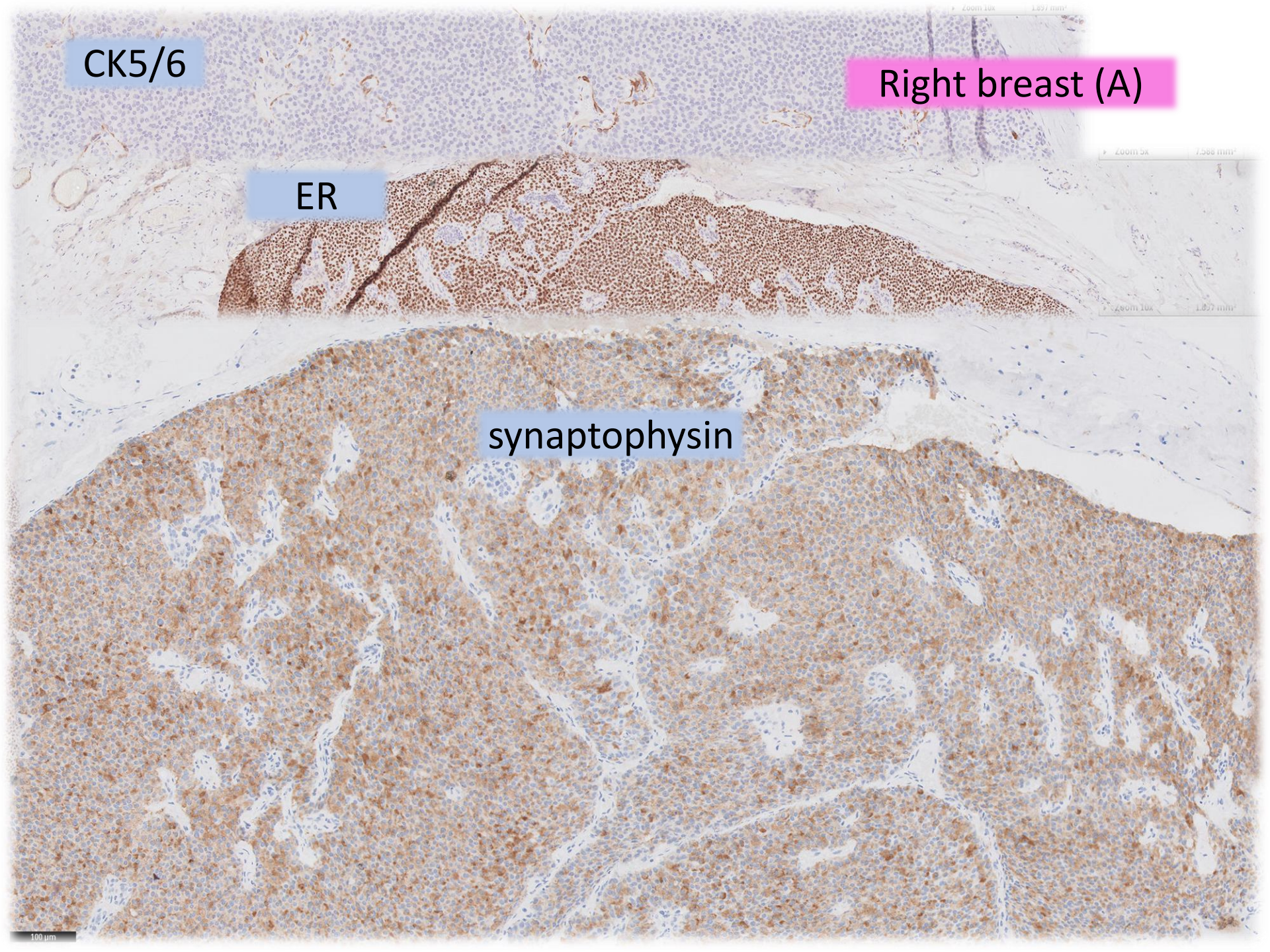


Right breast (A)

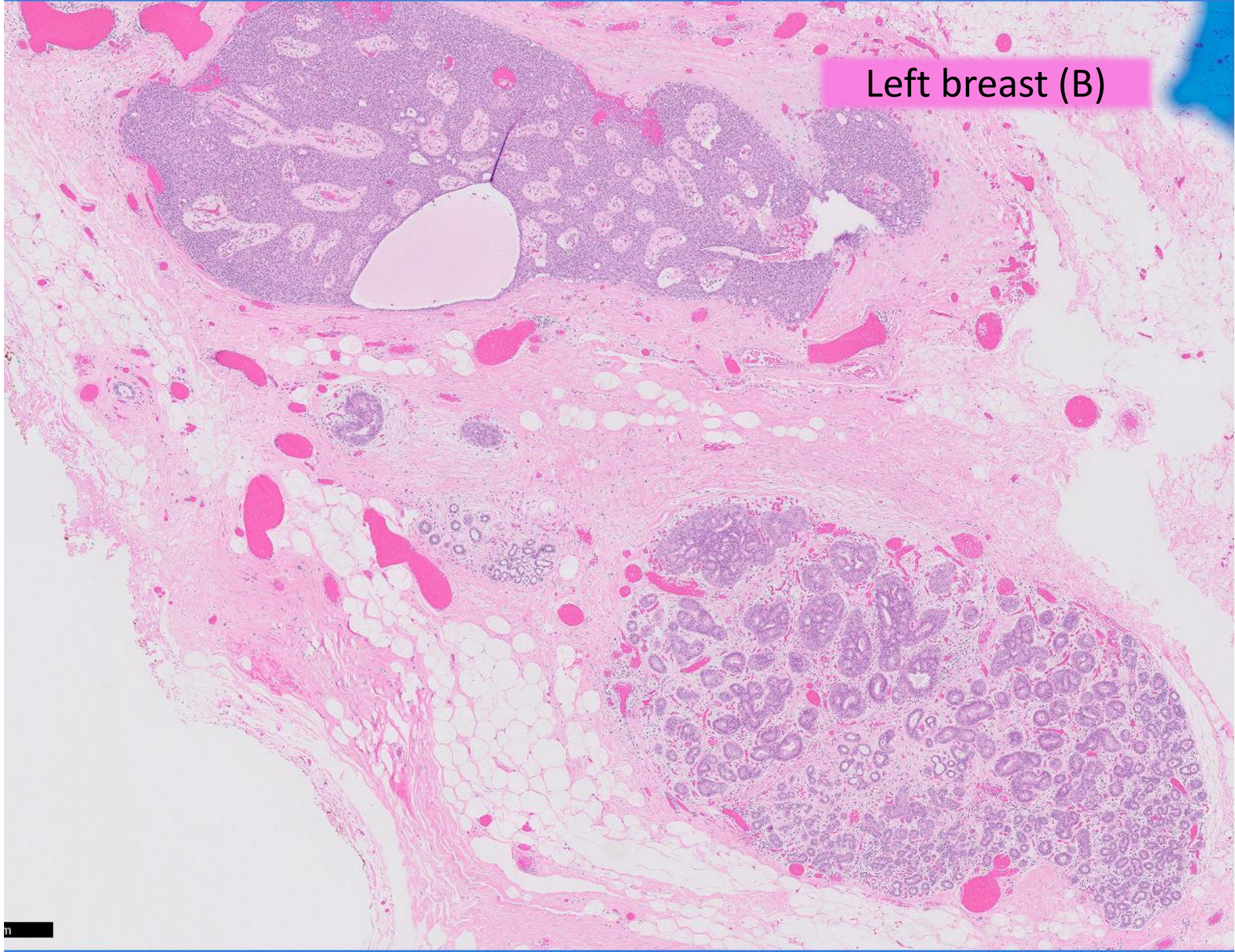CK5/6

ER

synaptophysin

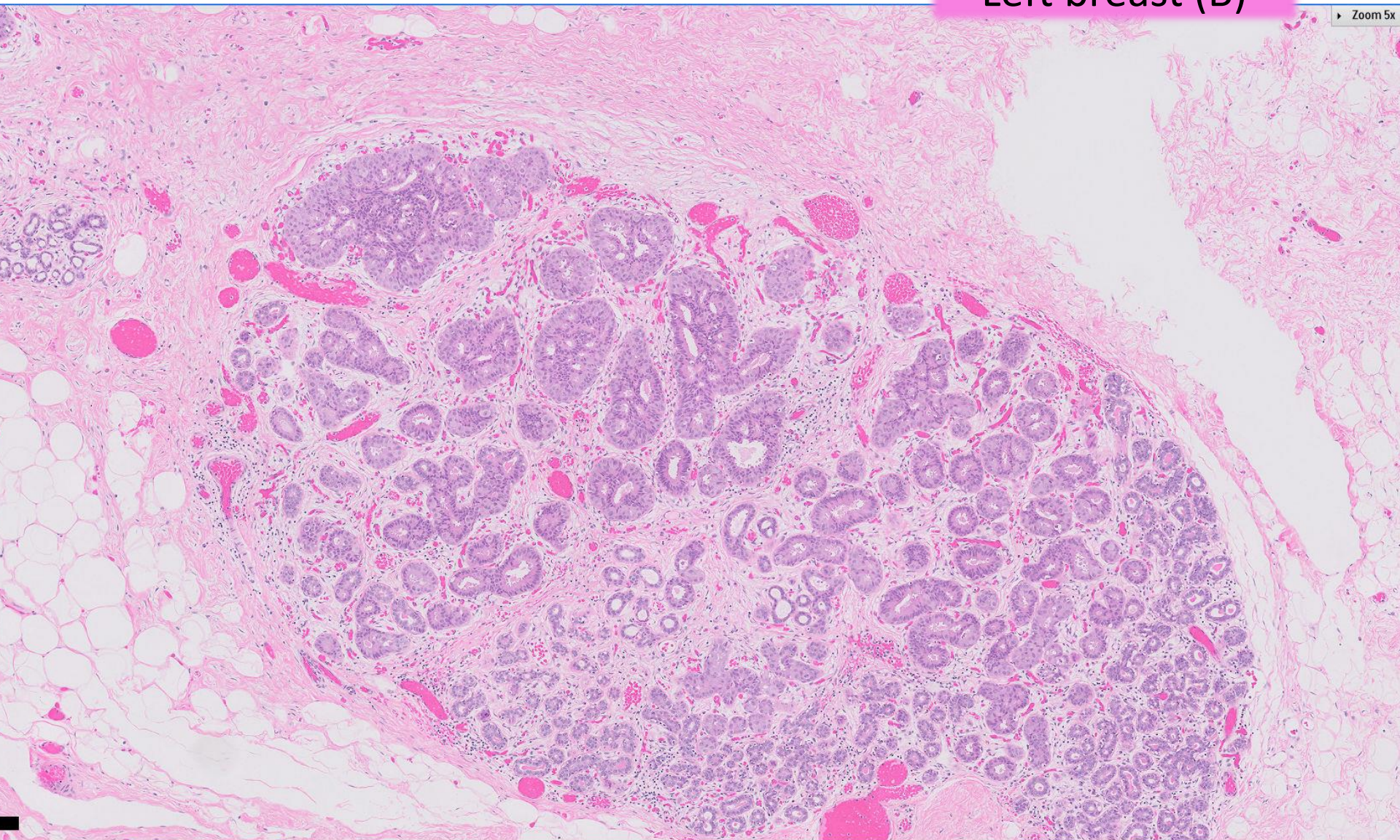


Left breast (B)



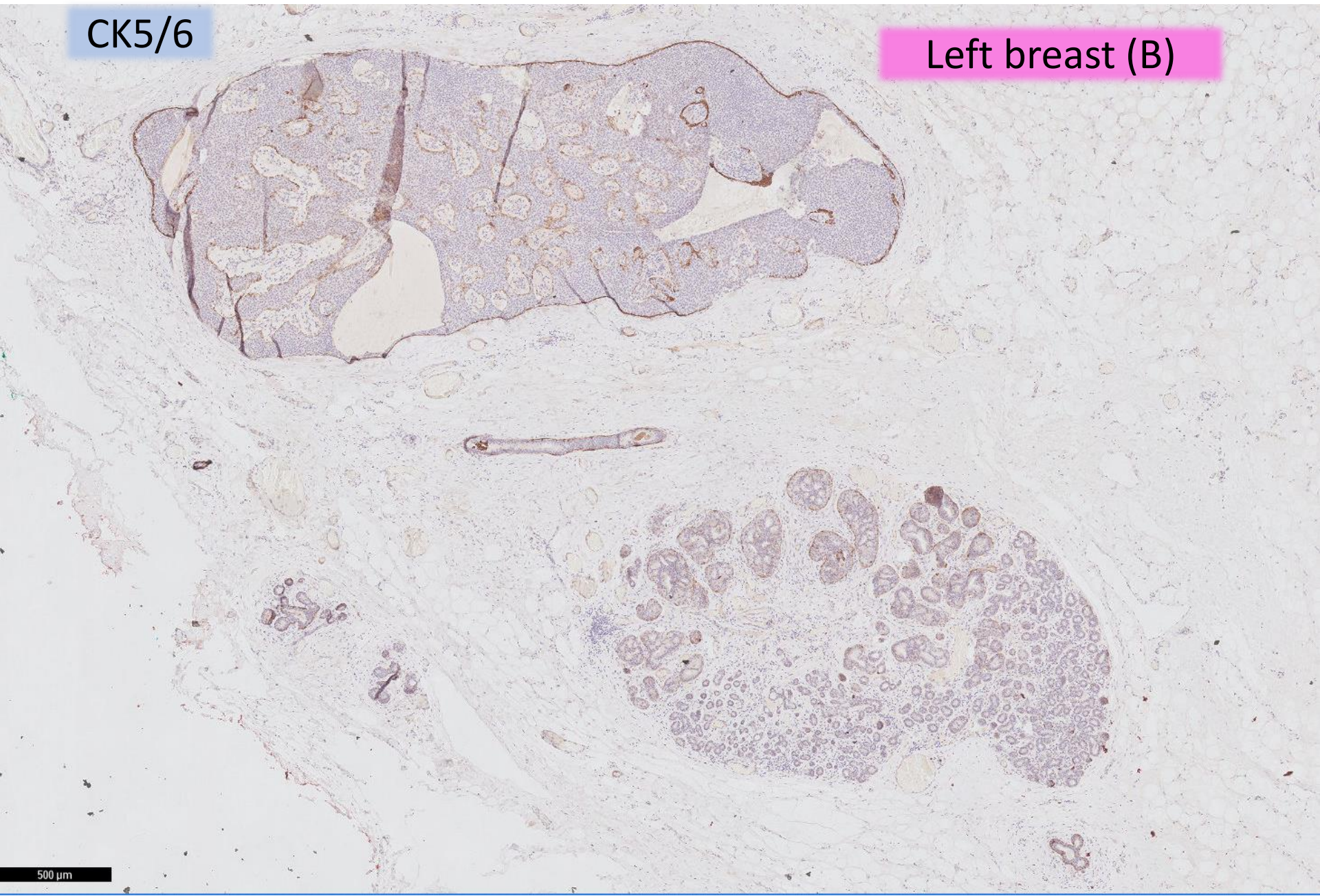
Left breast (B)

Zoom 5x



CK5/6

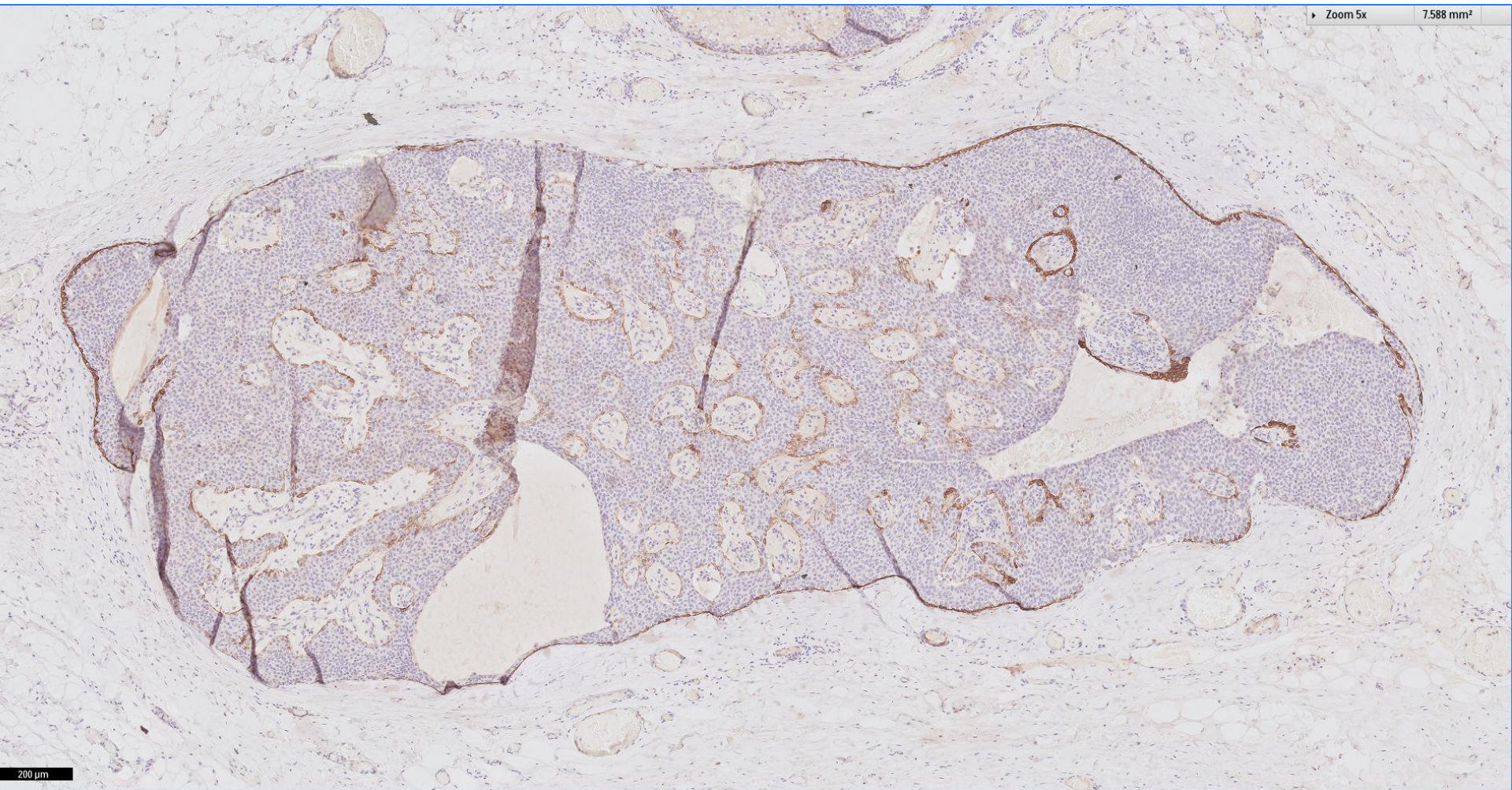
Left breast (B)



500 μm

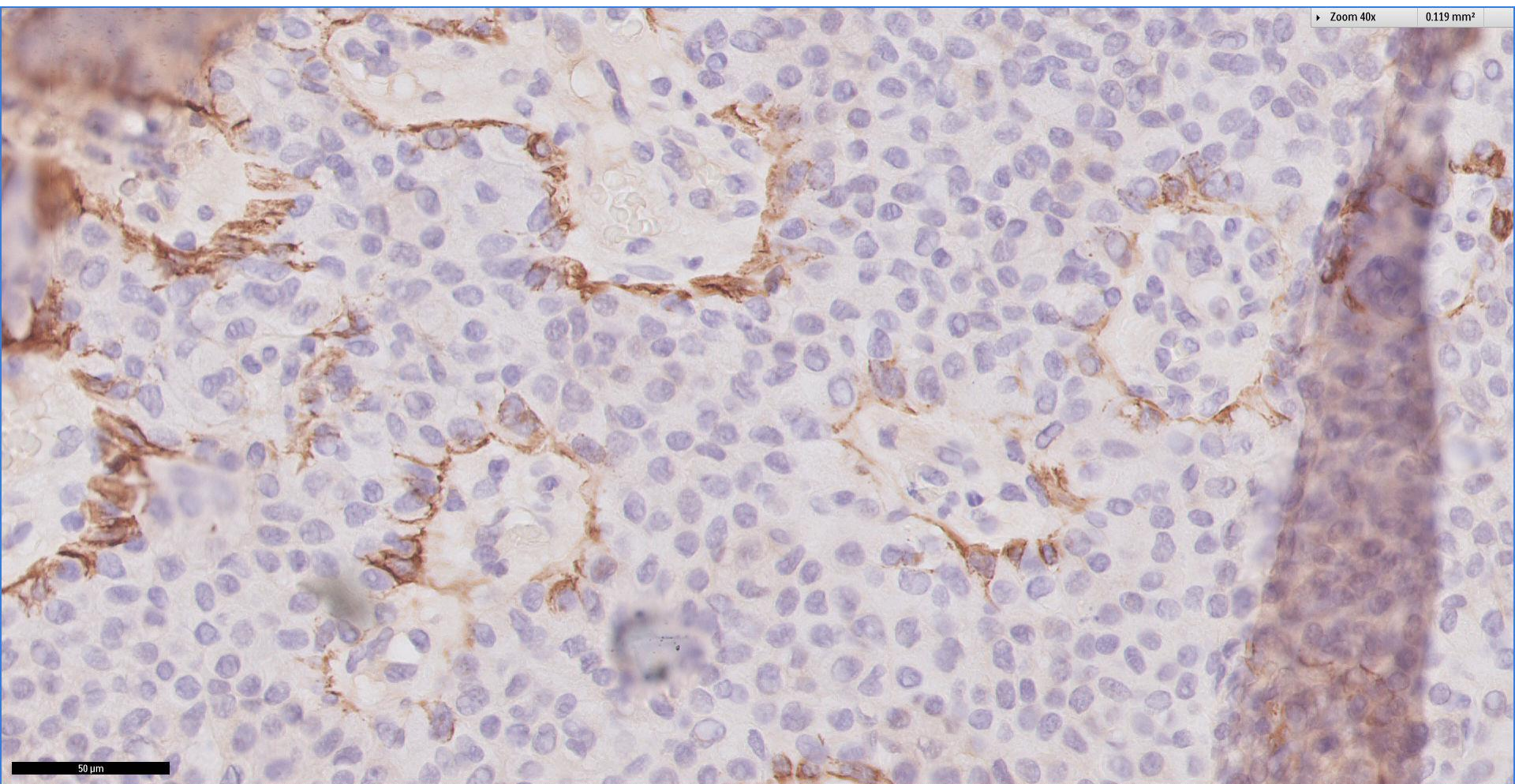
CK5/6

Left breast (B)



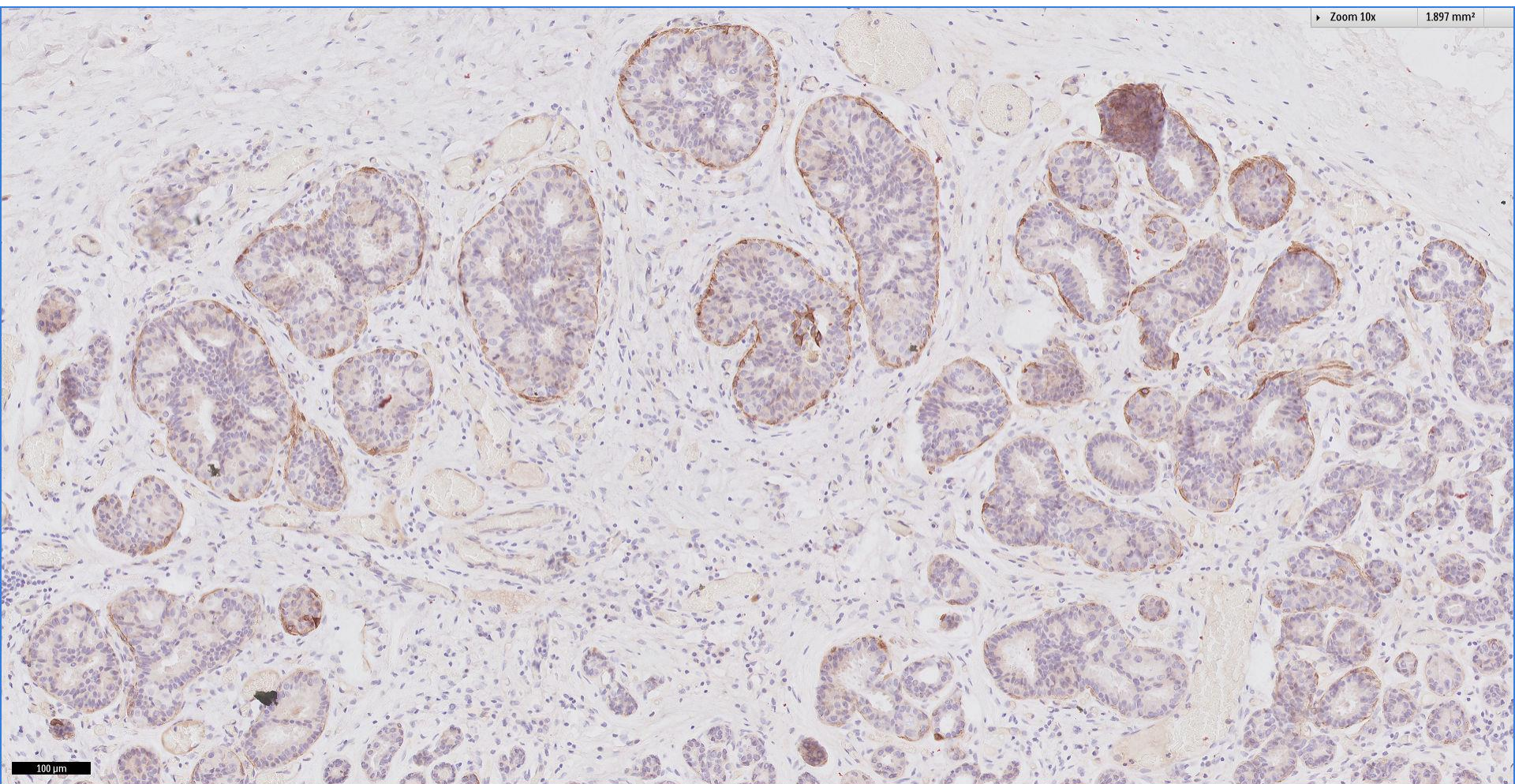
CK5/6

Left breast (B)



CK5/6

Left breast (B)



Diagnosis

Right breast tumour, A ~

Solid-papillary carcinoma in situ, low to intermediate nuclear grade, without necrosis, 14mm.

Left breast tumour, B ~

Solid-papillary carcinoma in situ, low to intermediate nuclear grade, without necrosis, 5mm.



Singapore
General Hospital

SingHealth
Division of Pathology



SingHealth DukeNUS
ACADEMIC MEDICAL CENTRE

PATHOLOGY



IAP
International Academy of Pathology
Singapore Division

 Breast
Pathology
Course 2017

