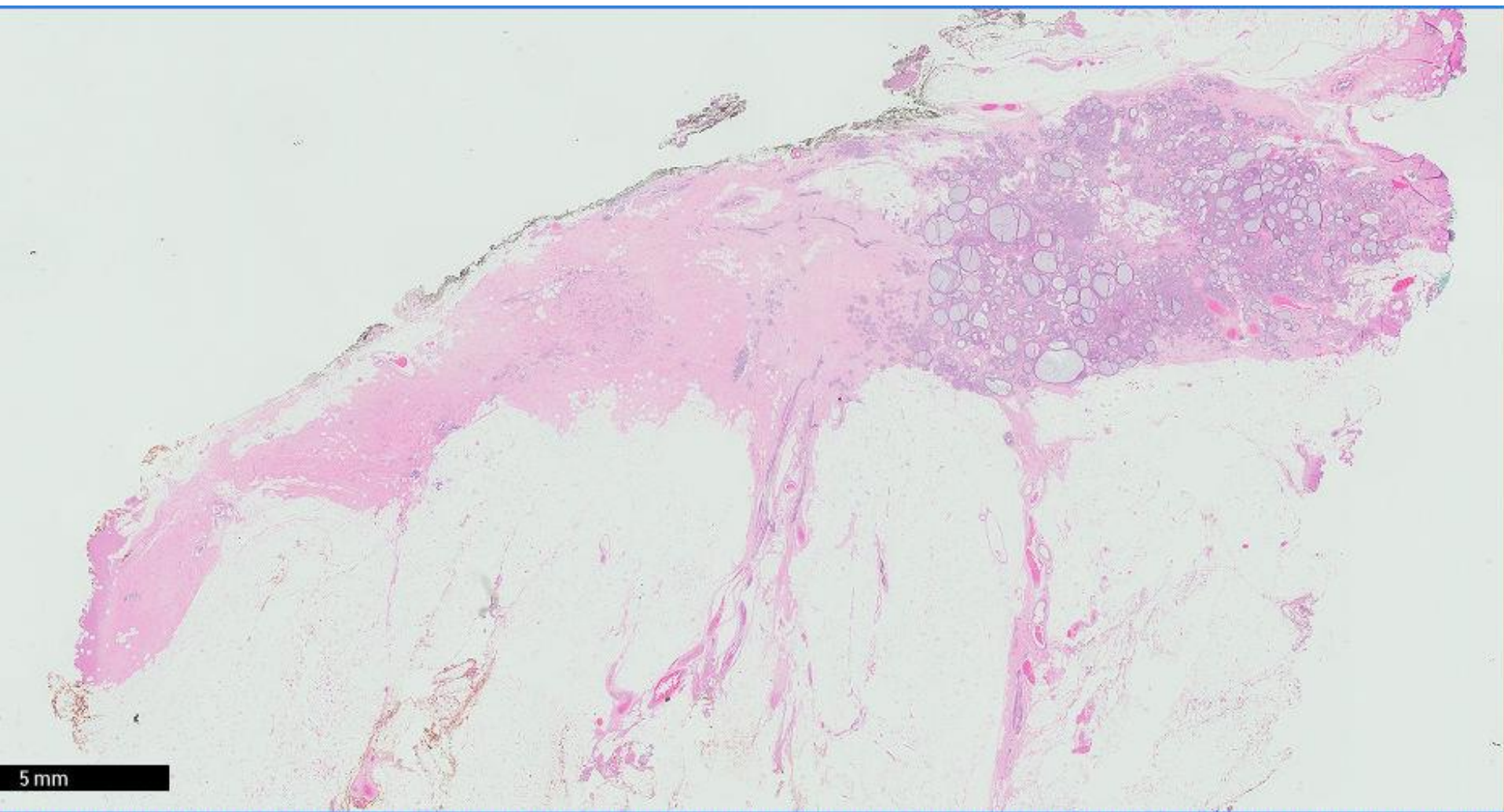


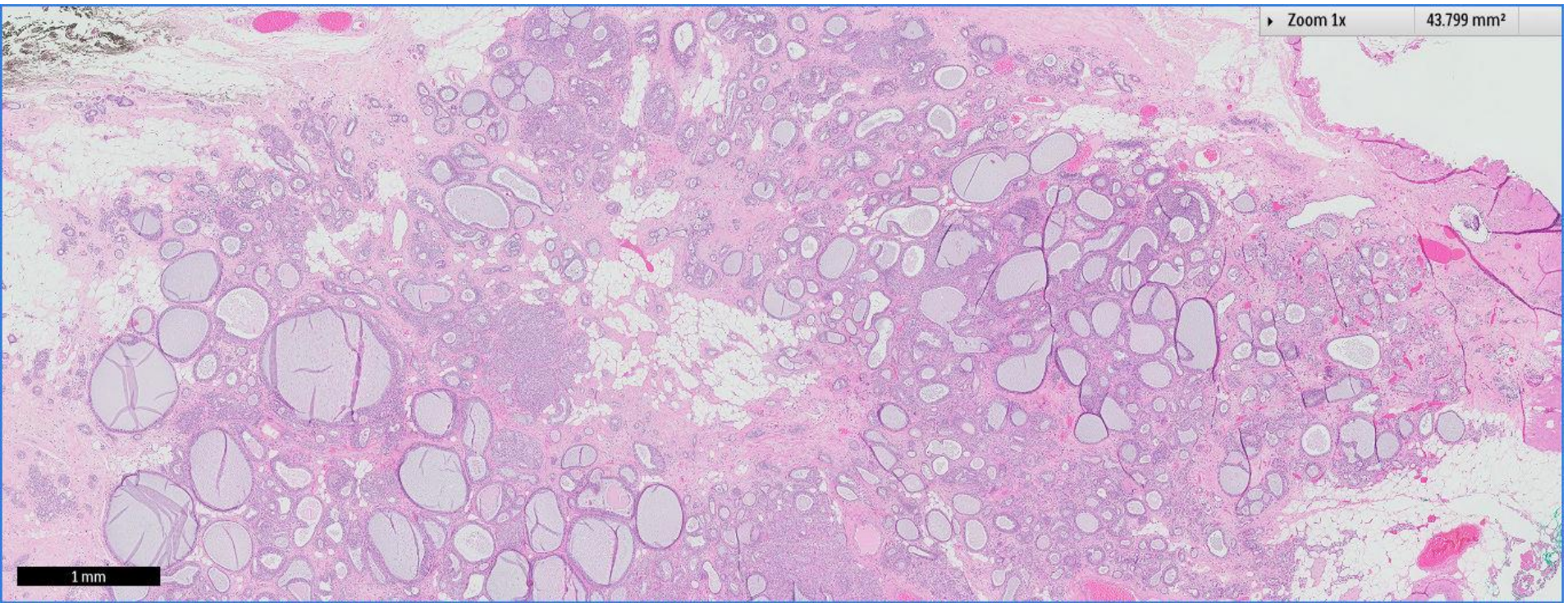
Case 29

66 year old Chinese woman underwent right mastectomy and axillary clearance for right breast invasive ductal carcinoma and sentinel lymph node positivity.

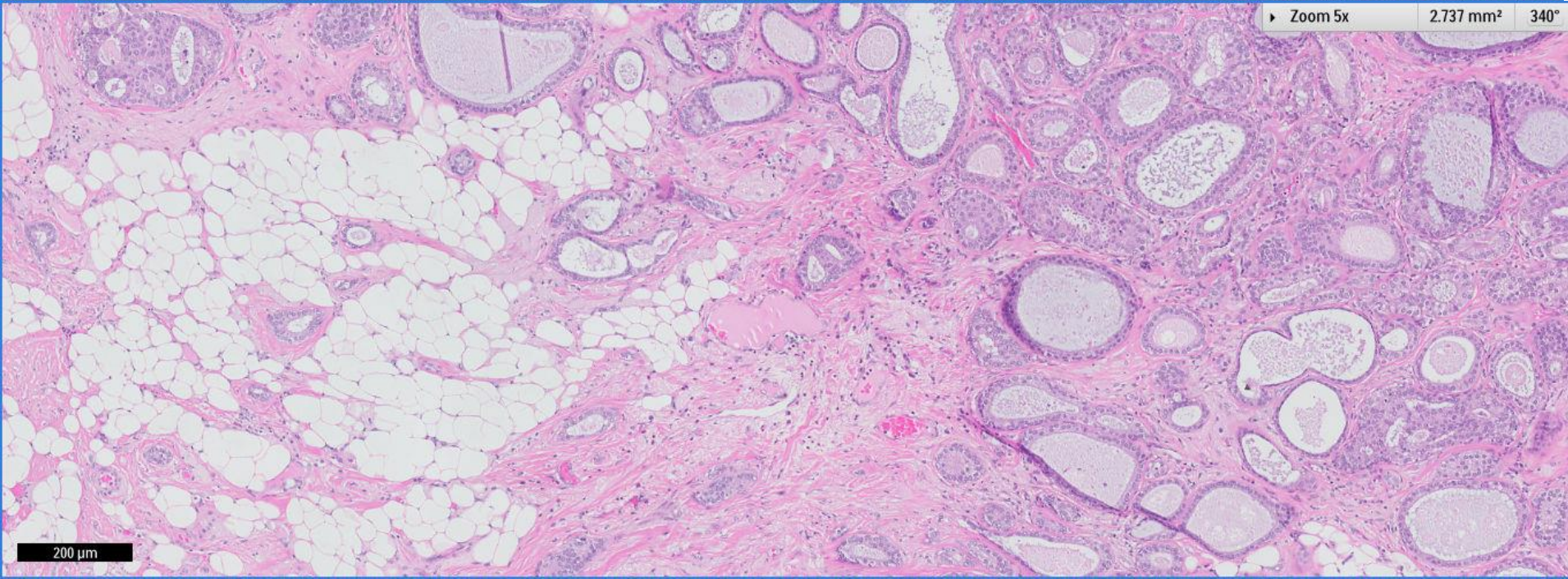
Left breast hookwire localization excision of radiologic pleomorphic calcifications was performed at the same time.

Slide provided is from the left breast.

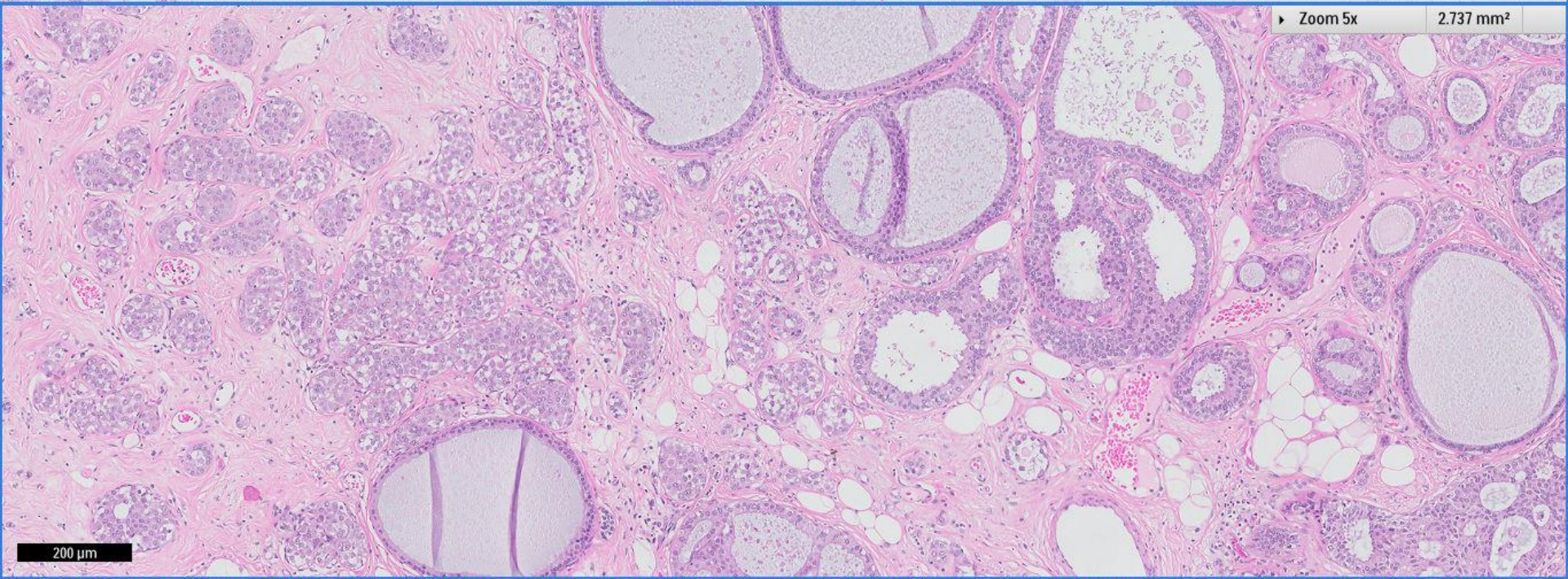
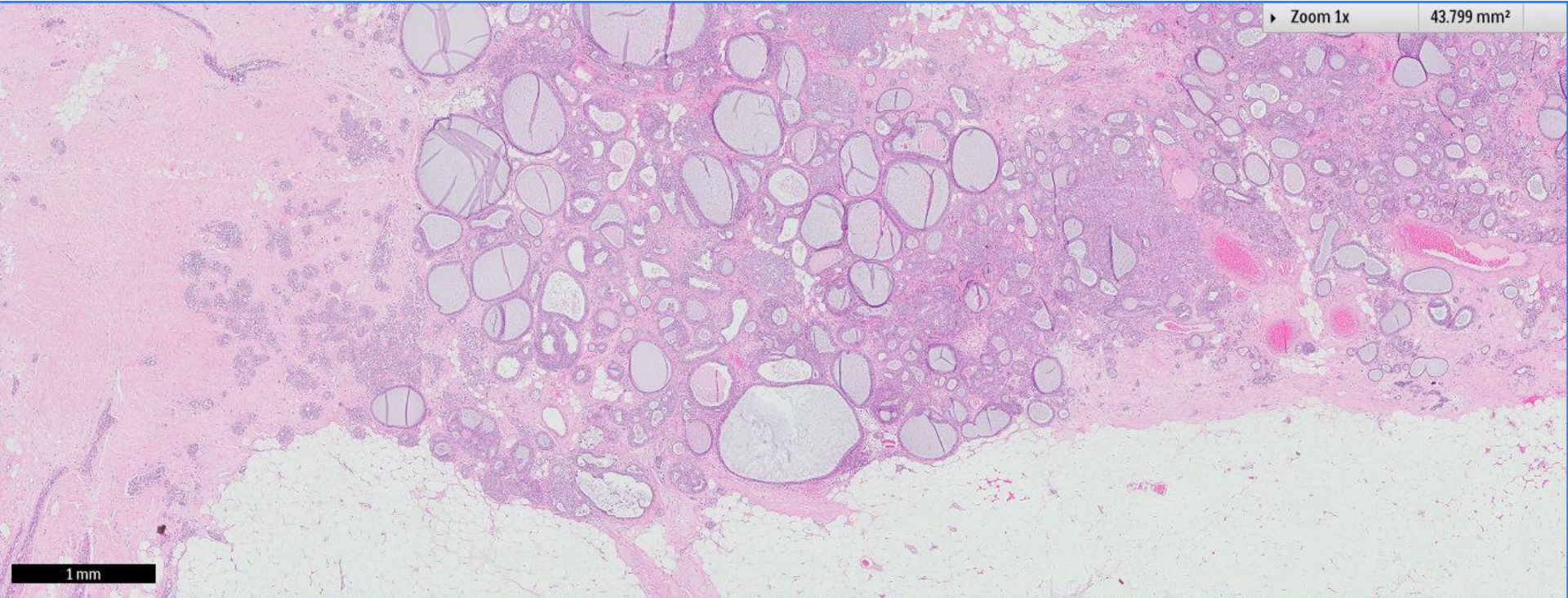


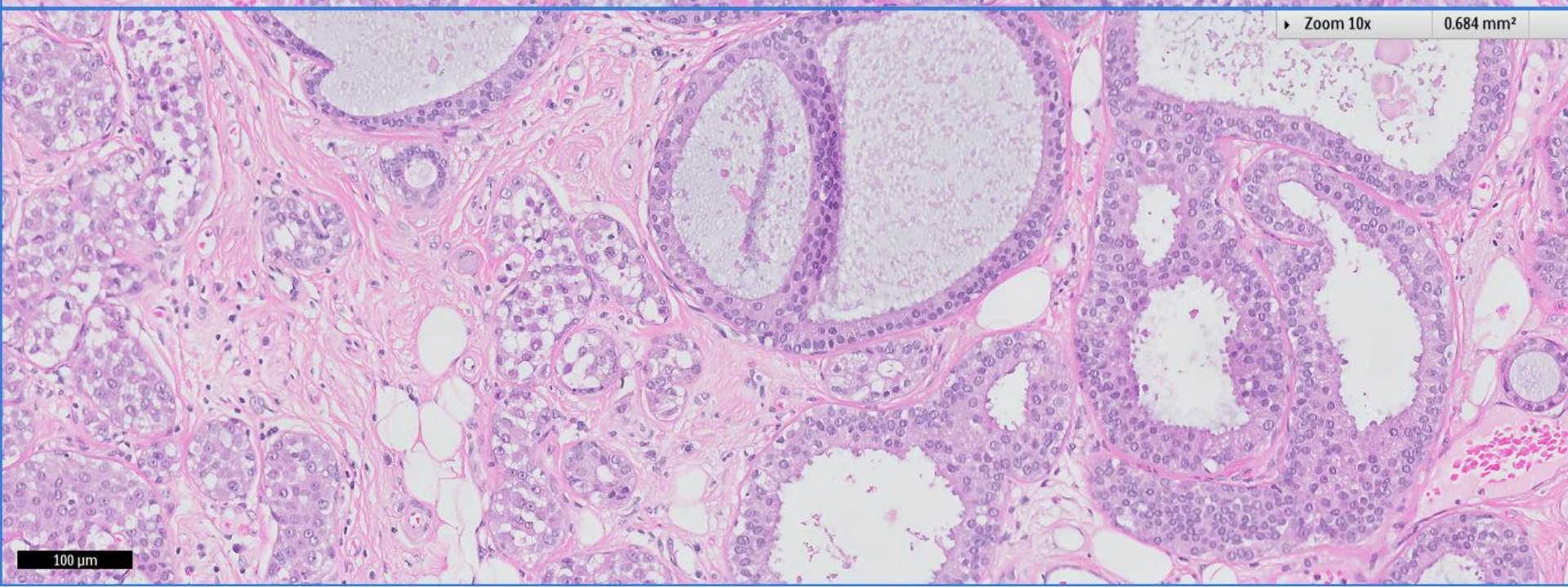
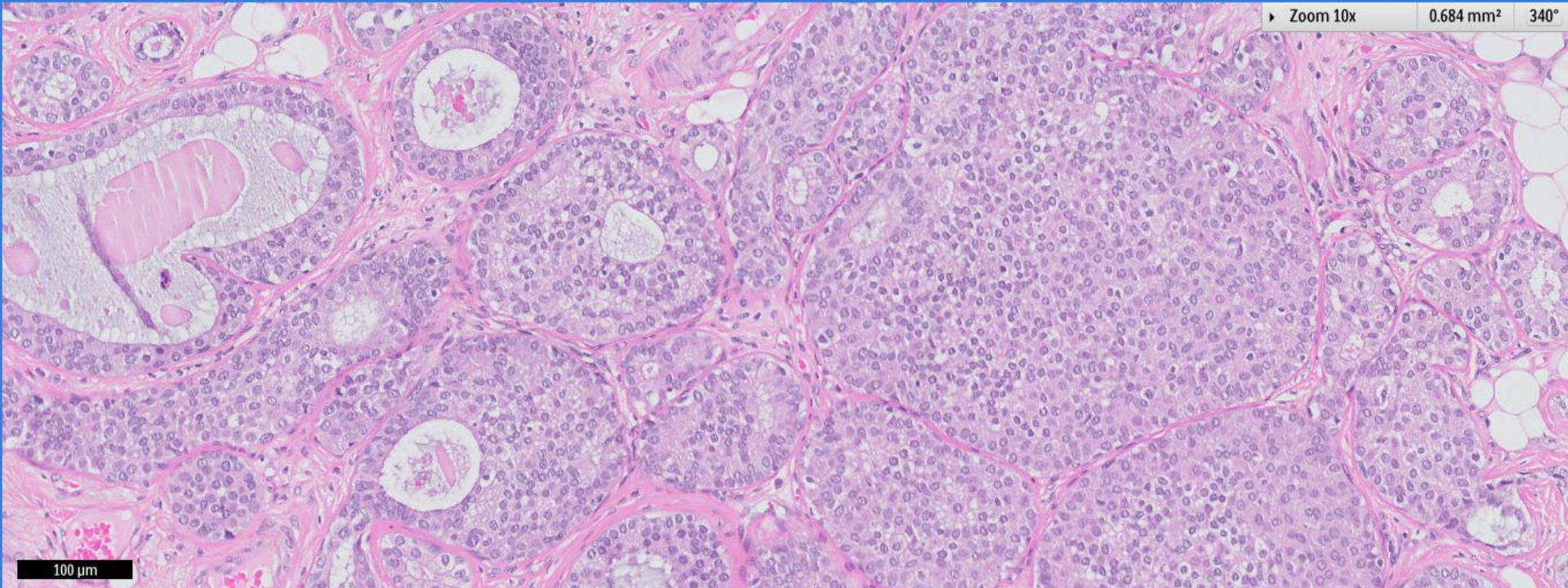


1 mm



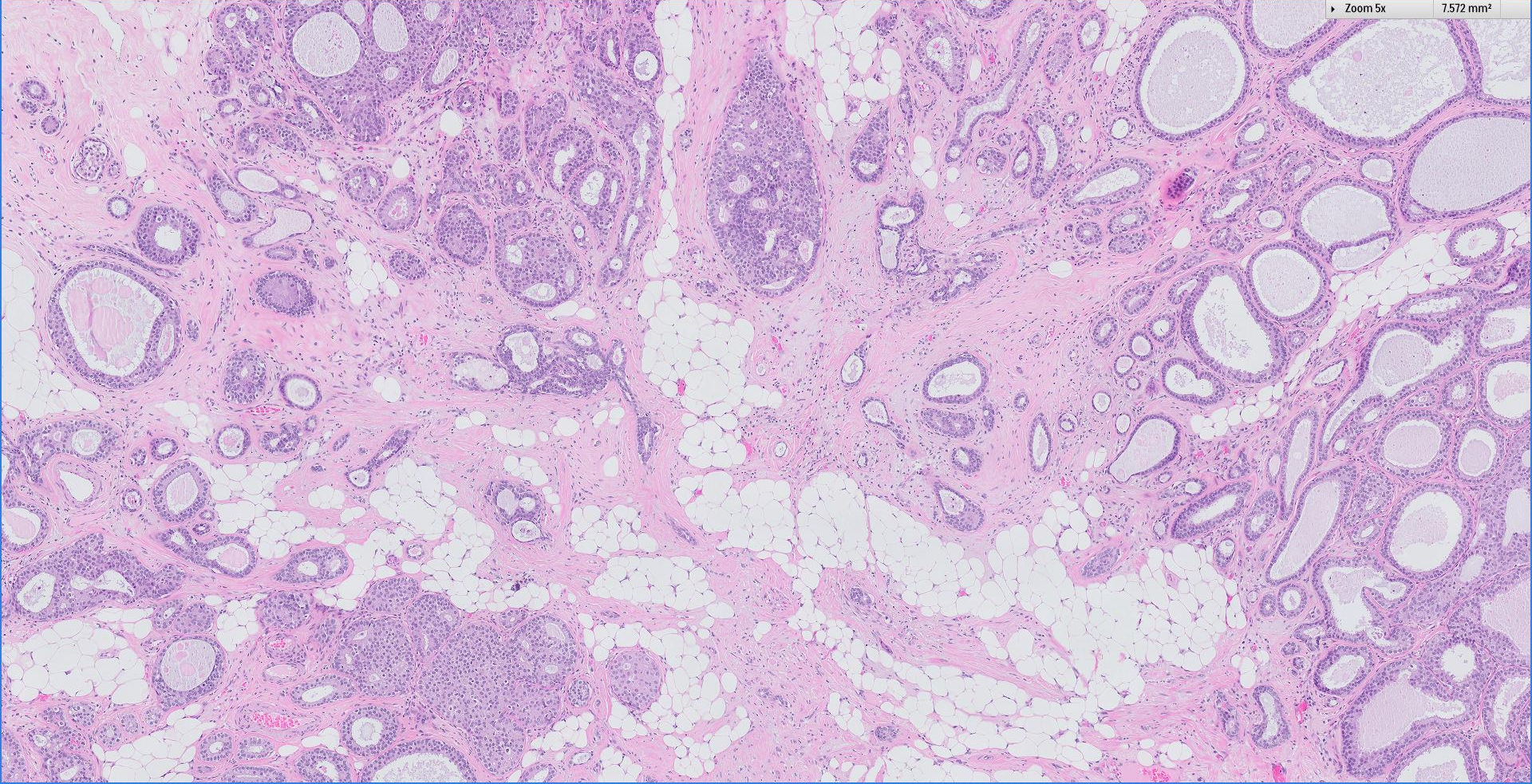
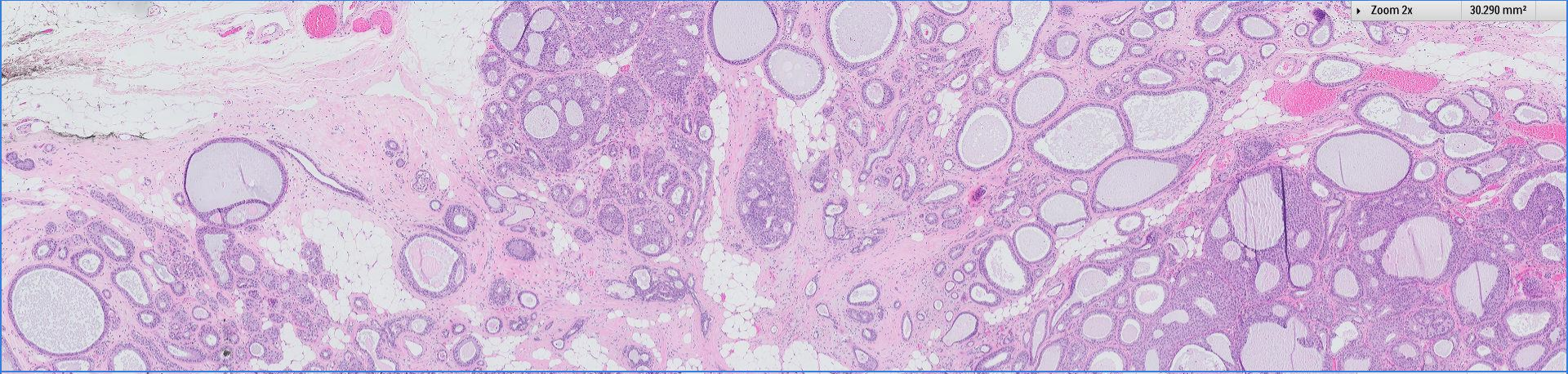
200 μm





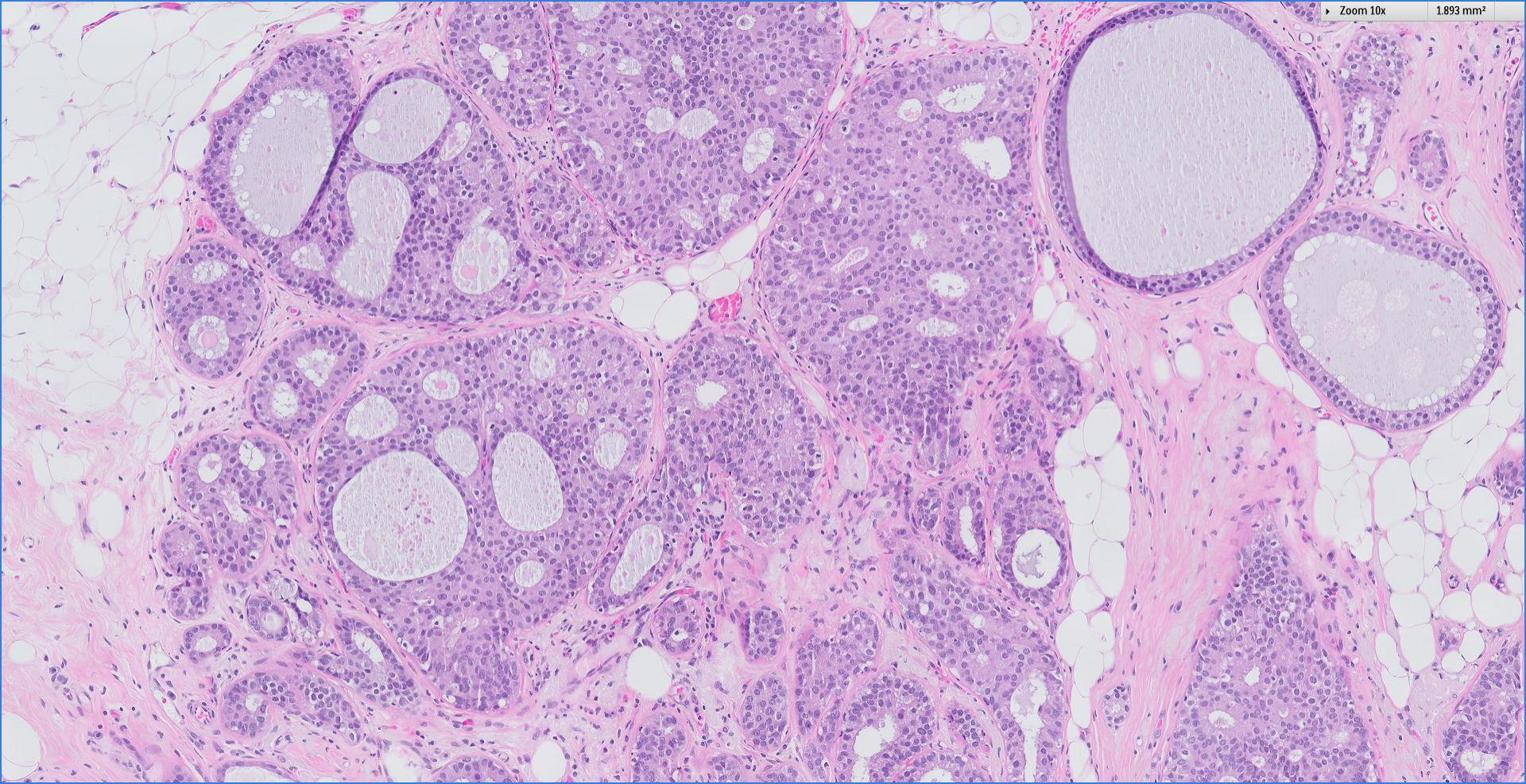
Mini-waterfall, Singapore Botanic Gardens

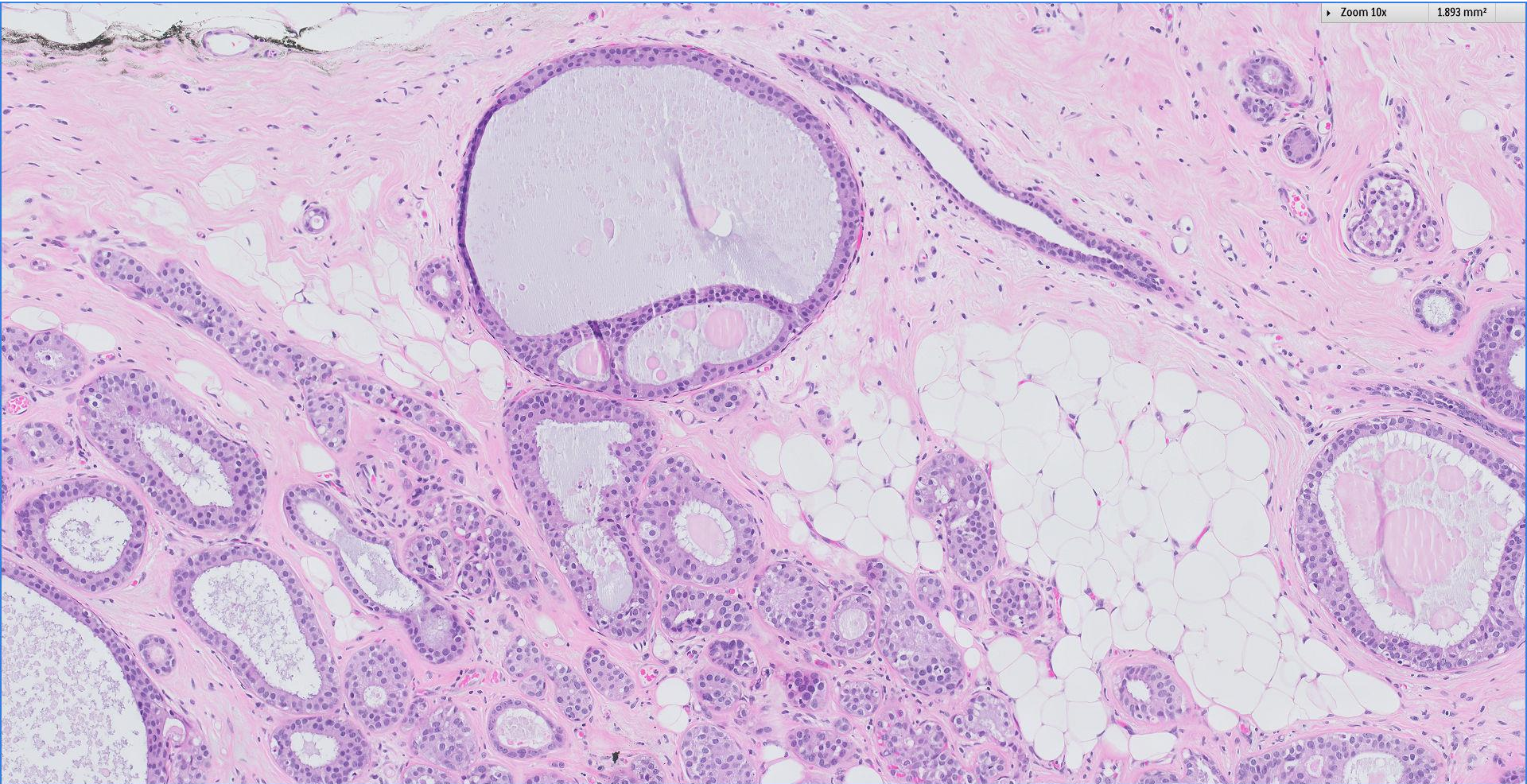




Zoom 10x

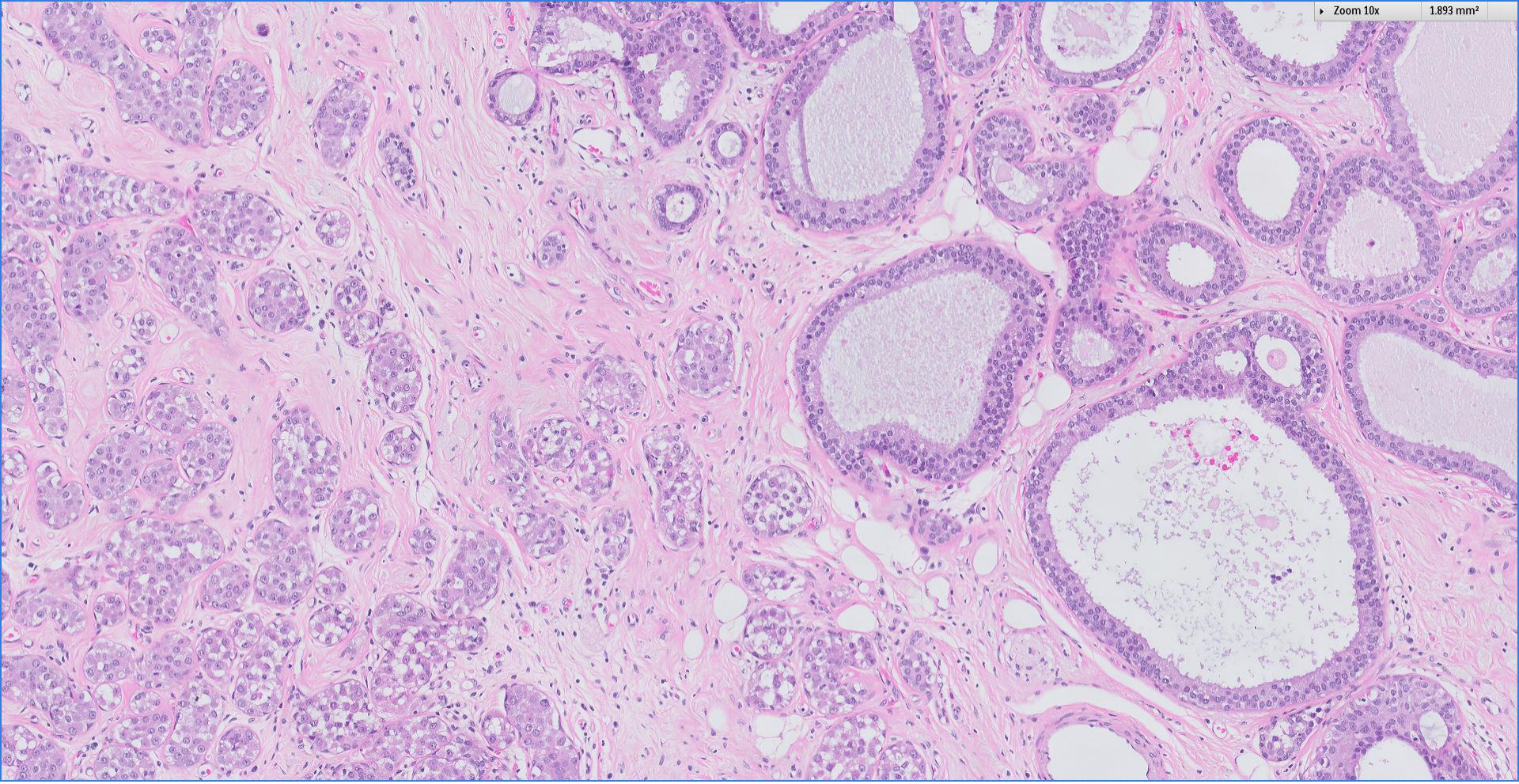
1.893 mm²

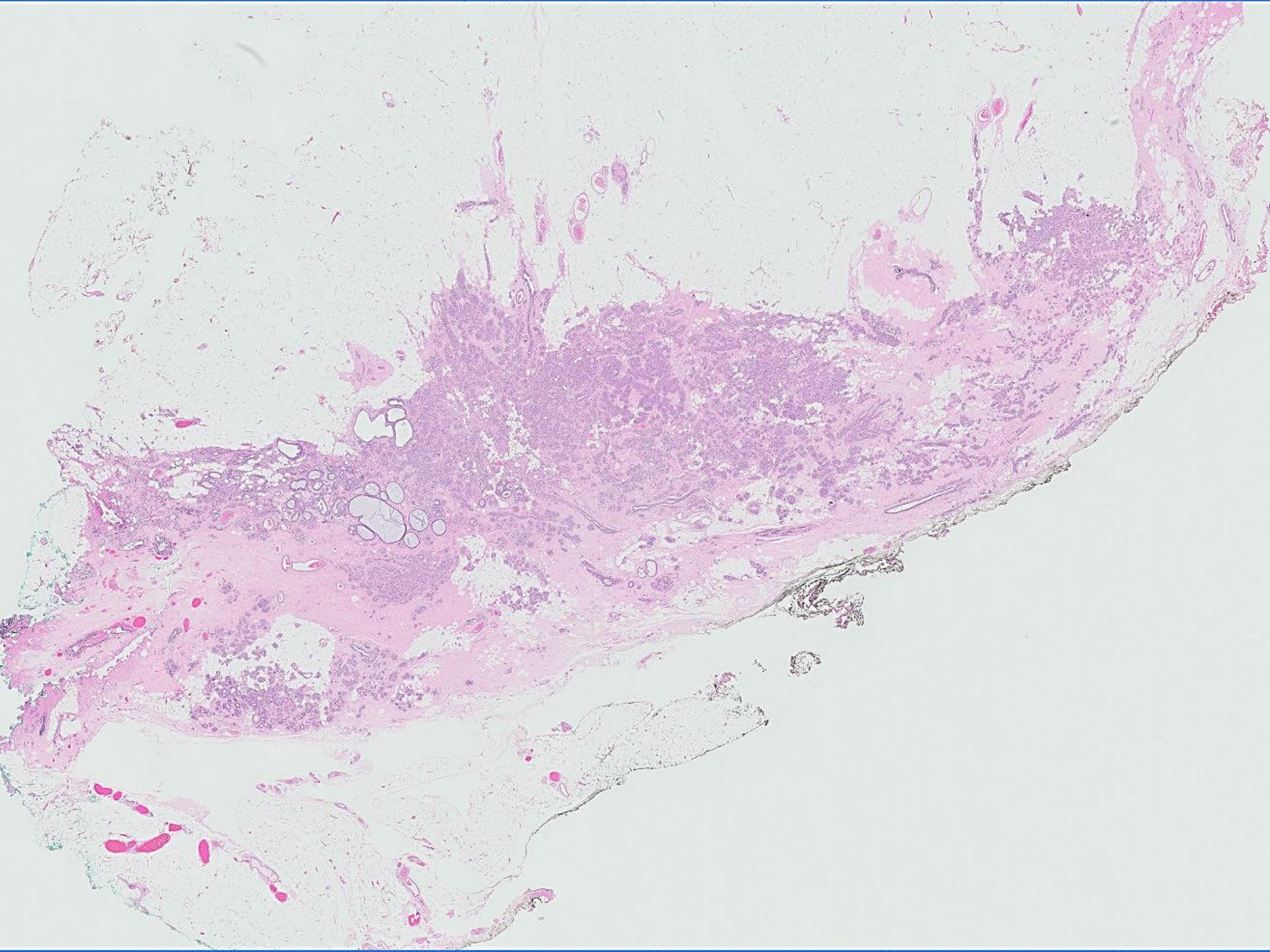


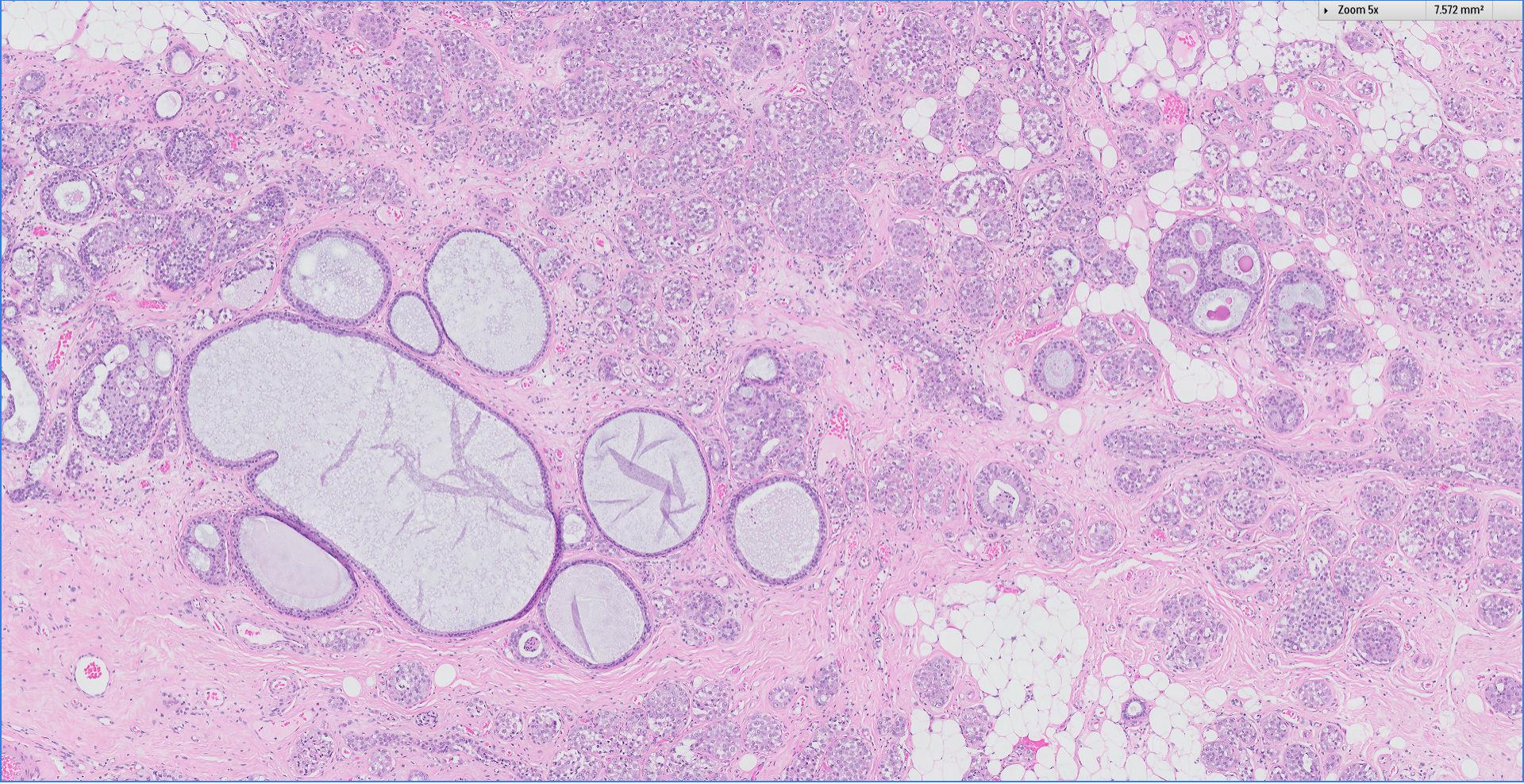


Zoom 10x

1.893 mm²

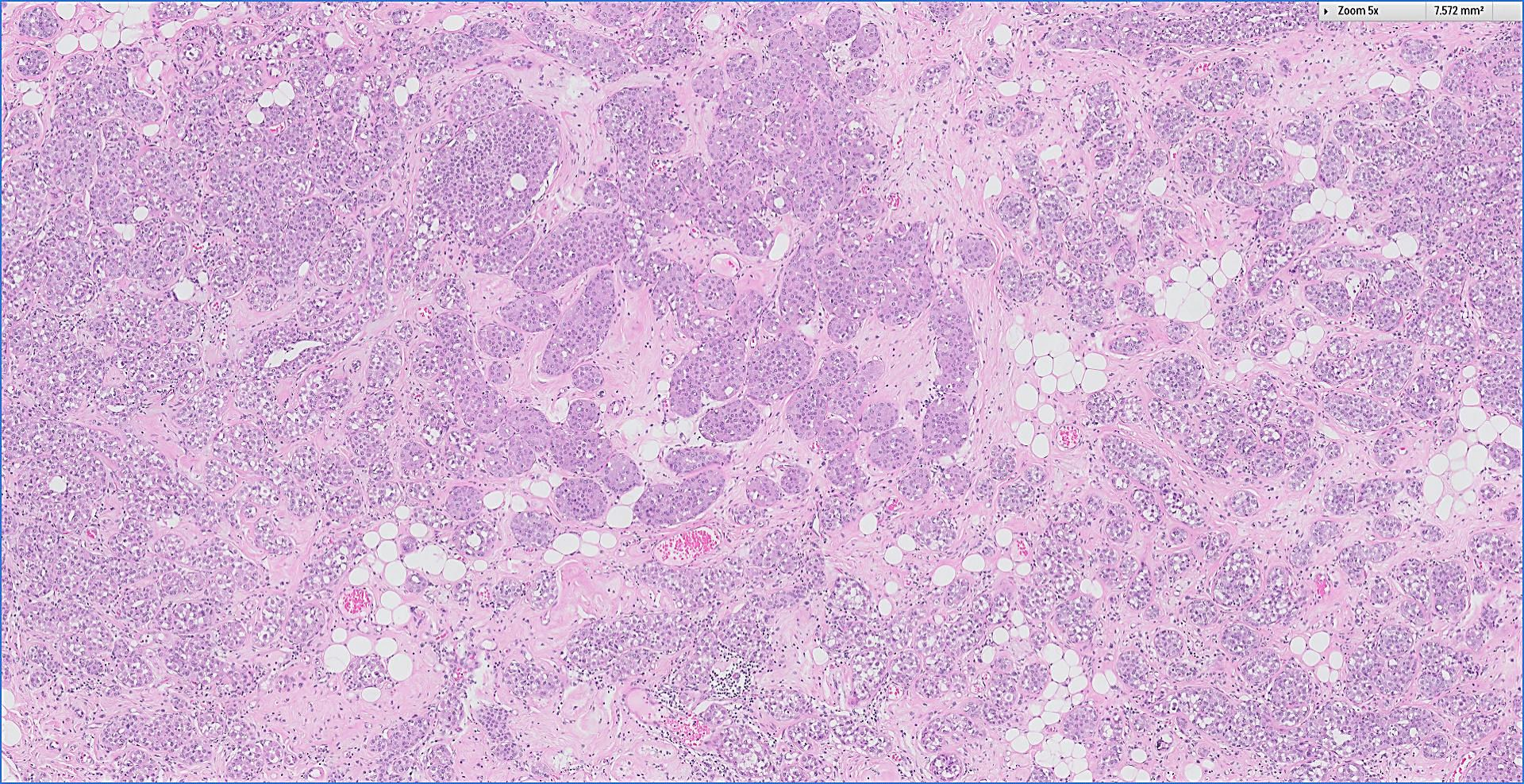






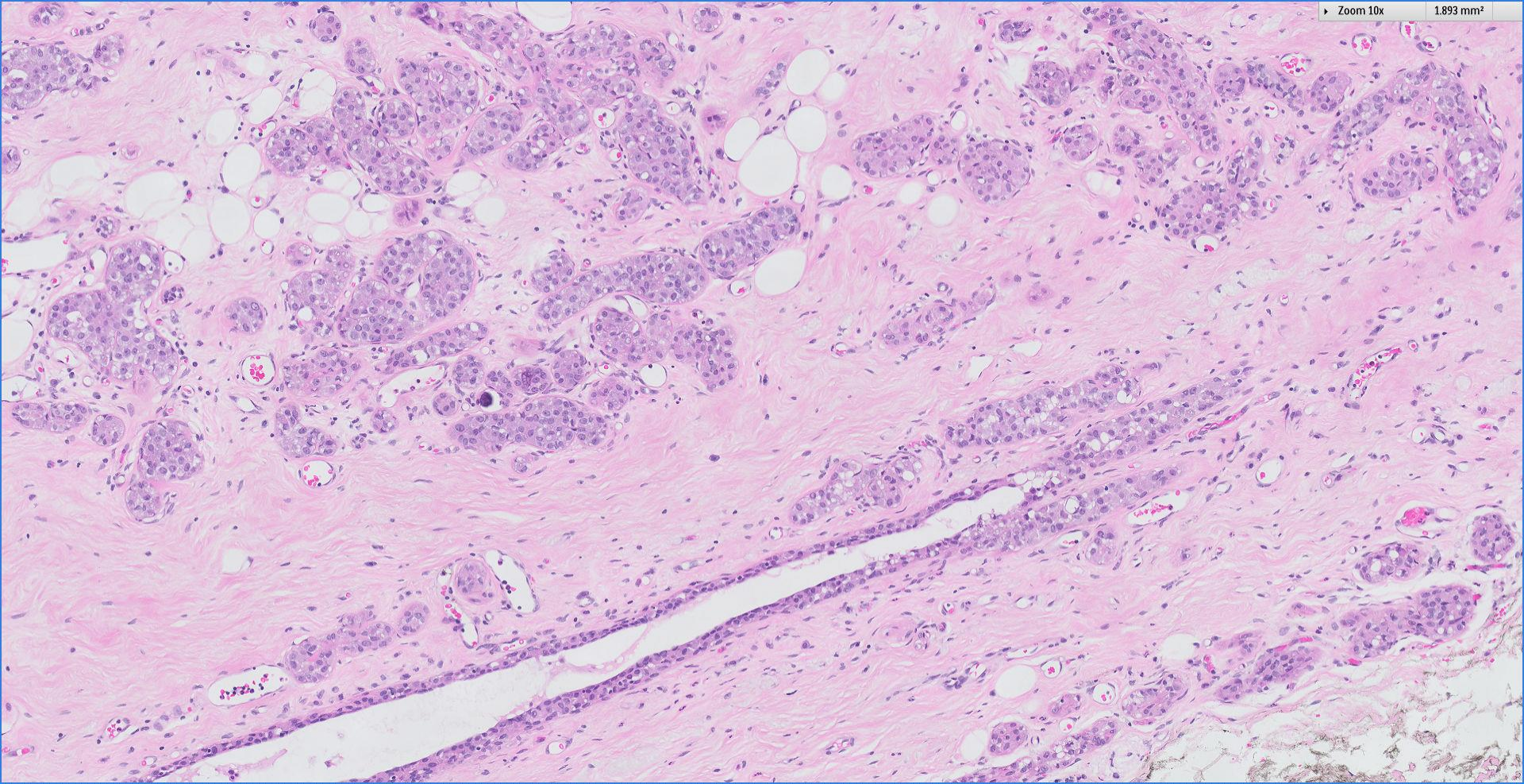
Zoom 5x

7.572 mm²



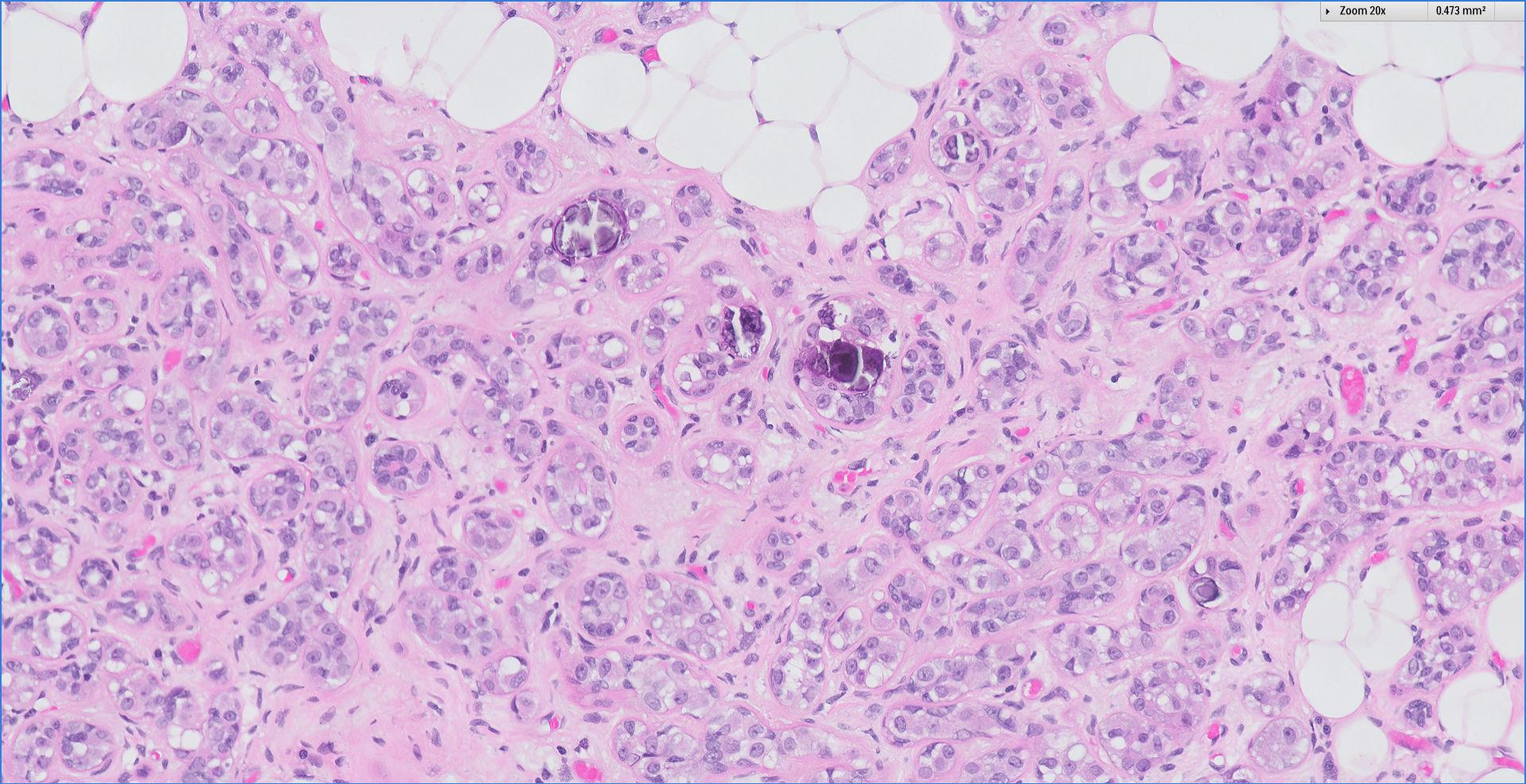
Zoom 10x

1.893 mm²

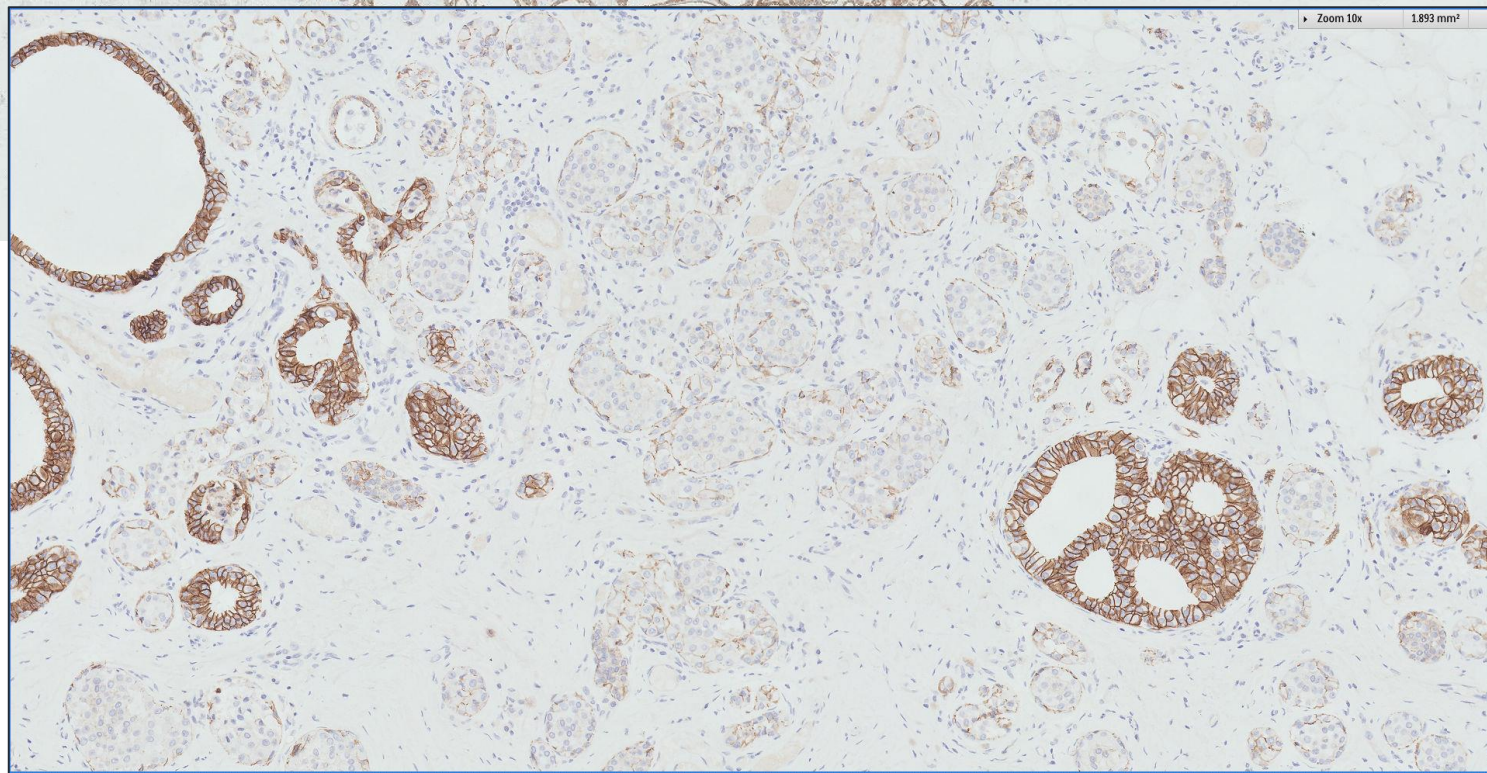
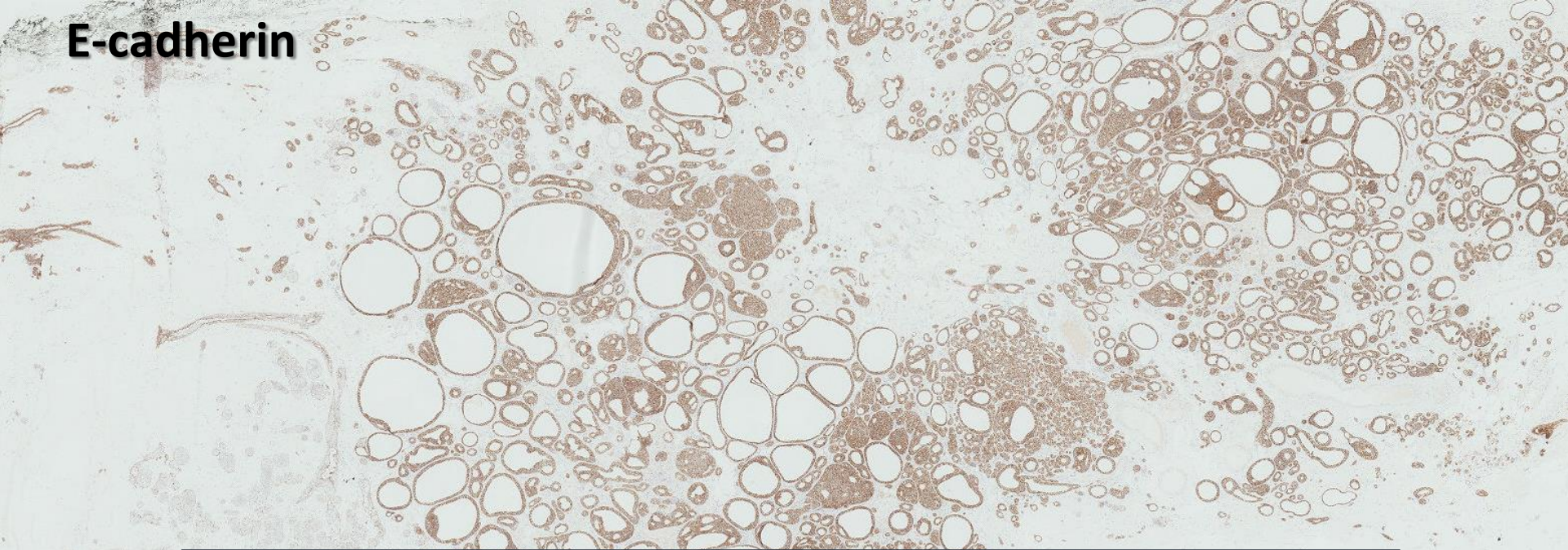


Zoom 20x

0.473 mm²



E-cadherin



Diagnosis

Left breast hookwire localization excision biopsy ~

***Ductal carcinoma in situ, low nuclear grade,
without necrosis***

***Lobular neoplasia (atypical lobular hyperplasia and
lobular carcinoma in situ)***

Radial sclerosing lesion

 Breast
Pathology
Course 2016



Pathology Building 1958-2013, by Ong Kim Seng