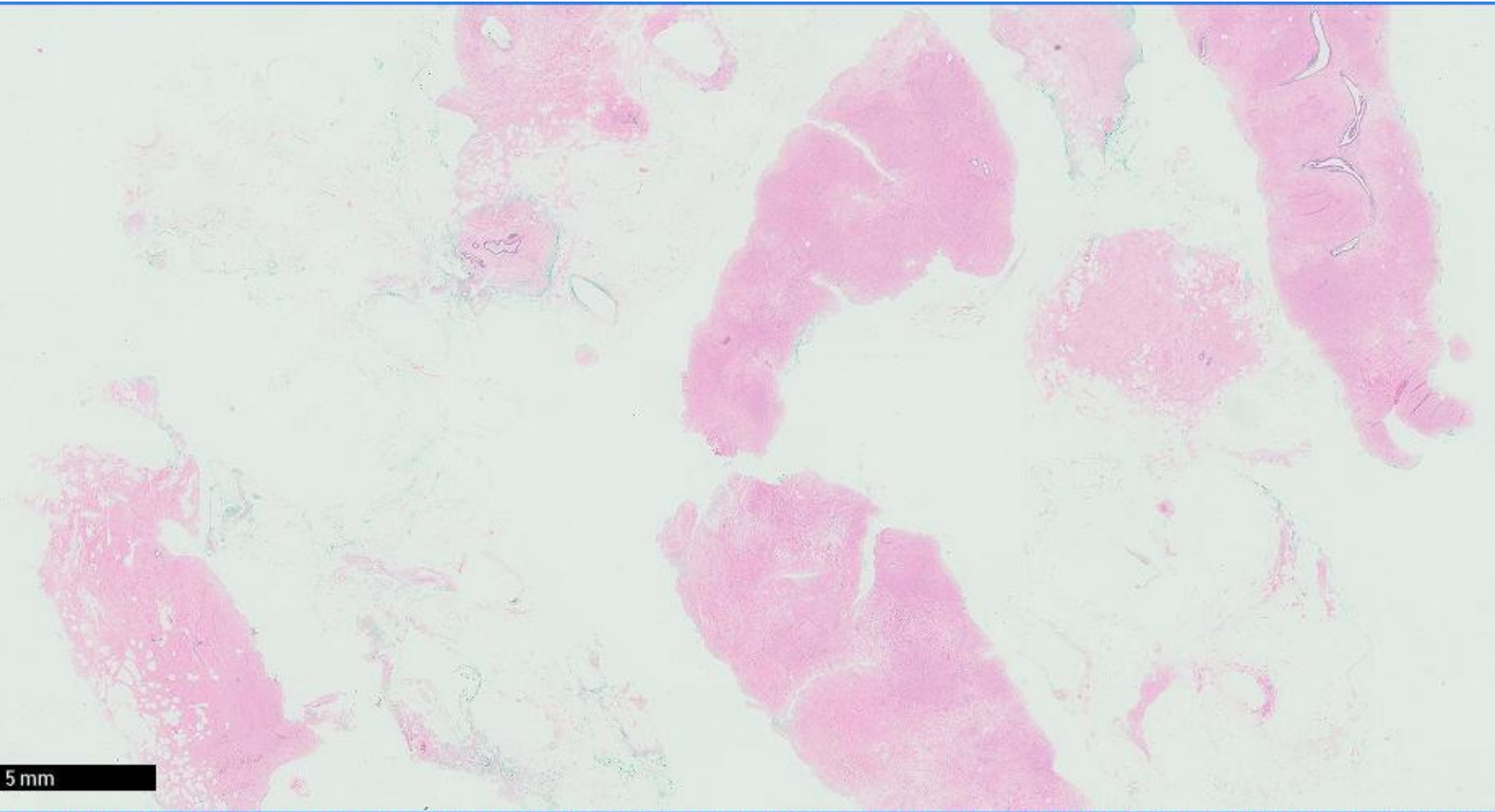
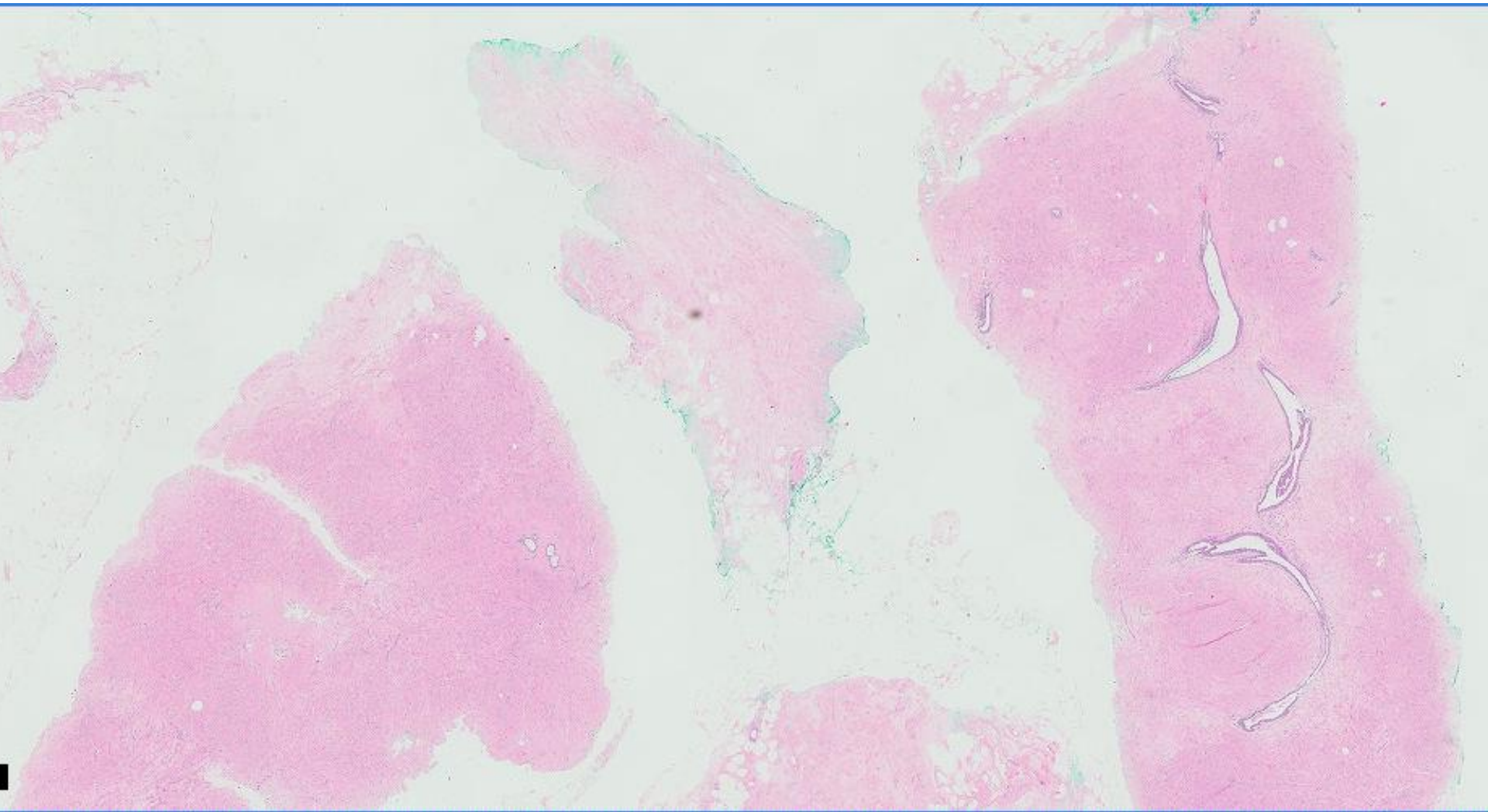
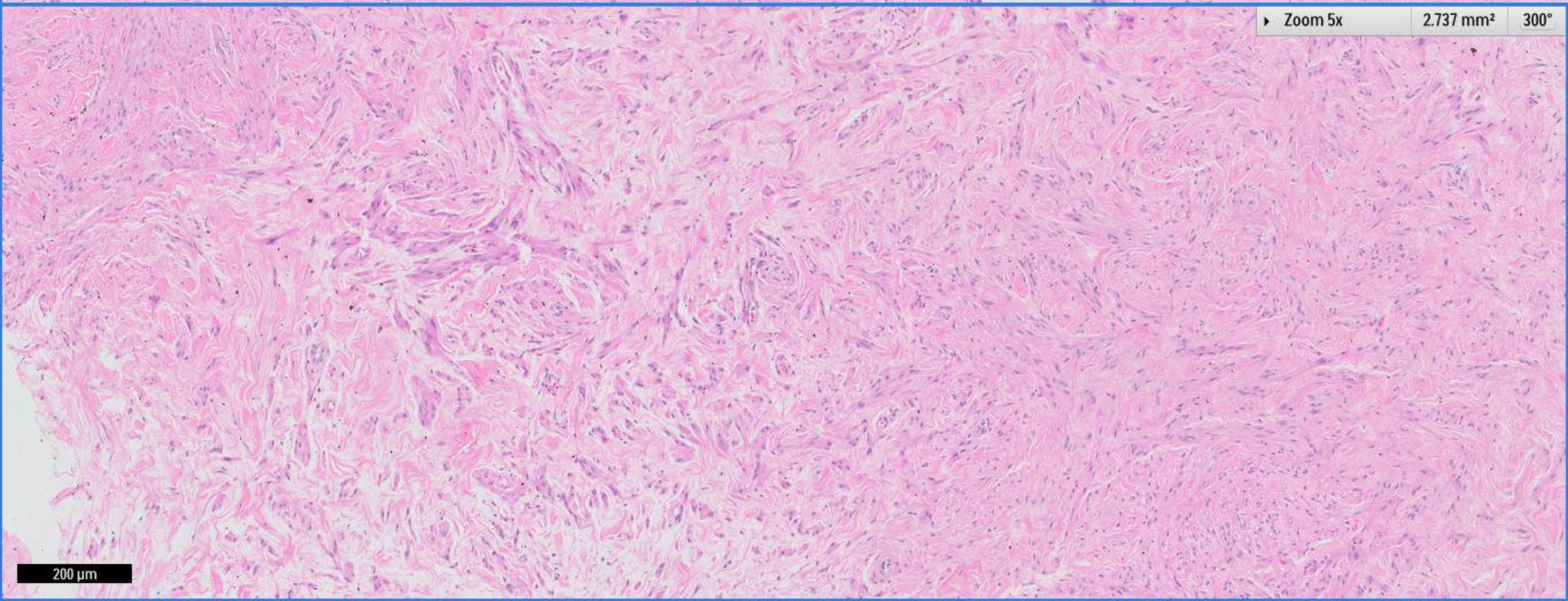
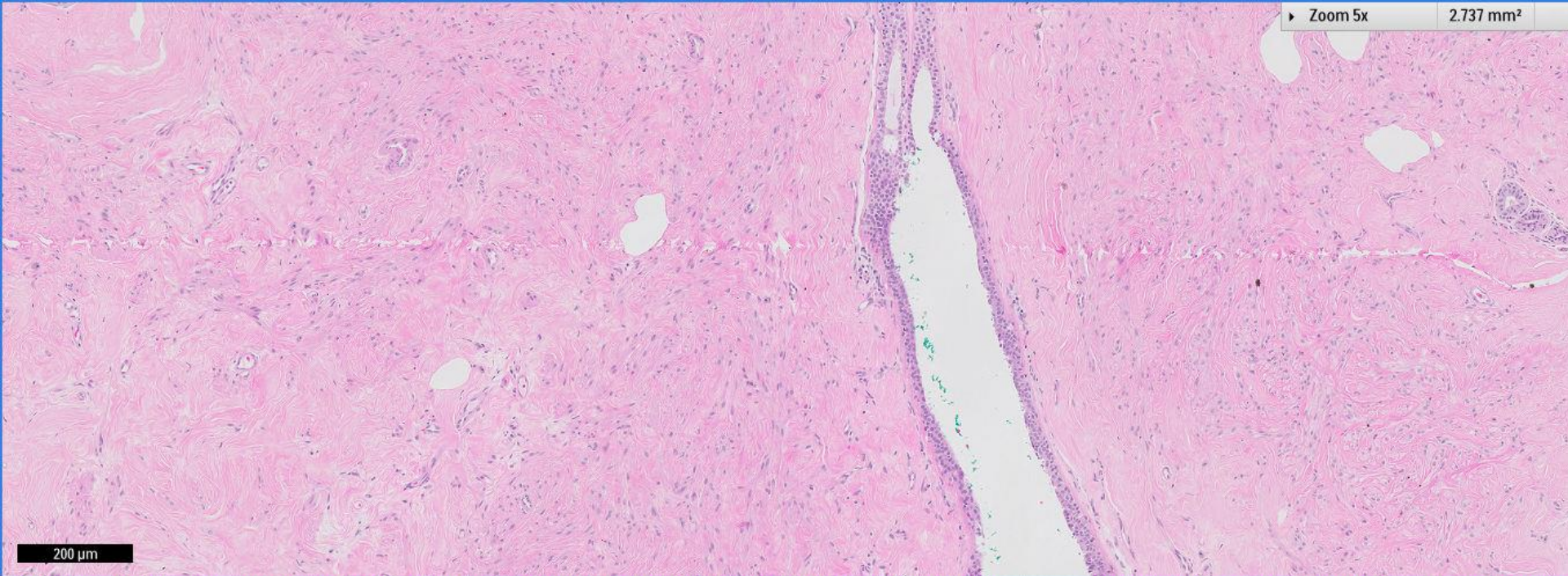


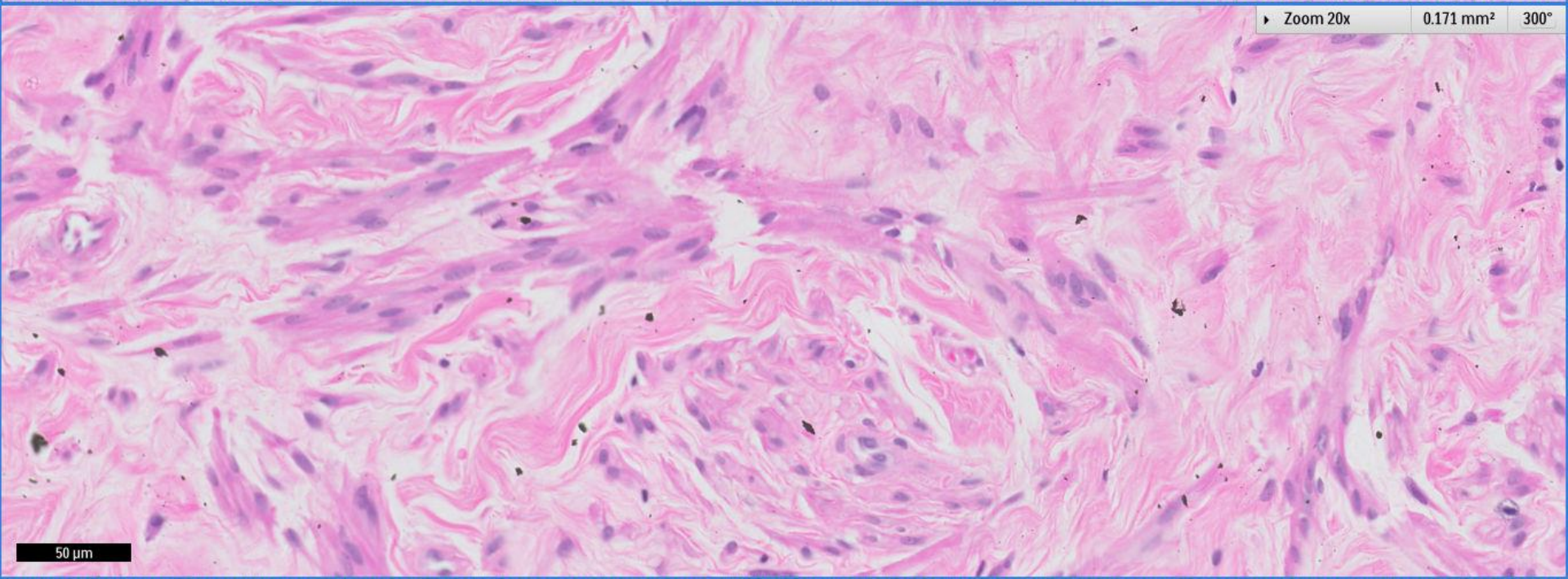
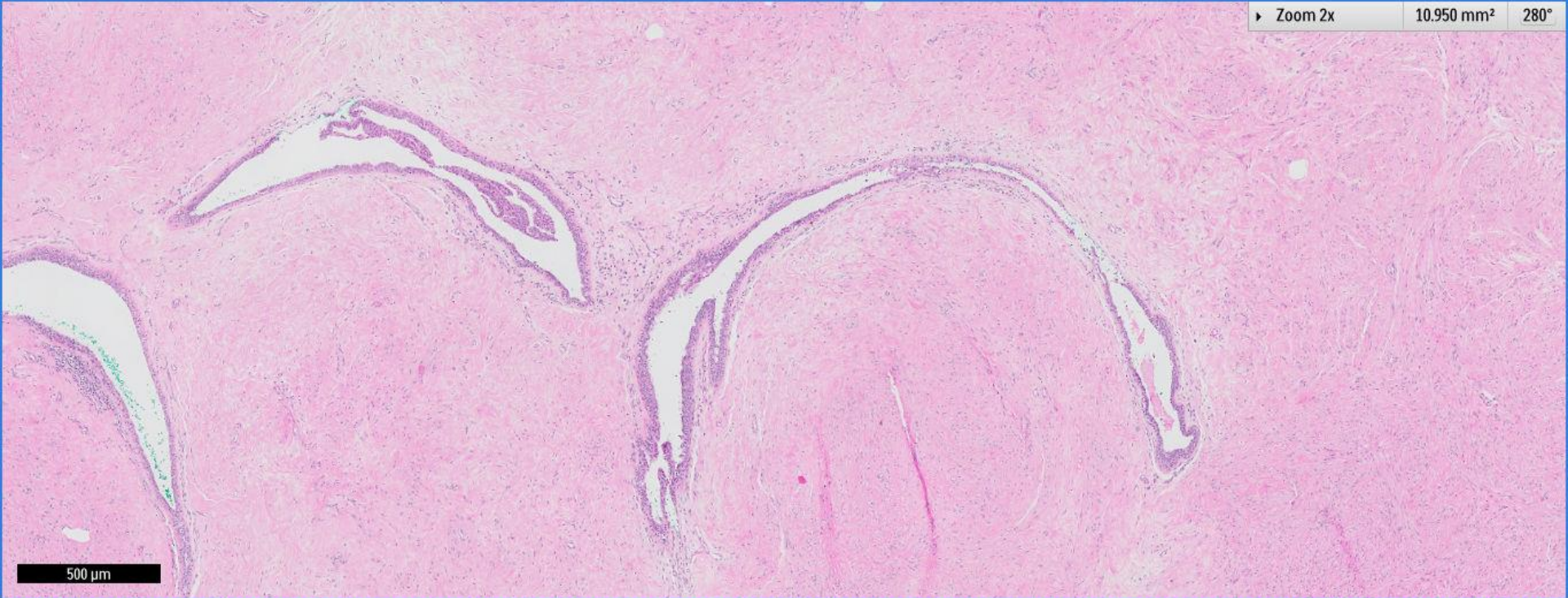
Case 15

56 year old Indian woman with a right breast lump at 10 o'clock.
Vacuum assisted excision biopsy.

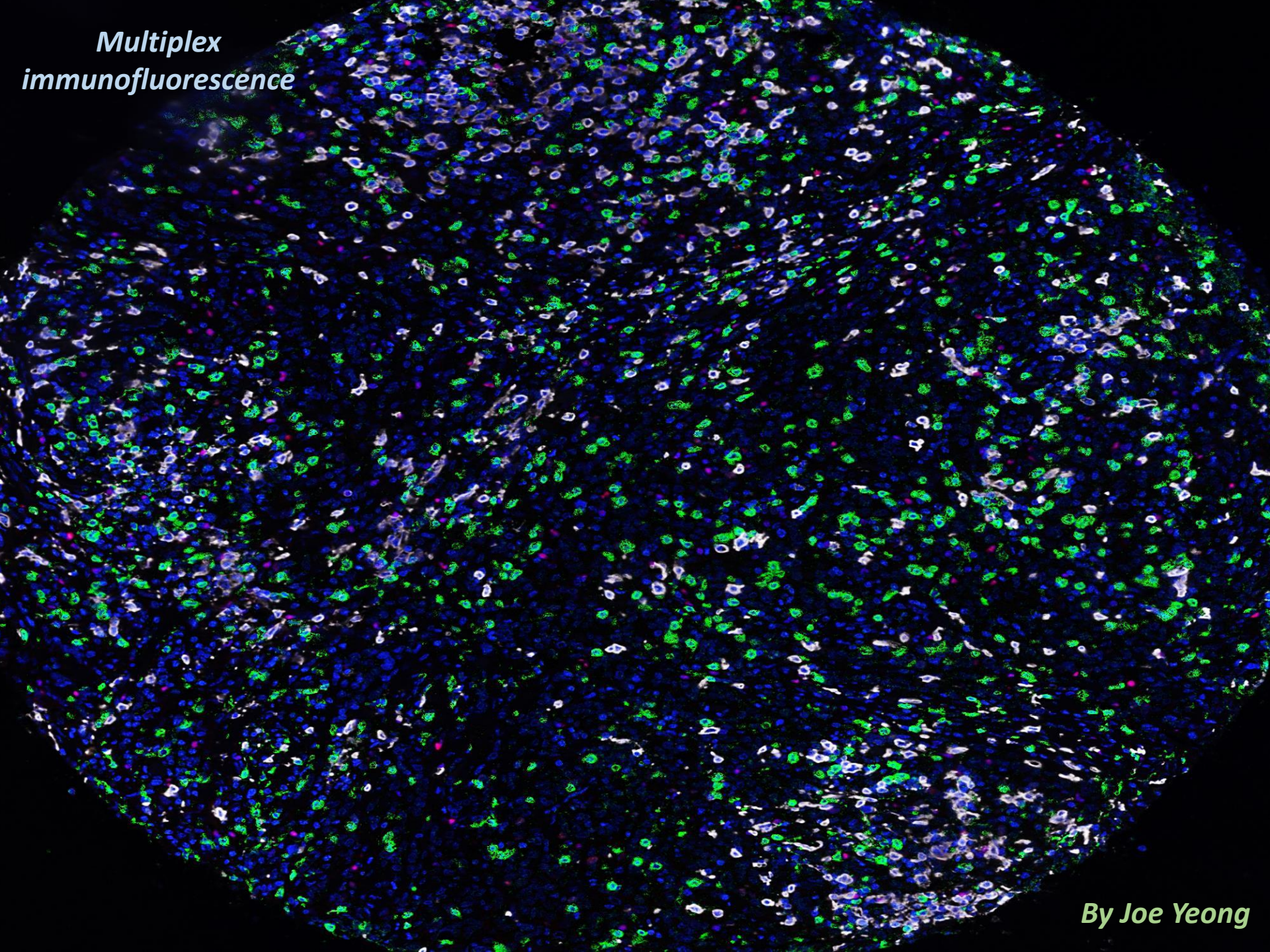






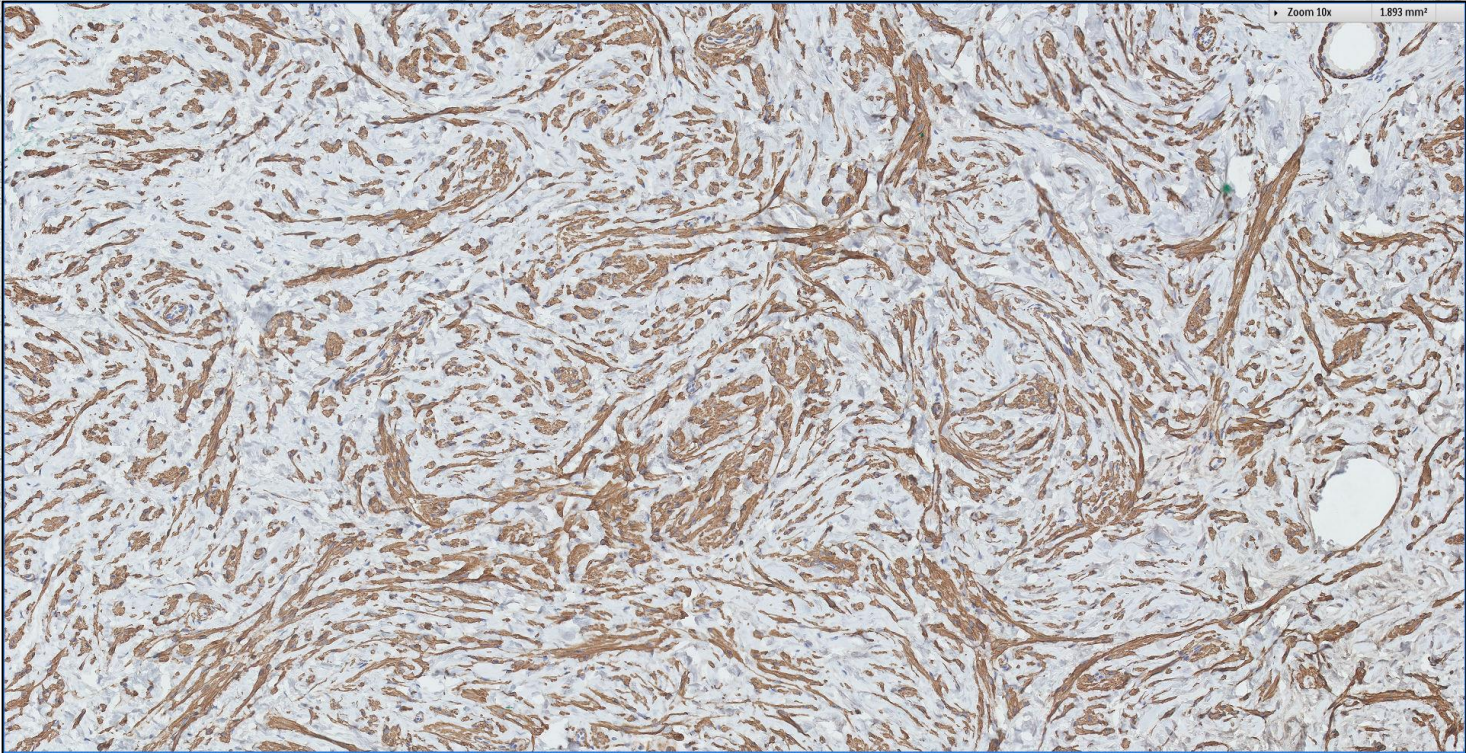


*Multiplex
immunofluorescence*



By Joe Yeong

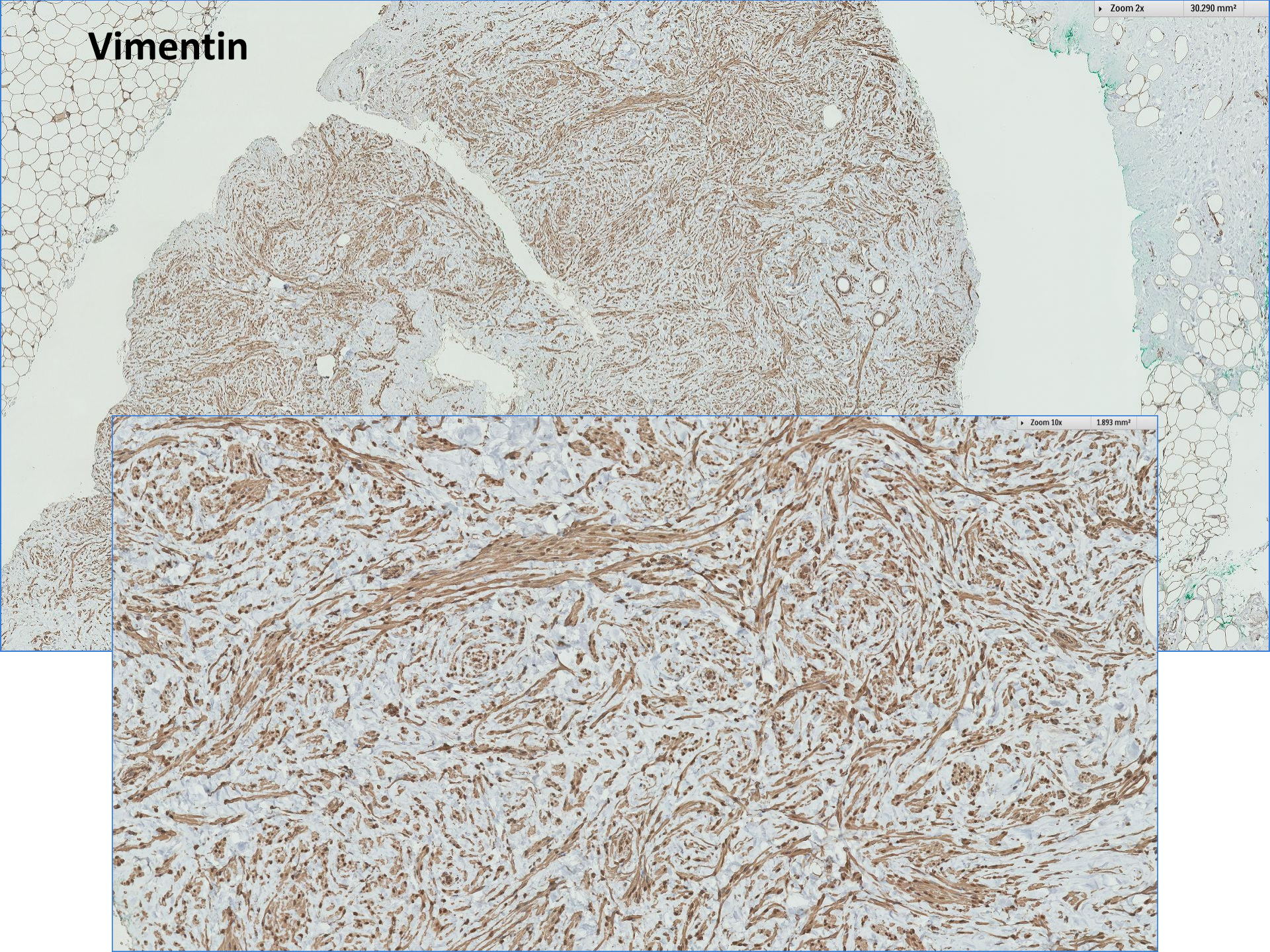
SMA



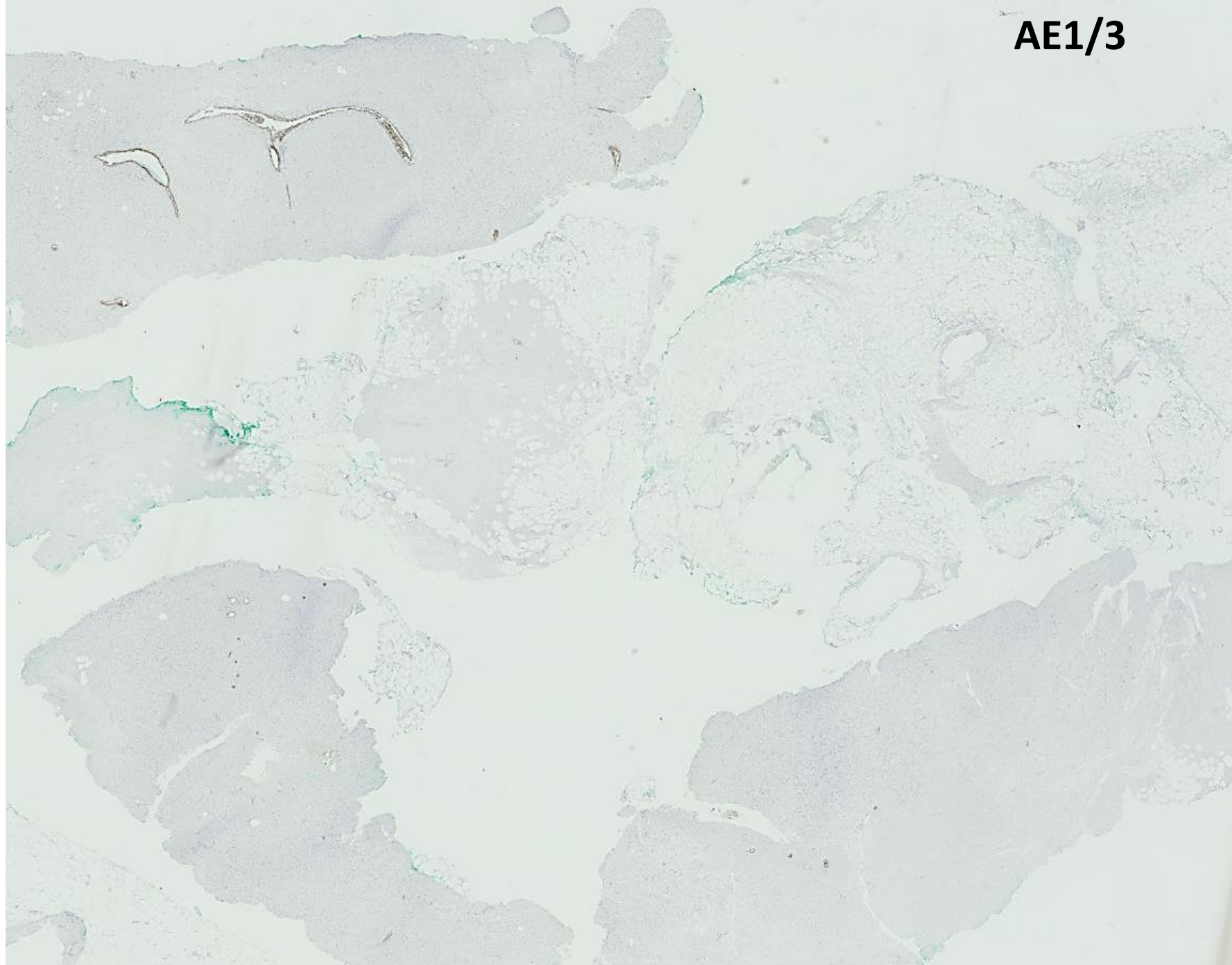
Vimentin

Zoom 2x 30.290 mm²

Zoom 10x 1.893 mm²



AE1/3



Diagnosis


Right breast lump 10 o'clock vacuum assisted excision biopsy ~

Fibroadenoma with stromal myoid metaplasia

Fibroadenoma ~ stromal changes

- Cellular ~ cellular fibroadenoma, juvenile fibroadenoma.
- Stromal multinucleated giant cells.
- Myxoid stroma ~ myxoid fibroadenoma (may be associated with Carney's complex with myxoid neoplasms and pigmented skin lesions)
- Hyalinisation and sclerosis.
- Stromal calcifications ~ radiological detection.
- Lipomatous, **smooth muscle**, osteochondroid metaplasia.
- Pseudoangiomatous stromal hyperplasia.
- Stromal mitoses, especially in young or pregnant patients.
- Infarction.

 Breast
Pathology
Course 2016



Pathology Building 1958-2013, by Ong Kim Seng