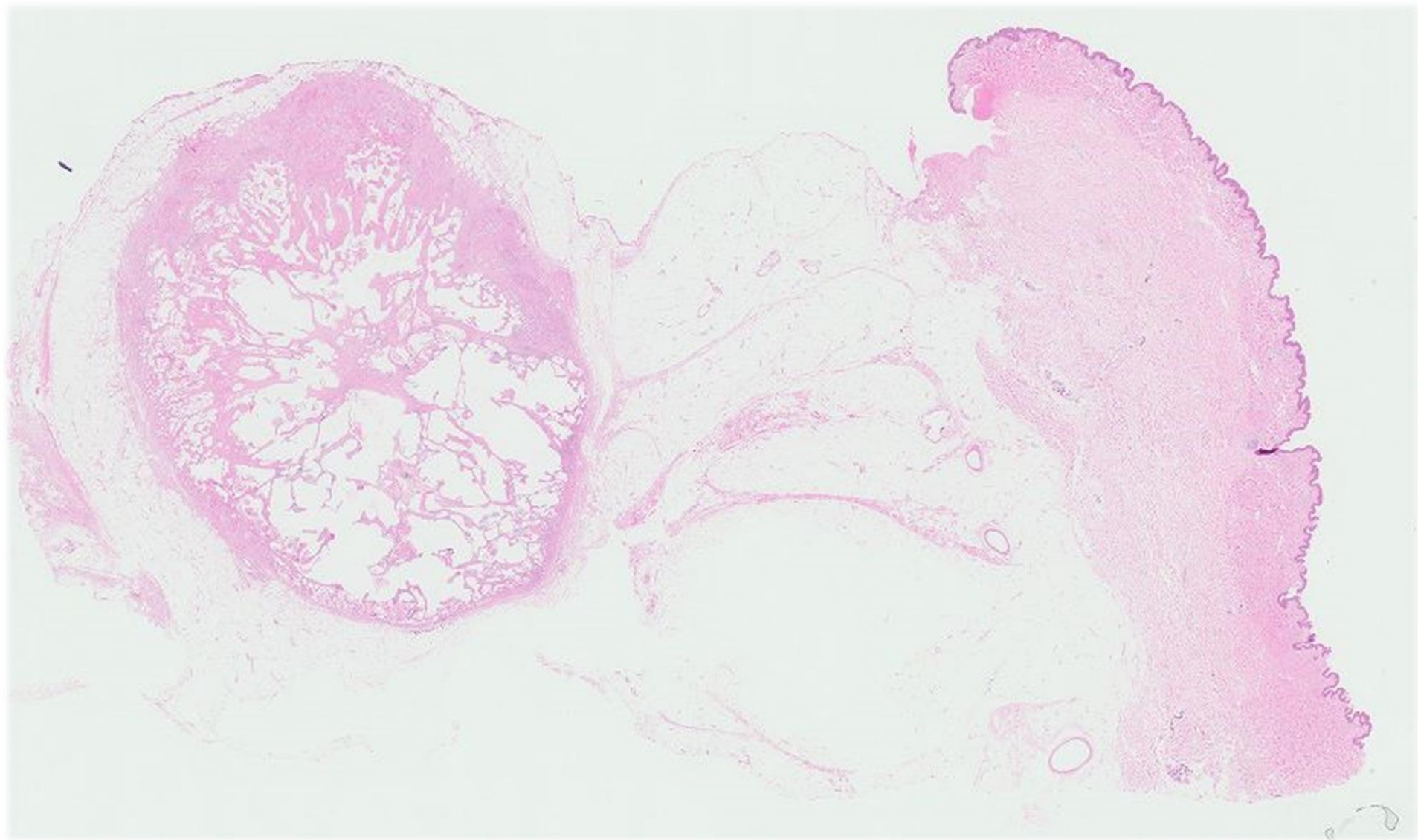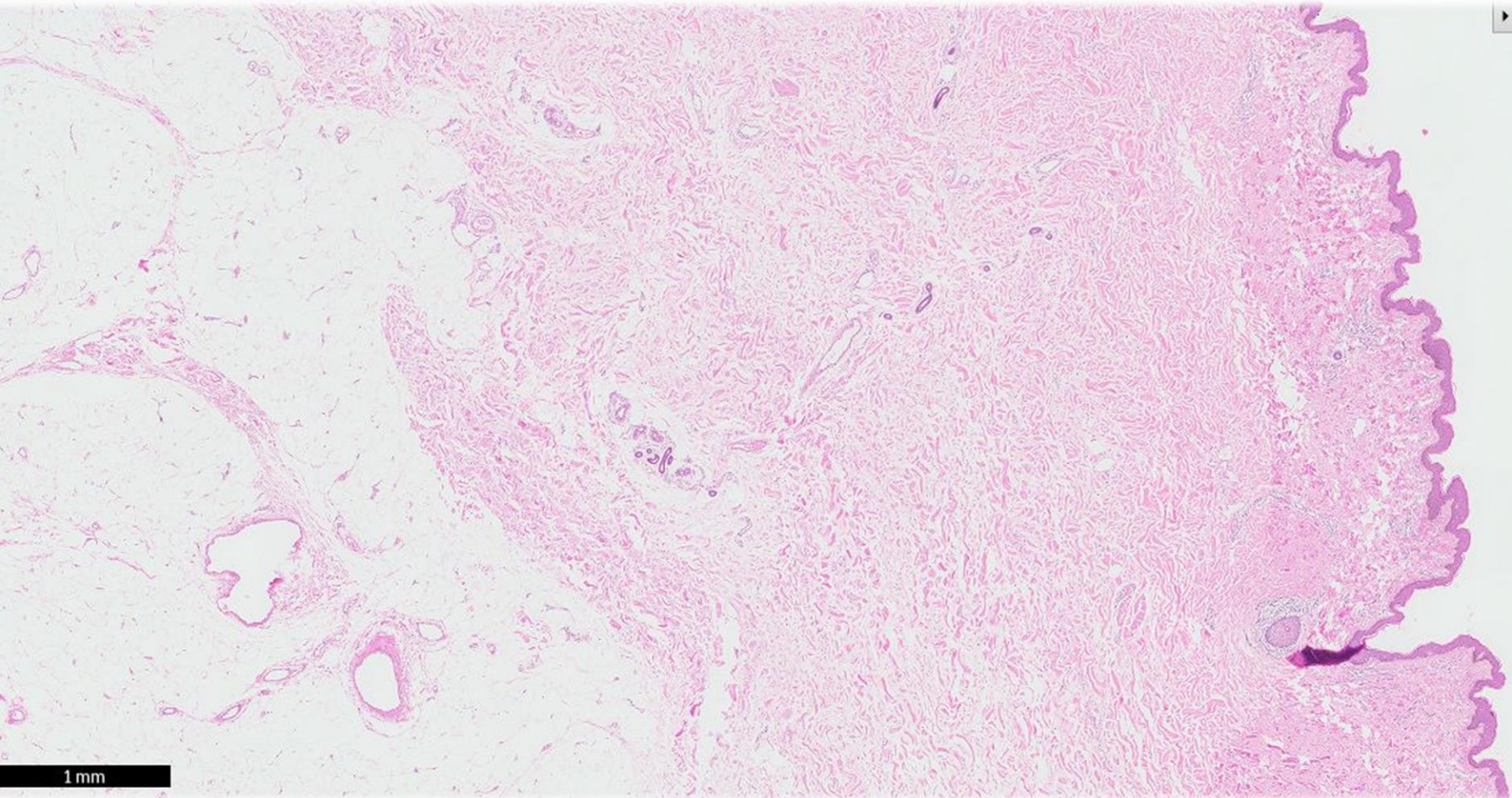


Case 18

61 year old lady with chronic and persistent left breast enlargement opted for a left mastectomy.



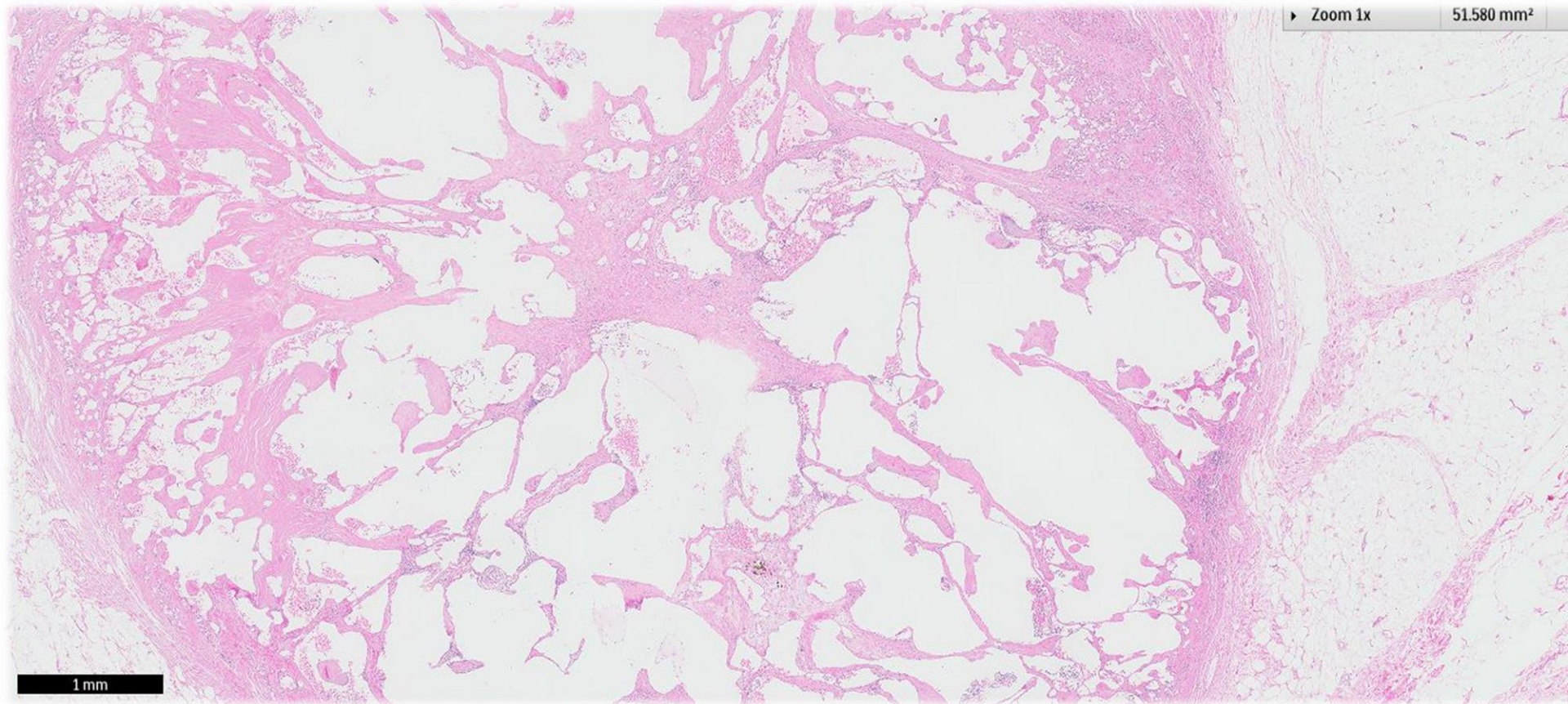




1 mm

▶ Zoom 1x

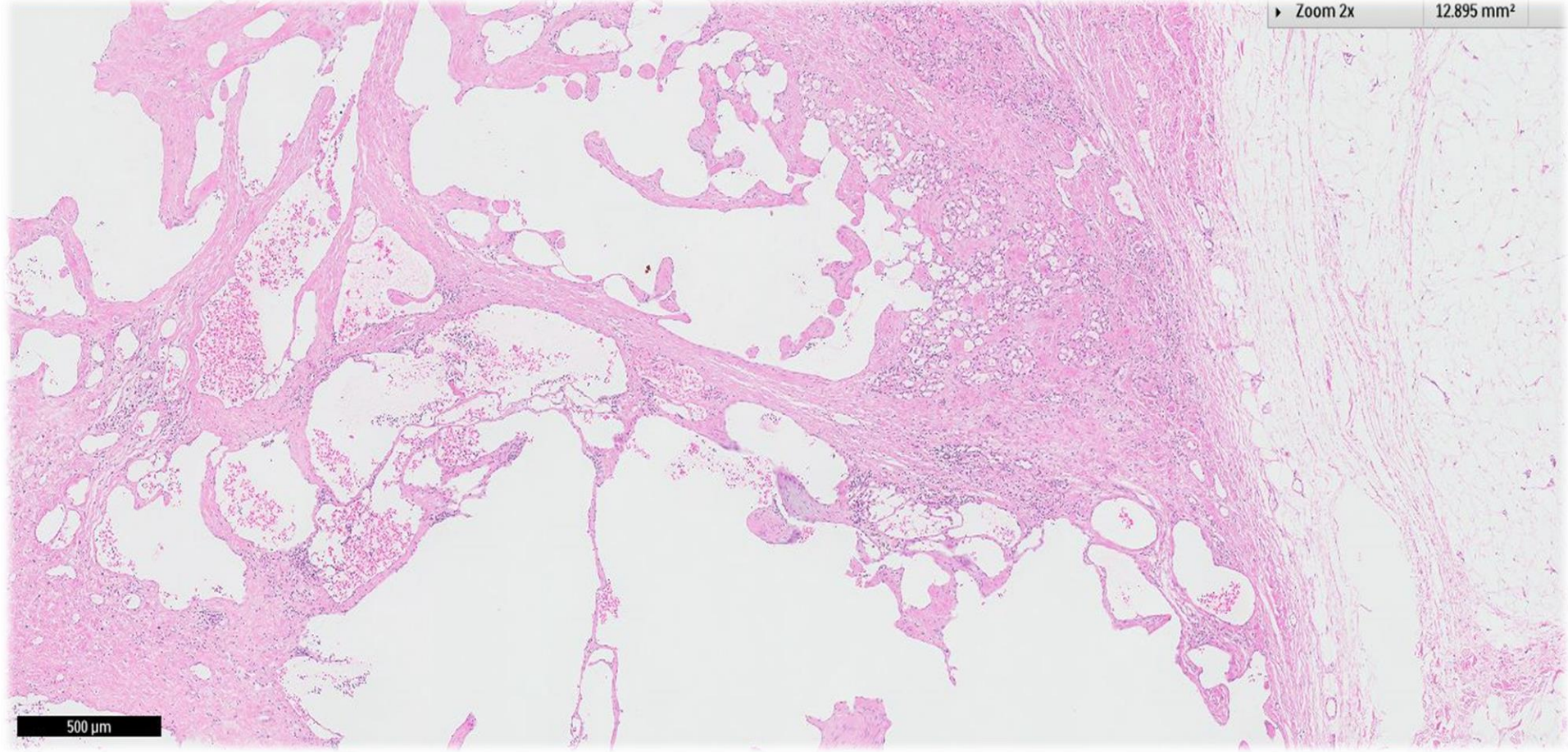
51.580 mm²



1 mm

Zoom 2x

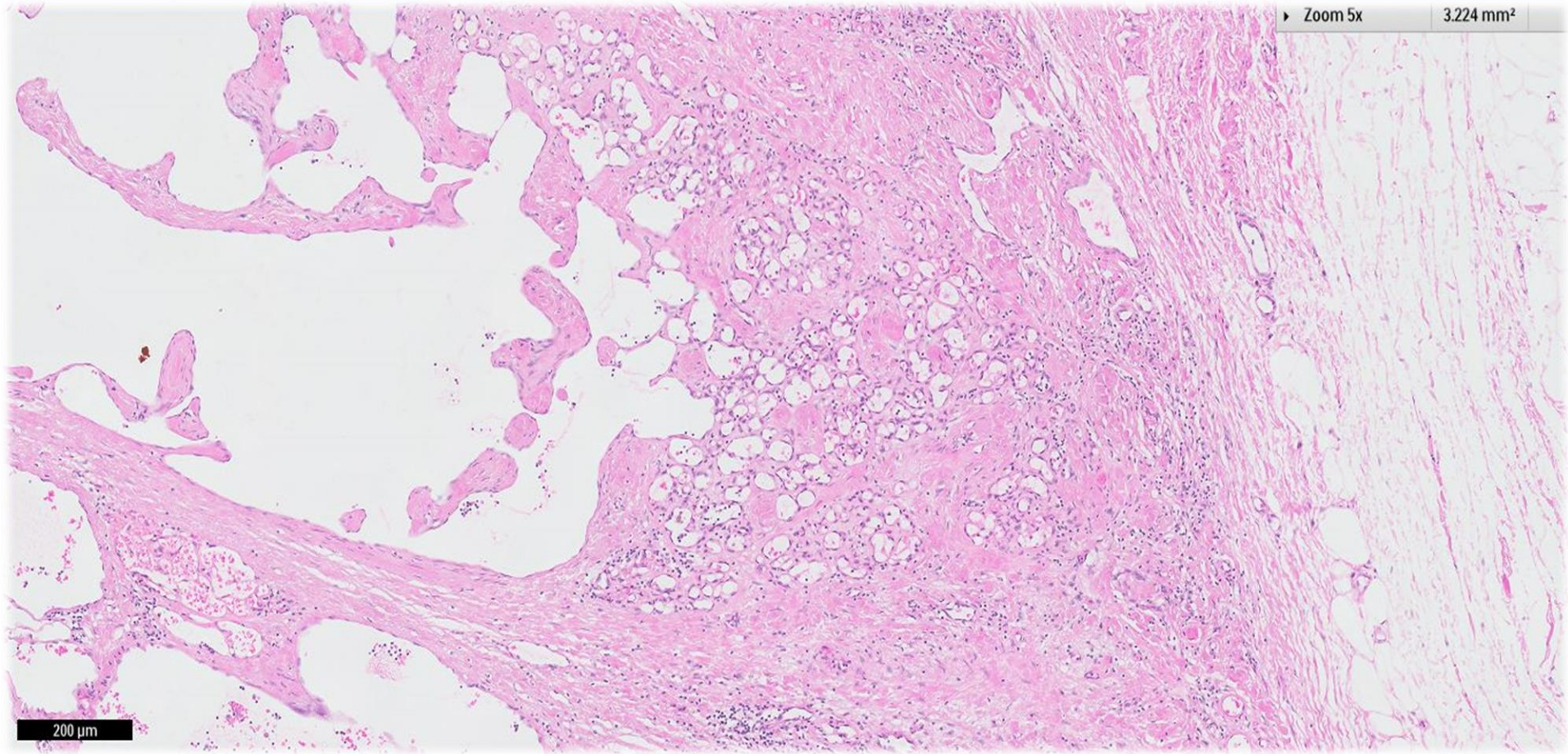
12.895 mm²



500 μ m

▶ Zoom 5x

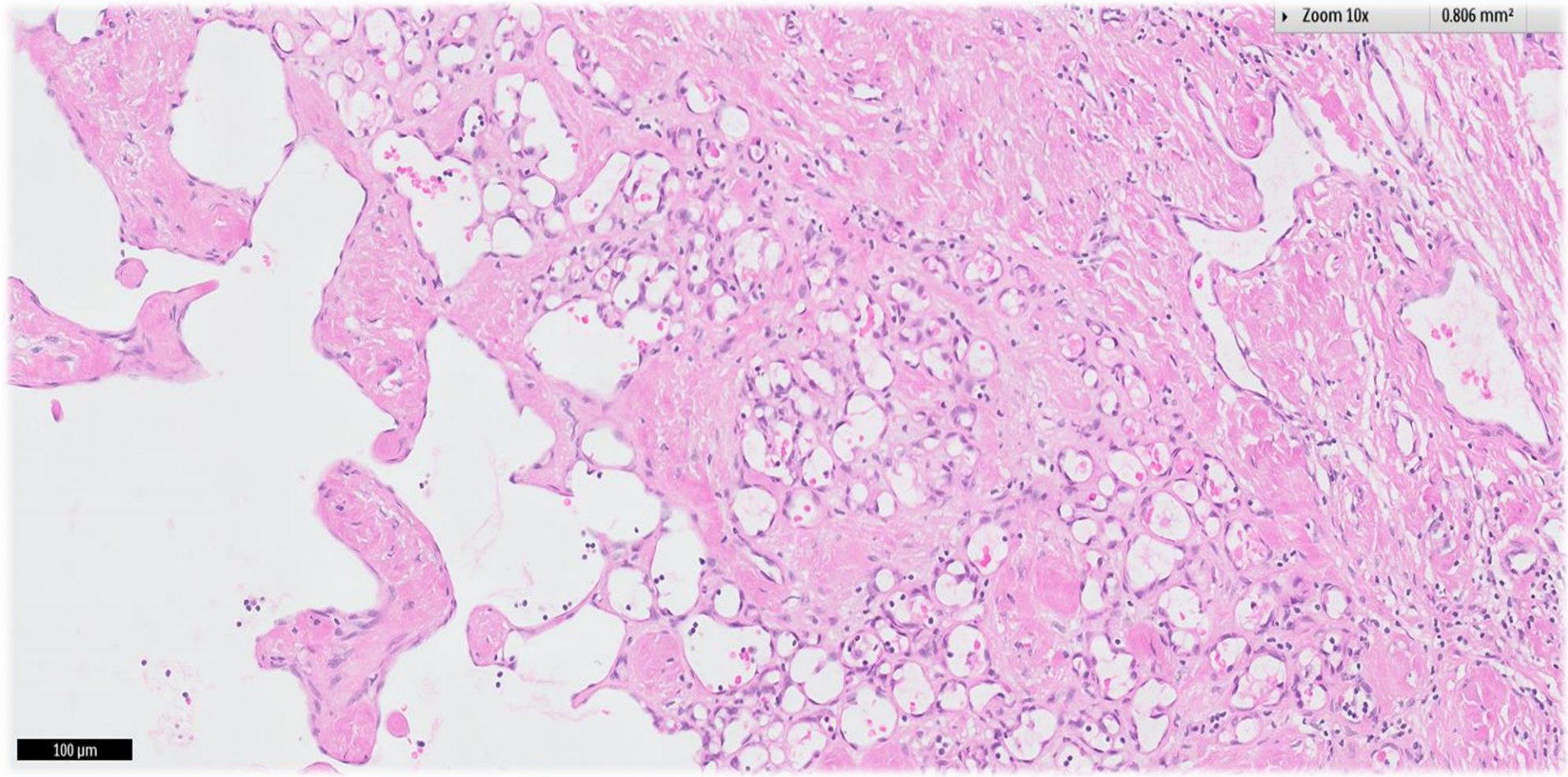
3.224 mm²



200 μ m

Zoom 10x

0.806 mm²



100 μm

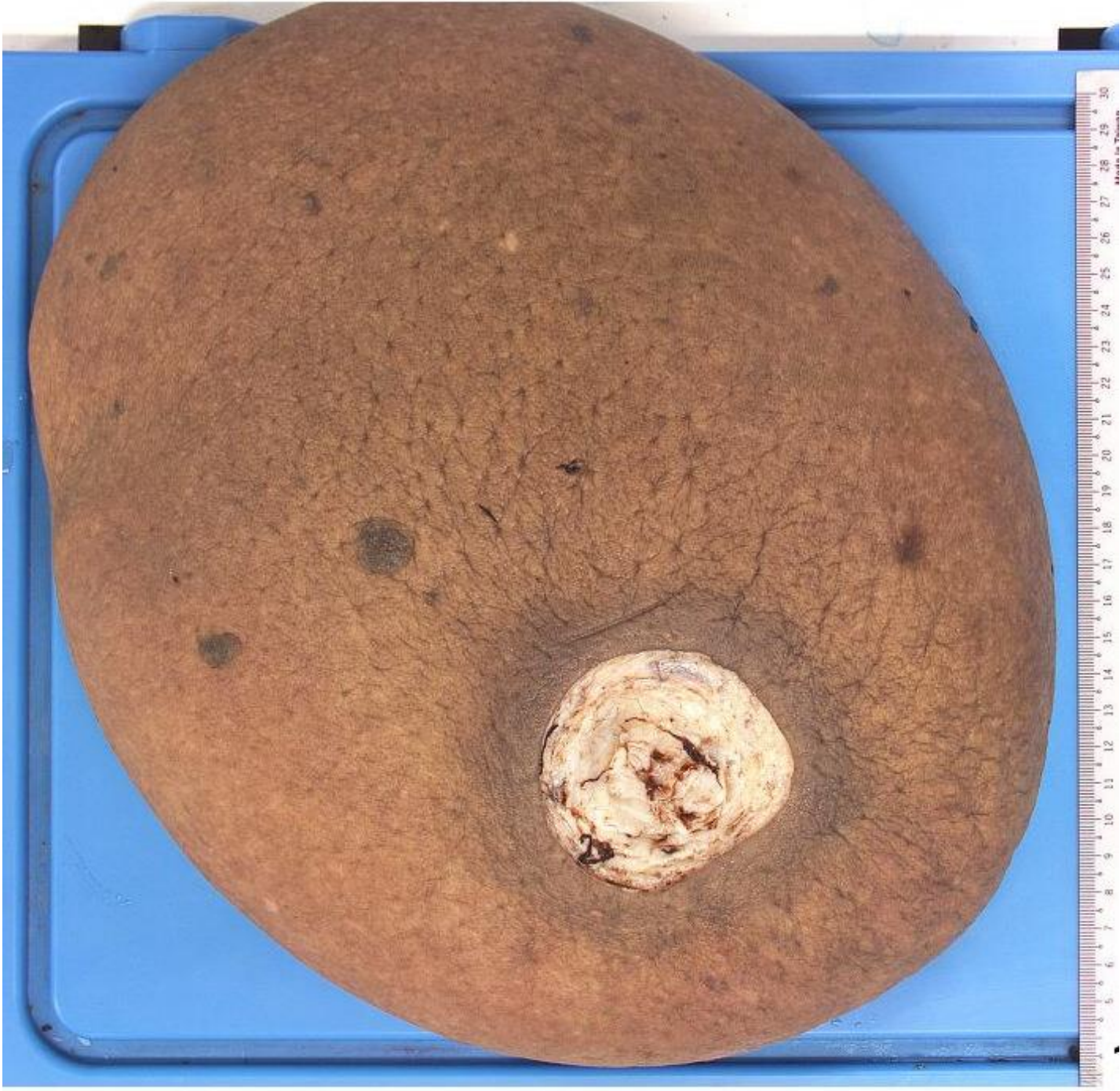
Academia



A 61-year-old Asian female with haemodialysis-dependent end-stage renal failure and a significant medical history of hypertension, diabetes mellitus, deep vein thrombosis, and pulmonary embolism presented with progressive enlargement of her left arm and breast.

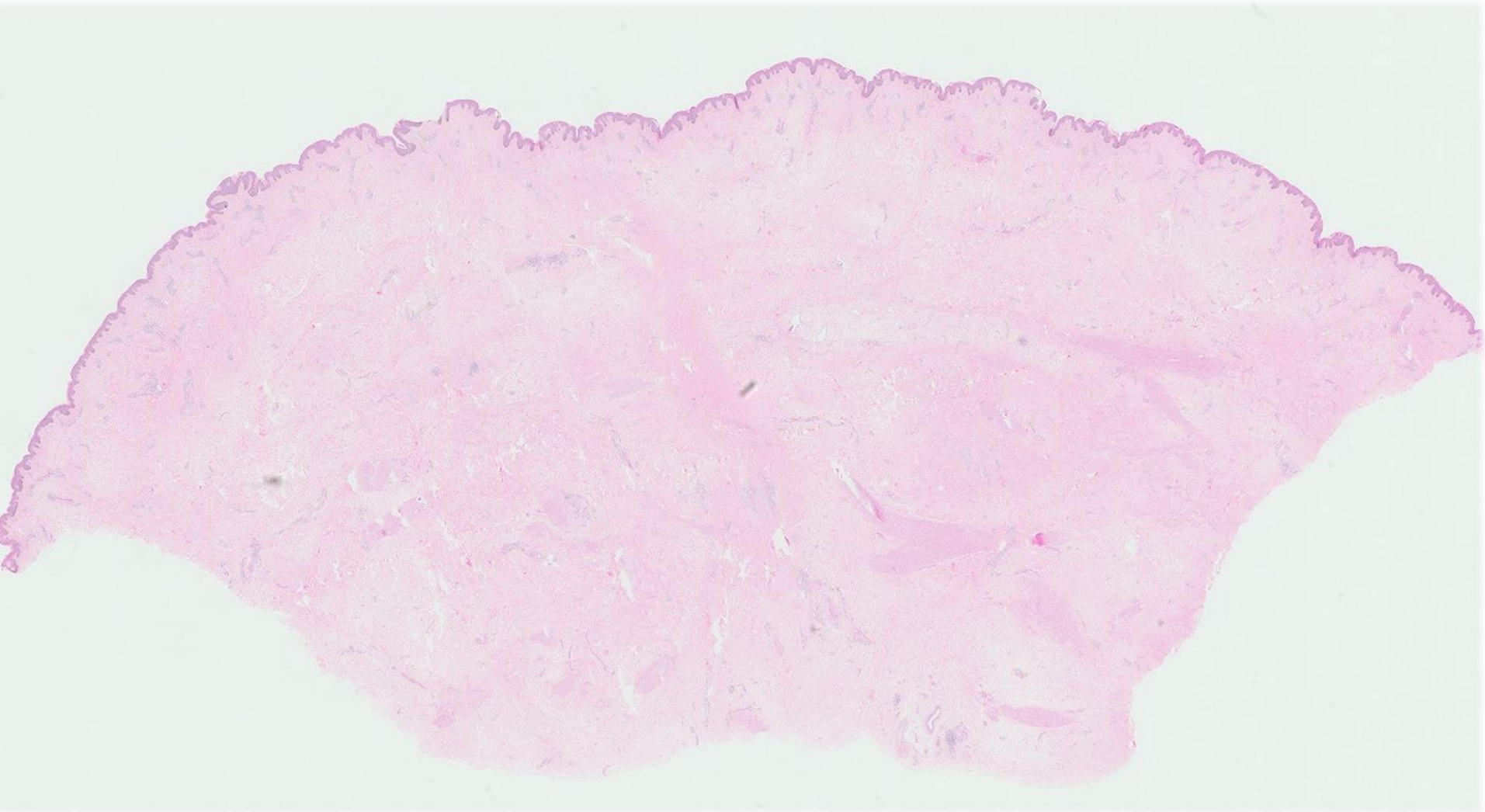
Magnetic resonance imaging revealed left axillary vein thrombosis extending to the left subclavian vein, without significant axillary lymphadenopathy.

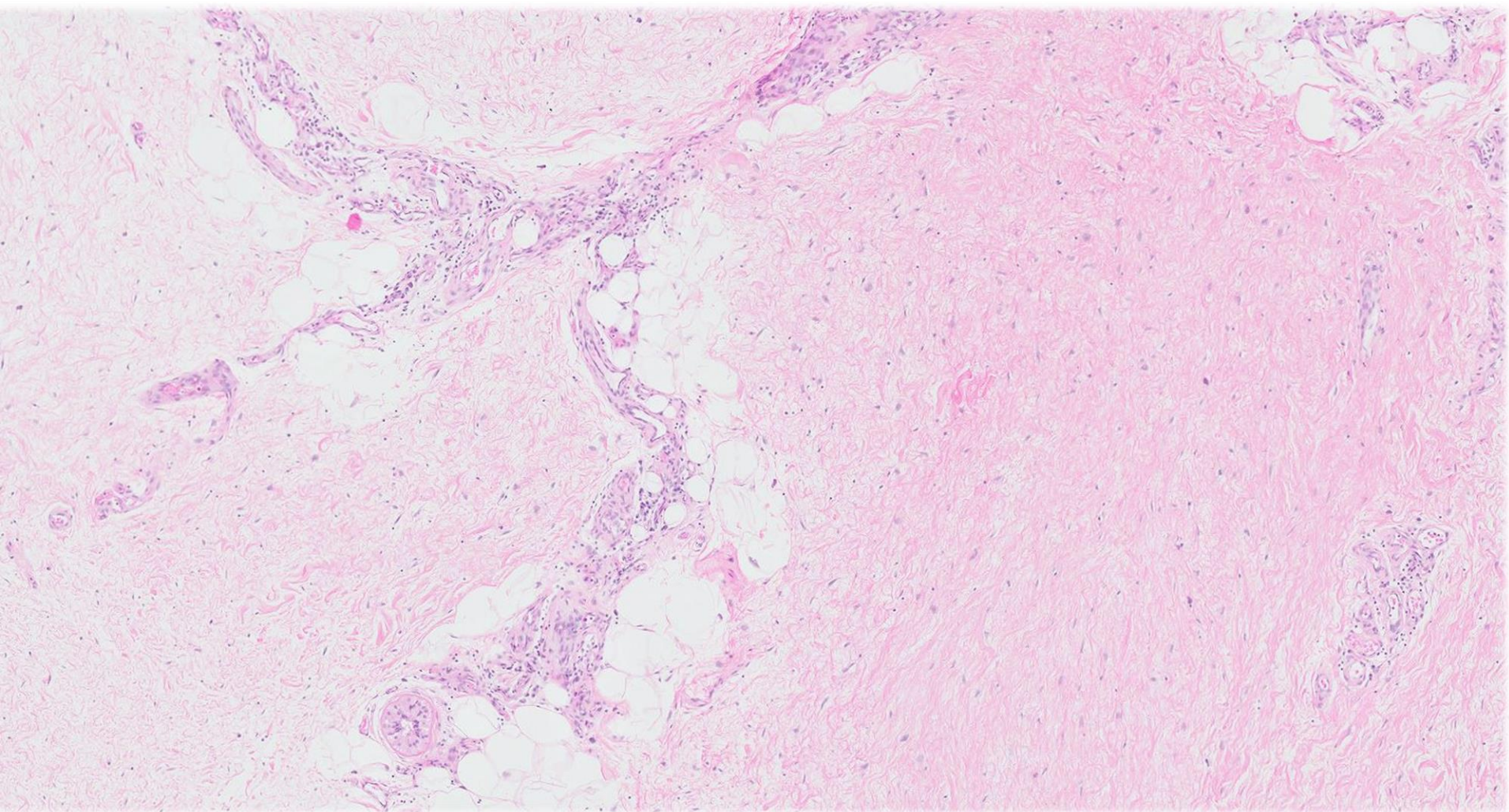
She had a previous episode of left upper limb cellulitis, which resolved after inpatient management. Owing to failure of conservative treatment, which included a period of compression garment therapy, the patient elected for a mastectomy.

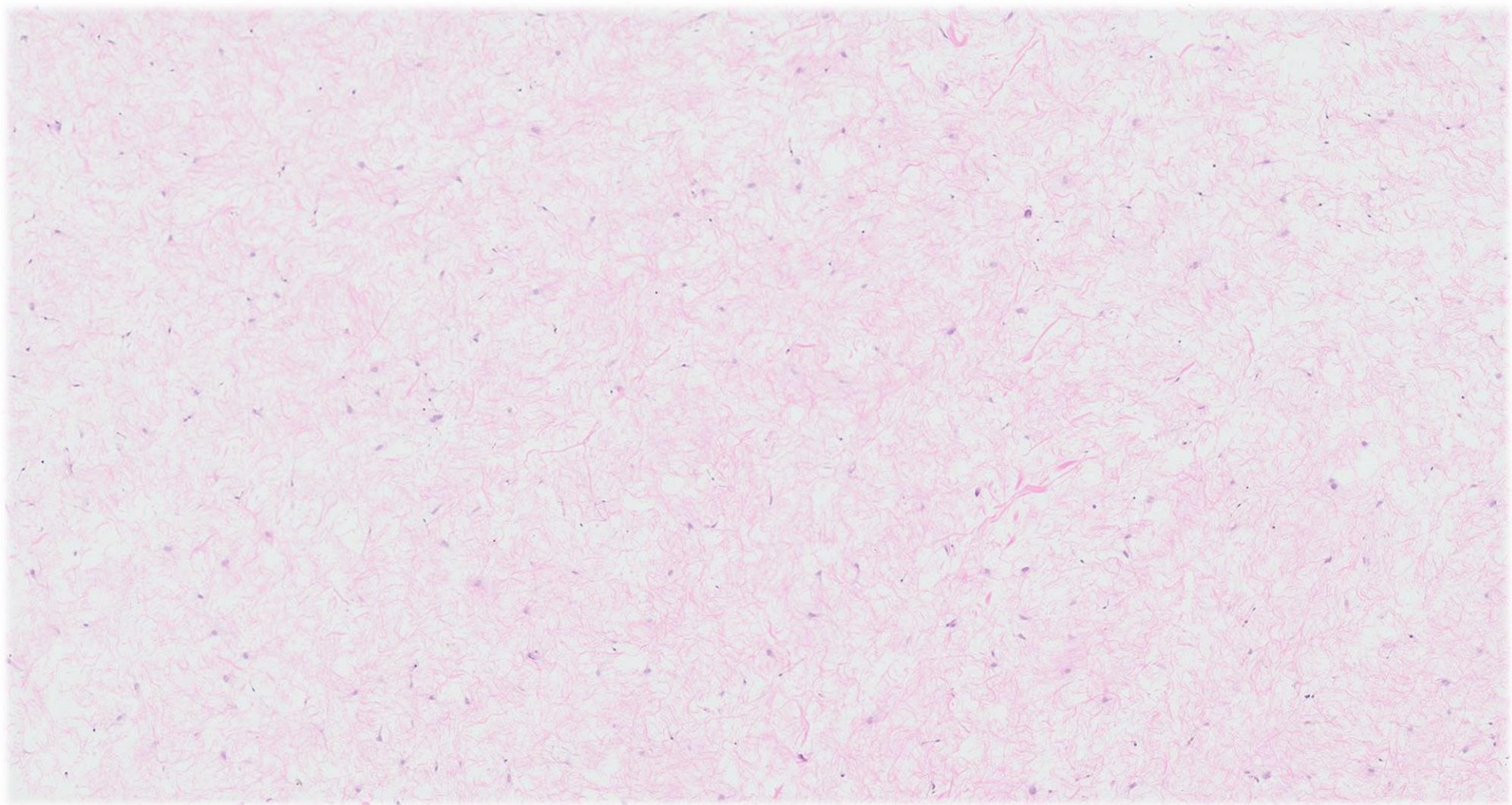


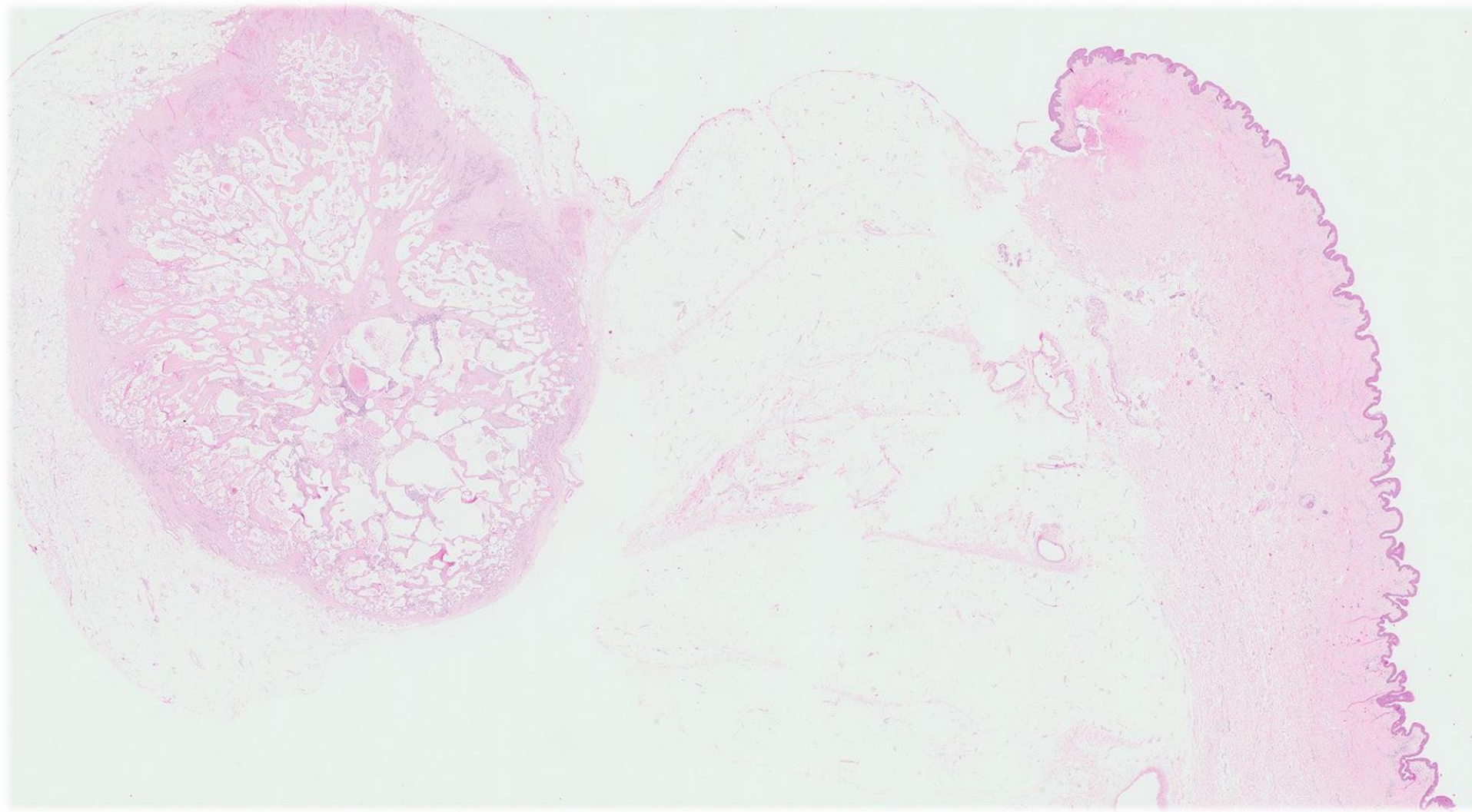
Macroscopy

- Left simple mastectomy specimen measured 31cm x 30cm x 9cm and weighed 4.1kg.
- Overlying skin showed generalised brawny discolouration.
- Sectioning the breast revealed an oedematous appearance with copious clear fluid oozing from the cut surfaces.
- A well-circumscribed nodule measuring 1.1cm in diameter was identified within the breast substance.

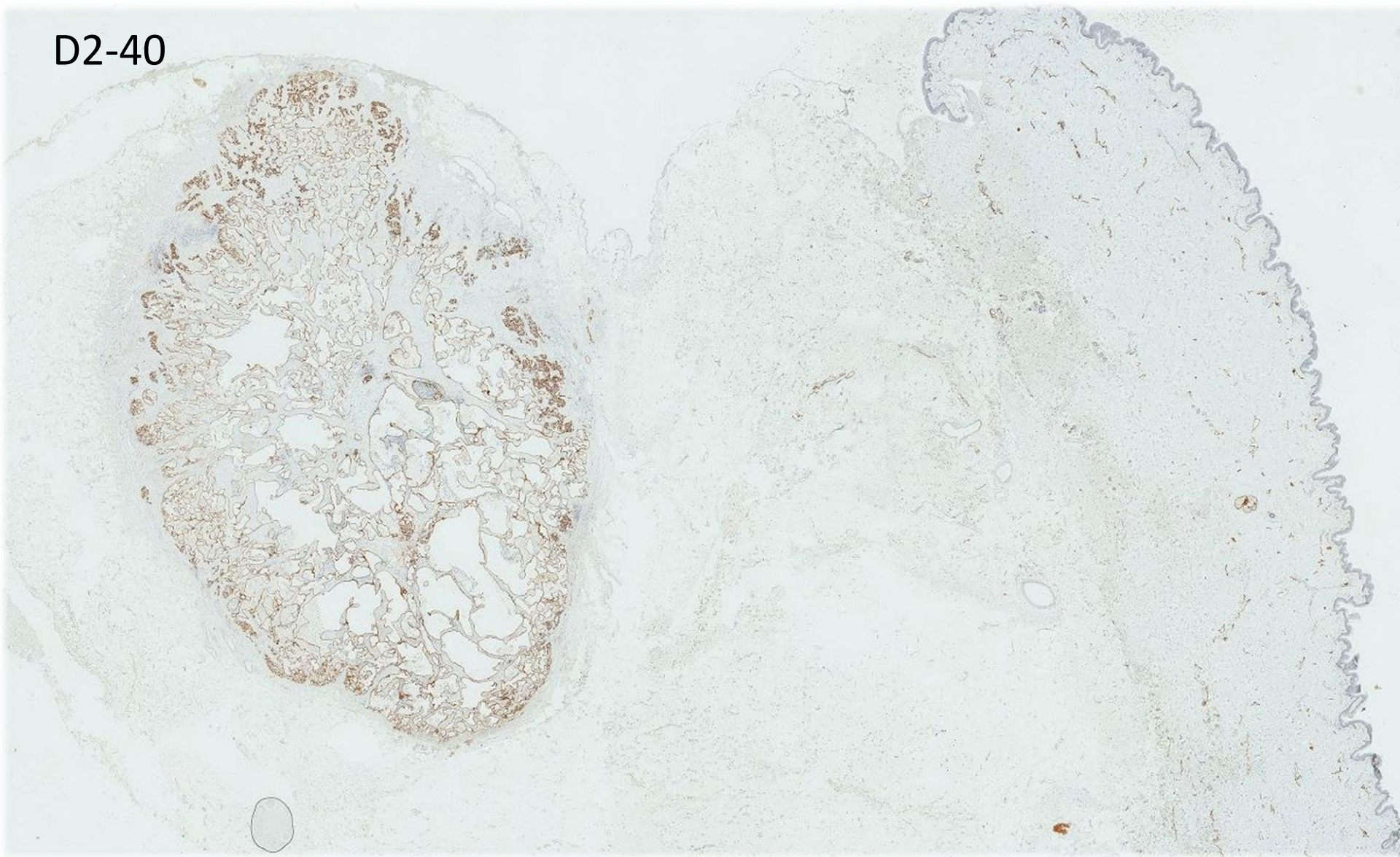








D2-40



Diagnosis

- Lymphangioma, in a background of lymphoedema of the breast.



Lymphoedema

- Characterised by the accumulation of protein-rich fluid within the interstitium, accompanied over time by fibrosis.
- Patient experiences an increase in mass of the affected organ, which initially manifests pitting oedema that eventually becomes firm due to supervening fibrosis.
- **Primary lymphoedema** may be congenital (Milroy's disease) or idiopathic (lymphedema precox or tarda).
- **Secondary lymphoedema**, in developed regions, is most commonly a result of lymphatic injury, iatrogenic (following oncologic surgery) or otherwise.
- Parasitic infestation by *Wuchereria* remains an important cause of acquired lymphoedema worldwide.

Upper limb and breast lymphoedema

- Upper limb lymphoedema is a well-described sequela of axillary lymph node dissection, with a wide range of reported incidences.
- Lymphoedema of the breast itself is less common, and has been reported following lumpectomy and radiation therapy.
- Besides the disfiguring and debilitating nature of the disease, with the potential for recurrent infections, malignant transformation is a dreaded complication of long-standing lymphoedema.

Upper limb and breast lymphoedema

- In 1906, Lowenstein described angiosarcoma developing in a patient who suffered chronic post-traumatic arm lymphoedema.
- In 1948, Stewart and Treves reported 6 cases of lymphangiosarcoma developing in post-mastectomy lymphoedema, or “elephantiasis chirurgica”, hence the eponymous syndrome.

Microscopy

- Lymphoedematous tissues show stromal oedema with “pushing apart” of normal tissue constituents.
- Hypocellular proliferation of fibroblastic cells,
- Ectatic tortuous lymphatics may be observed.
- Variable participation of chronic inflammatory cells.
- Multinucleated stromal giant cells, established fibrosis, acanthosis and hyperkeratosis of overlying skin.
- Complications are fat necrosis or cellulitis.
- Presence of a localised, circumscribed lymphatic proliferation is compatible with a diagnosis of lymphangioma, in a background of lymphoedema.

Differential diagnosis

- Intravascular papillary endothelial hyperplasia
 - Papillary formations associated with thrombus
 - Single layer of lining endothelial cells that are devoid of atypia.
- Acquired lymphangiectasis
 - Widespread dilatation of superficial lymphatics
 - Clinical picture of grouped vesicles and bullae

Differential diagnosis

- Lymphangiosarcoma or angiosarcoma
 - Interanastomosing architecture
 - Increased cellularity
 - Endothelial atypia
 - Mitotic activity
- Well-differentiated liposarcoma
 - Stromal giant cells within an adipocyte-rich milieu such as the breast parenchyma may provoke a consideration of well-differentiated liposarcoma
 - D2-40 (podoplanin), a sensitive and specific immunohistochemical marker of lymphatic endothelium, can aid in differential diagnosis
- Clinicoradiological correlation is essential for arriving at a correct pathological diagnosis.

References

- Warren AG, Brorson H, Borud LJ, Slavin SA. Lymphedema: a comprehensive review. *Ann Plast Surg.* 2007;59(4):464-472.
- Paskett ED, Naughton MJ, McCoy TP, Case LD, Abbott JM. The Epidemiology of Arm and Hand Swelling in Premenopausal Breast Cancer Survivors. *Cancer Epidemiol Biomarkers Prev.* 2007;16(4):775-782.
- Nesvold I-L, Dahl AA, Løkkevik E, Marit Mengshoel A, Fosså SD. Arm and shoulder morbidity in breast cancer patients after breast-conserving therapy versus mastectomy. *Acta Oncol.* 2008;47(5):835-842.
- Bumpers HL, Best IM, Norman D, Weaver WL. Debilitating lymphedema of the upper extremity after treatment of breast cancer. *Am J Clin Oncol.* 2002;25(4):365-367.
- Stewart FW, Treves N. lymphangiosarcoma in postmastectomy lymphedema; a report of six cases in elephantiasis chirurgica. *Cancer.* 1948;1(1):64-81.
- Rao AG. Acquired lymphangiectasis following surgery and radiotherapy of breast cancer. *Indian J Dermatol.* 60(1):106.
- Giannelli V, Rockley PF. Acquired lymphangiectasis following mastectomy and radiation therapy--report of a case and review of the literature. *Cutis.* 1996;58(4):276-278.
- Breiteneder-Geleff S, Soleiman A, Kowalski H, et al. Angiosarcomas express mixed endothelial phenotypes of blood and lymphatic capillaries: podoplanin as a specific marker for lymphatic endothelium. *Am J Pathol.* 1999;154(2):385-394.
- Fukunaga M. Expression of D2-40 in lymphatic endothelium of normal tissues and in vascular tumours. *Histopathology.* 2005;46(4):396-402.

