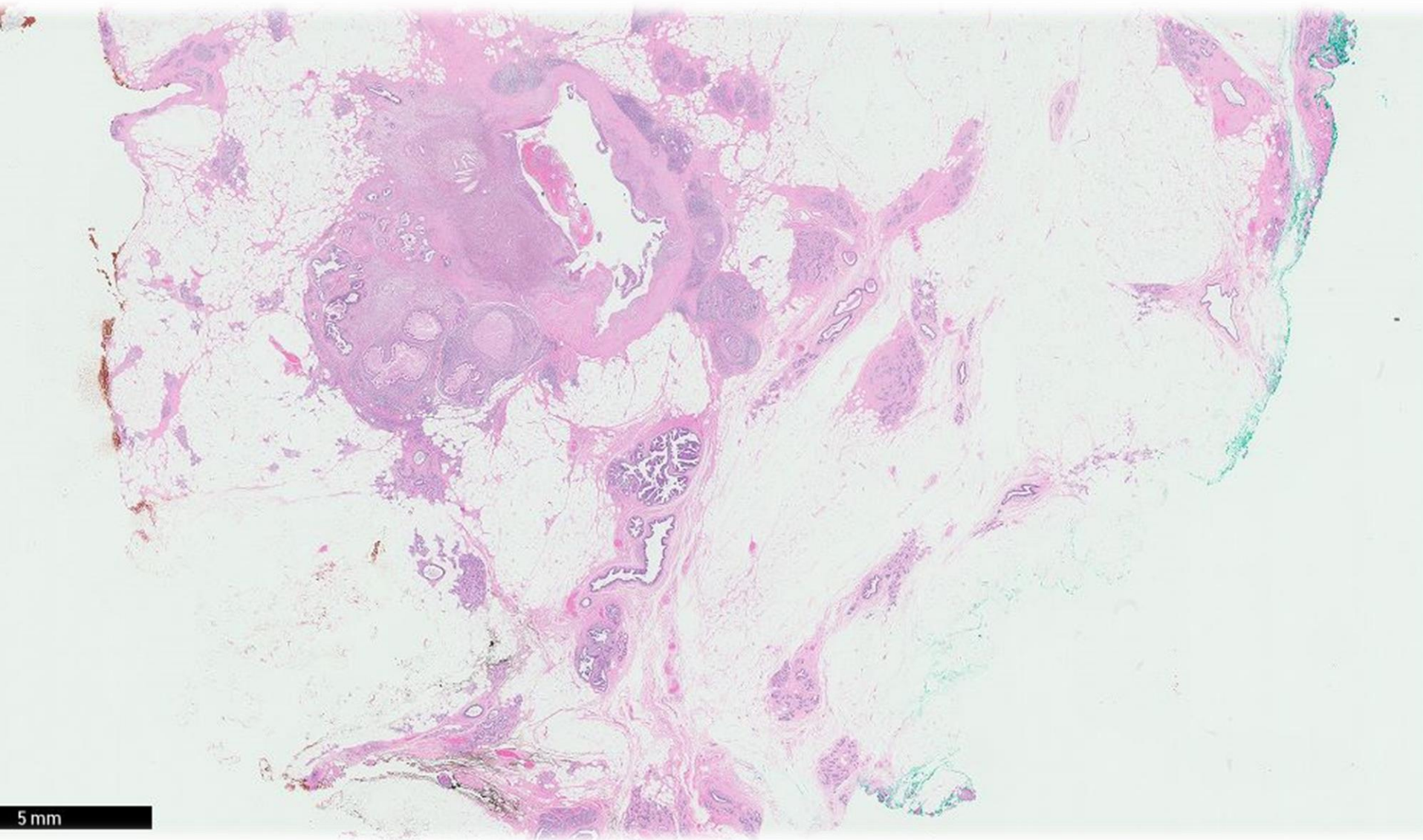


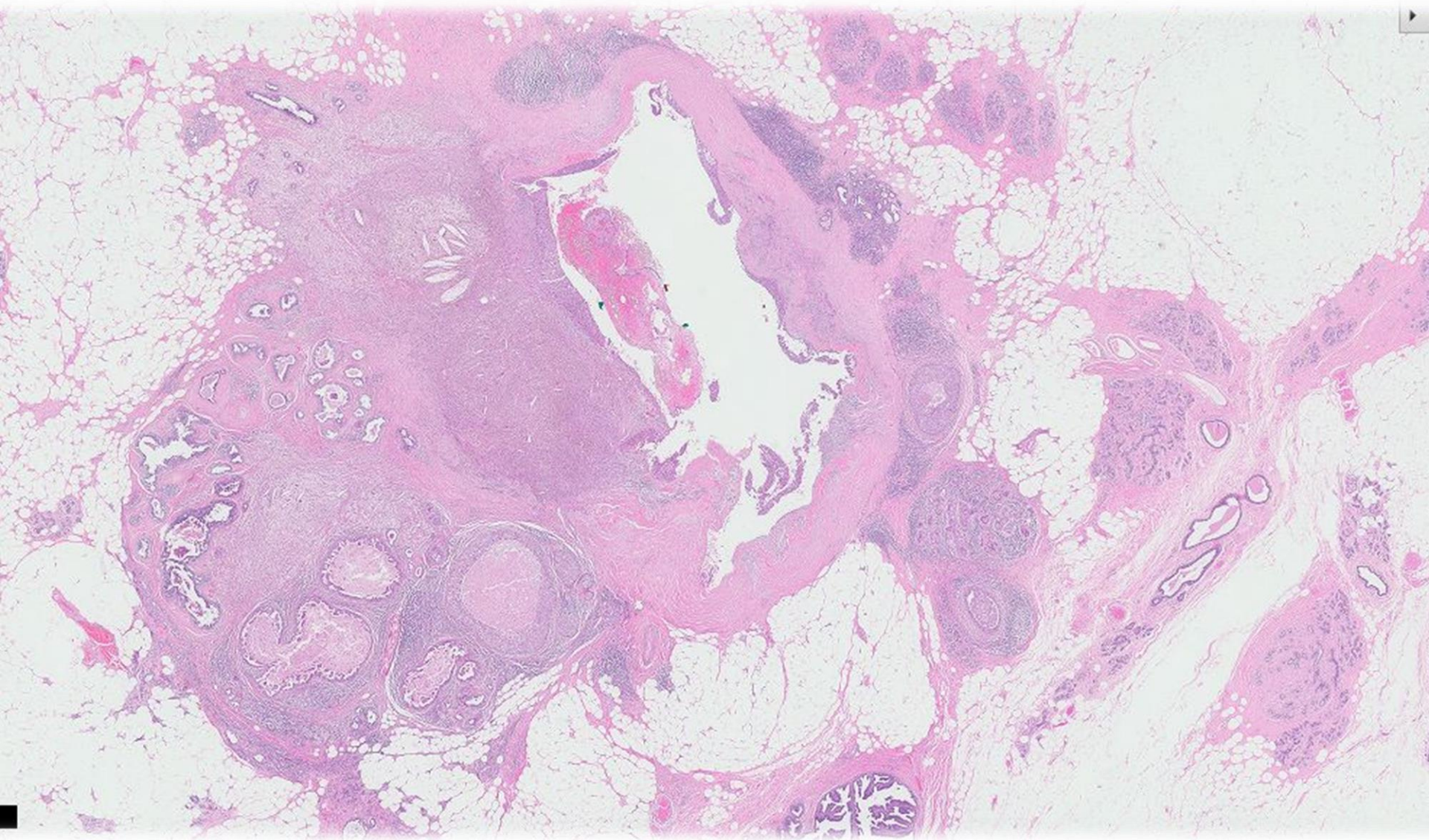
# Case 4

45 year old Malay lady with wide excision of the right breast.



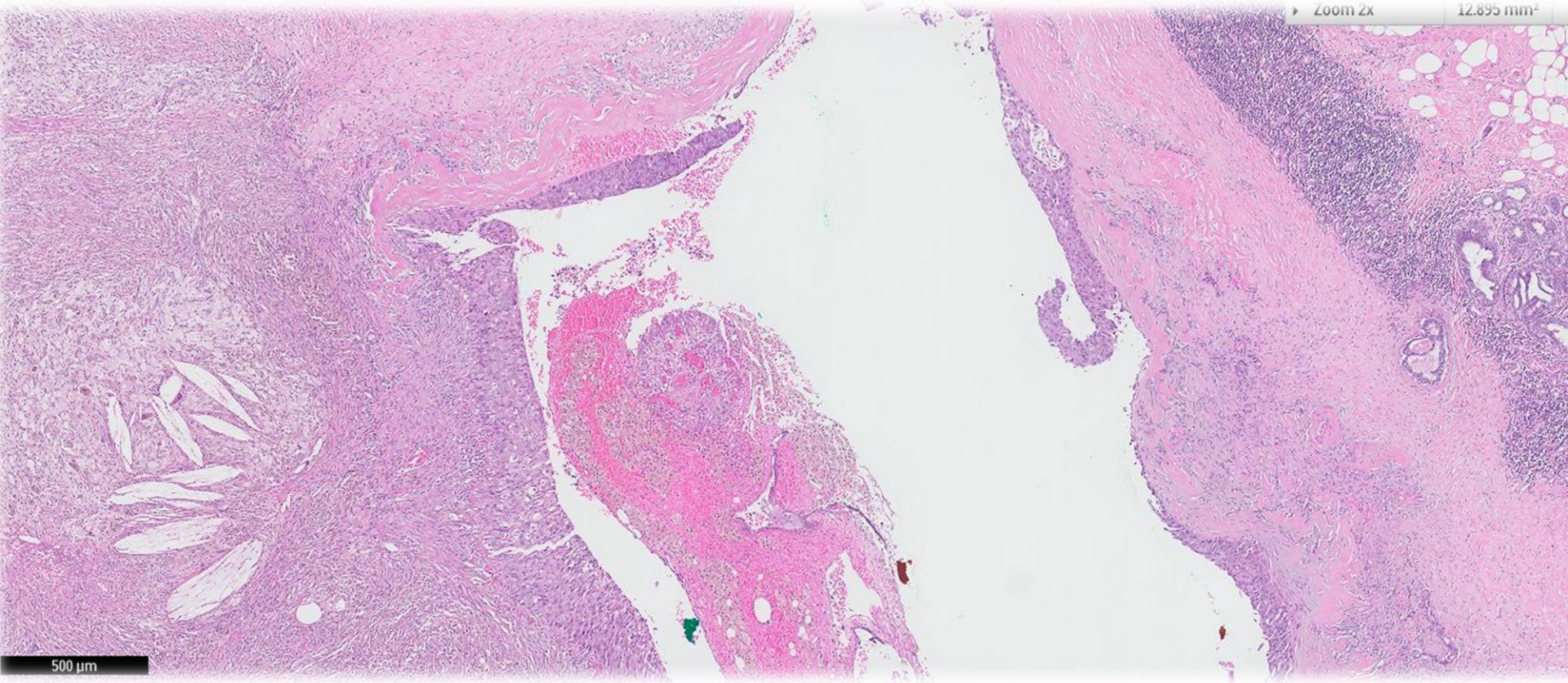


5 mm



Zoom 2x

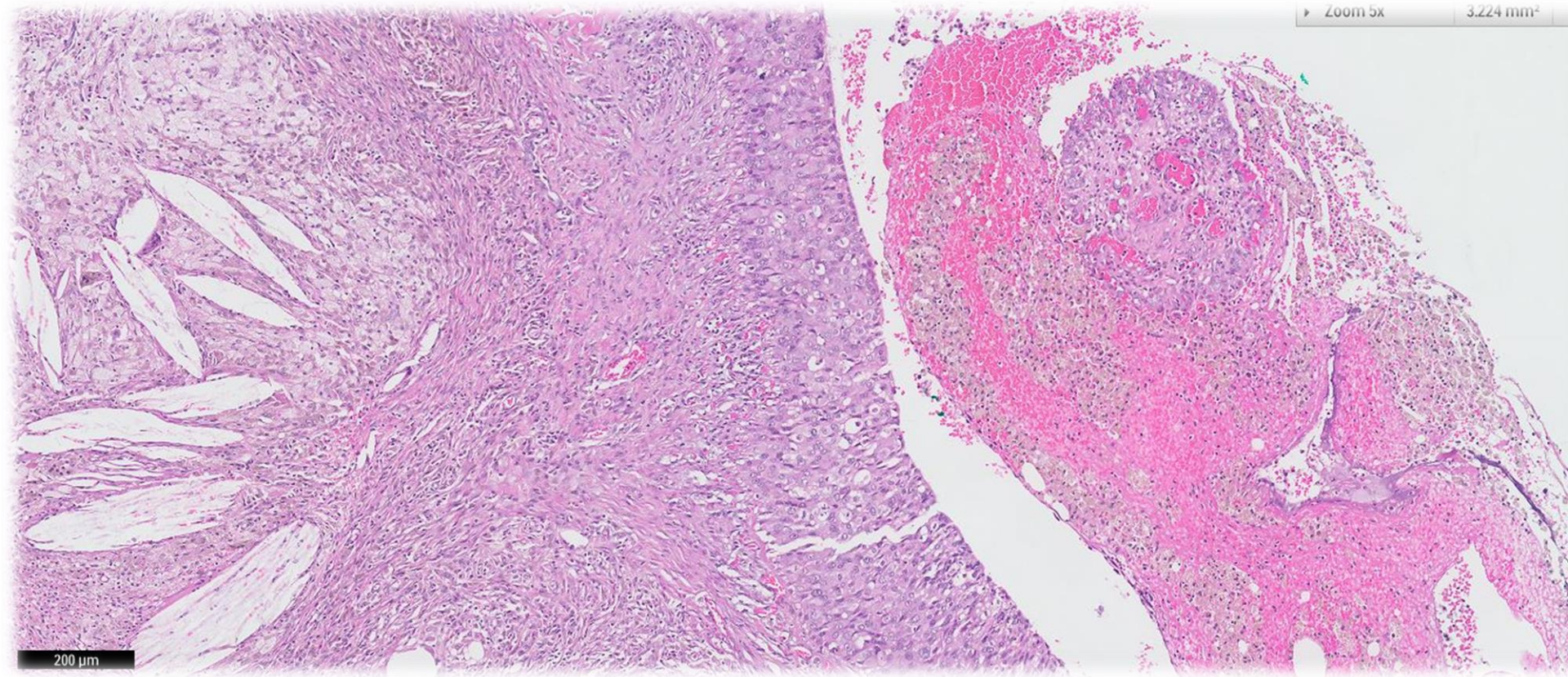
12.895 mm<sup>2</sup>



500 μm

Zoom 5x

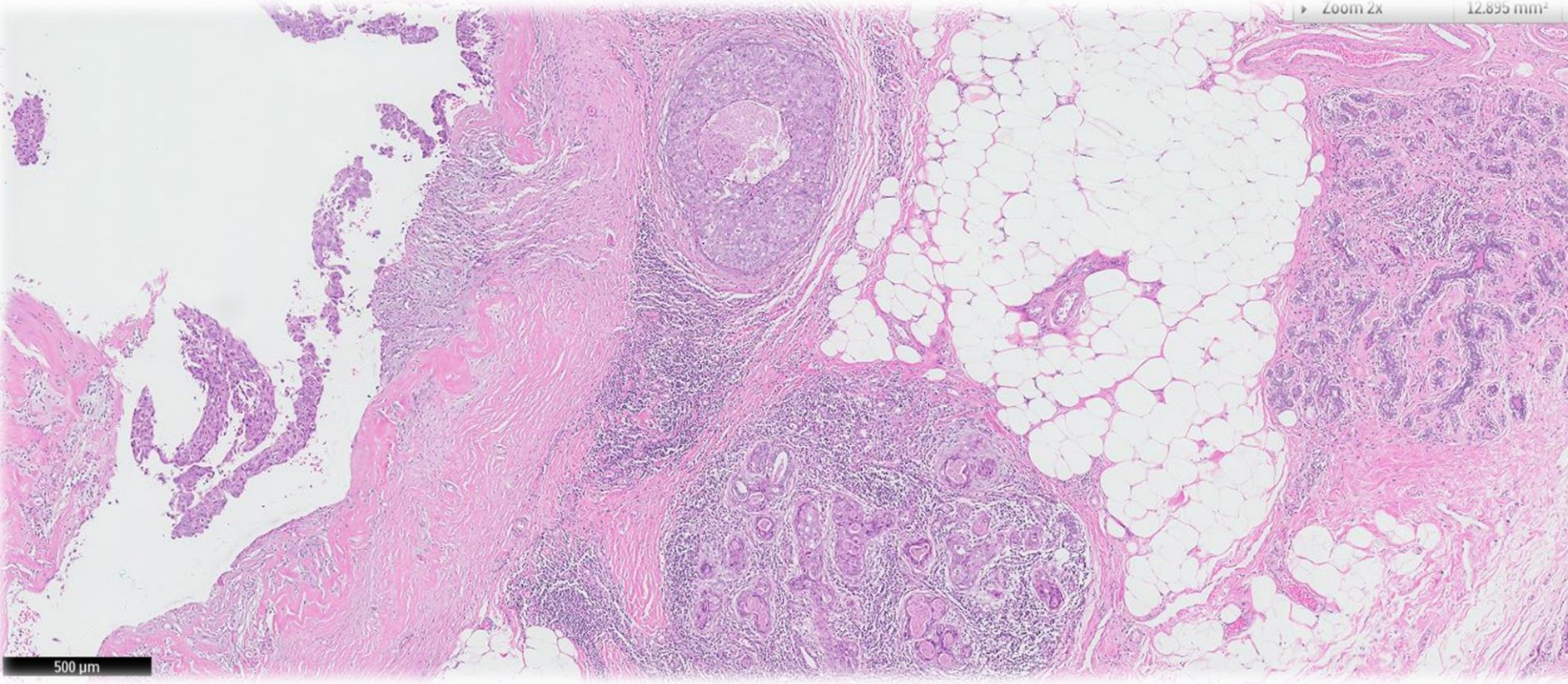
3.224 mm<sup>2</sup>



200  $\mu$ m

Zoom 2x

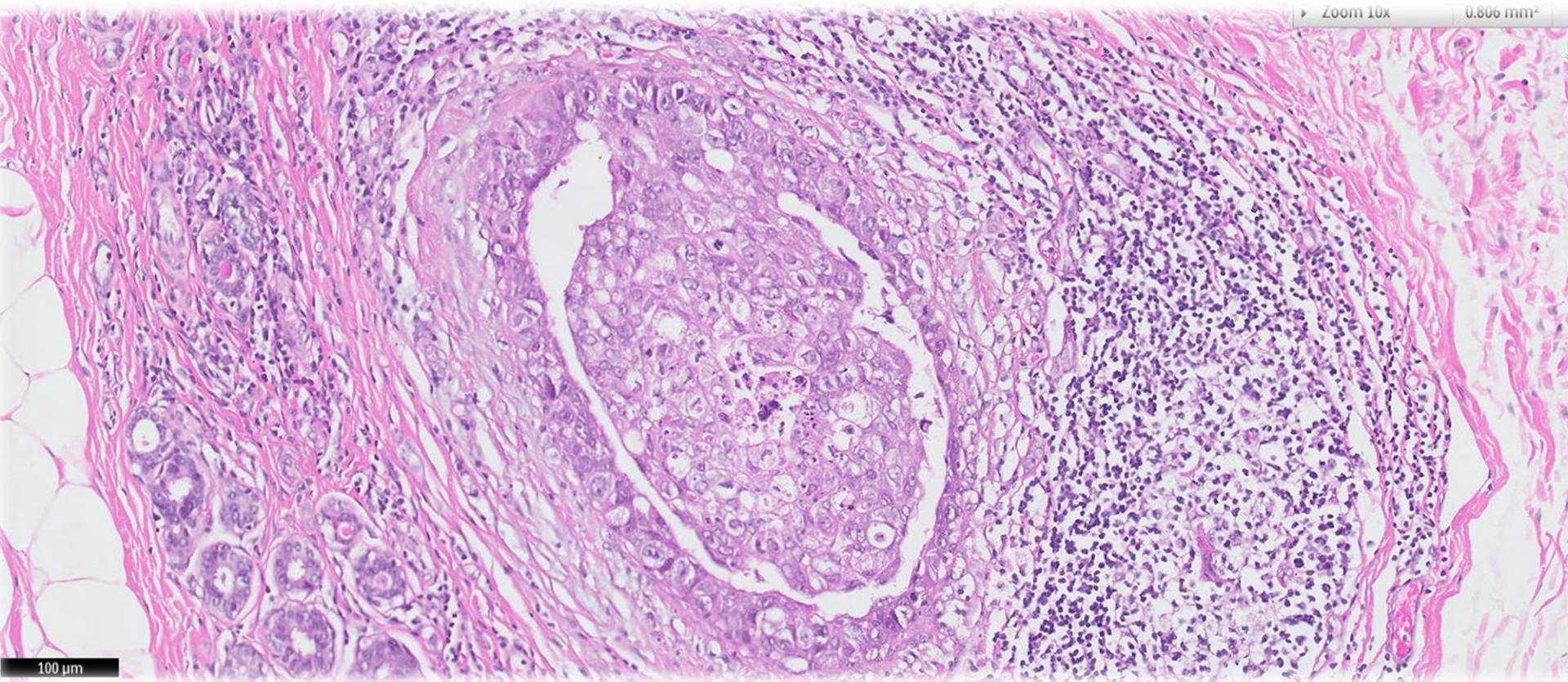
12.895 mm<sup>2</sup>



500 μm

Zoom 10x

0.806 mm<sup>2</sup>

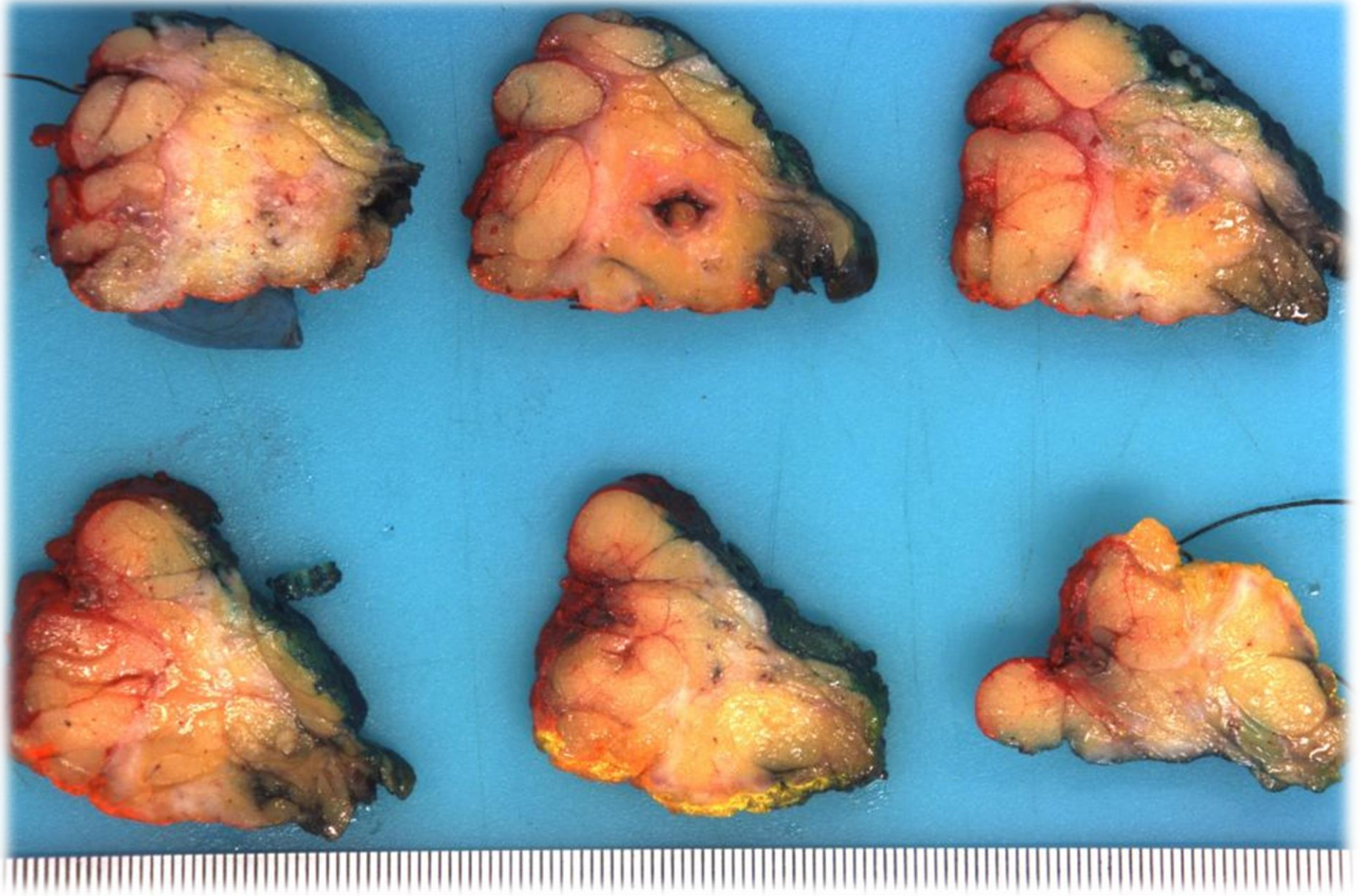


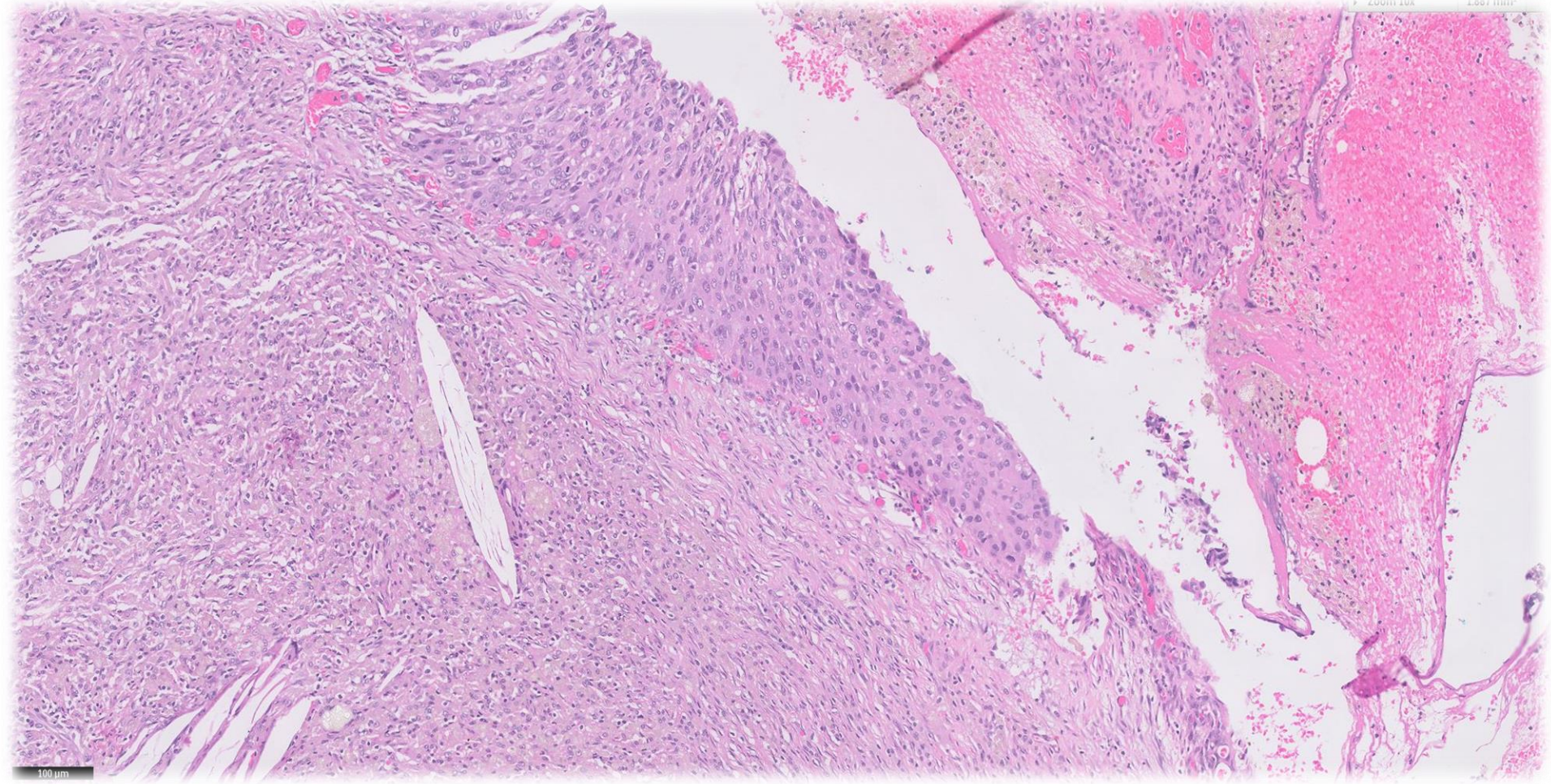
100 μm

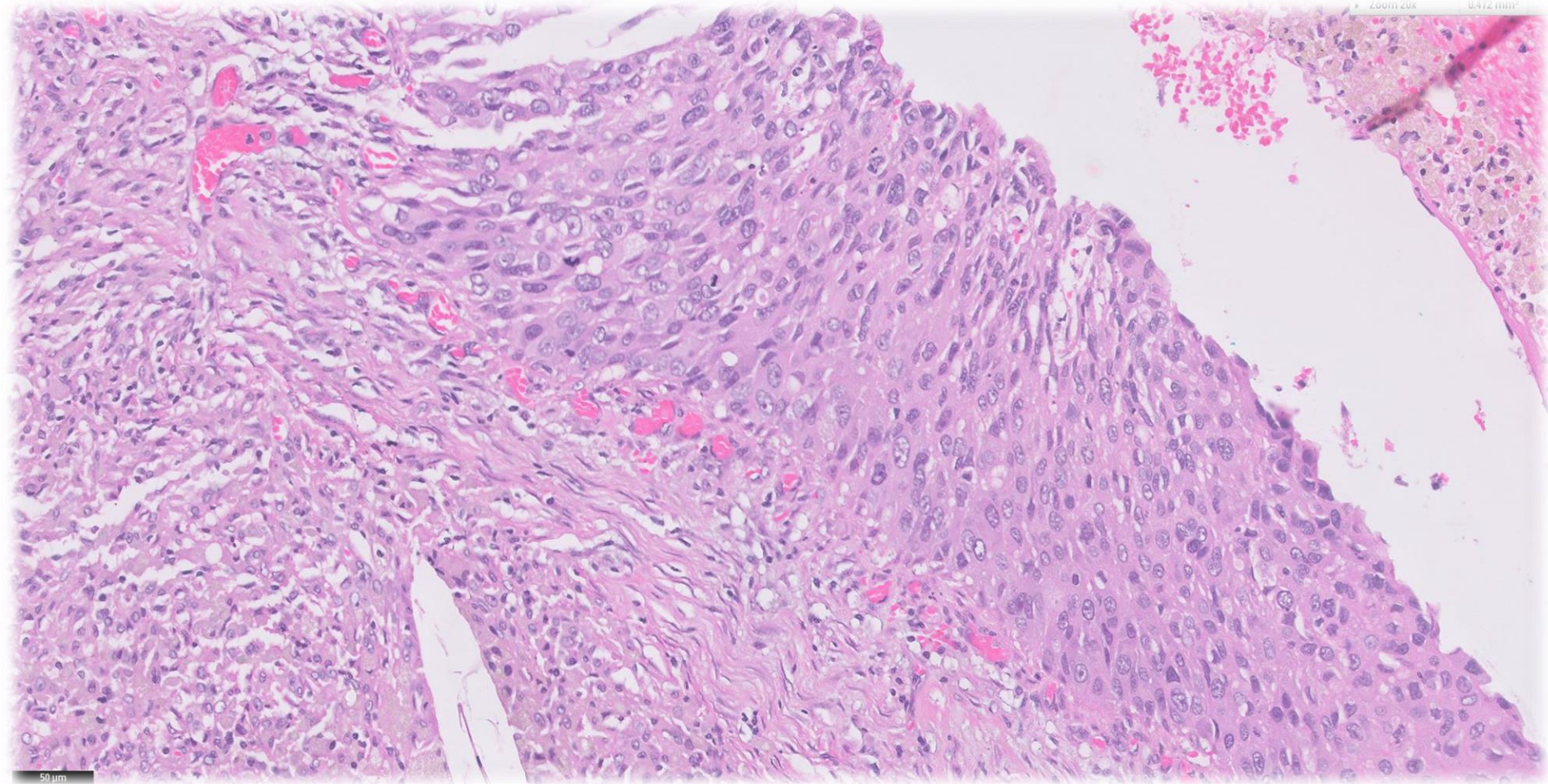


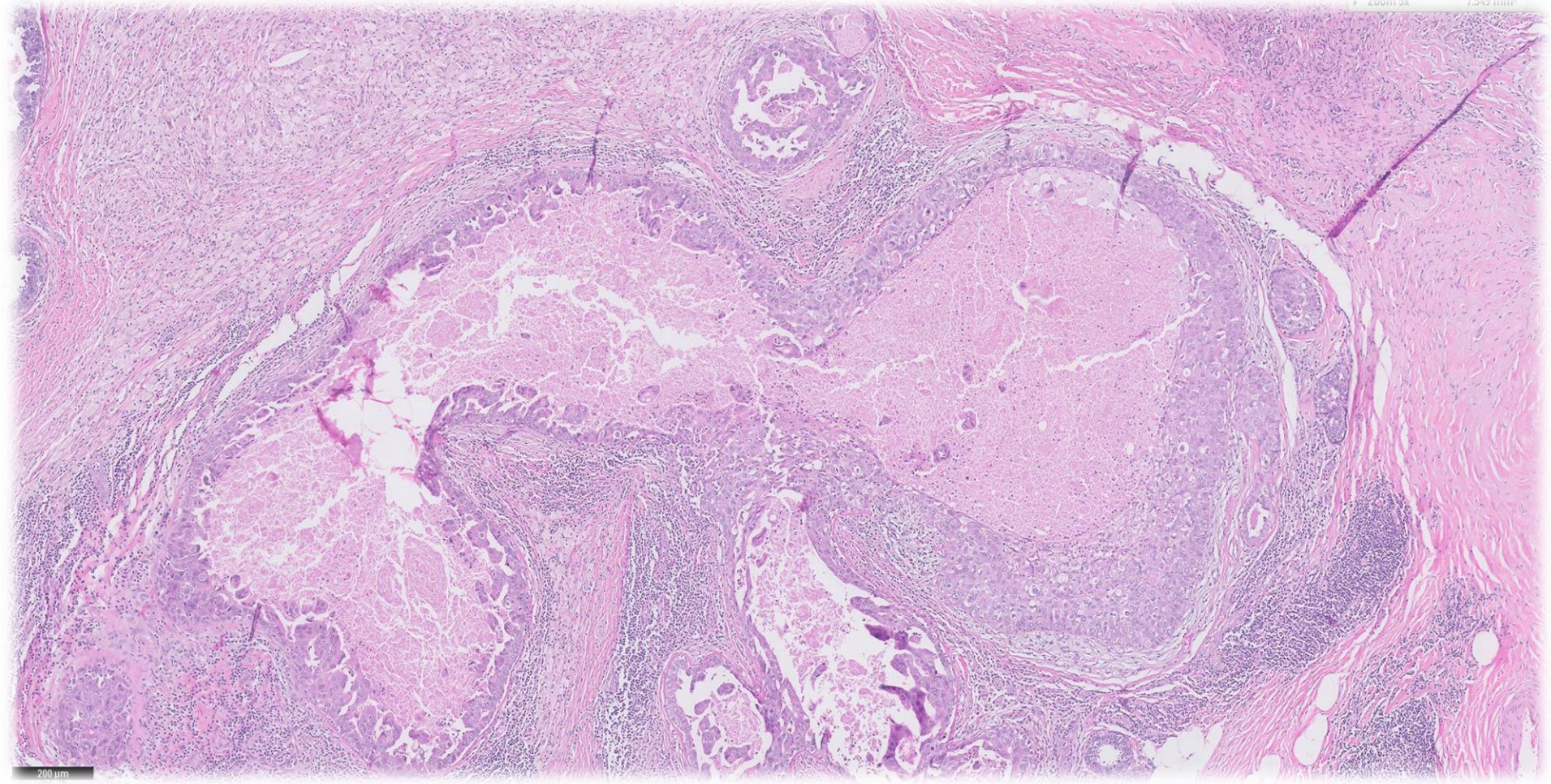
***Orchid Garden  
Singapore Botanic Gardens***

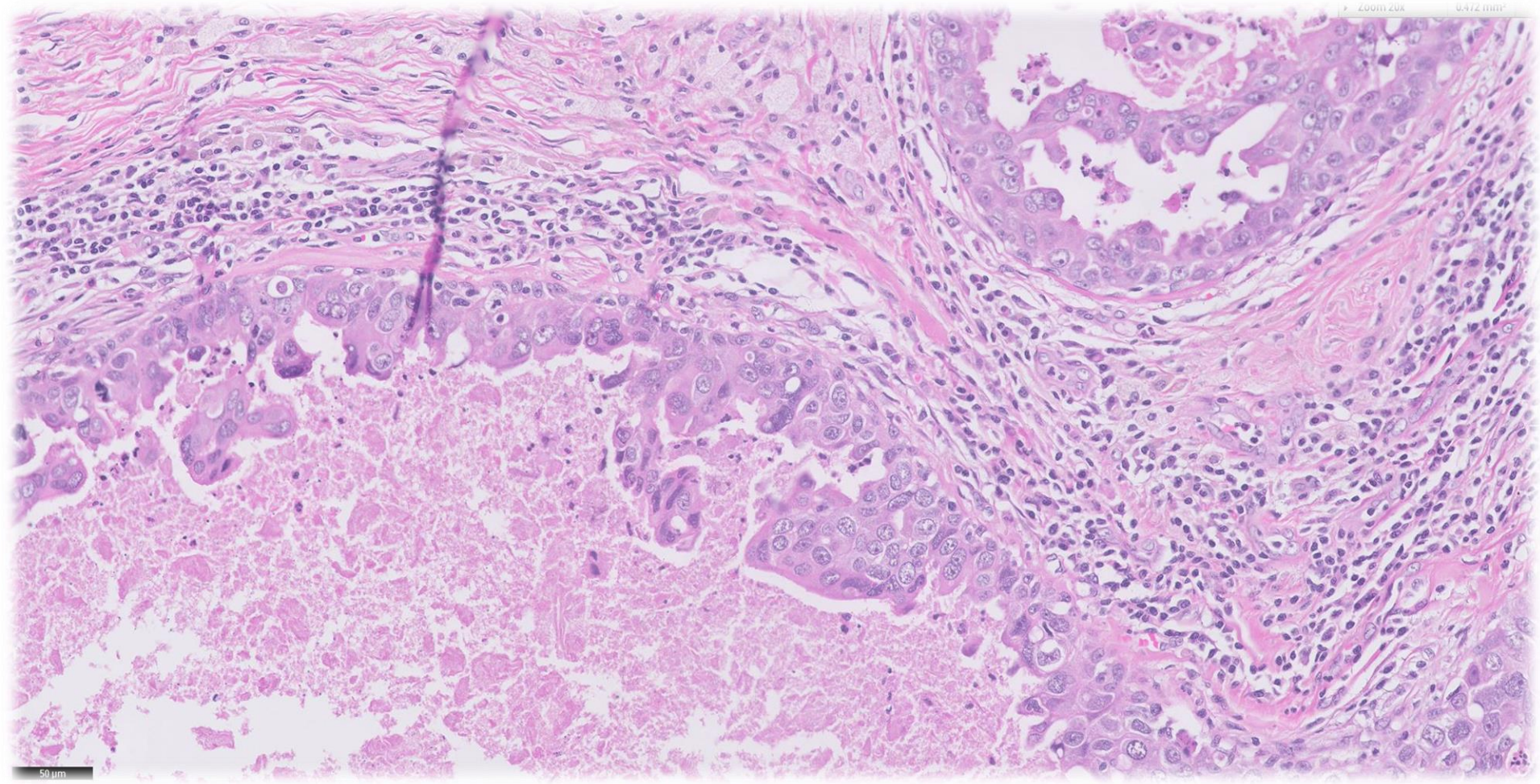


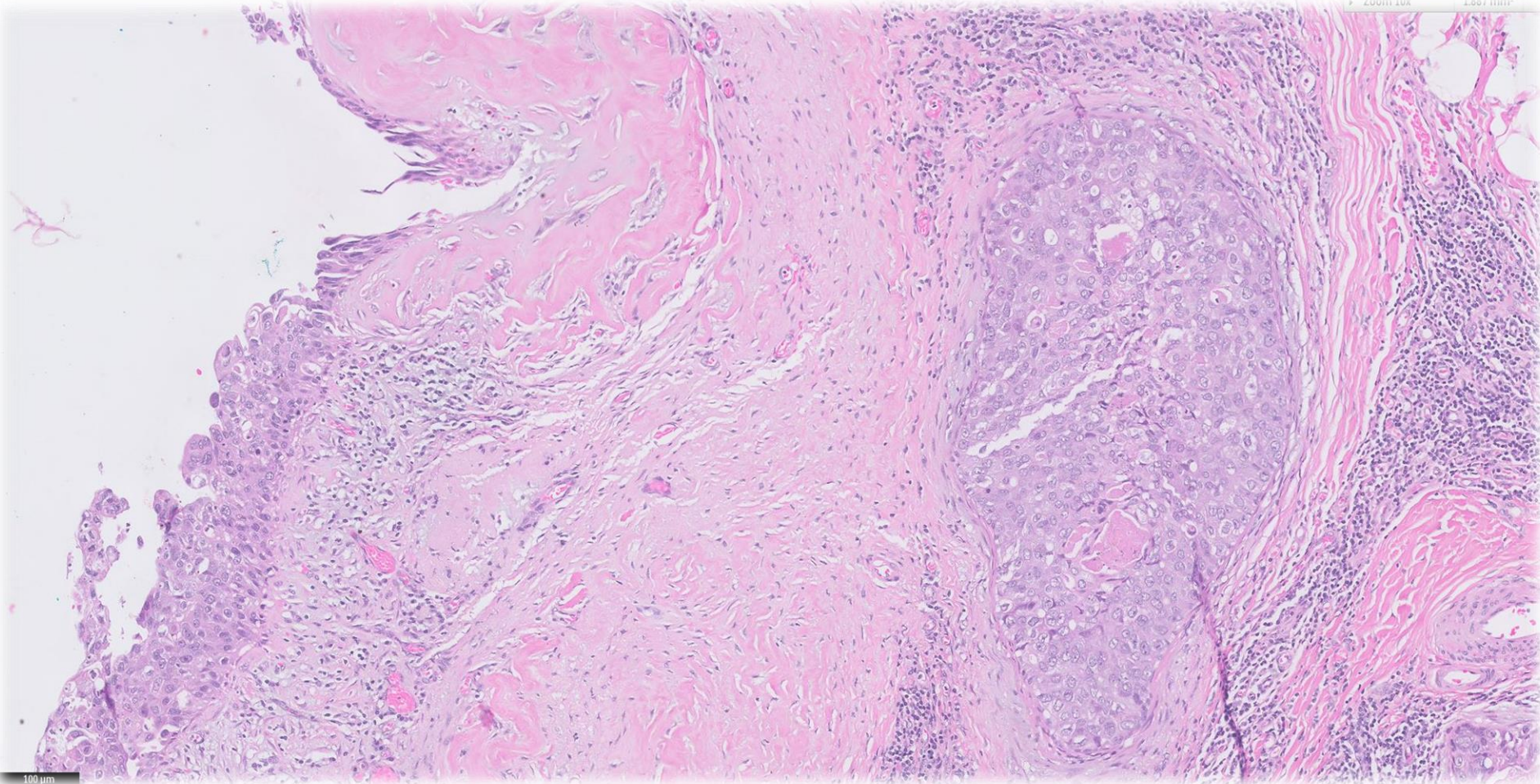


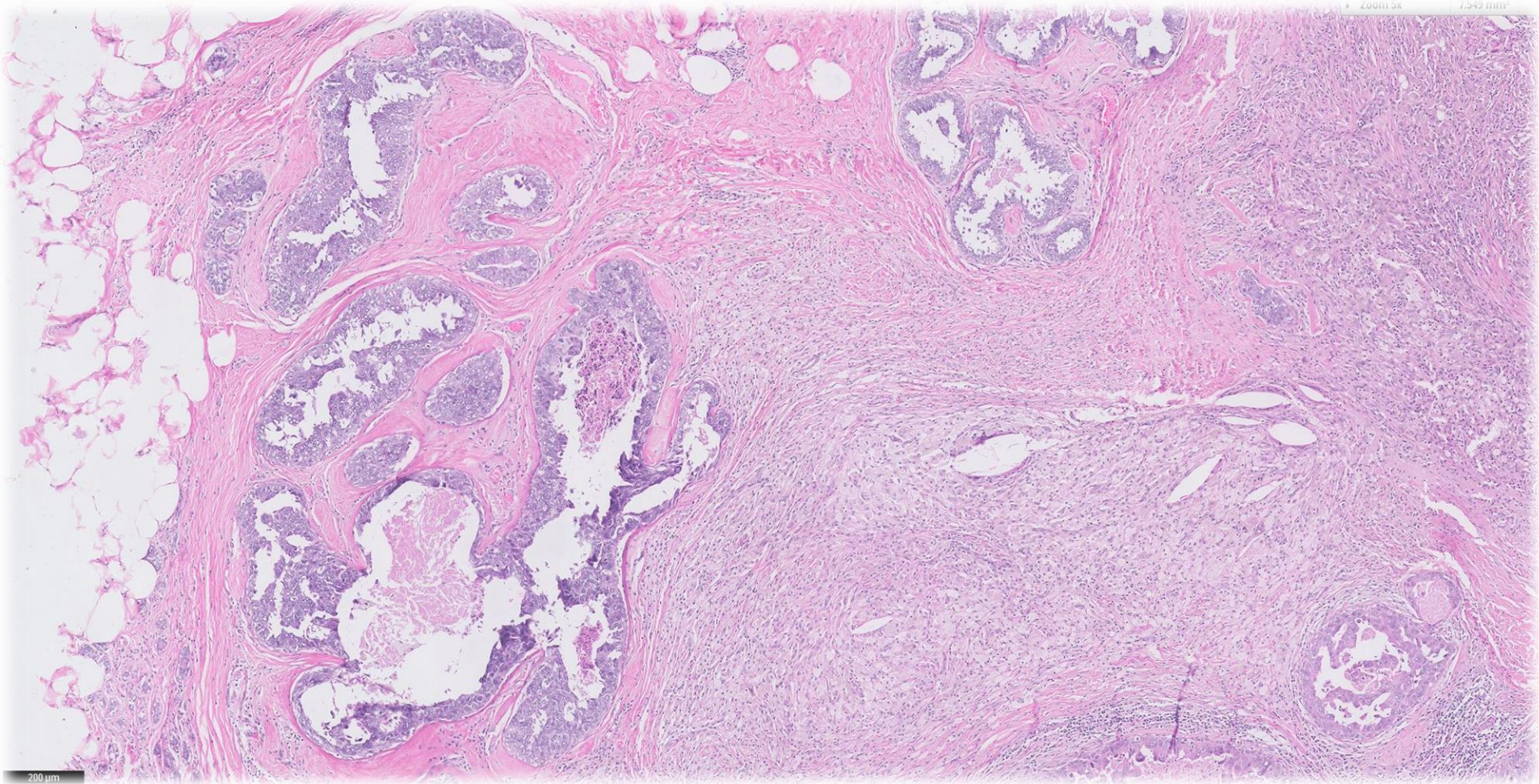


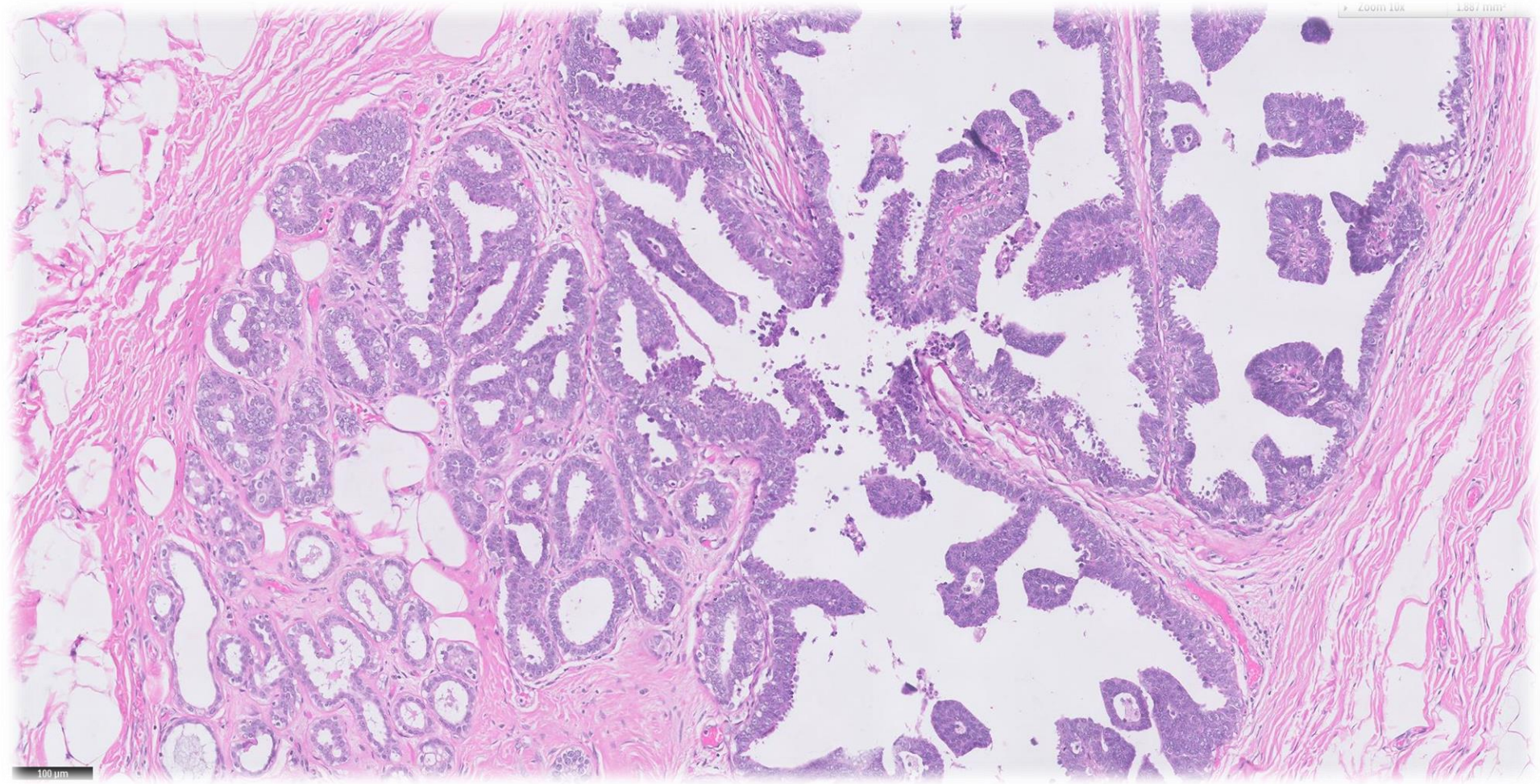




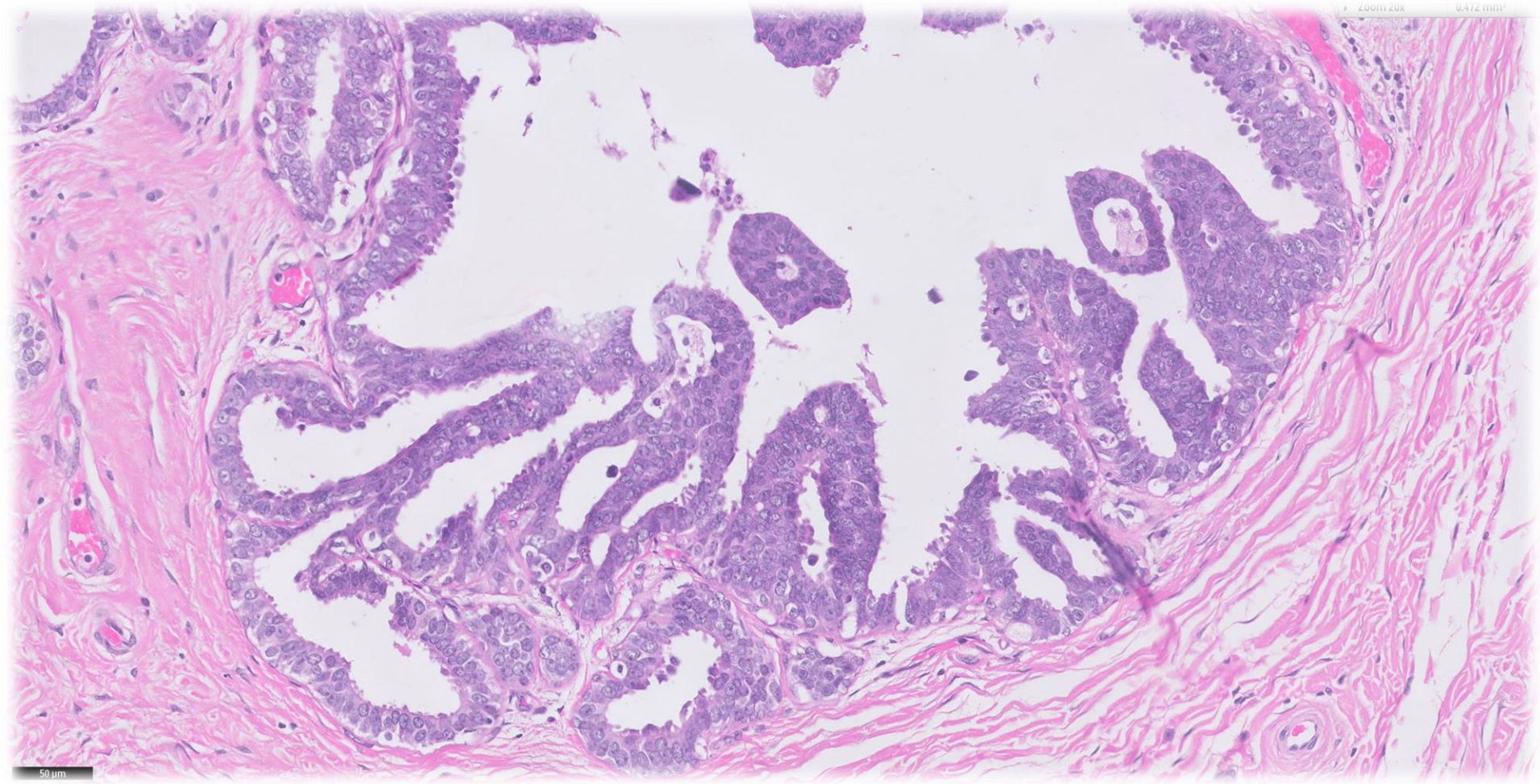












# Diagnosis

- Right breast excision:
  - Ductal carcinoma in situ, high nuclear grade with necrosis and cystic changes.
  - ER negative, PR negative.
  - Small component of low nuclear grade DCIS.



# Classification of DCIS

- Nuclear grade ~
  - Low, intermediate, high
- Based on highest grade present.
- Although infrequent, low and high grade DCIS can coexist in the same breast, and sometimes even in the same duct.

