

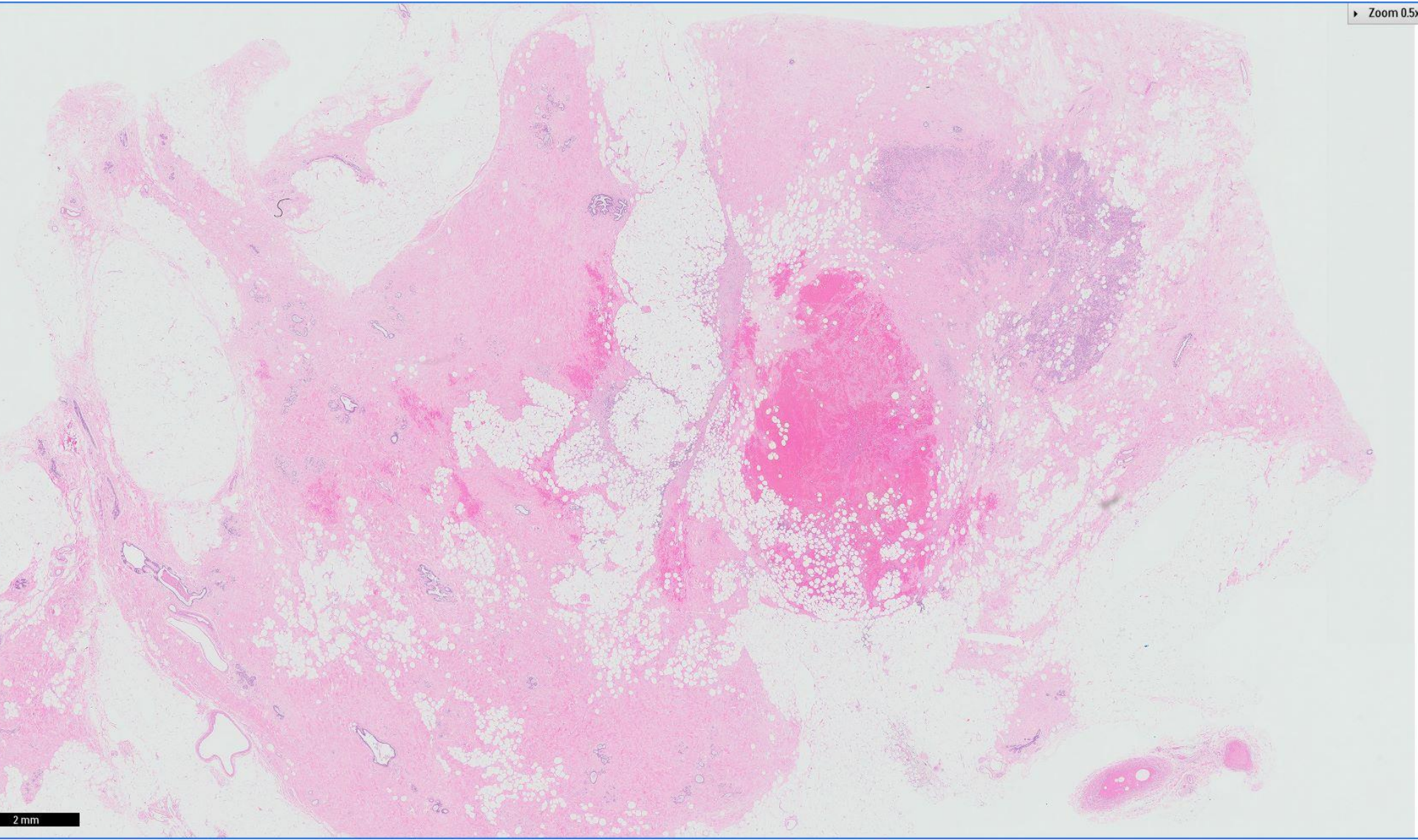
# Case 32

40 year old woman with a right breast lump.

There was a past history of right breast invasive carcinoma 7 years ago, status post wide excision and sentinel lymph node biopsy, with postoperative radiation.

Core biopsy of current right breast lump confirmed cancer, followed by right mastectomy and axillary clearance.

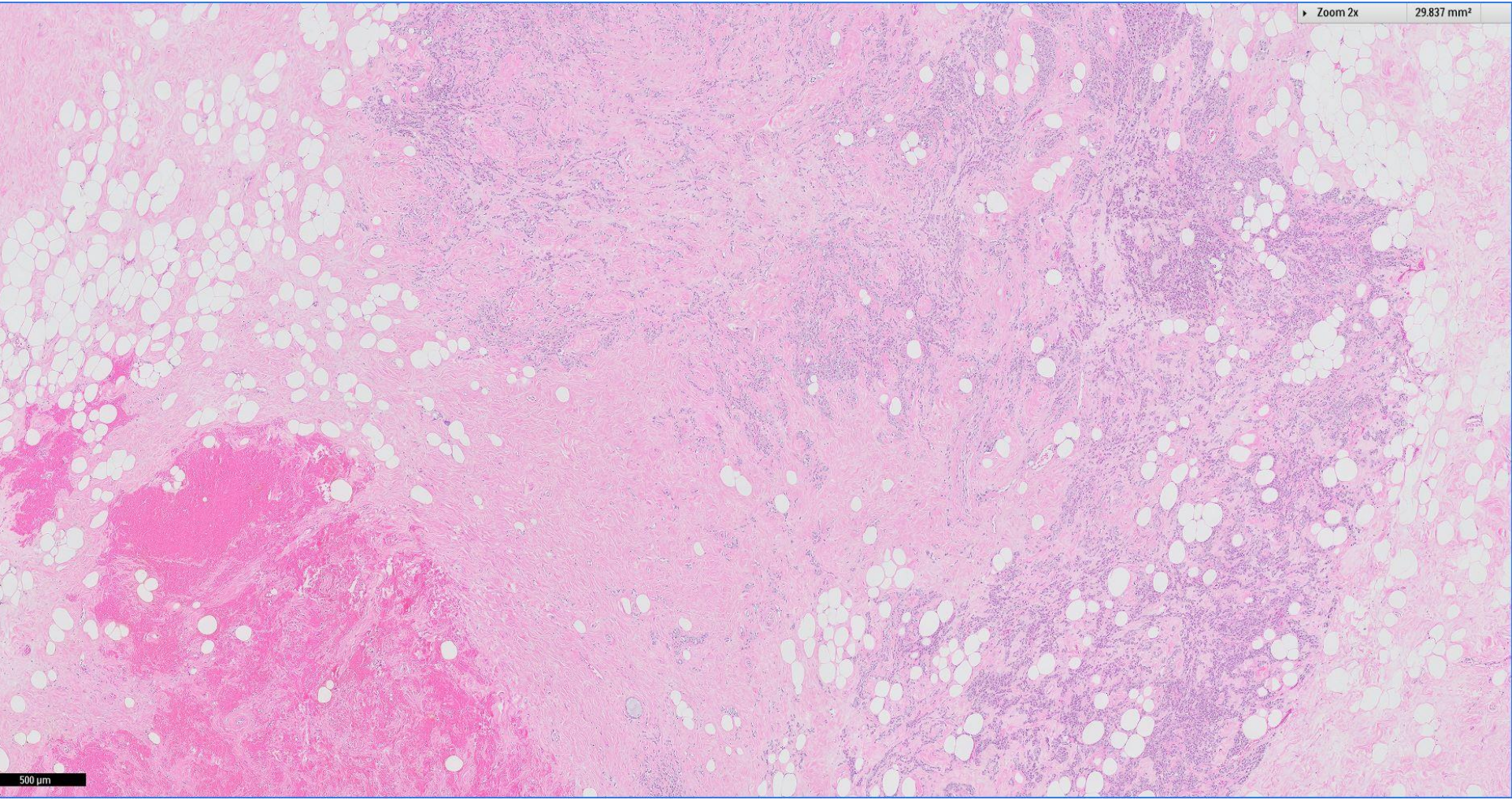






▶ Zoom 2x

29.837 mm<sup>2</sup>

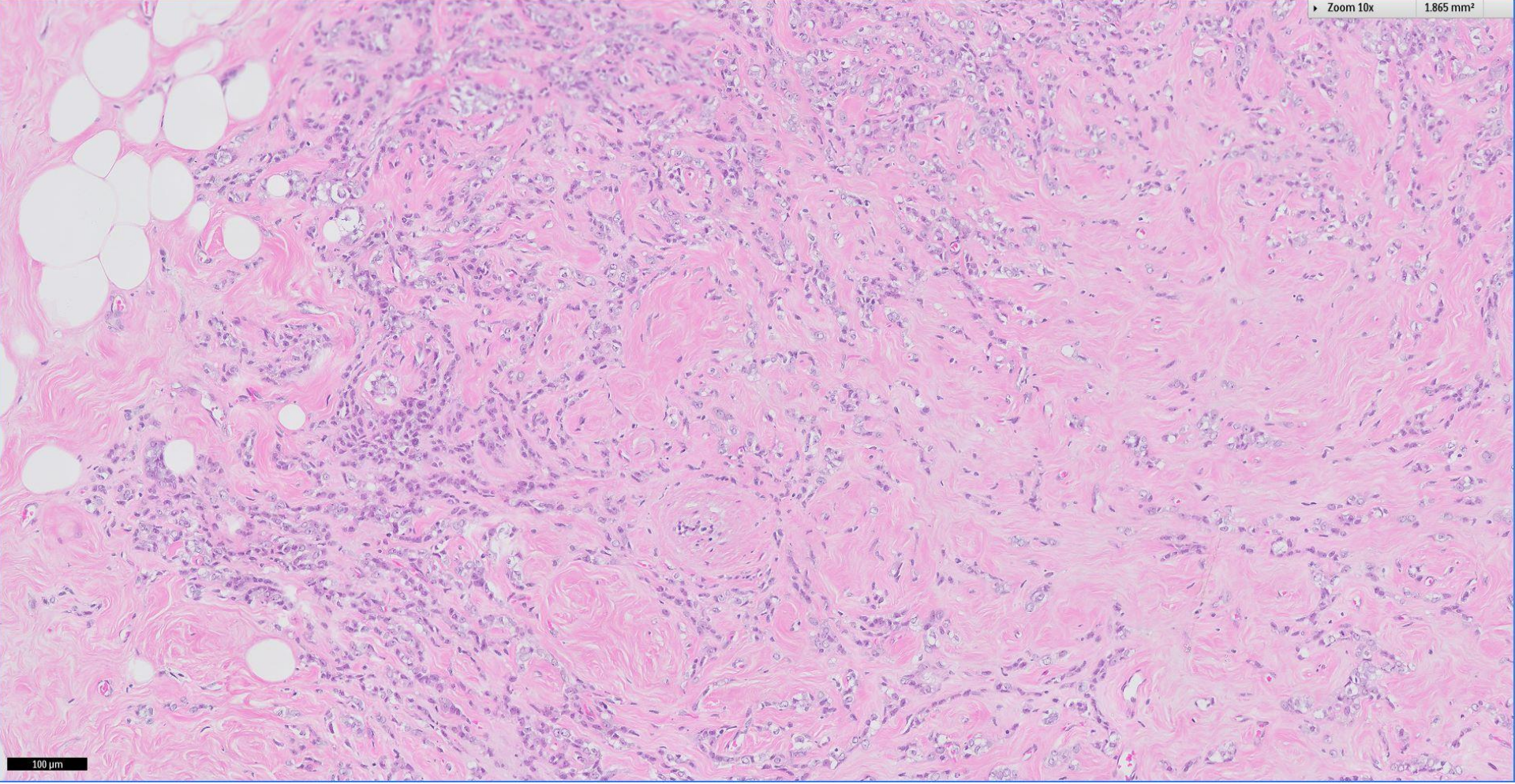


500  $\mu$ m



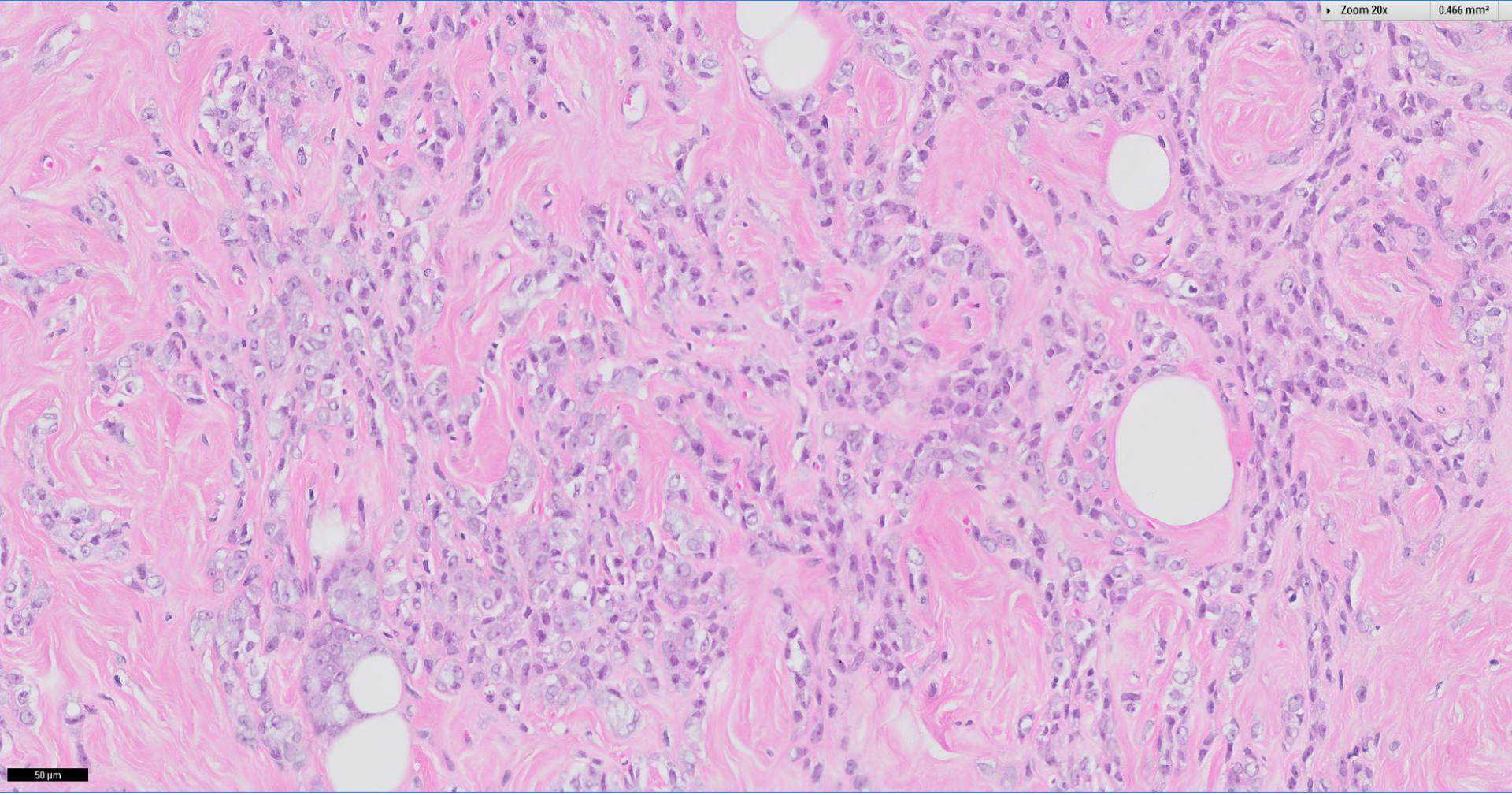
Zoom 10x

1.865 mm<sup>2</sup>



100  $\mu$ m

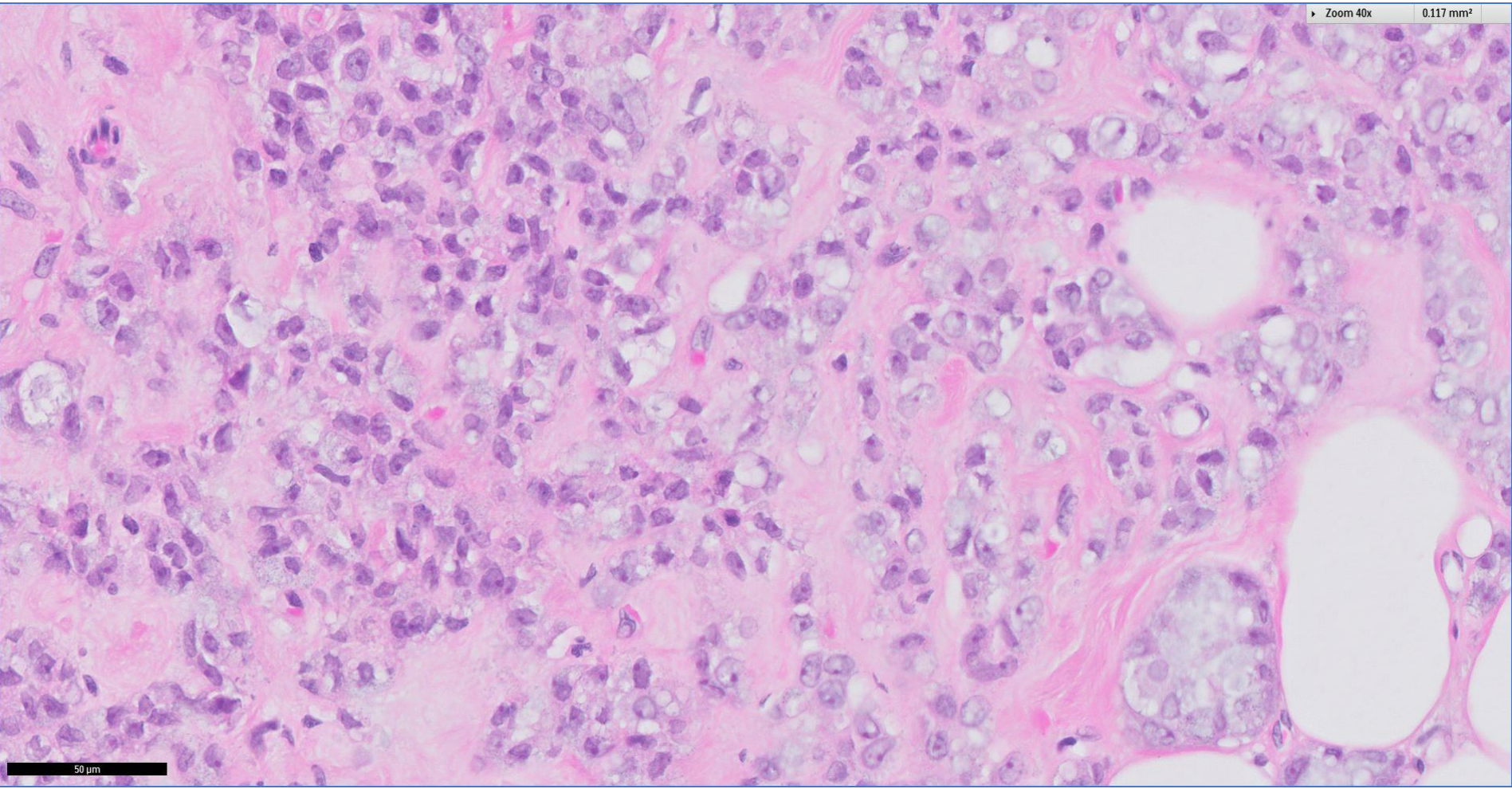






Zoom 40x

0.117 mm<sup>2</sup>



50 μm

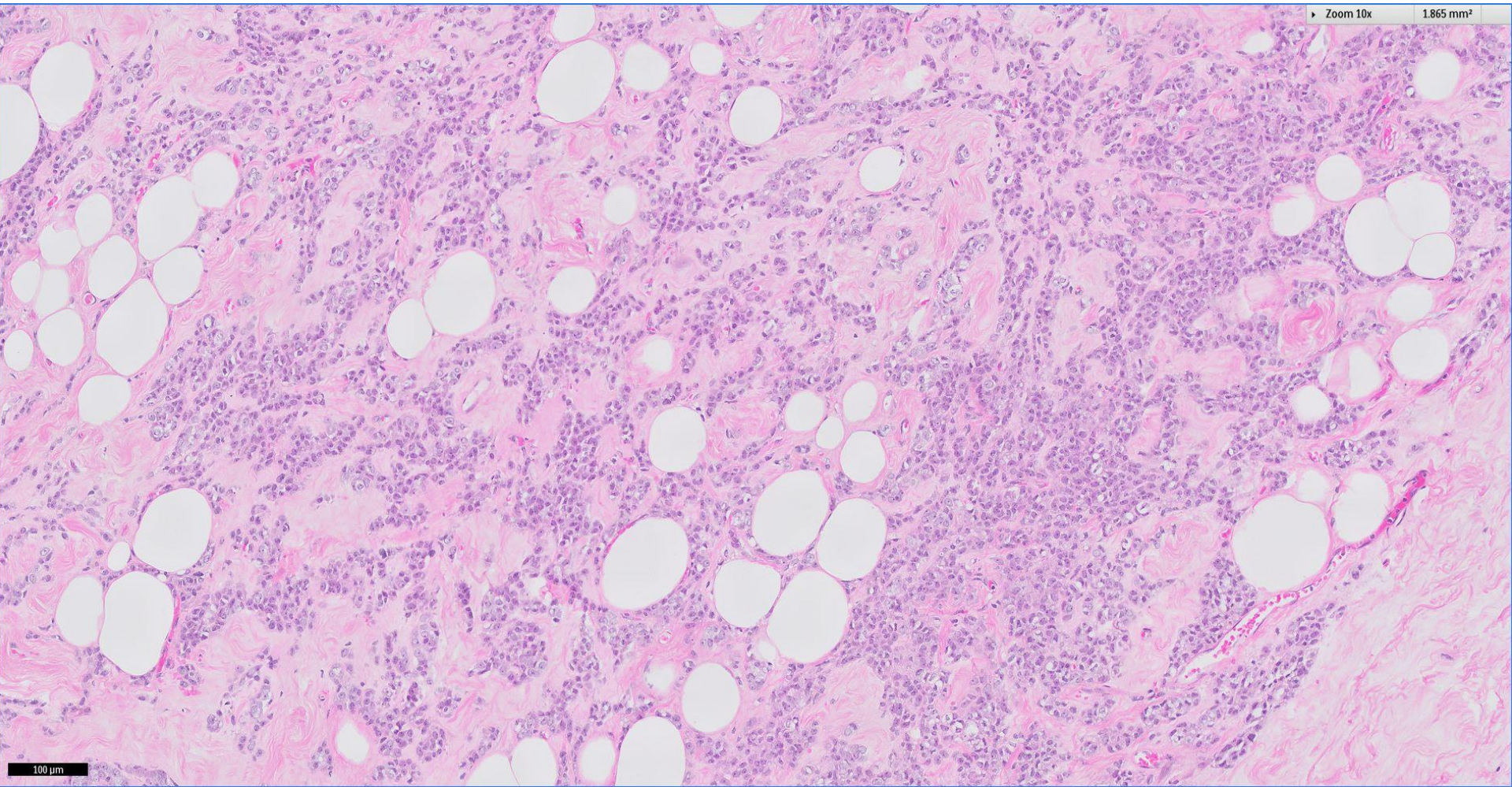






Zoom 10x

1.865 mm<sup>2</sup>

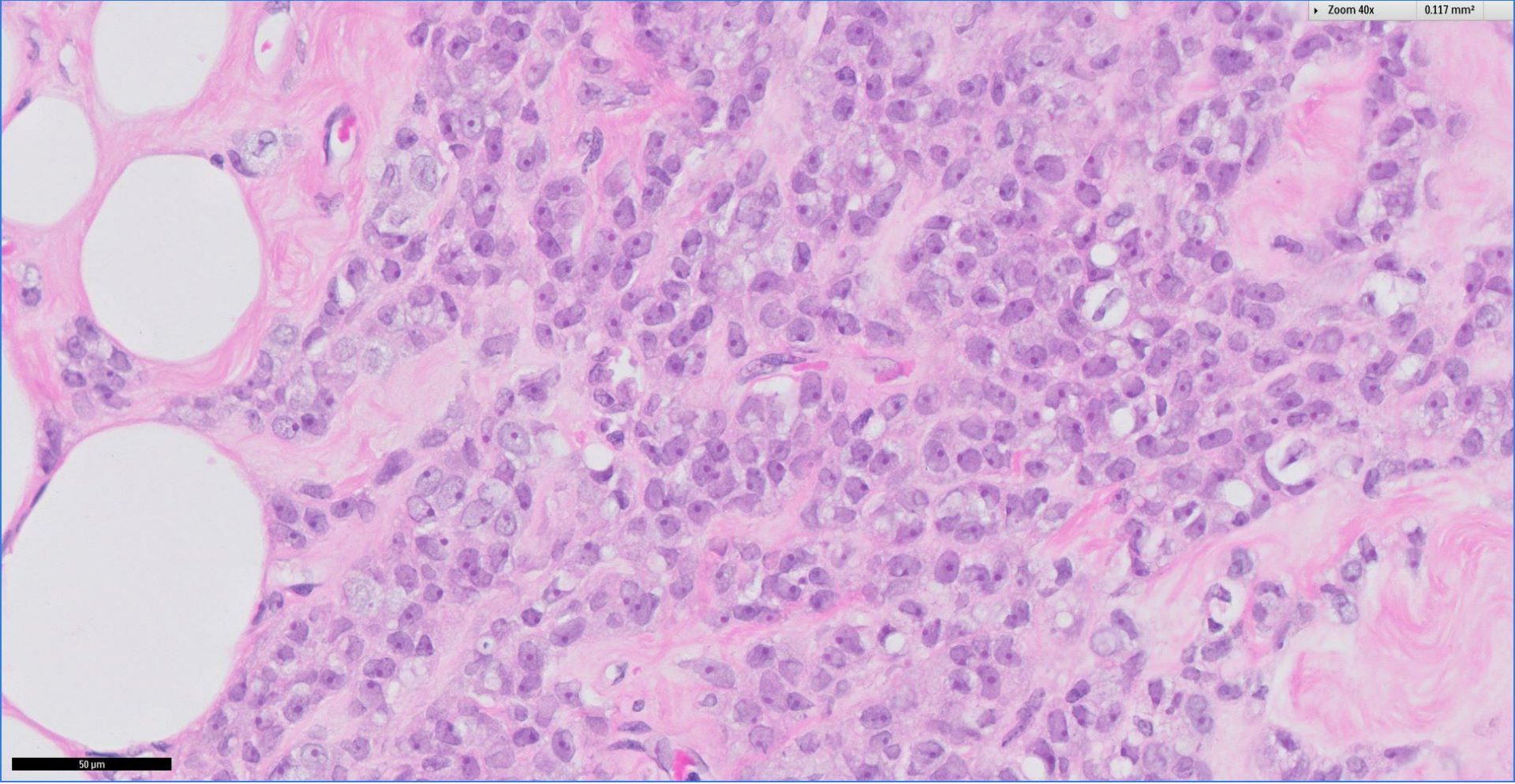


100  $\mu$ m



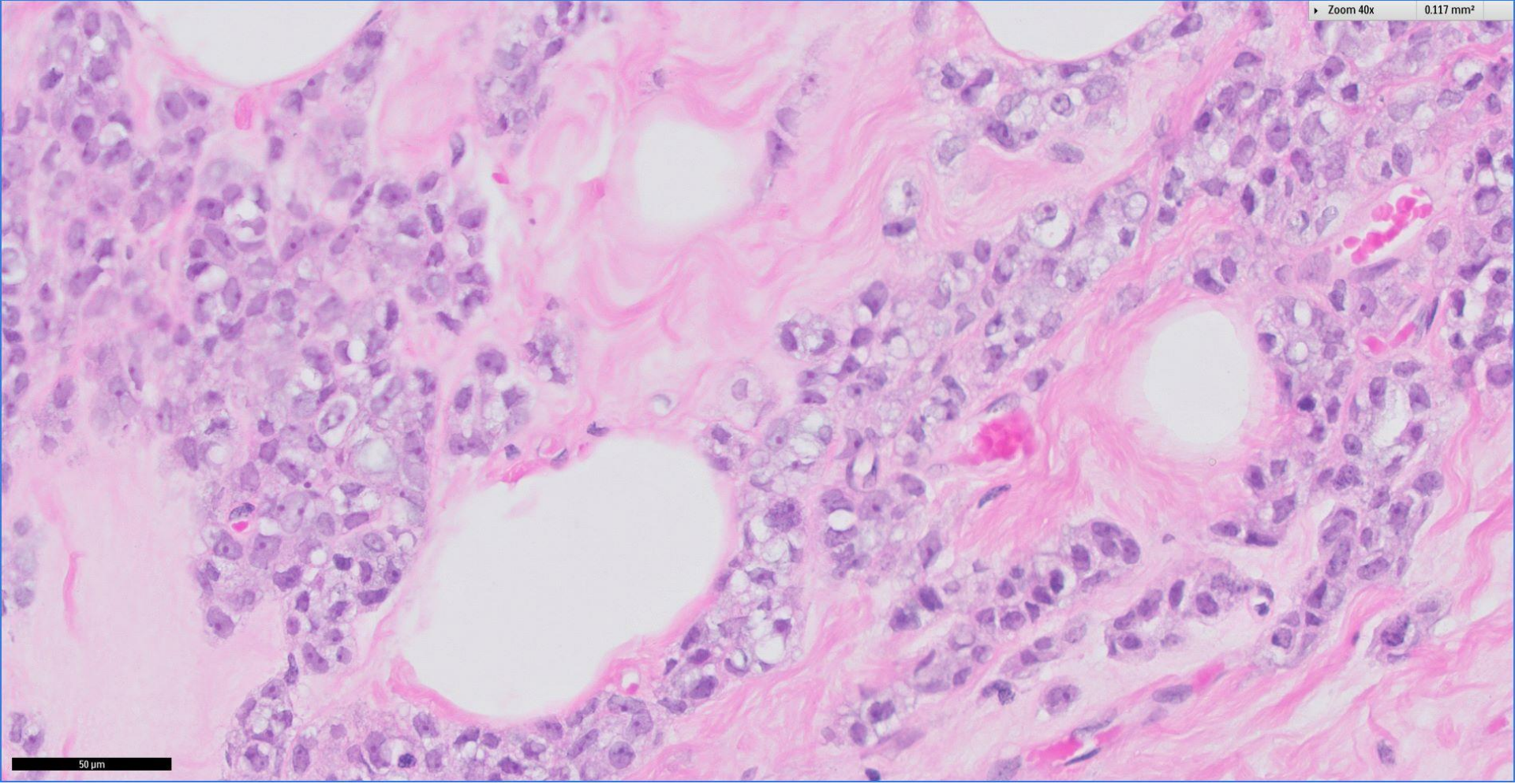
Zoom 40x

0.117 mm<sup>2</sup>



50 μm



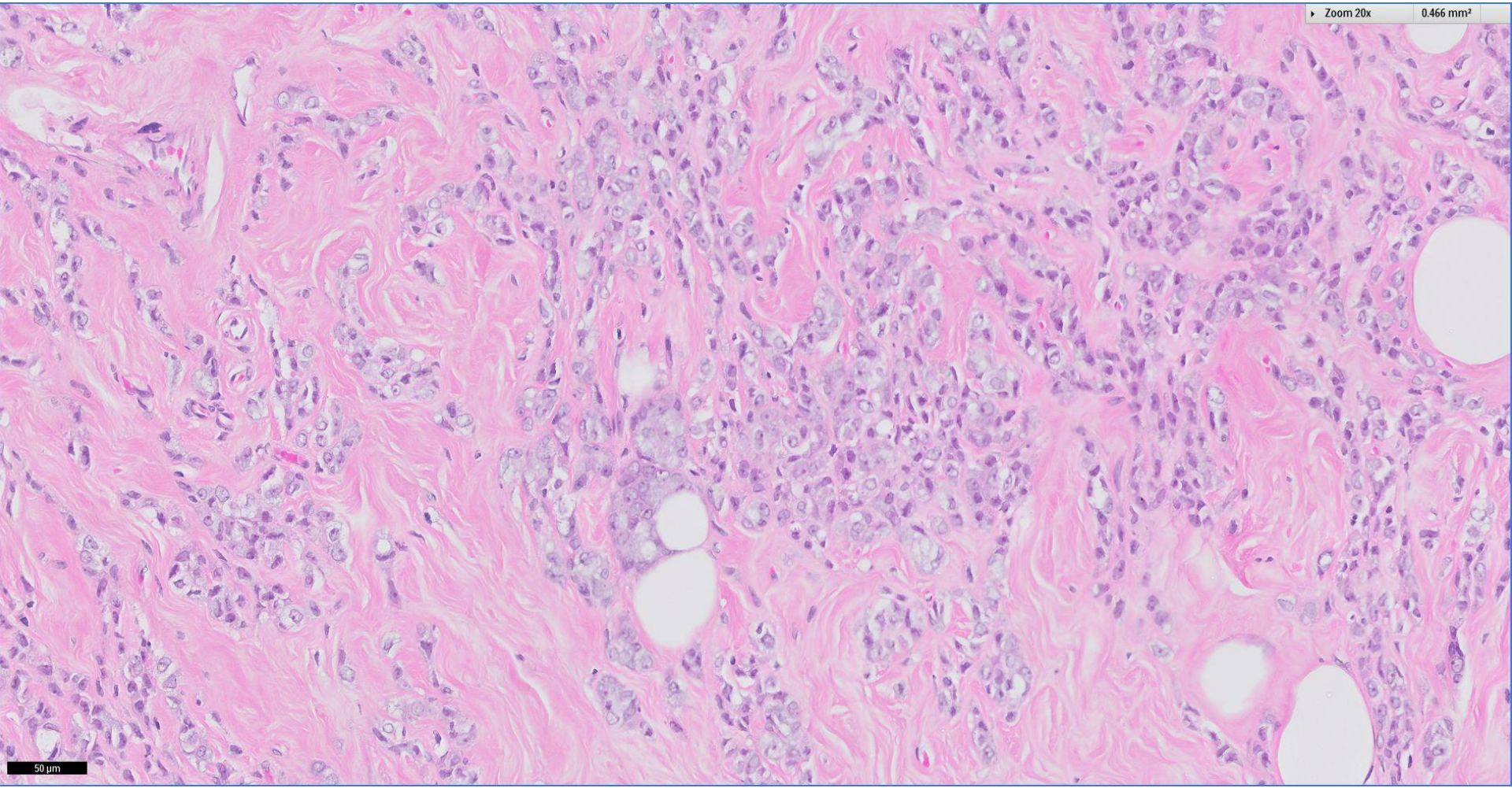


50  $\mu$ m



Zoom 20x

0.466 mm<sup>2</sup>

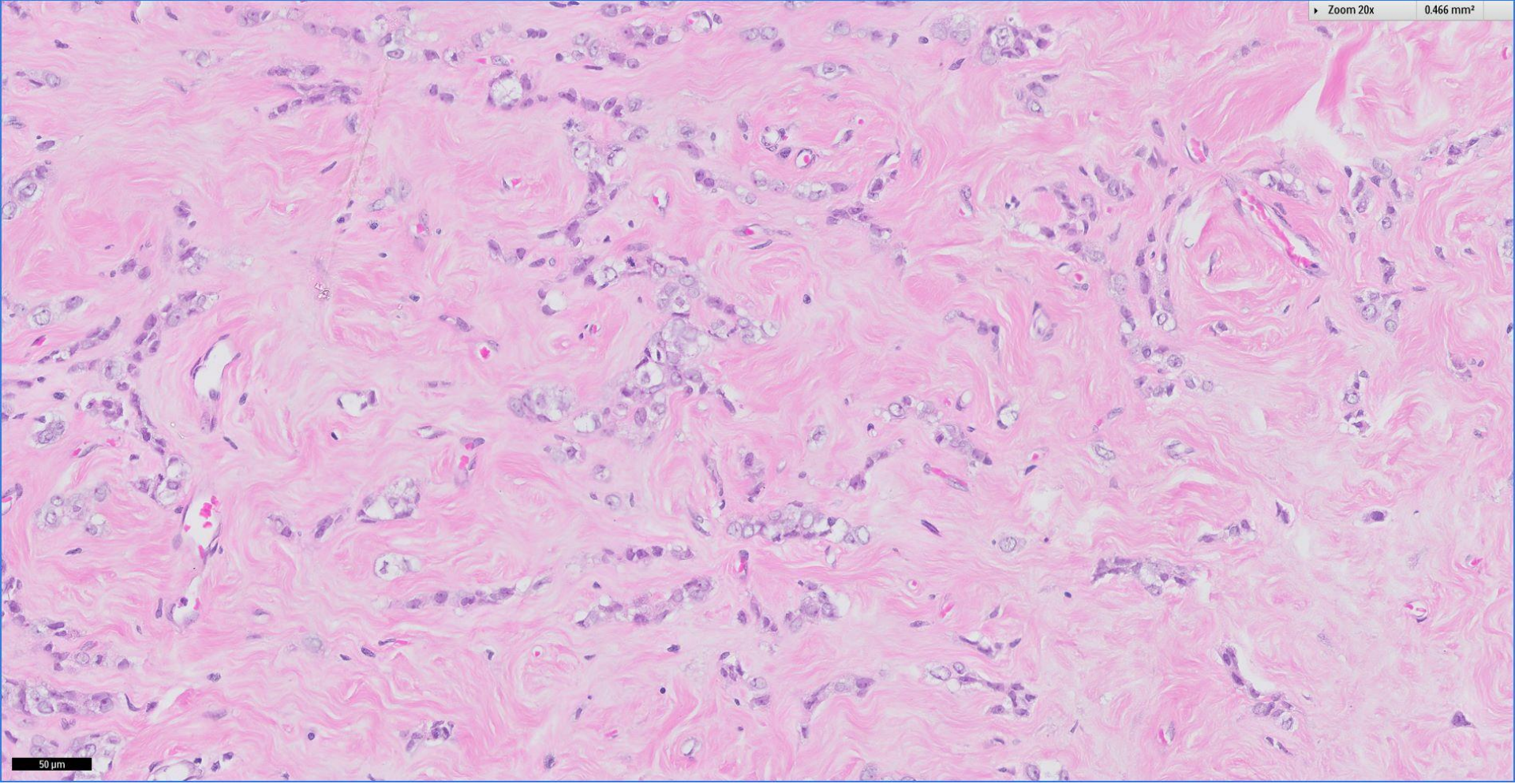


50  $\mu$ m



Zoom 20x

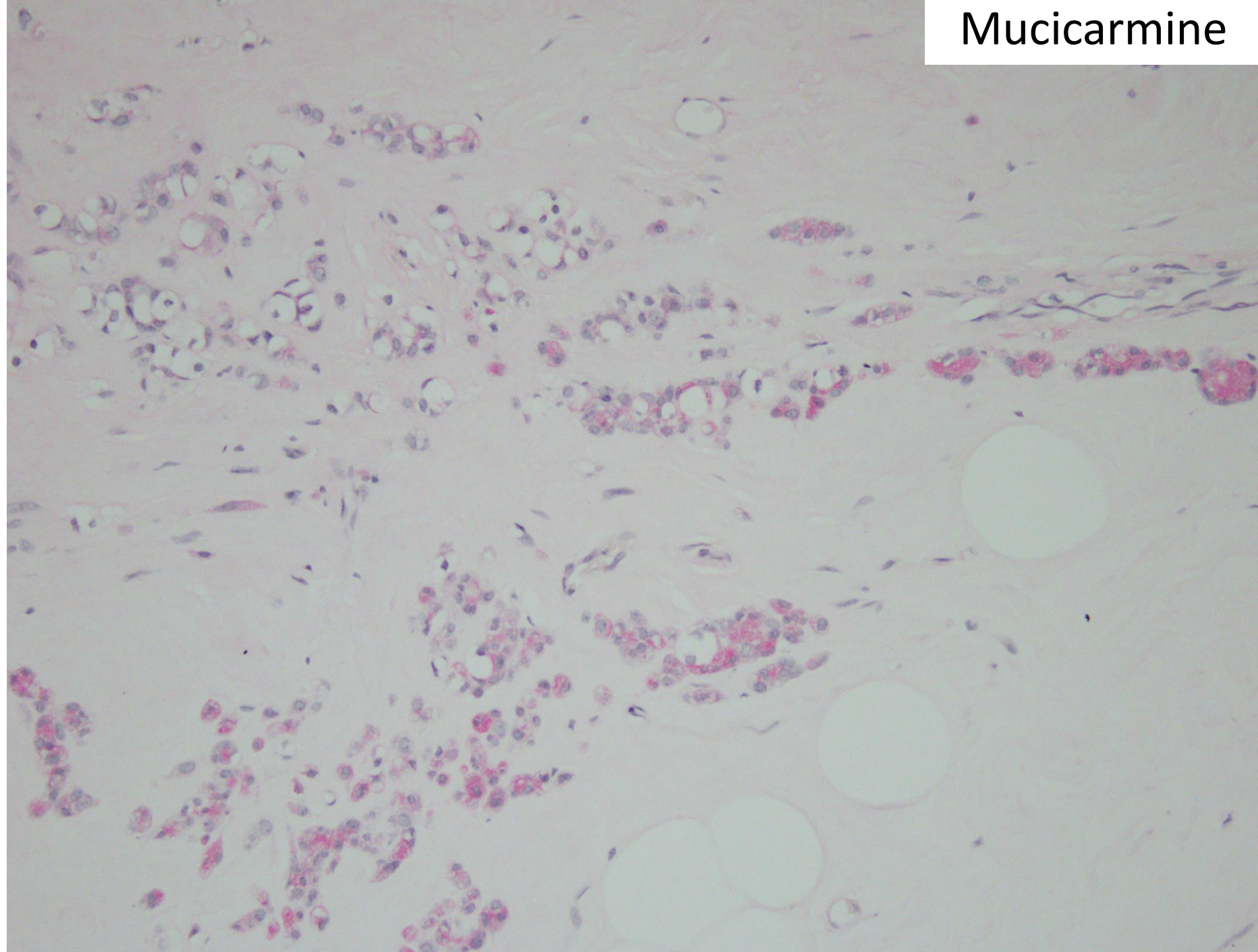
0.466 mm<sup>2</sup>



50 μm

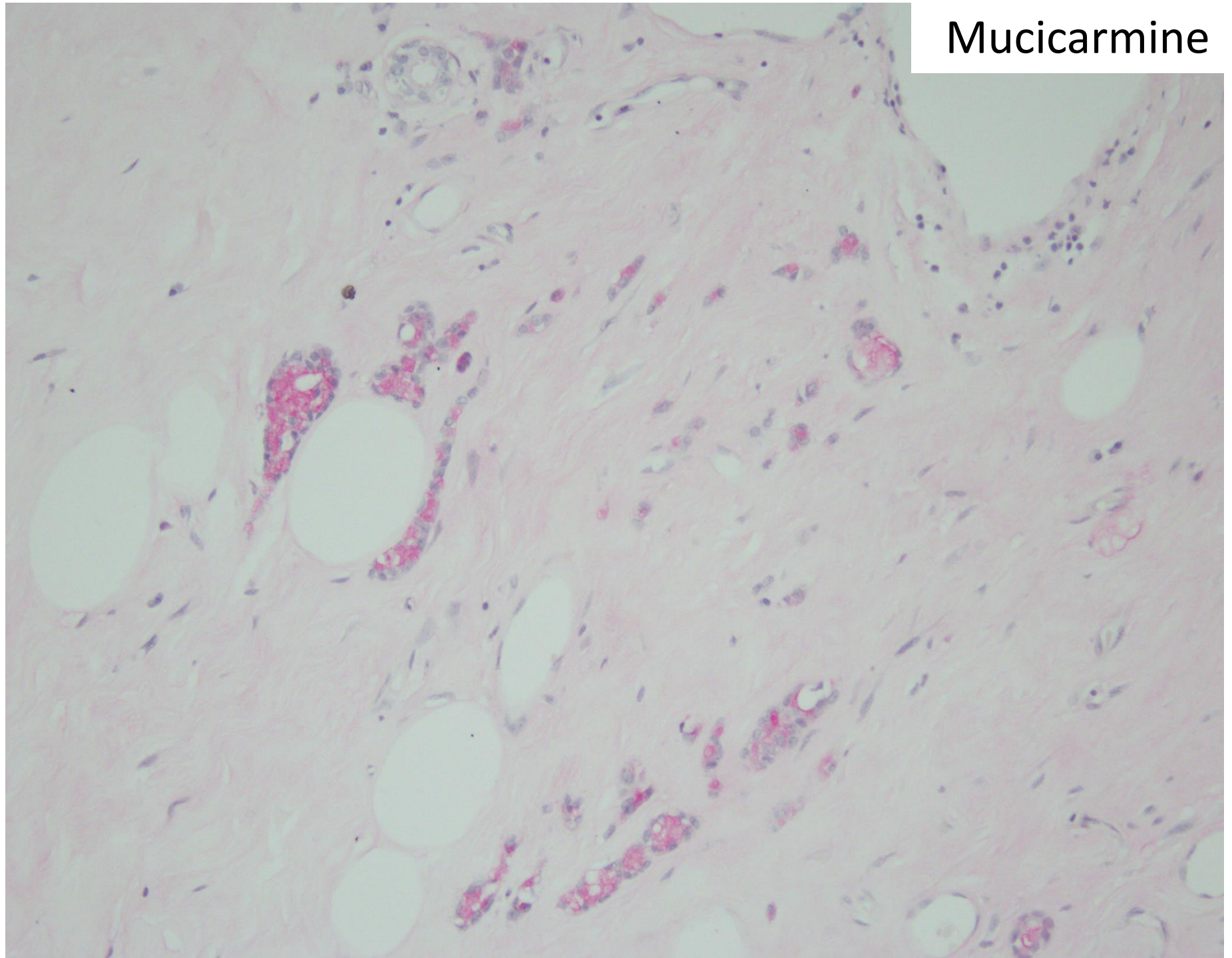


Mucicarmine



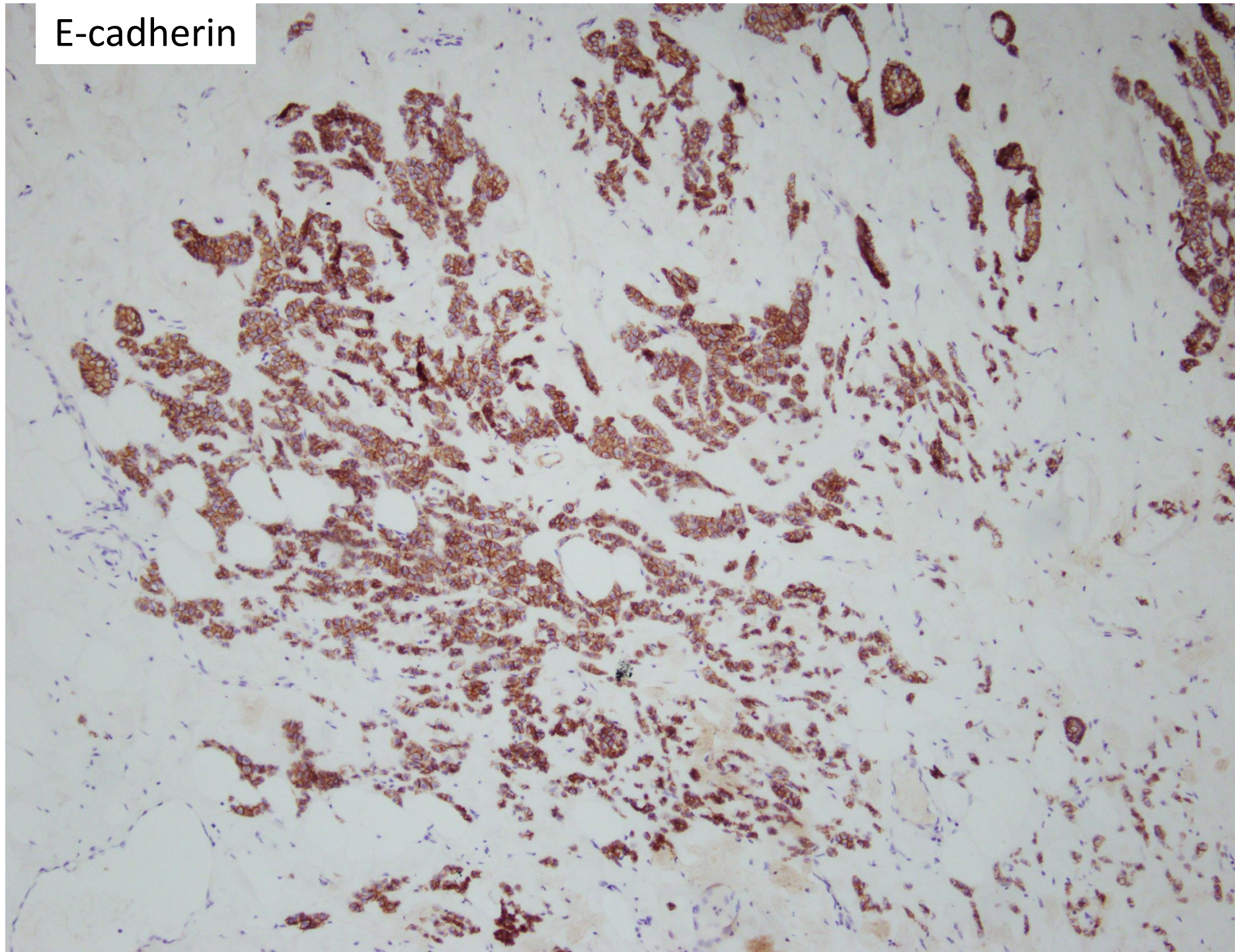


Mucicarmine



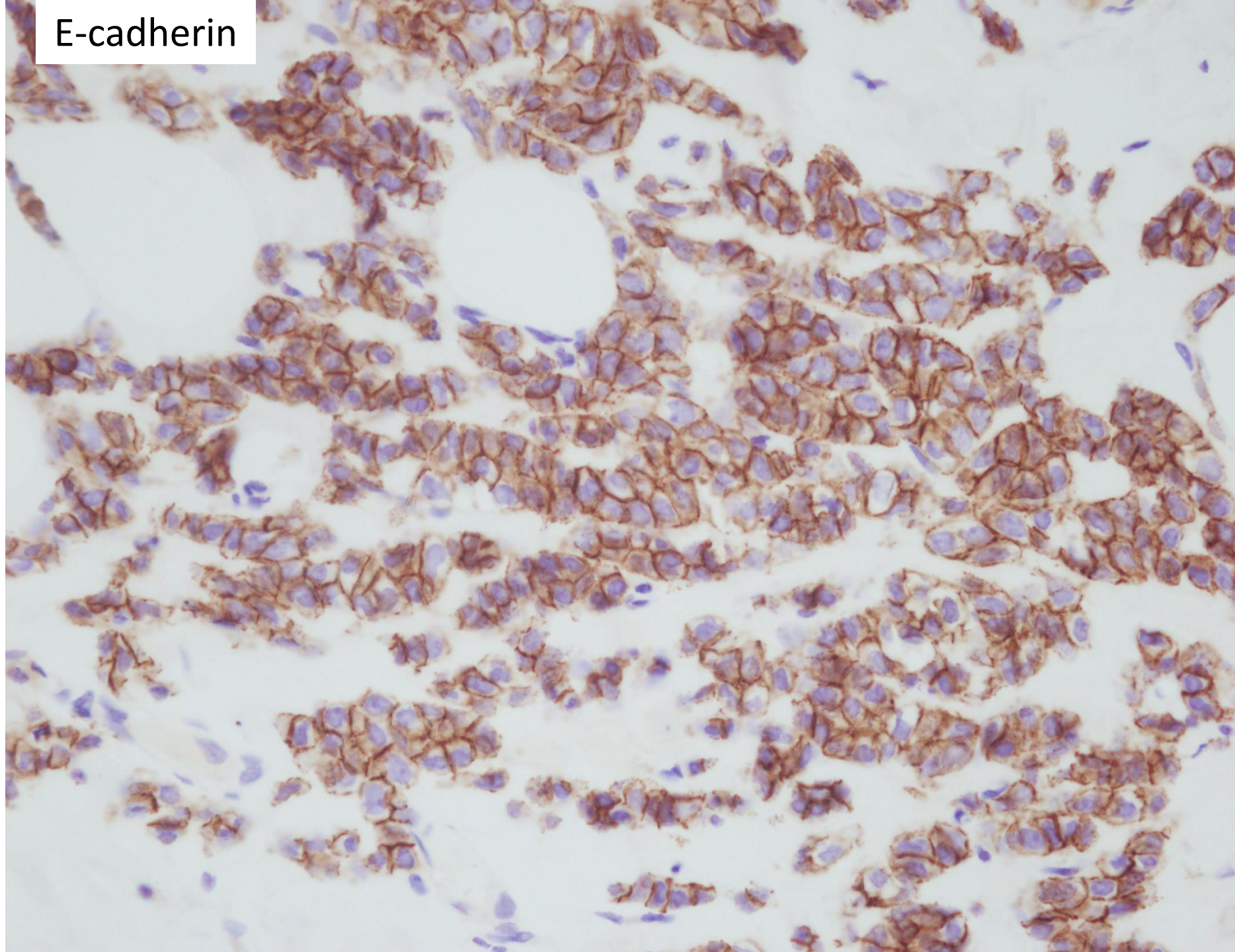


E-cadherin





E-cadherin





Right breast, mastectomy:  
Invasive ductal carcinoma, grade 3  
*(cytoplasmic mucin present)*





## Spectrum of breast lesions with mucin

- ▶ With extracellular mucin
  - Fibrocystic change with luminal mucin
  - Mucocele-like lesion (MLL), benign
  - MLL with atypical ductal hyperplasia
  - MLL with ductal carcinoma in situ
  - MLL with invasive mucinous carcinoma
  - Mucinous cystadenocarcinoma
  - Invasive mucinous carcinoma
  - Mixed mucinous-ductal carcinoma
- ▶ With intracellular mucin
  - Mucinous metaplasia
  - Lobular neoplasia
  - Ductal carcinoma in situ
  - Invasive lobular carcinoma
  - Invasive ductal carcinoma
- ▶ With stromal mucin
  - Fibroadenoma
  - Phyllodes tumour
  - Pleomorphic adenoma
  - Adenoid cystic carcinoma (also has extracellular mucin)
  - Matrix producing metaplastic carcinoma
  - Squamous cell carcinoma with prominent myxoid stroma
- ▶ Rare entities
  - Nodular mucinosis
  - Mucoepidermoid carcinoma
  - Metastases
- ▶ Mucin-like lesion
  - Injected foreign substance



 Breast  
Pathology  
Course 2014

