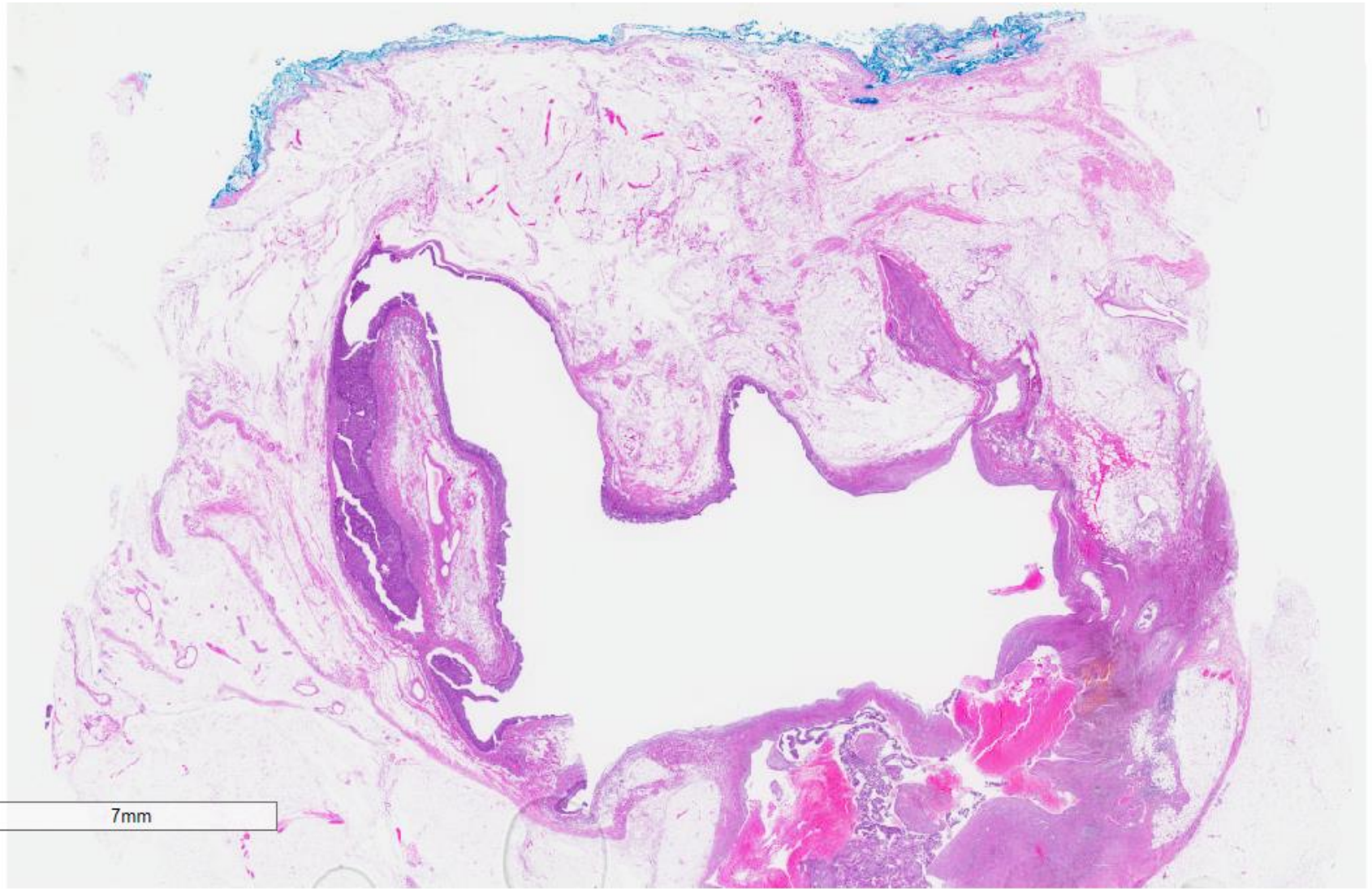
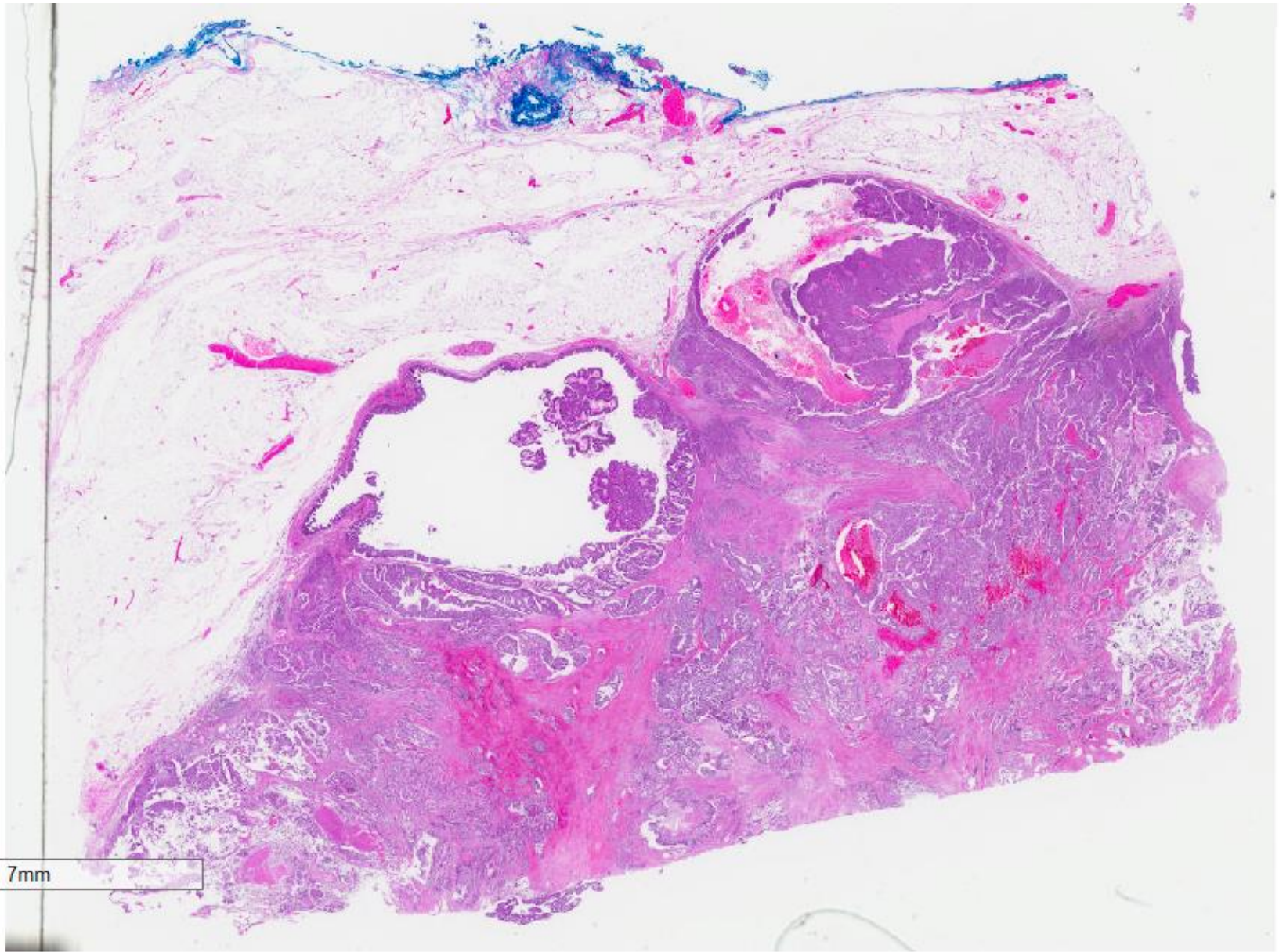


## Case 46

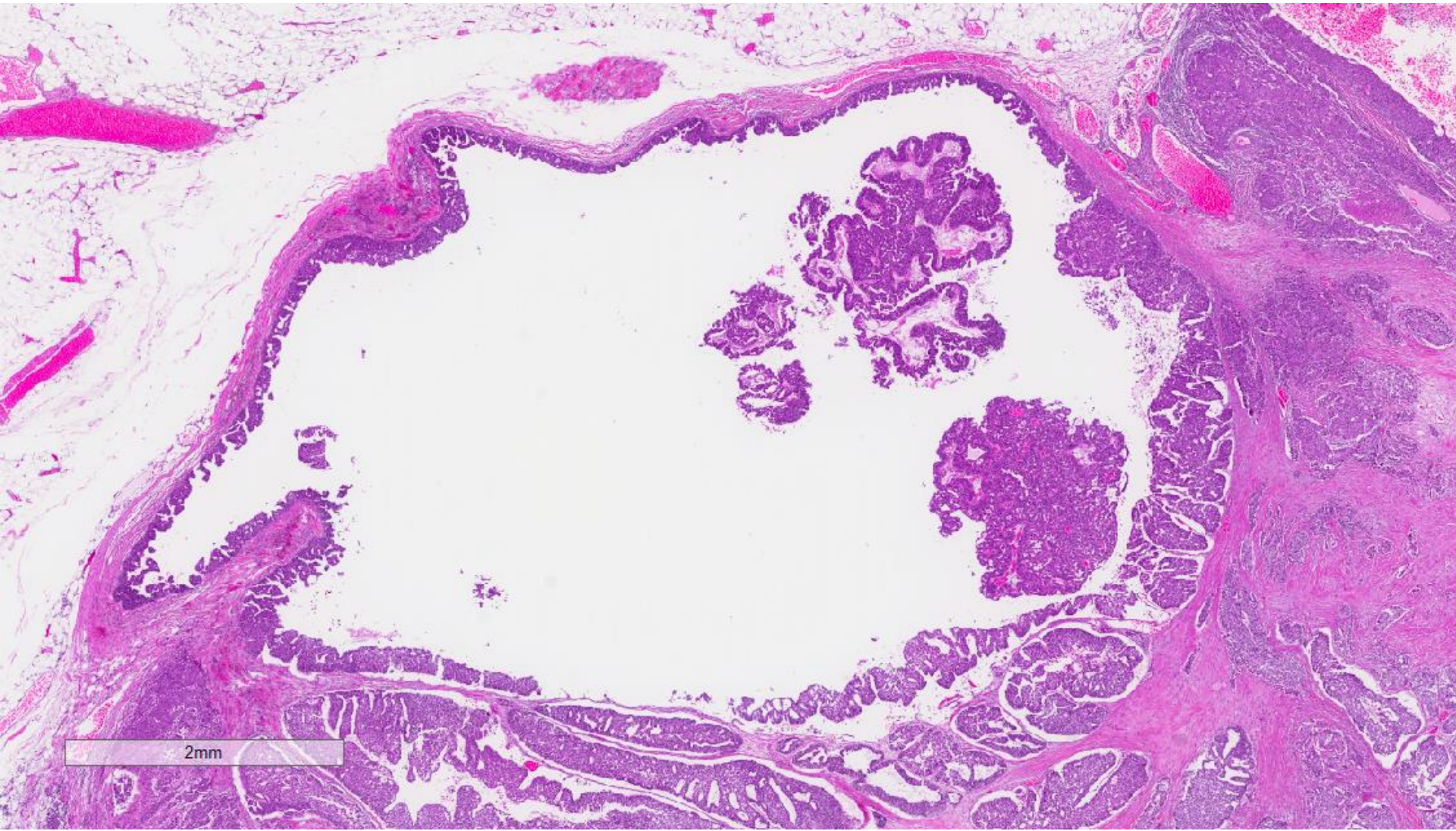
64 year old man underwent right mastectomy and axillary clearance for an 8 cm mass.



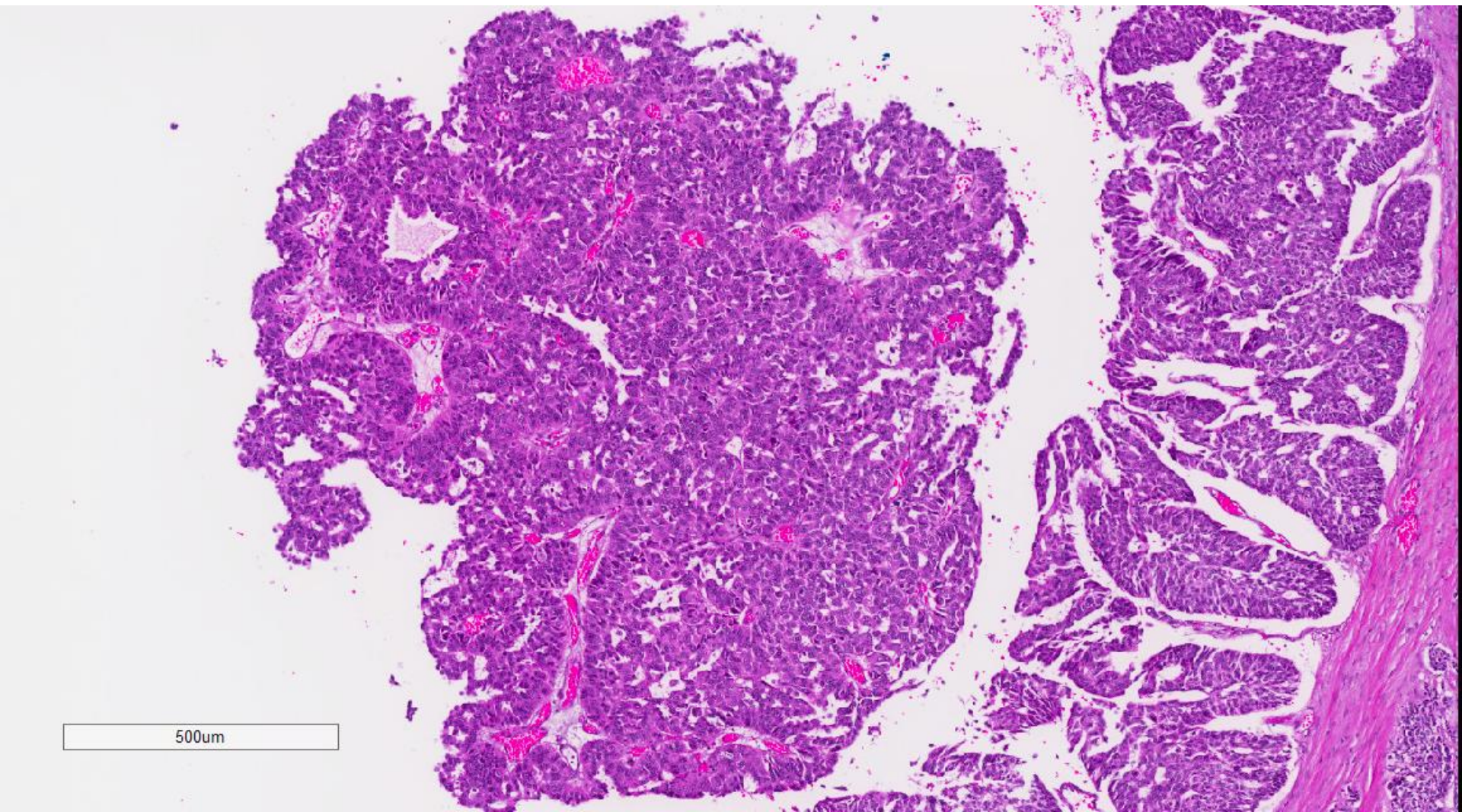
7mm



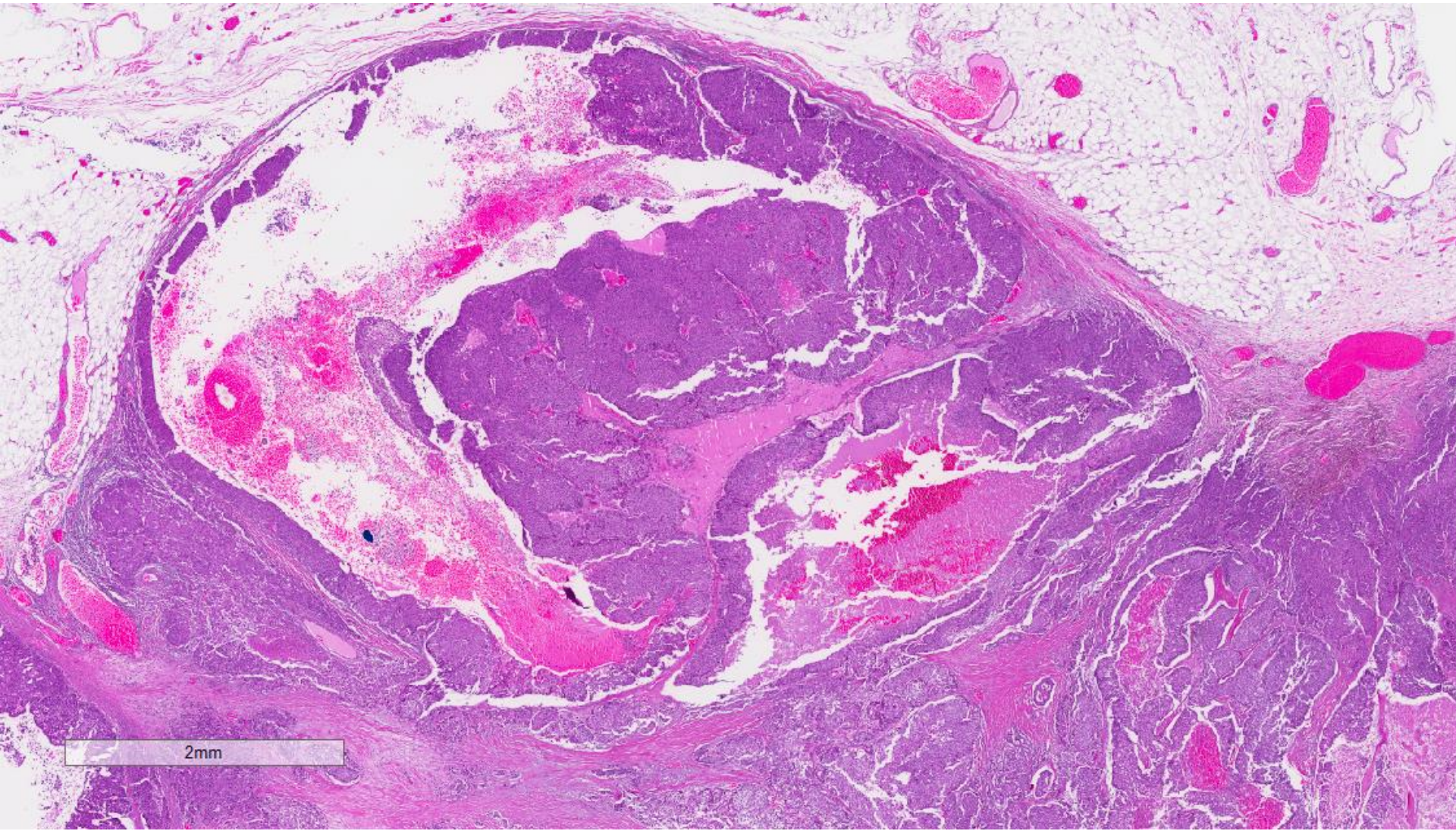
7mm



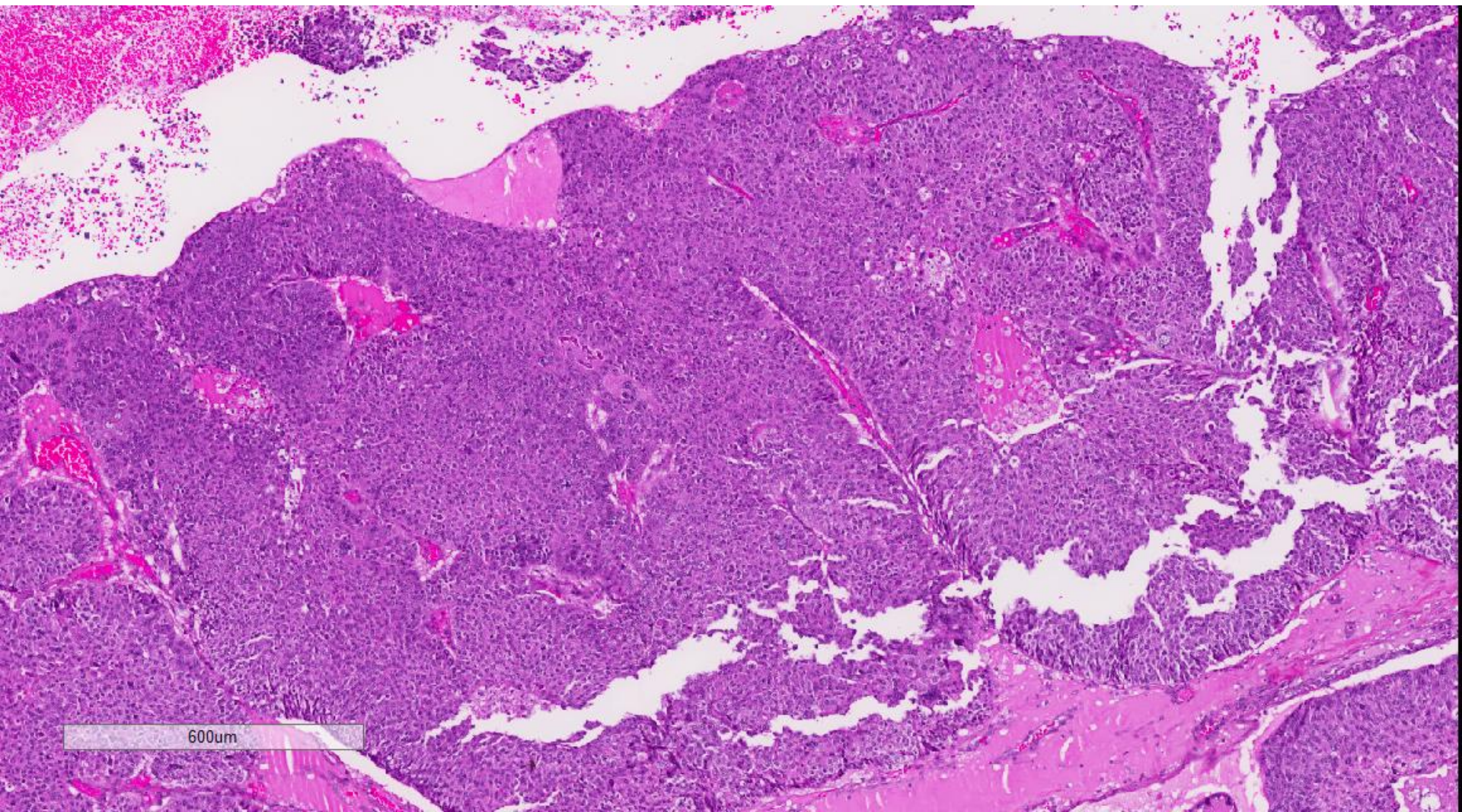
2mm



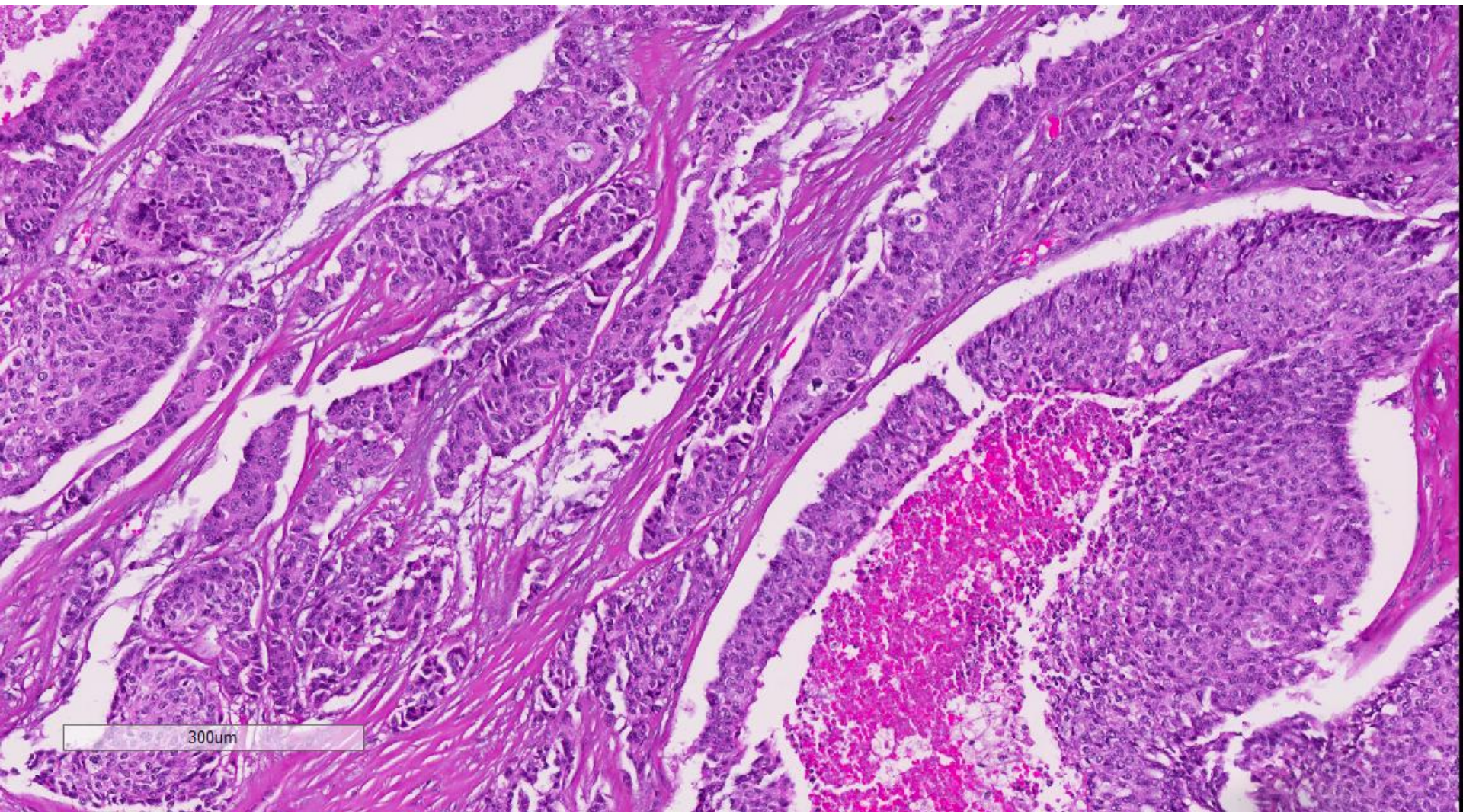
500um



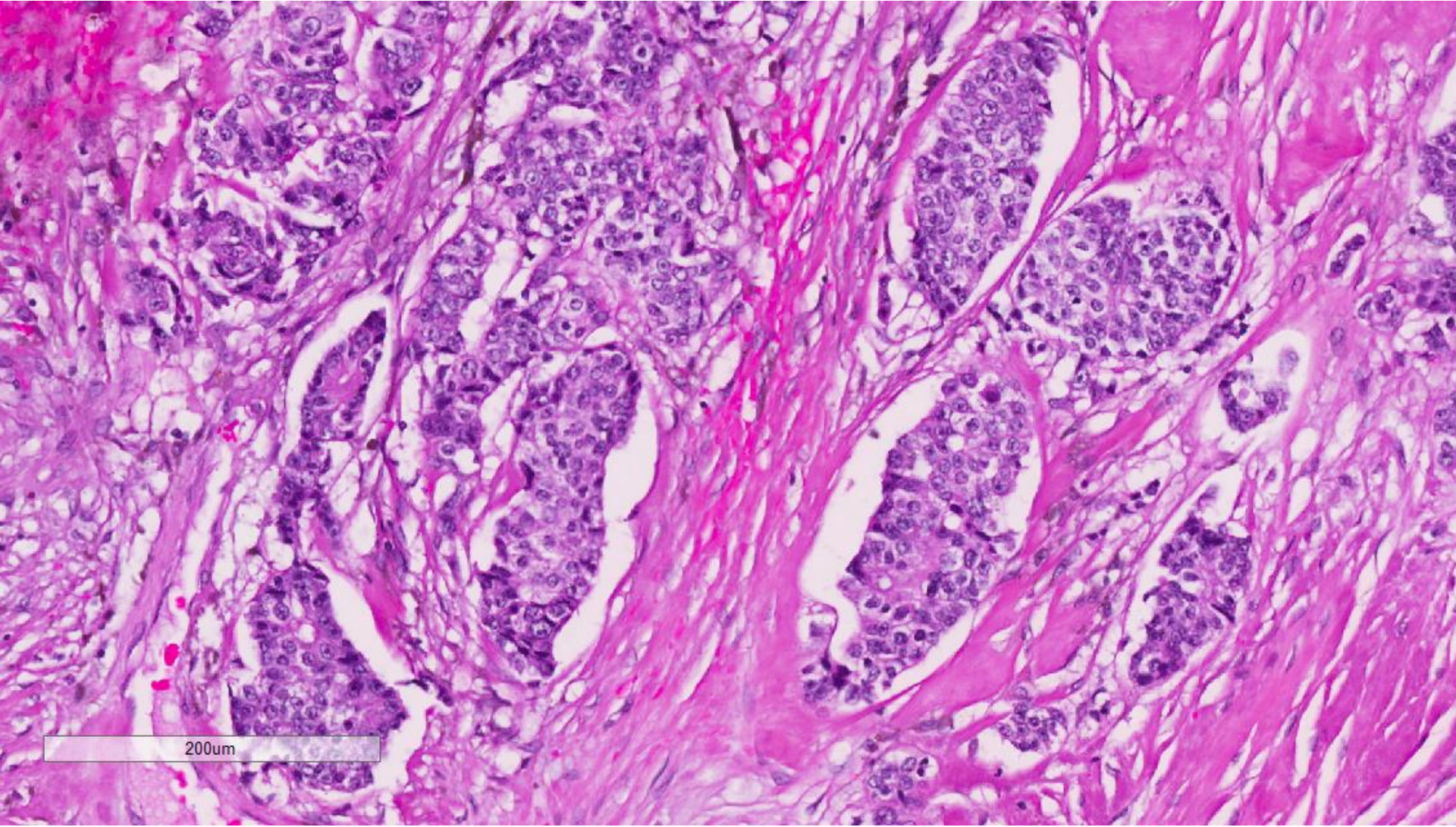
2mm

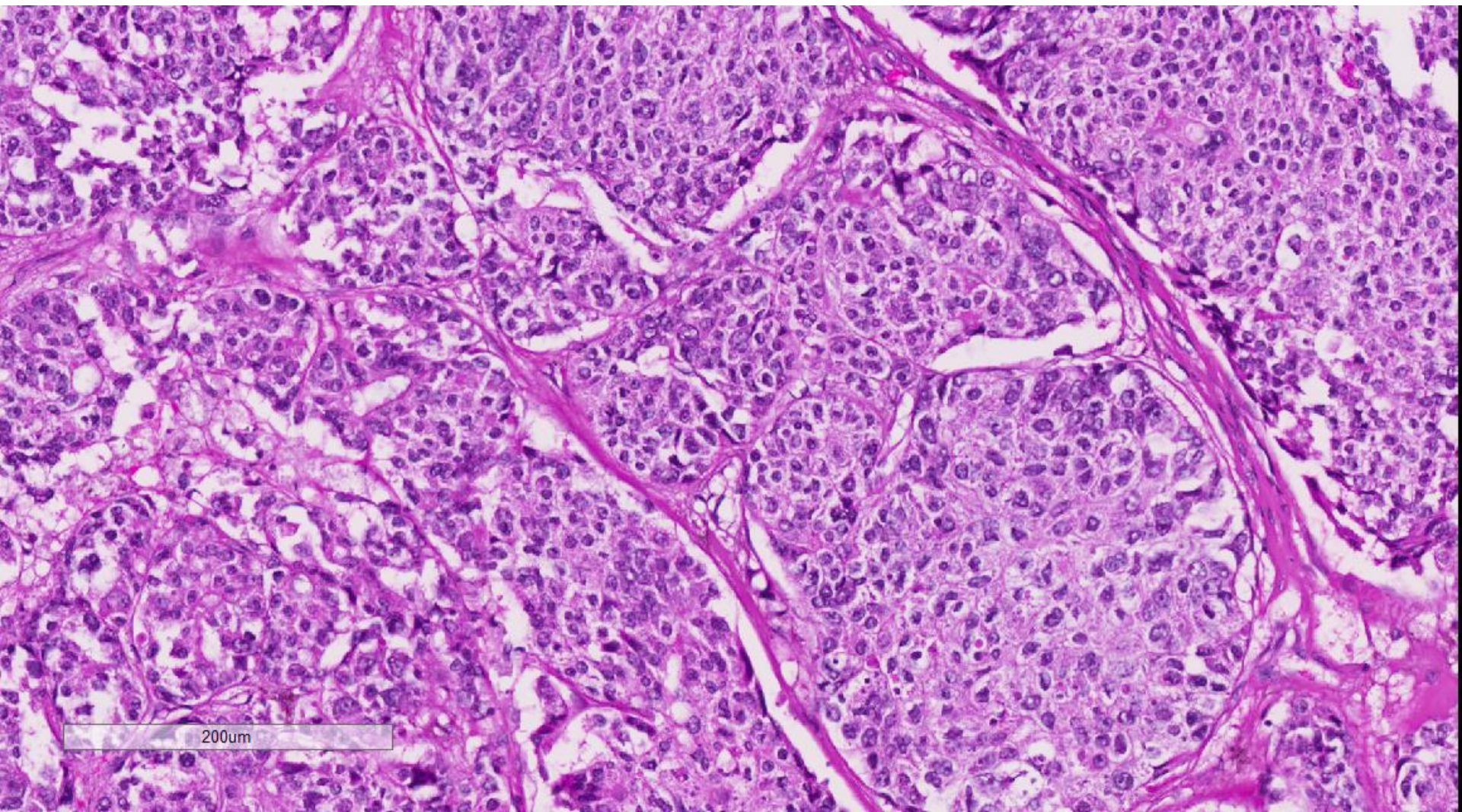


600um



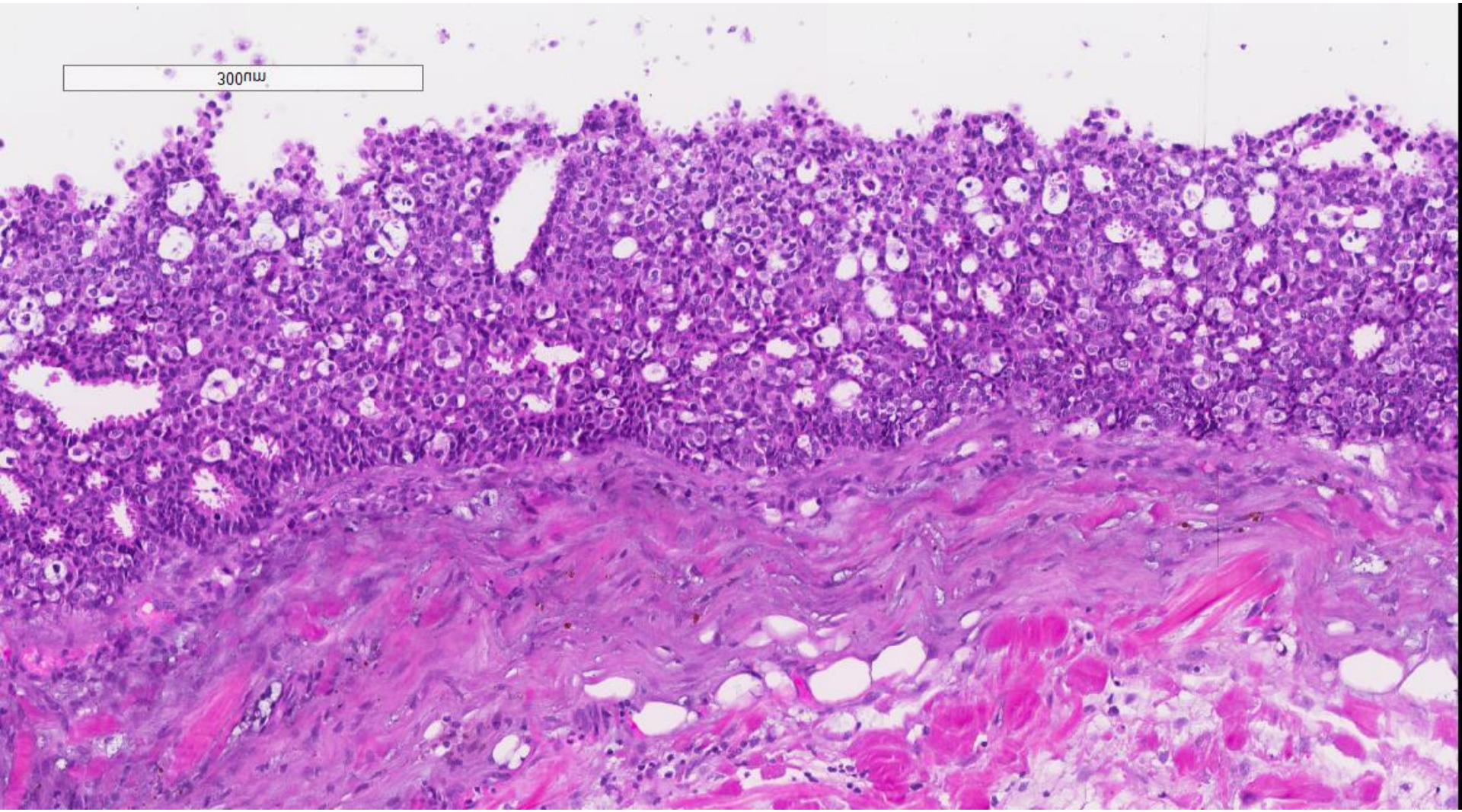






200um

300µm



# Immunohistochemistry

- ER positive, PR positive, cerbB2 negative.
- Negative staining for CK5/6 and p63.
- Synaptophysin focally positive.

# Invasive carcinoma with solid-papillary and ductal features, grade 1, 80 mm