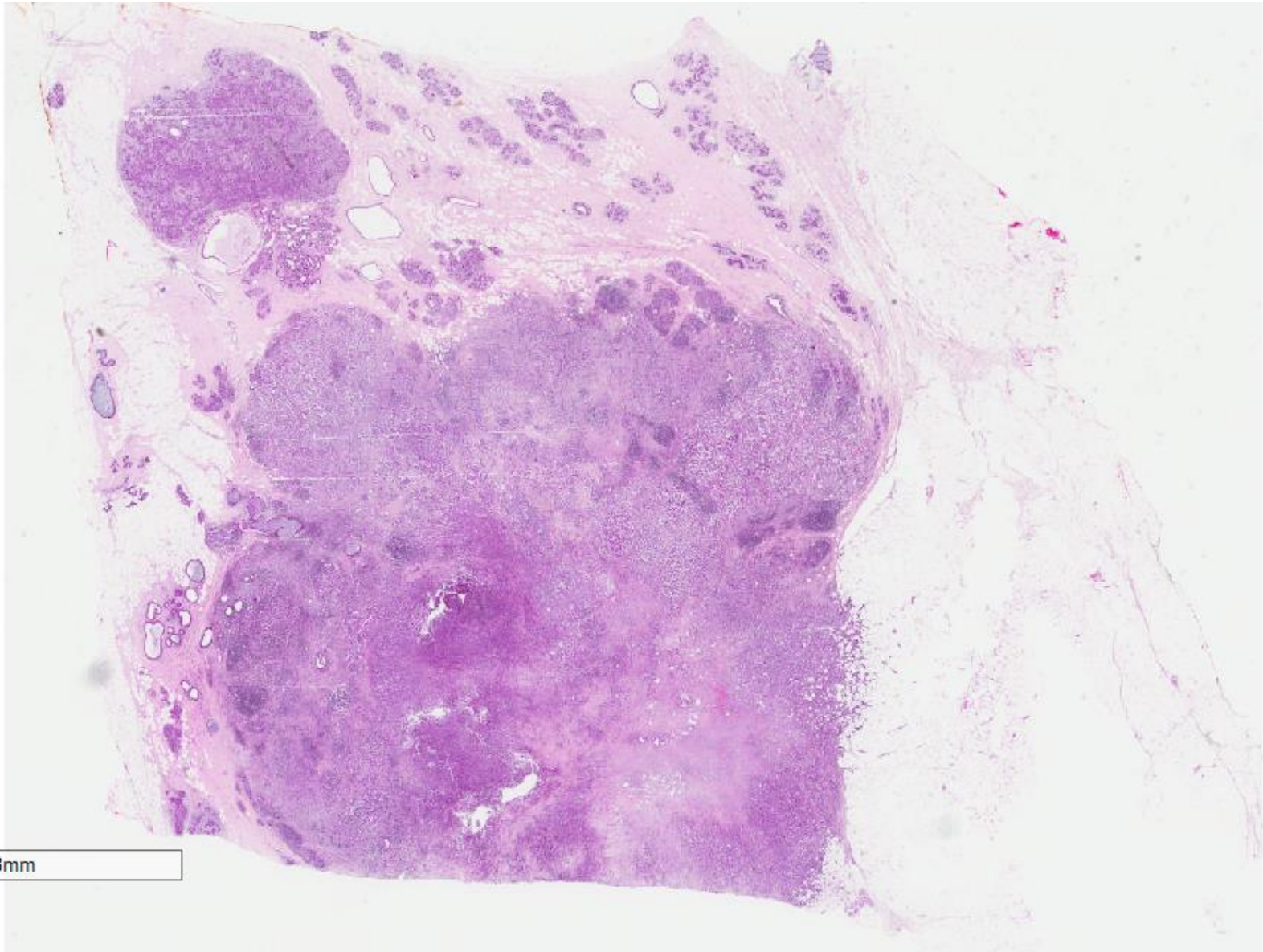
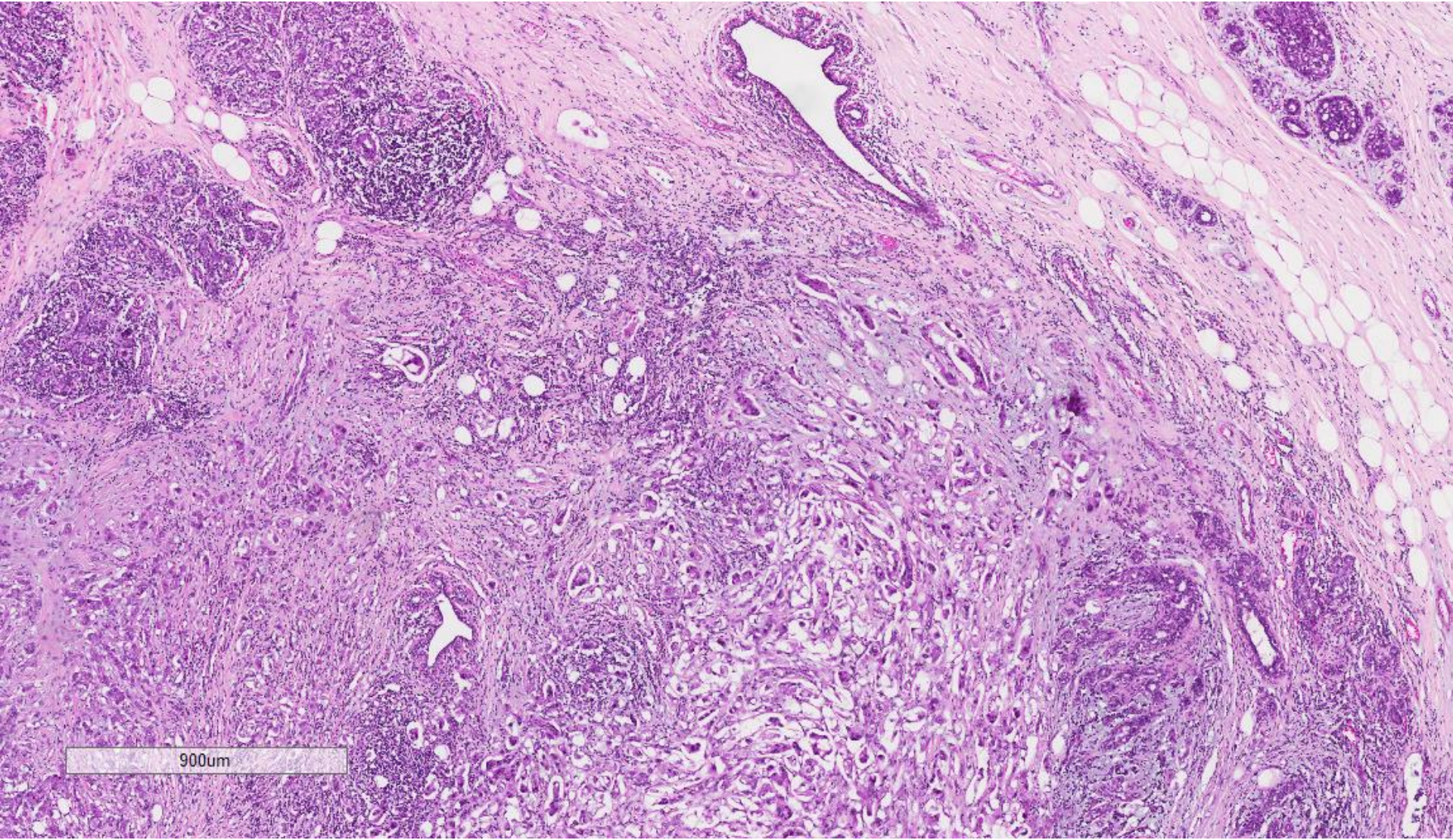


## Case 43

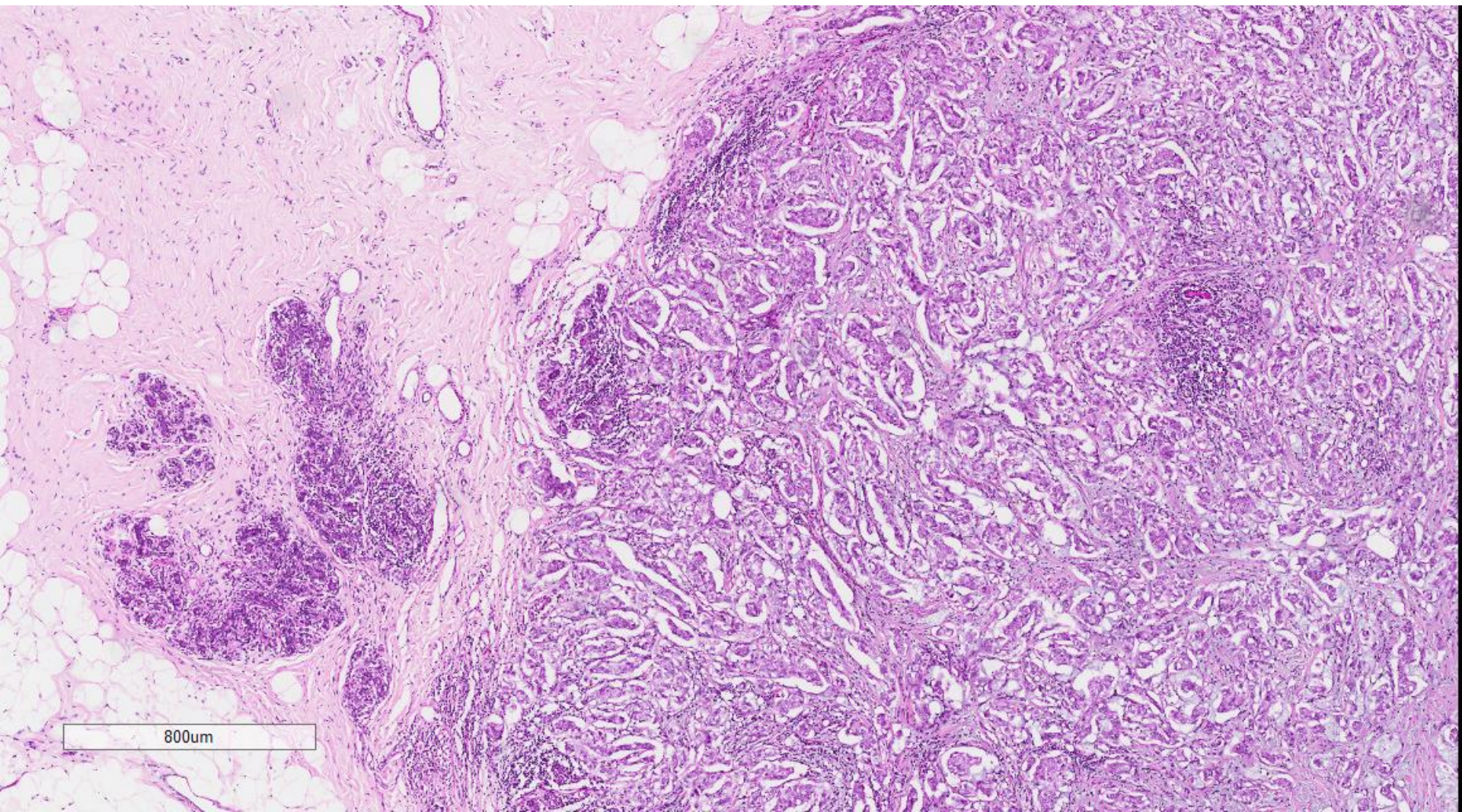
Left mastectomy from a 39 year old lady.



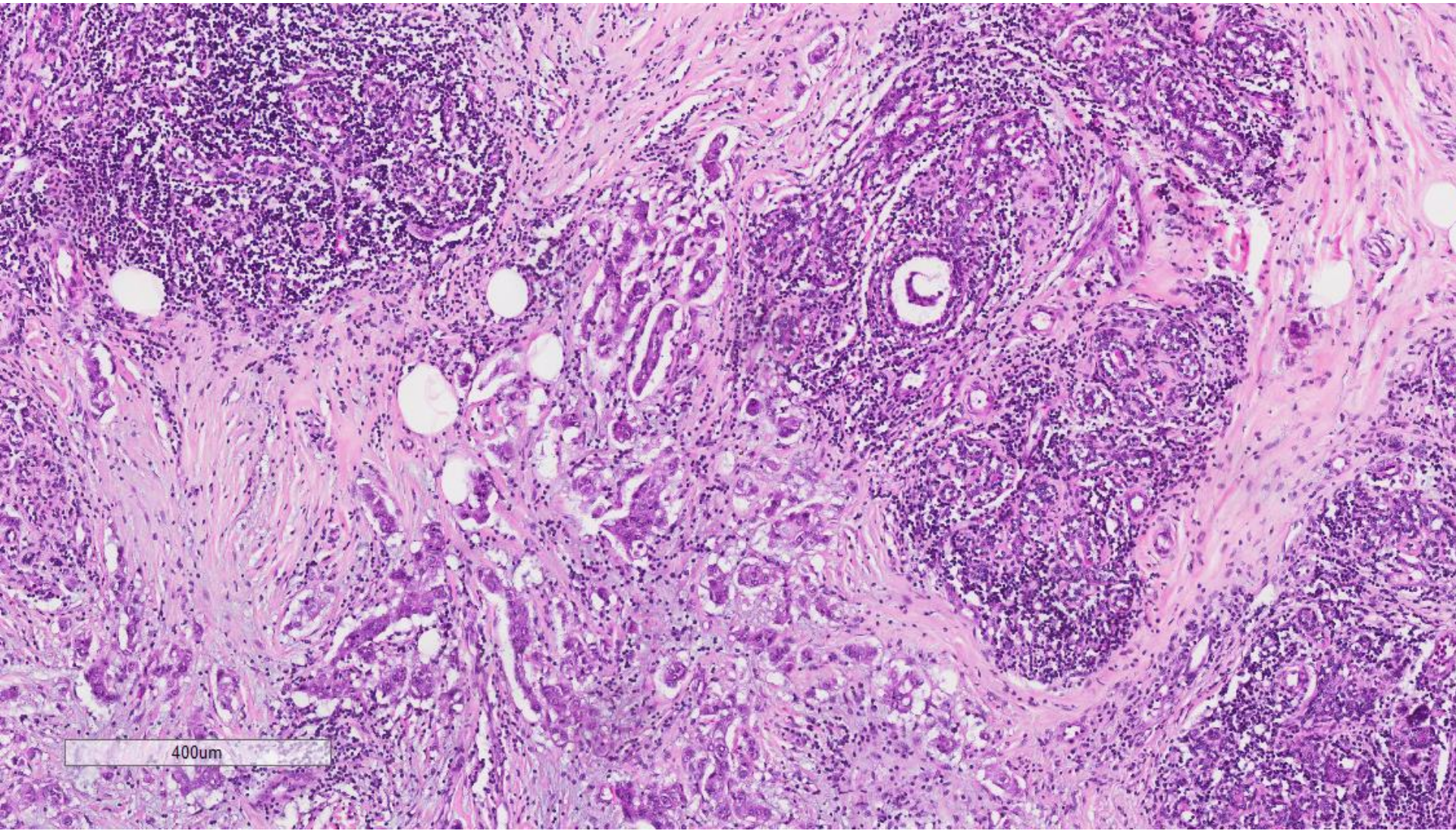
8mm



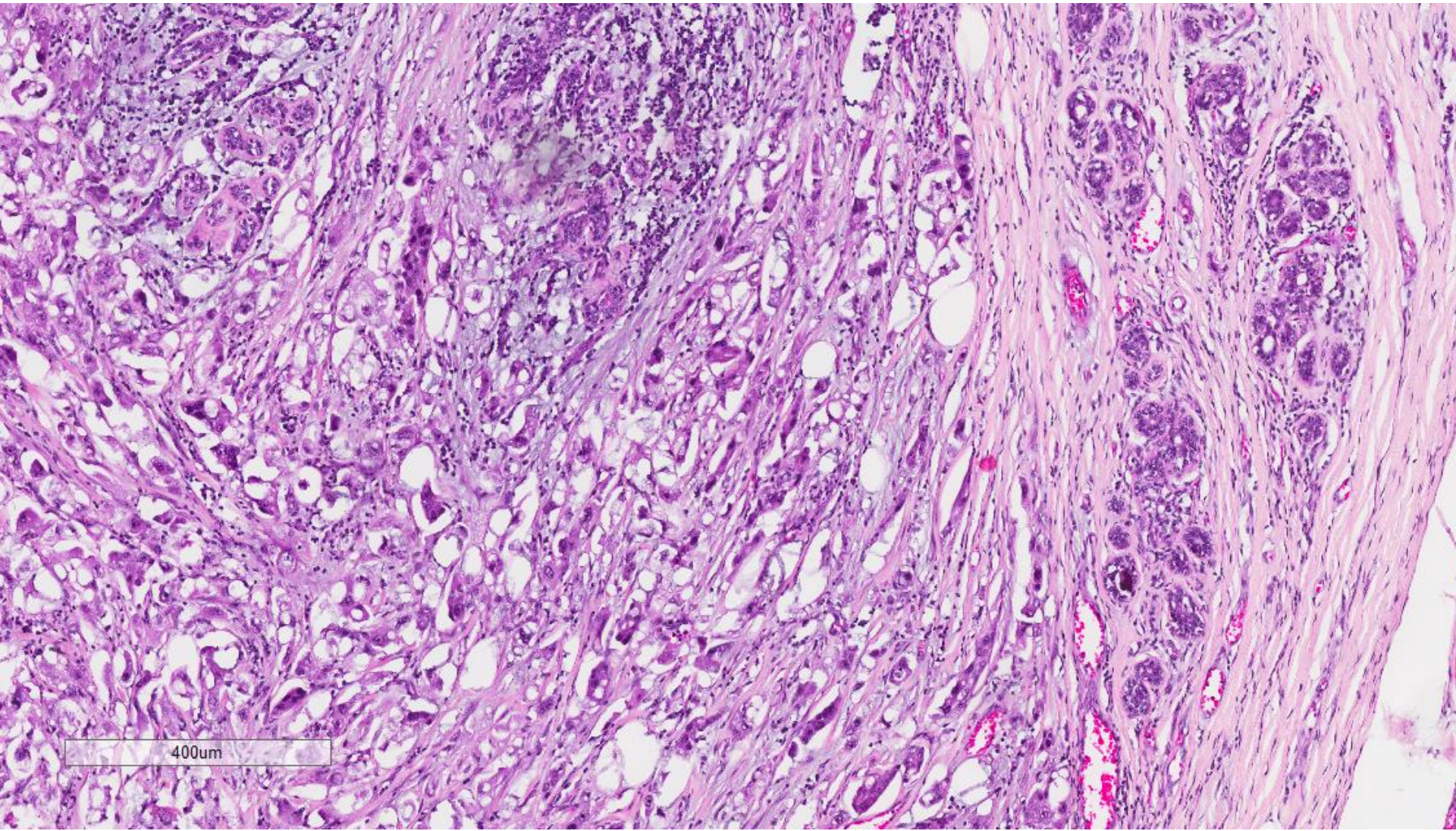
900µm



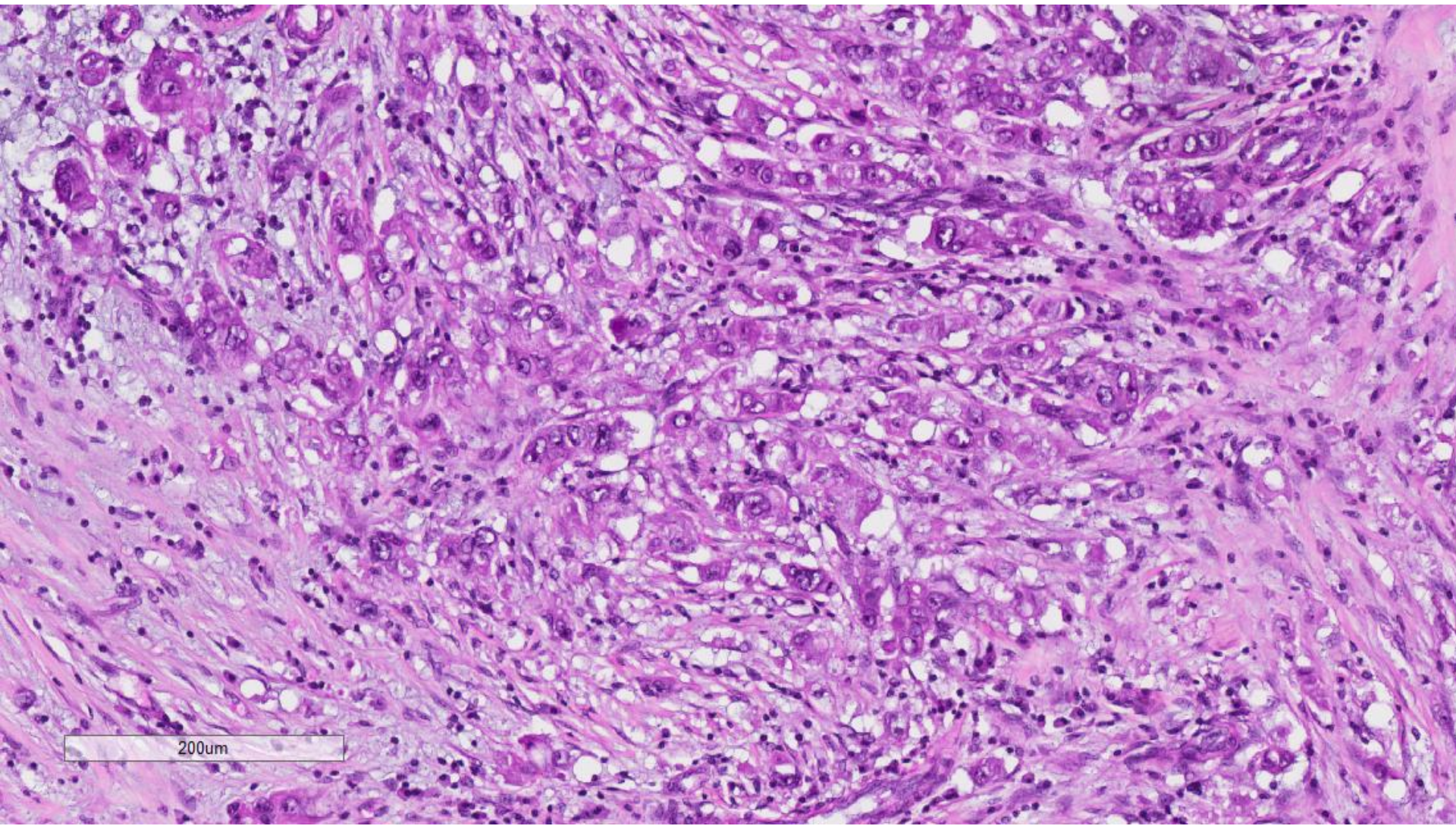
800um

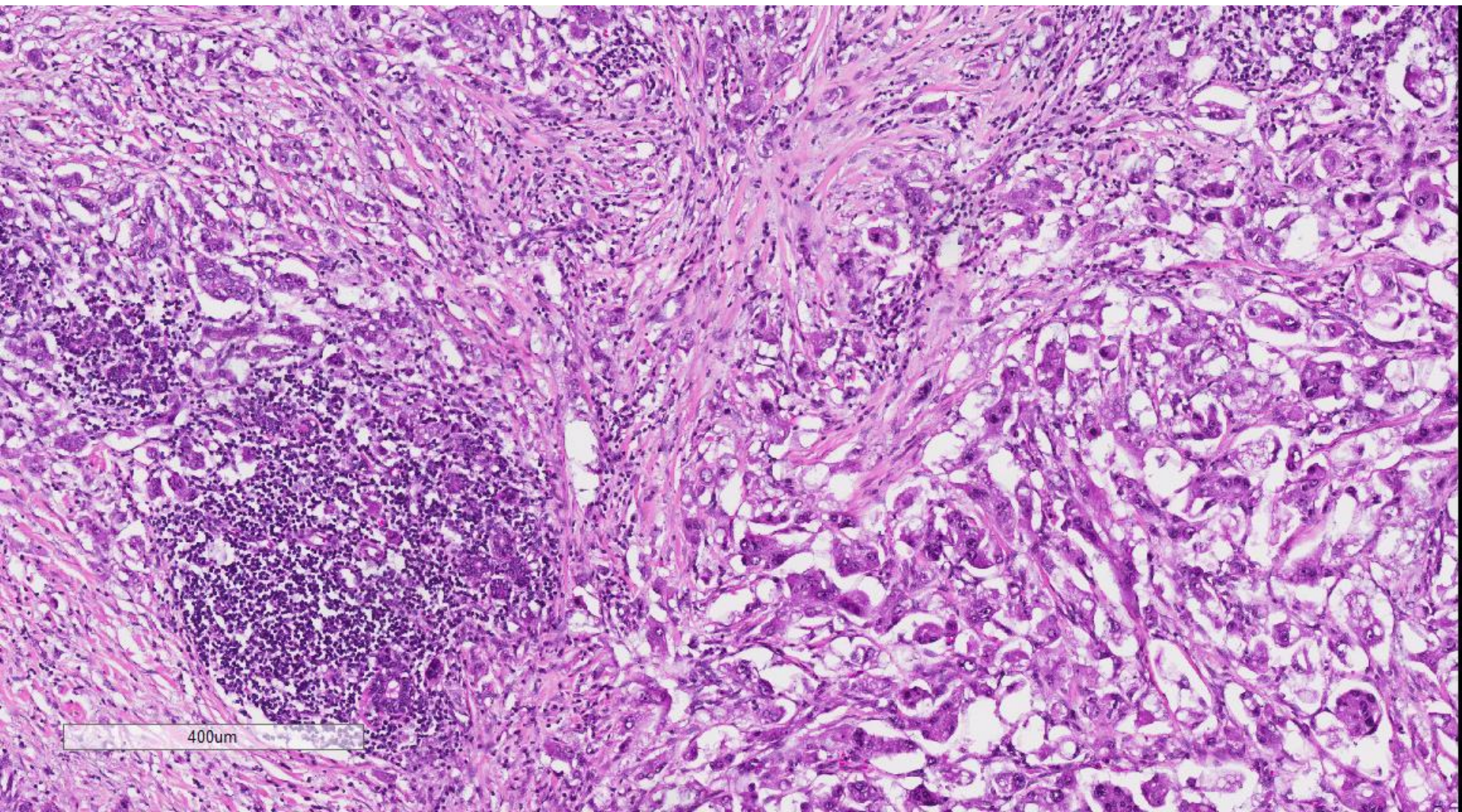


400um



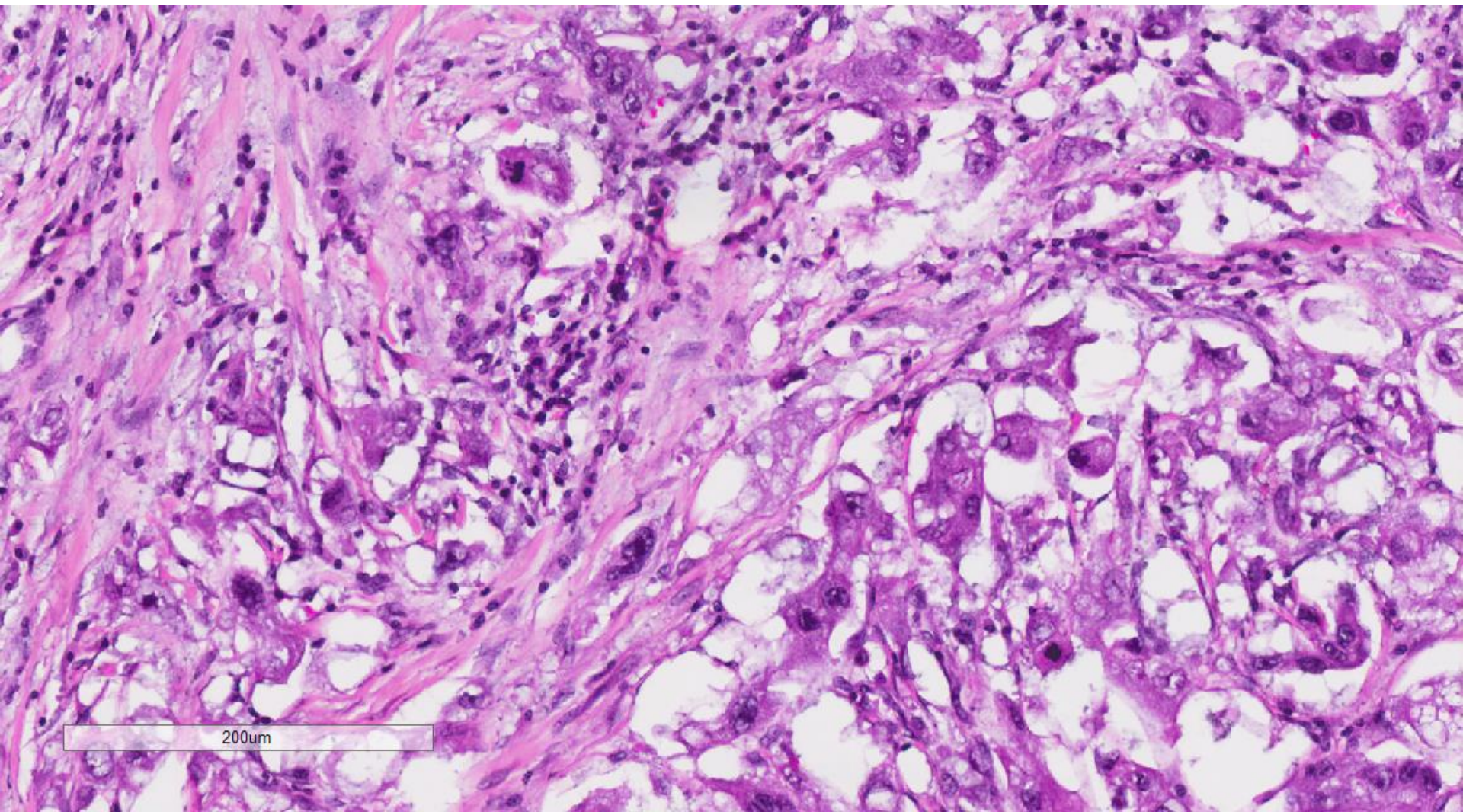
400um





400um





Invasive ductal carcinoma grade 3  
with micropapillary areas, 2.2 cm