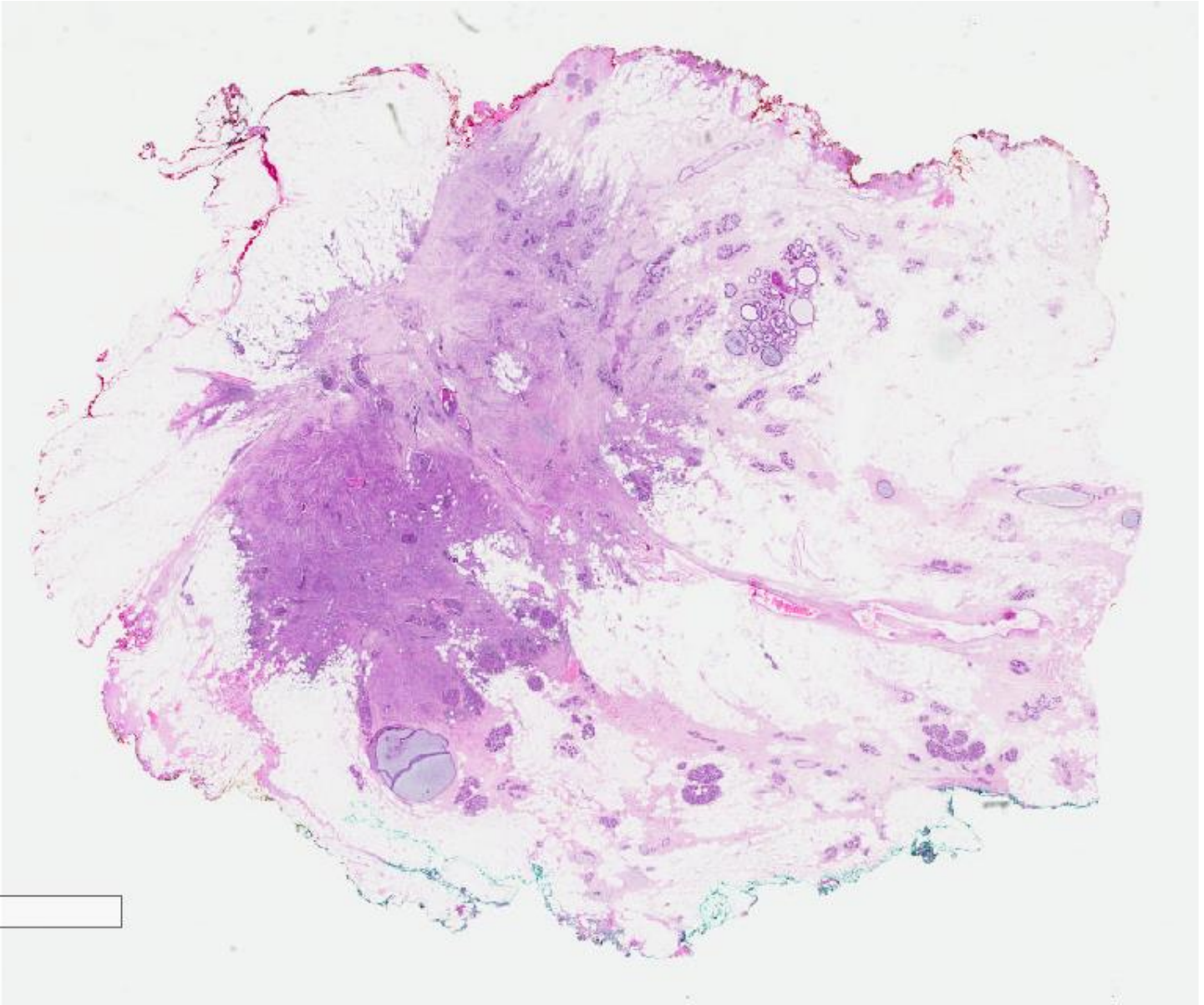
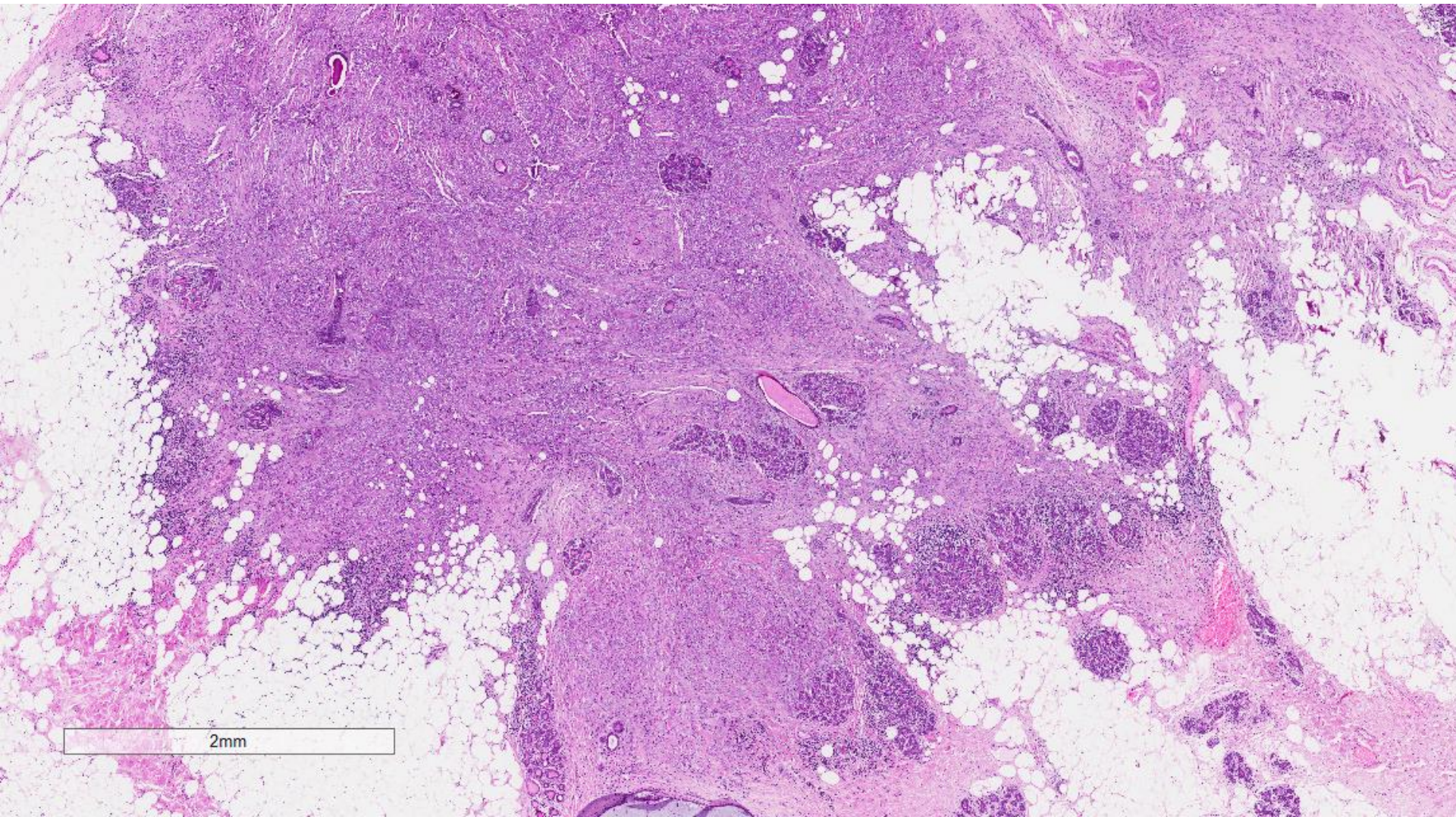


Case 42

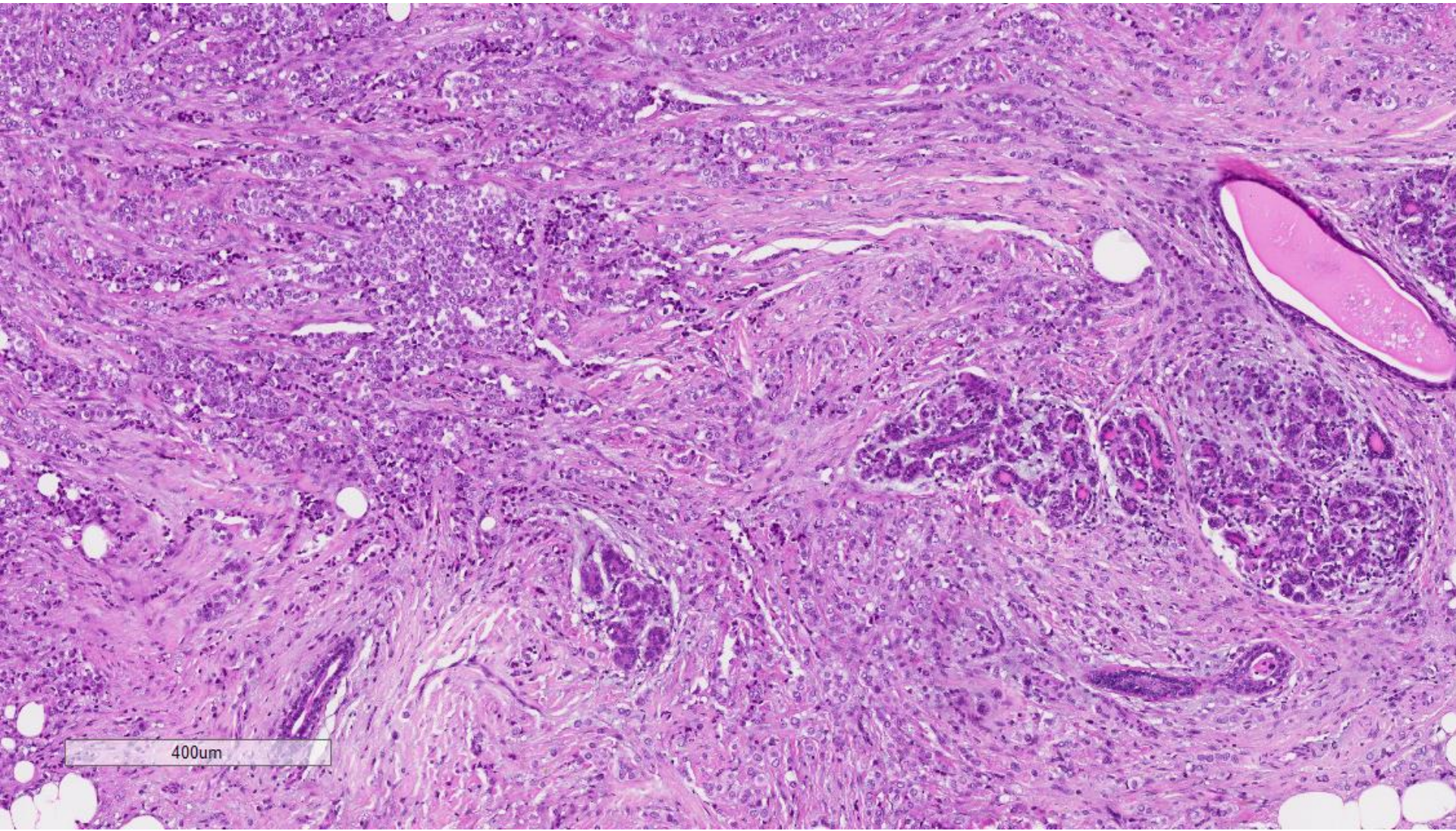
49 year old lady underwent wide excision of a left breast mass.

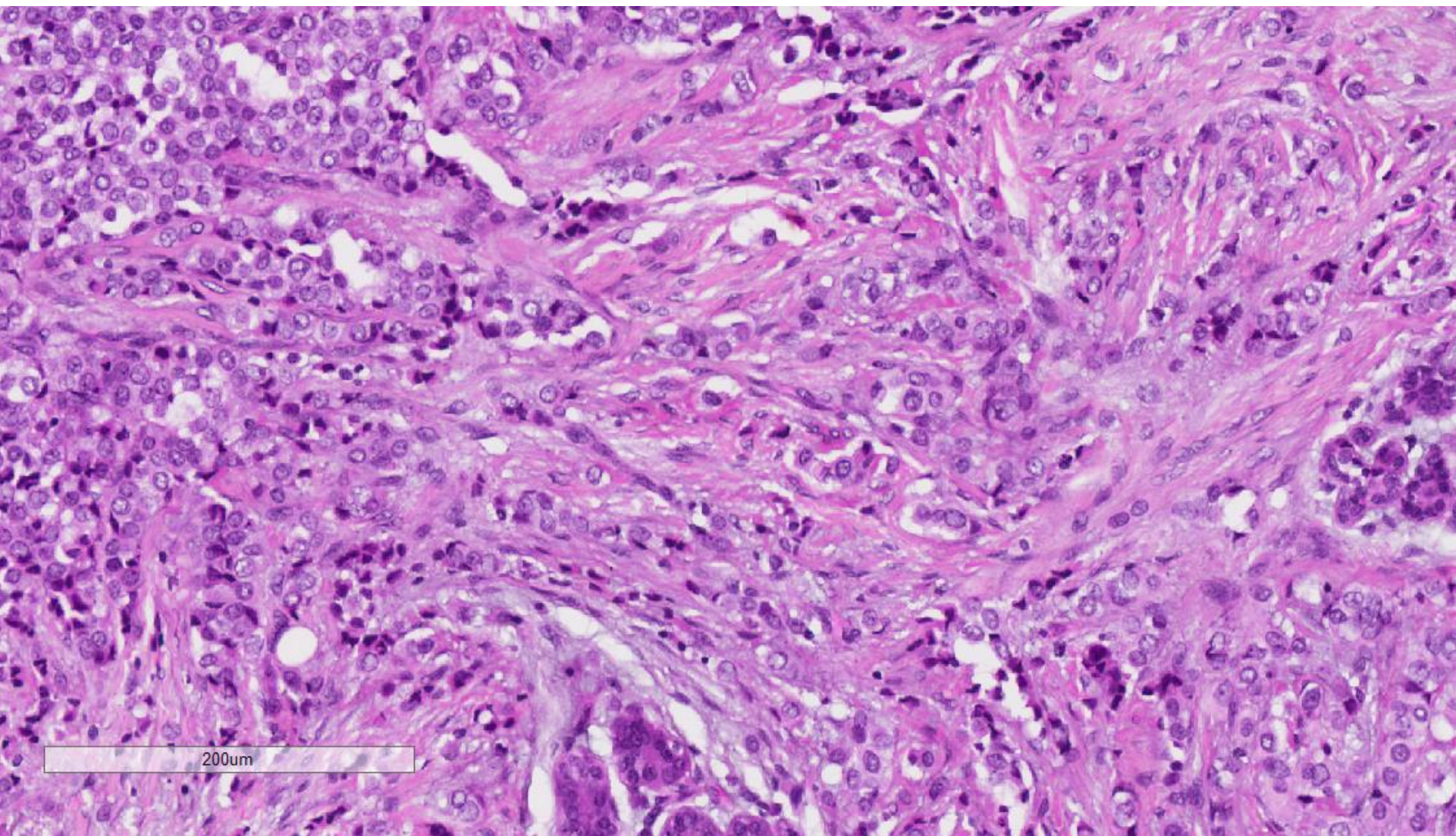


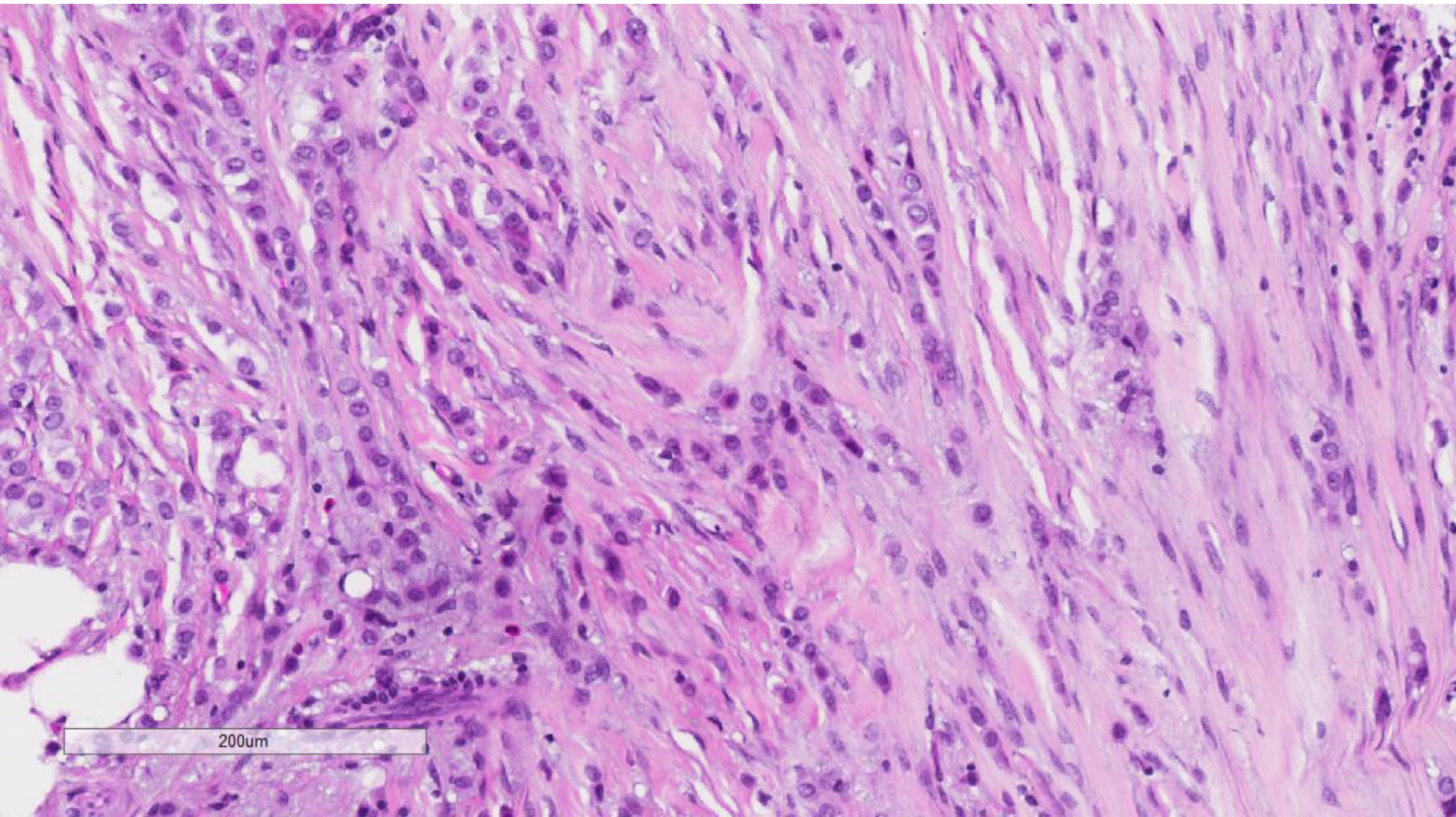
7mm



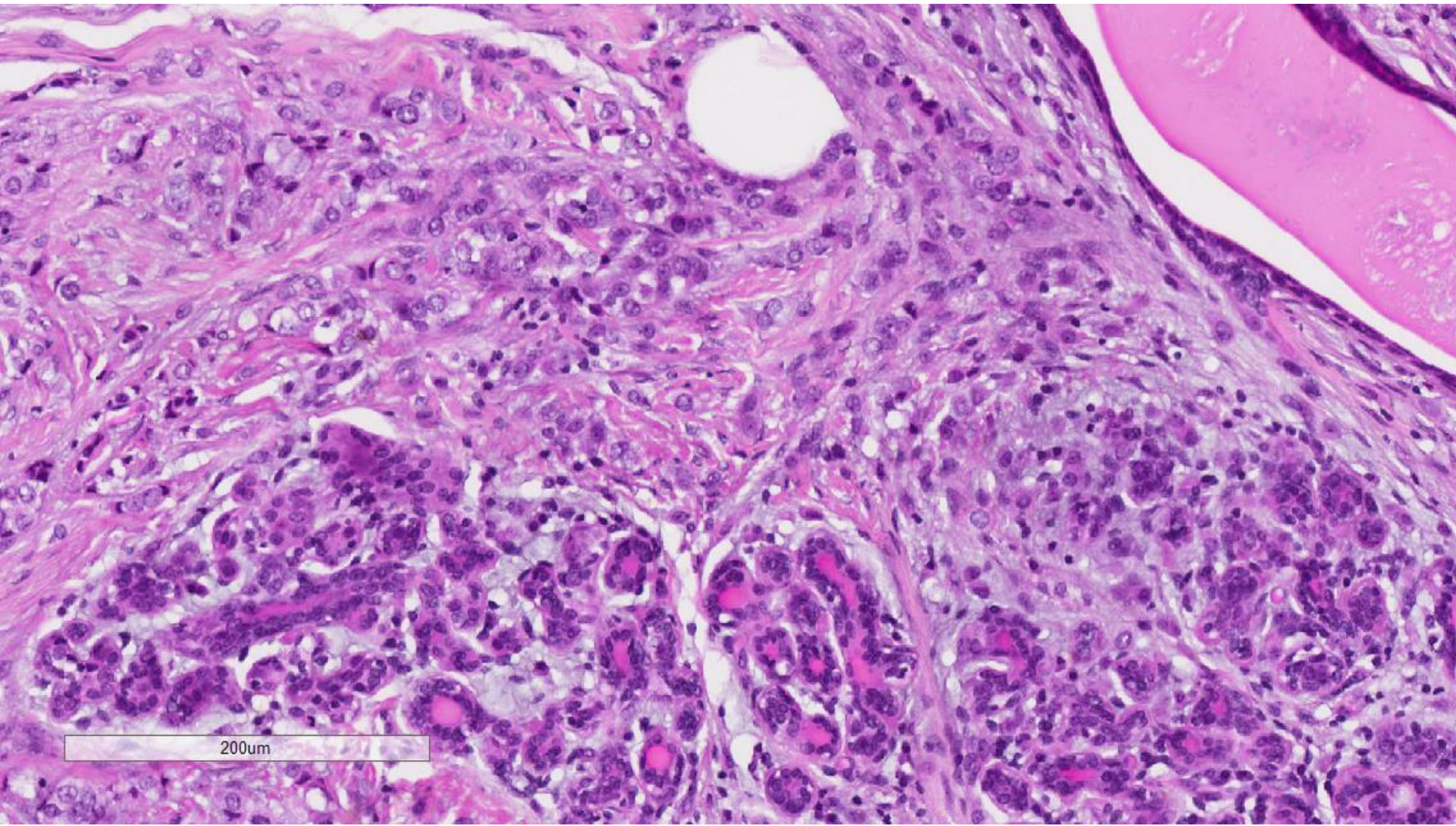
2mm



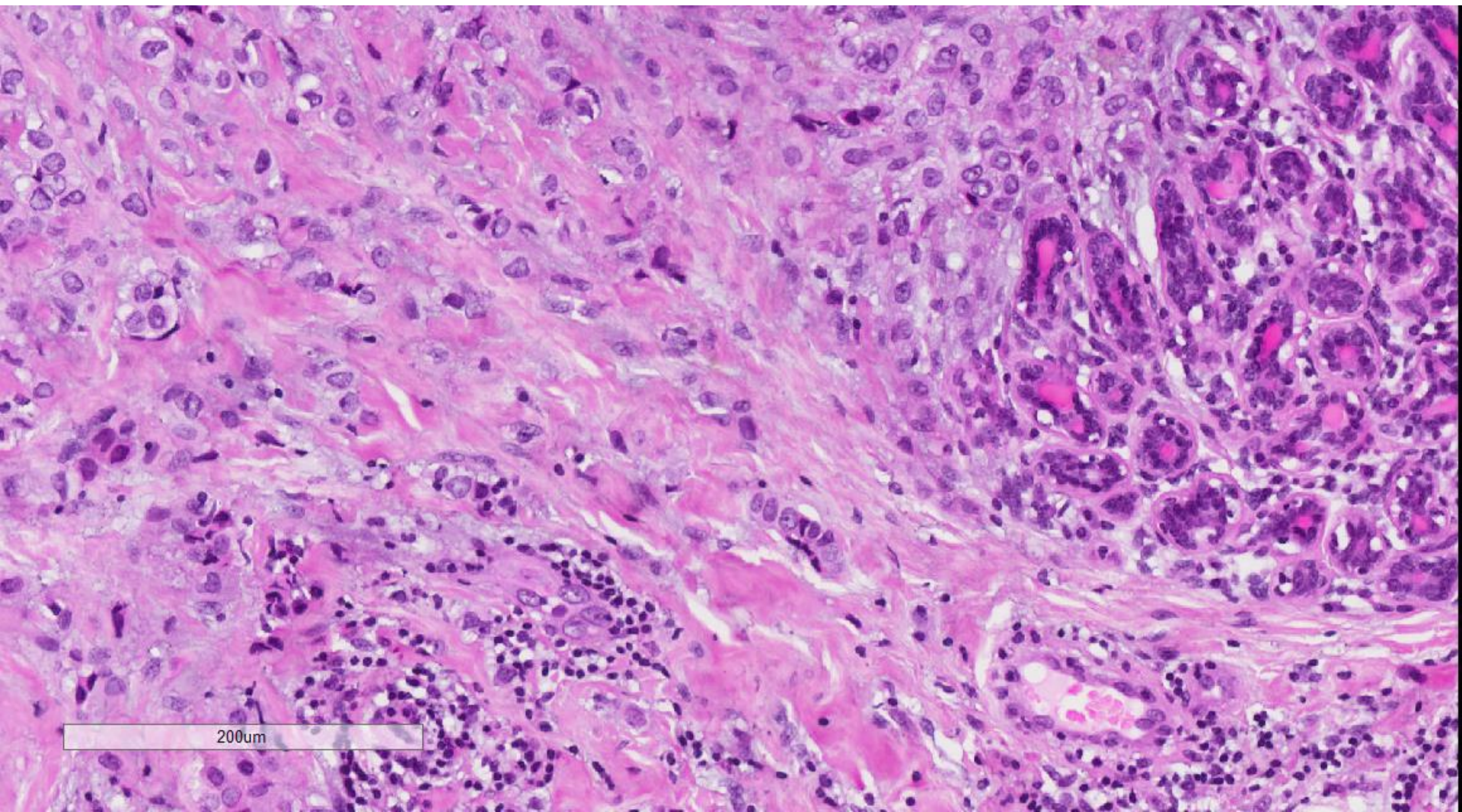


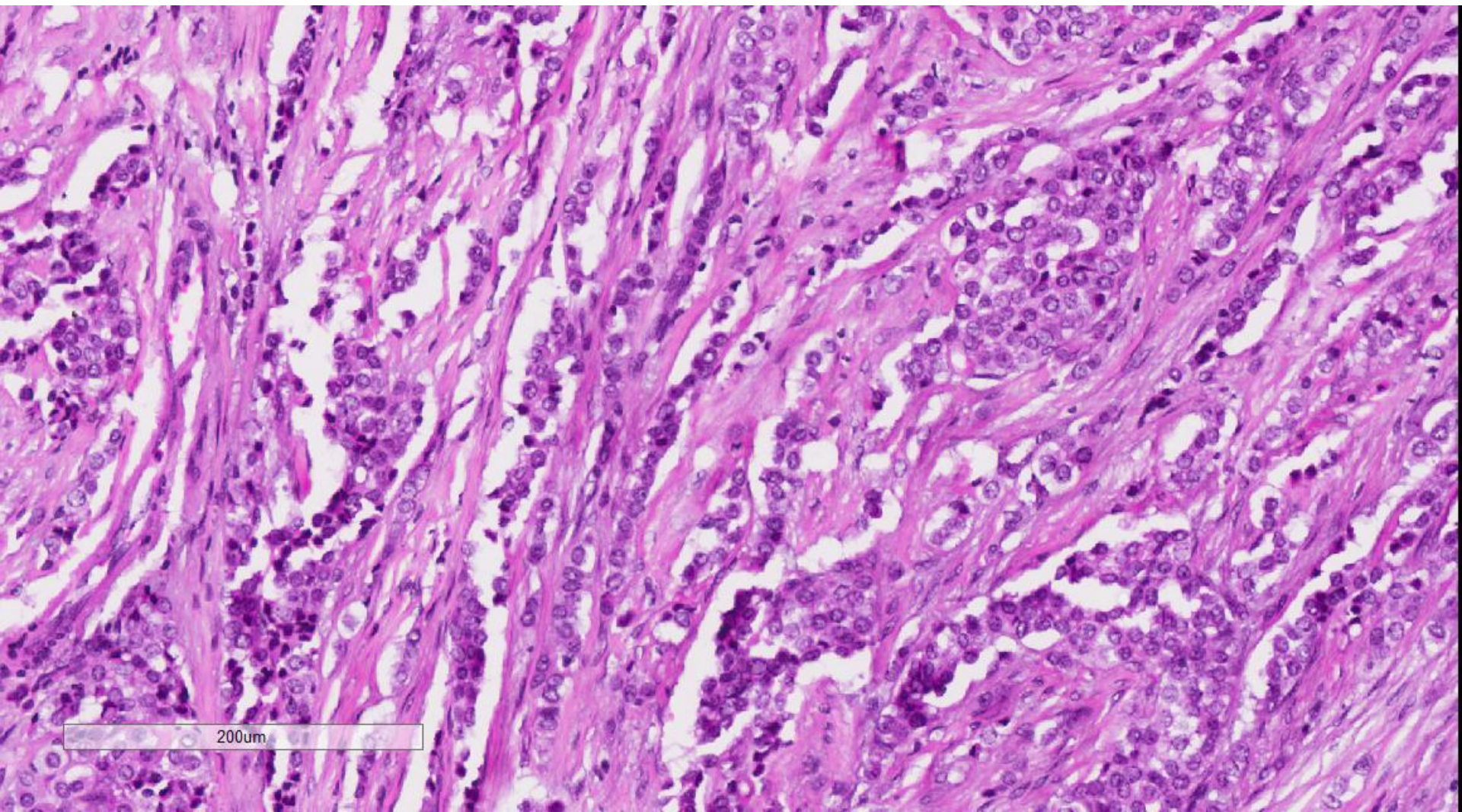


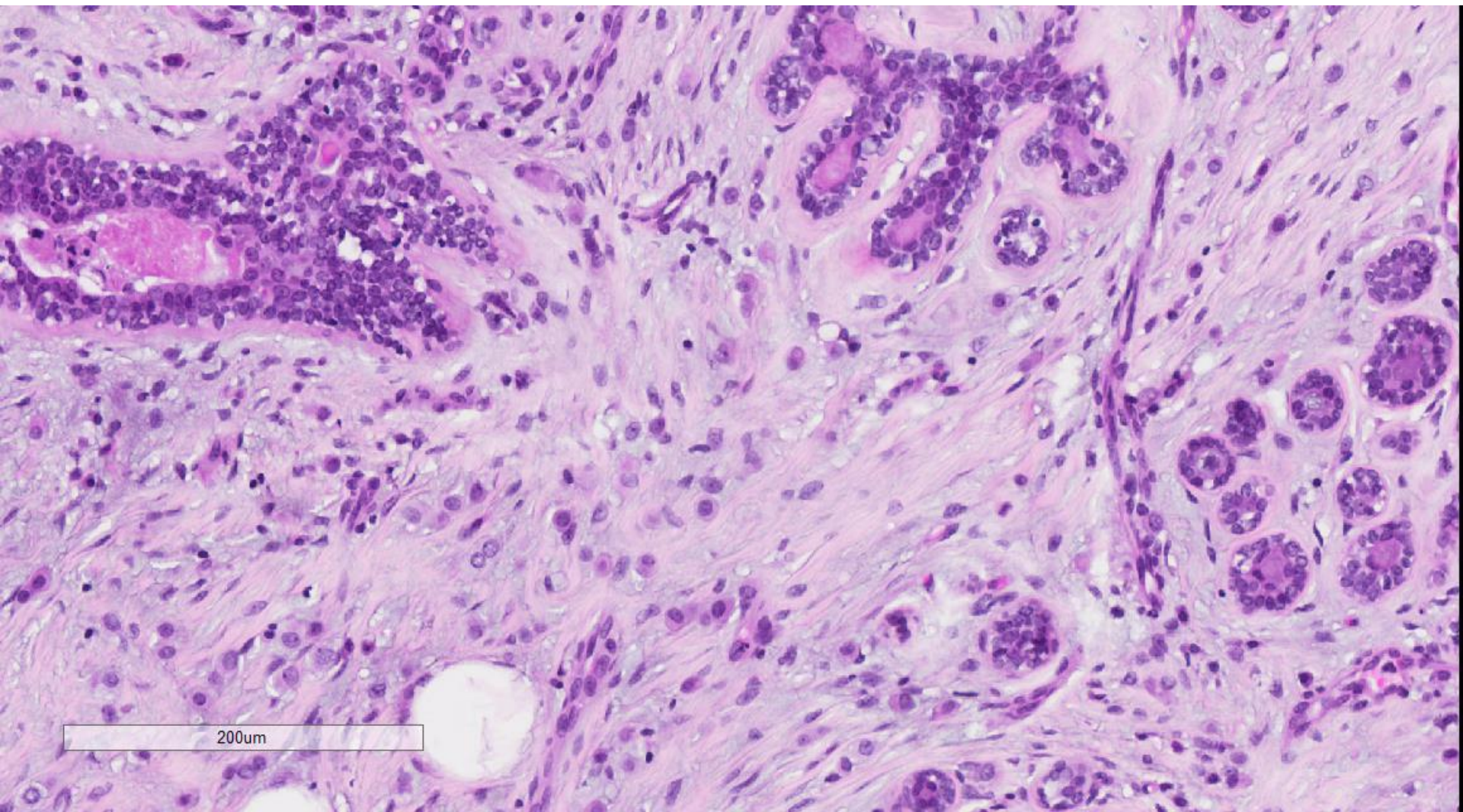
200um



200µm







Invasive lobular carcinoma, classic pattern, grade 1, 12mm