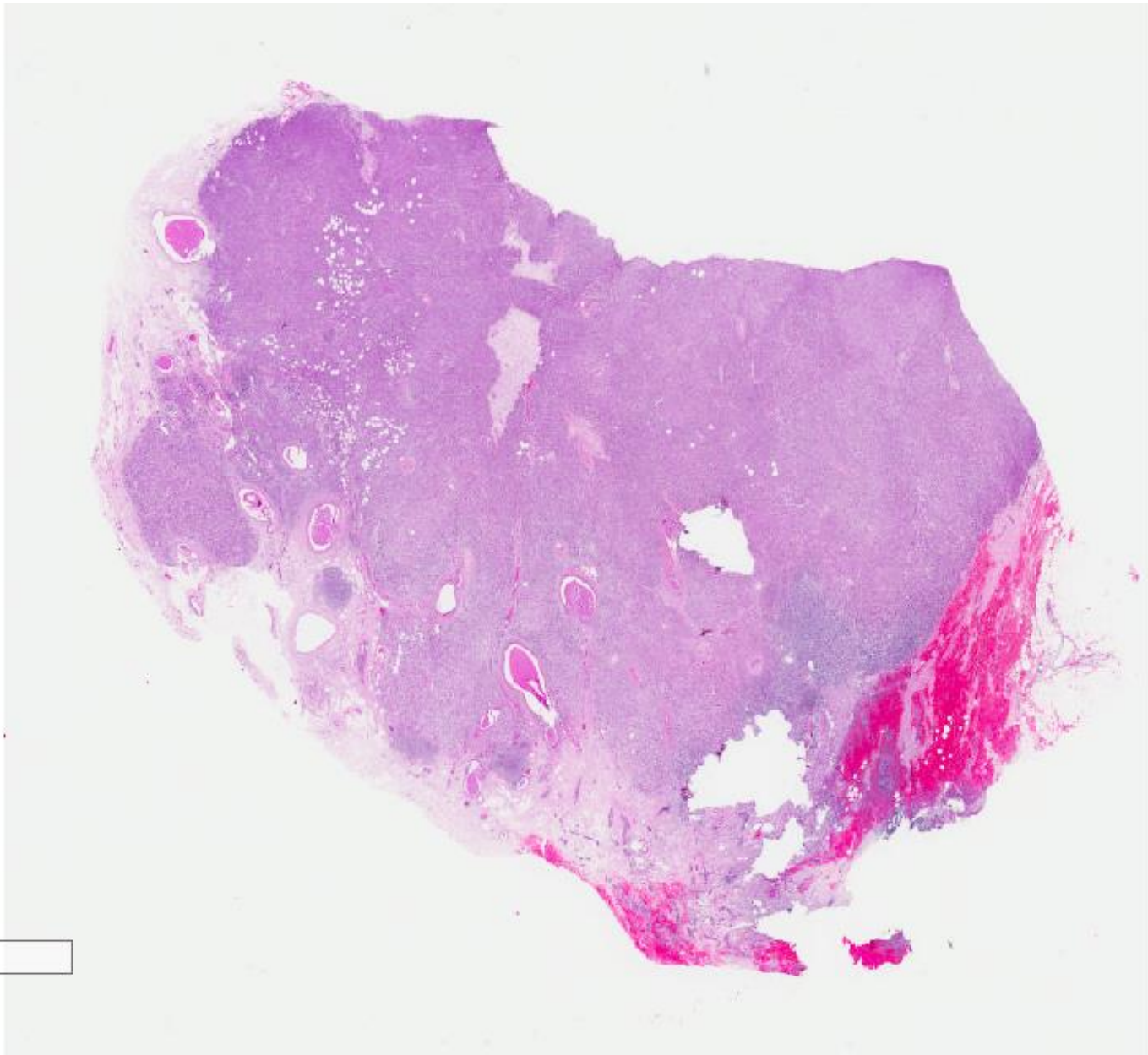
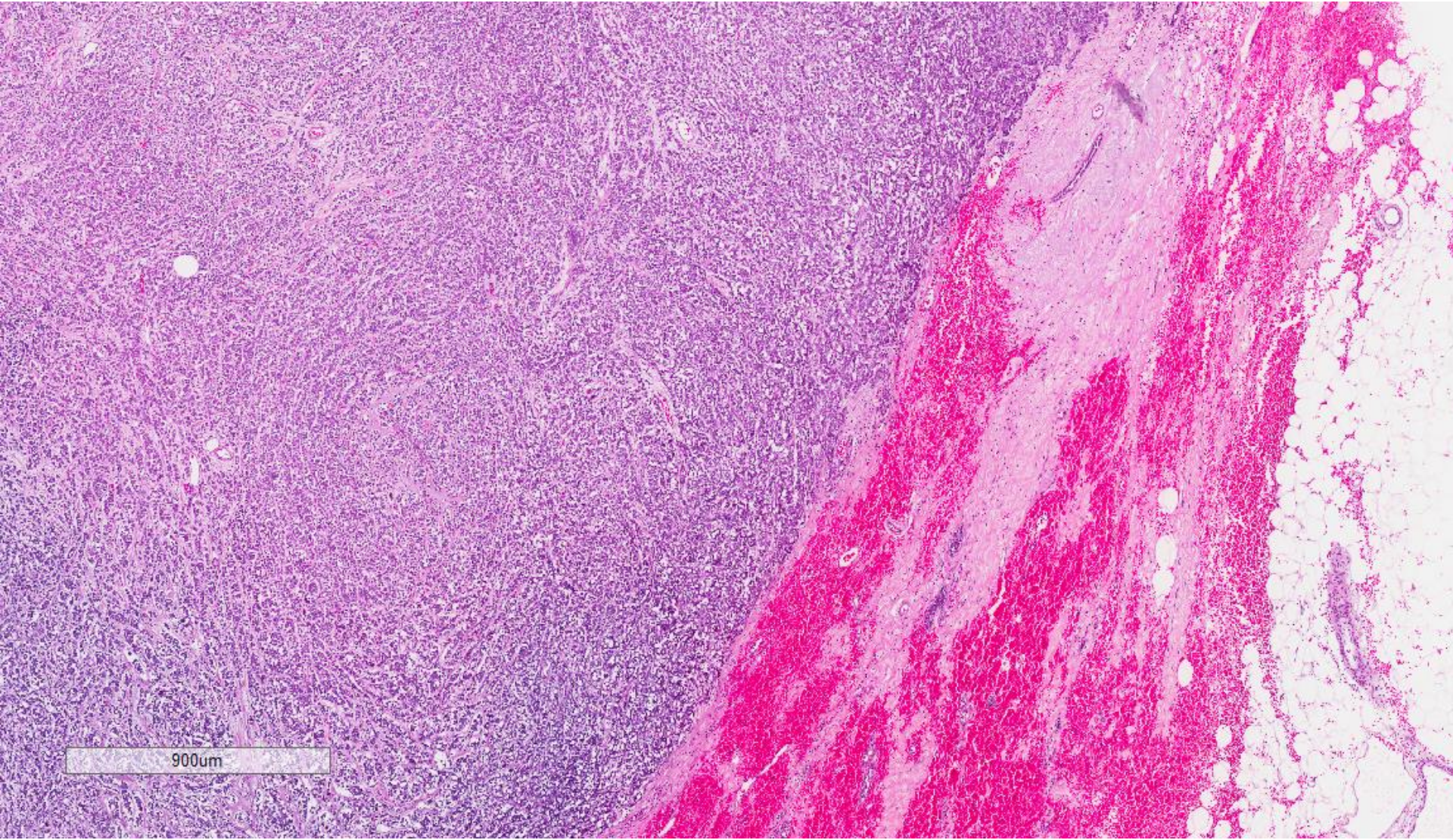


Case 39

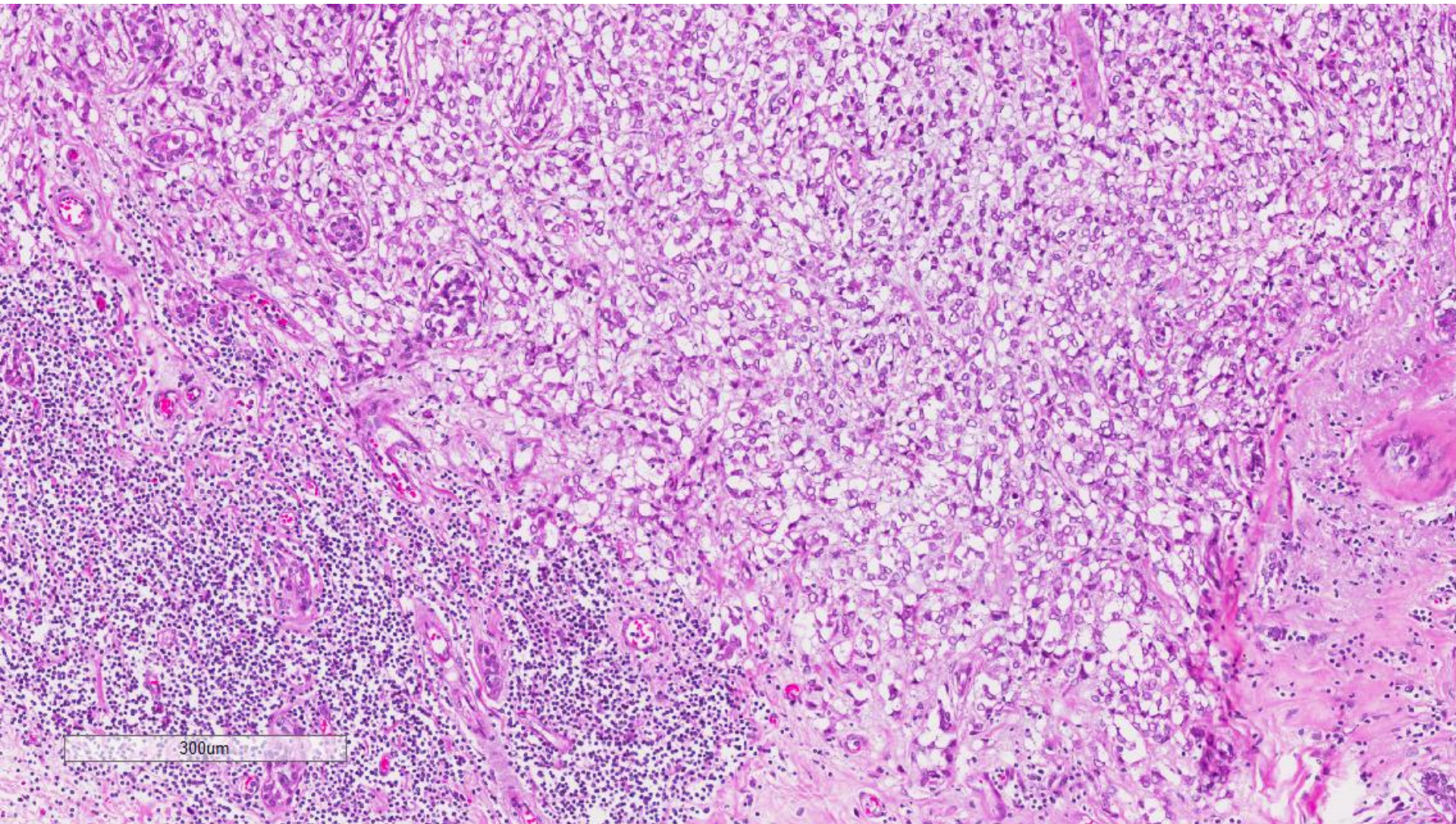
83 year old lady underwent mastectomy
for a right breast mass.

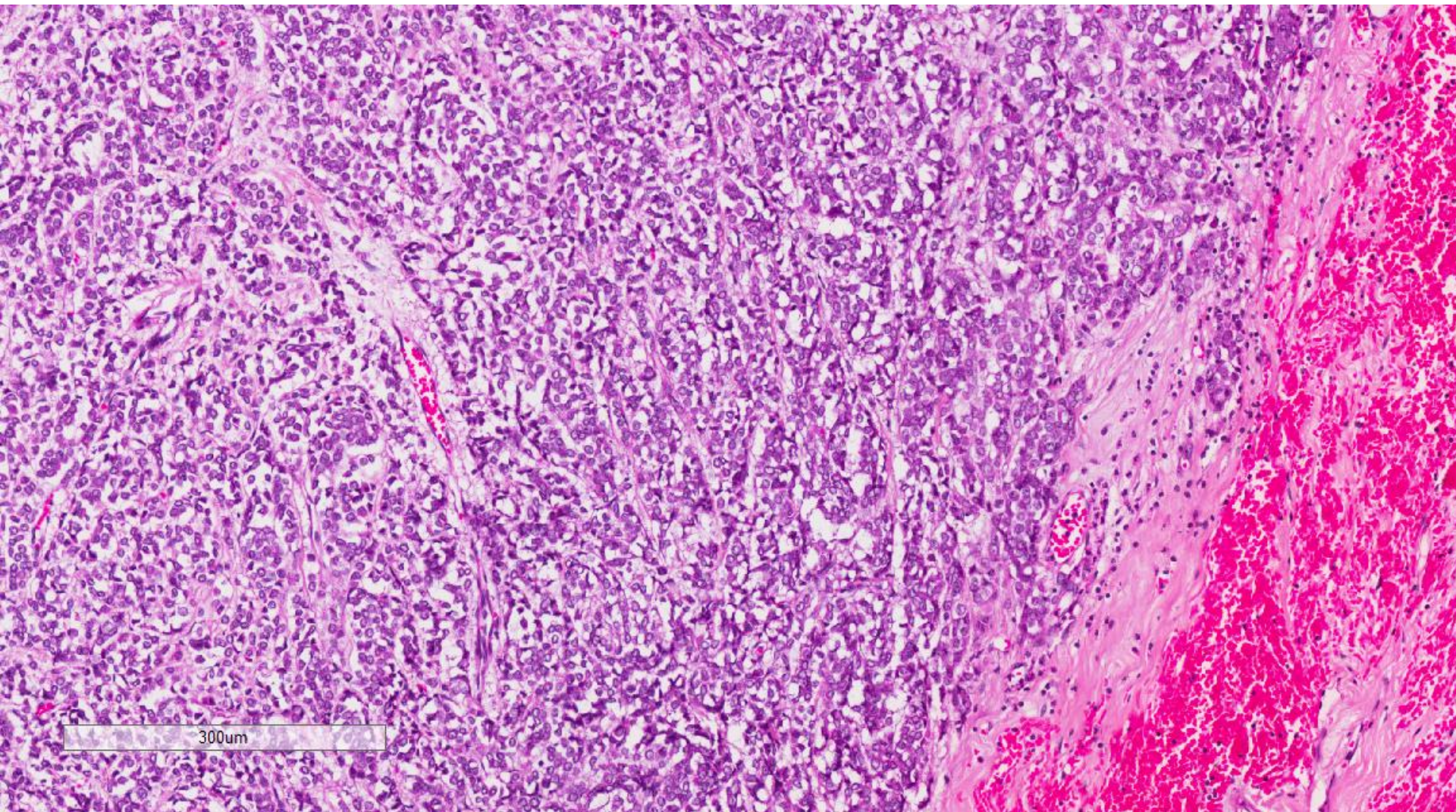


7mm

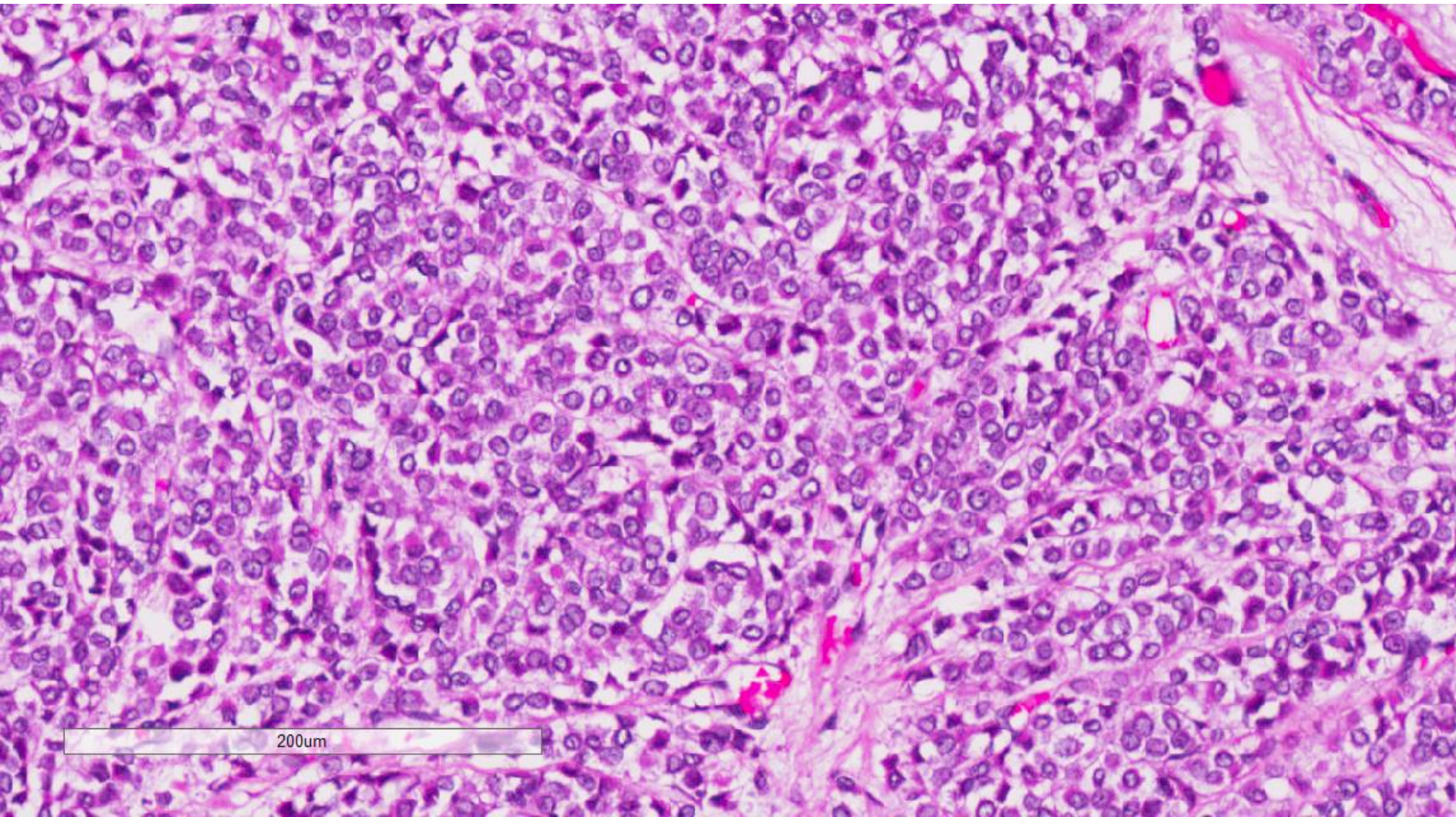


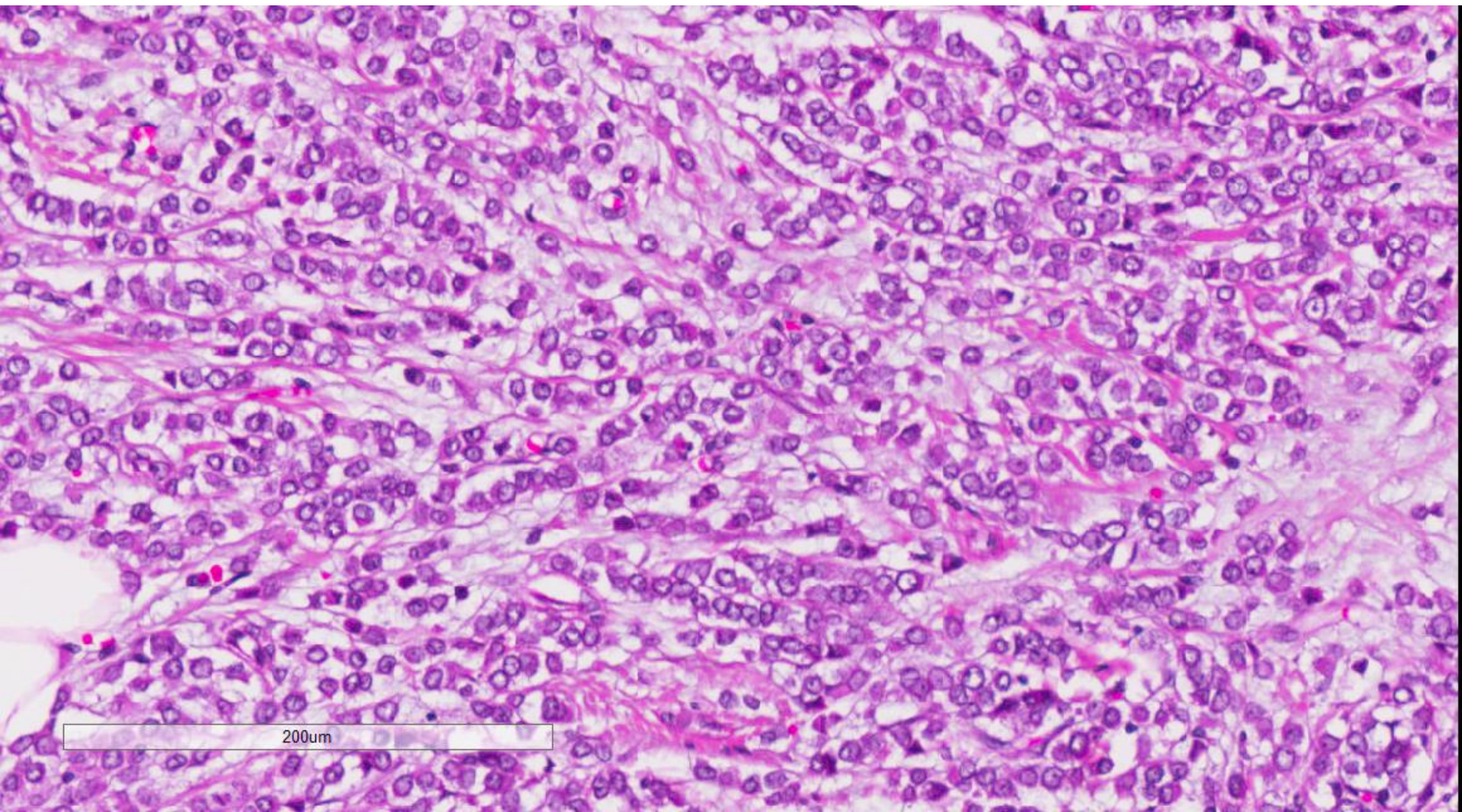
900um



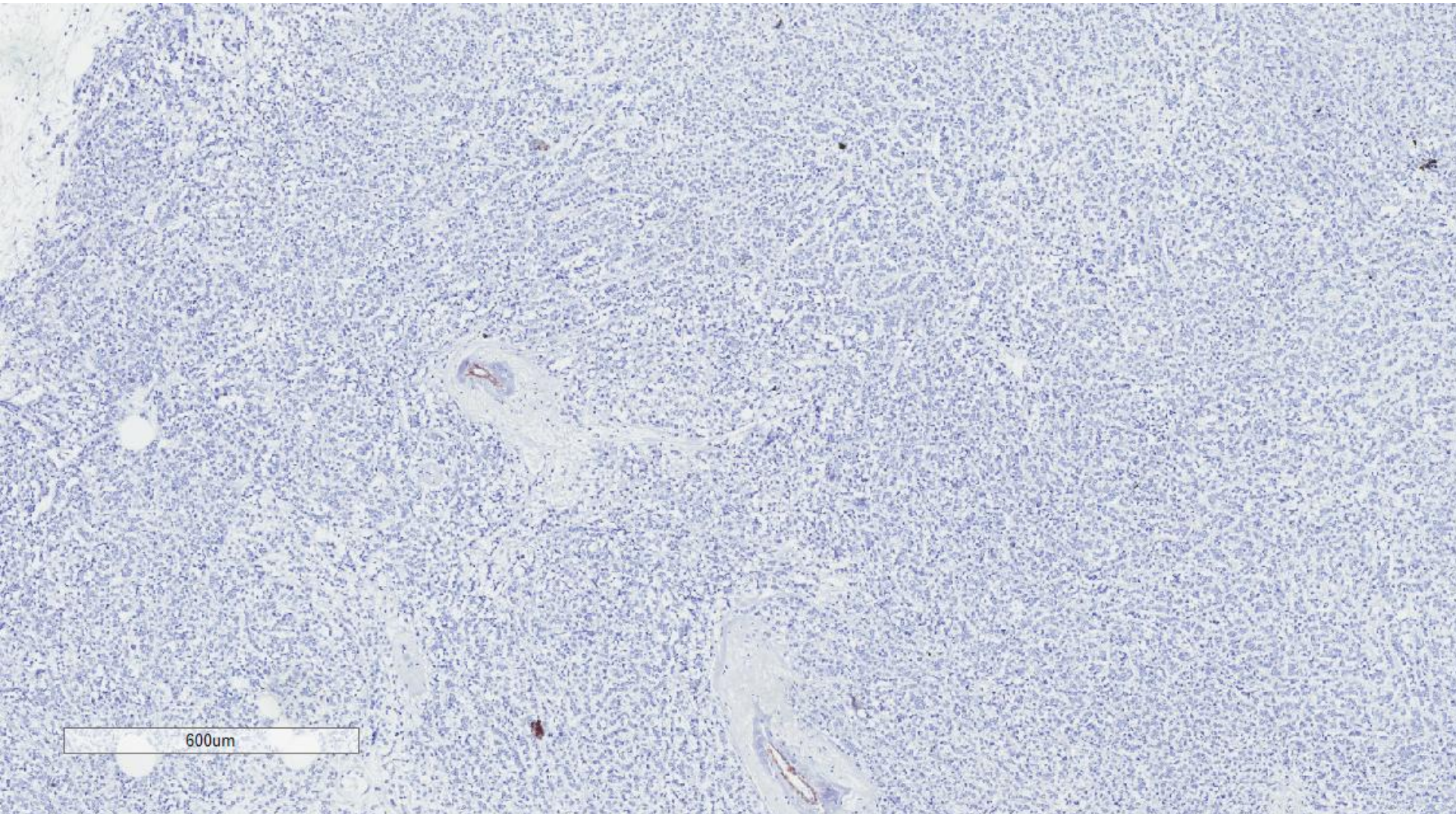


300um

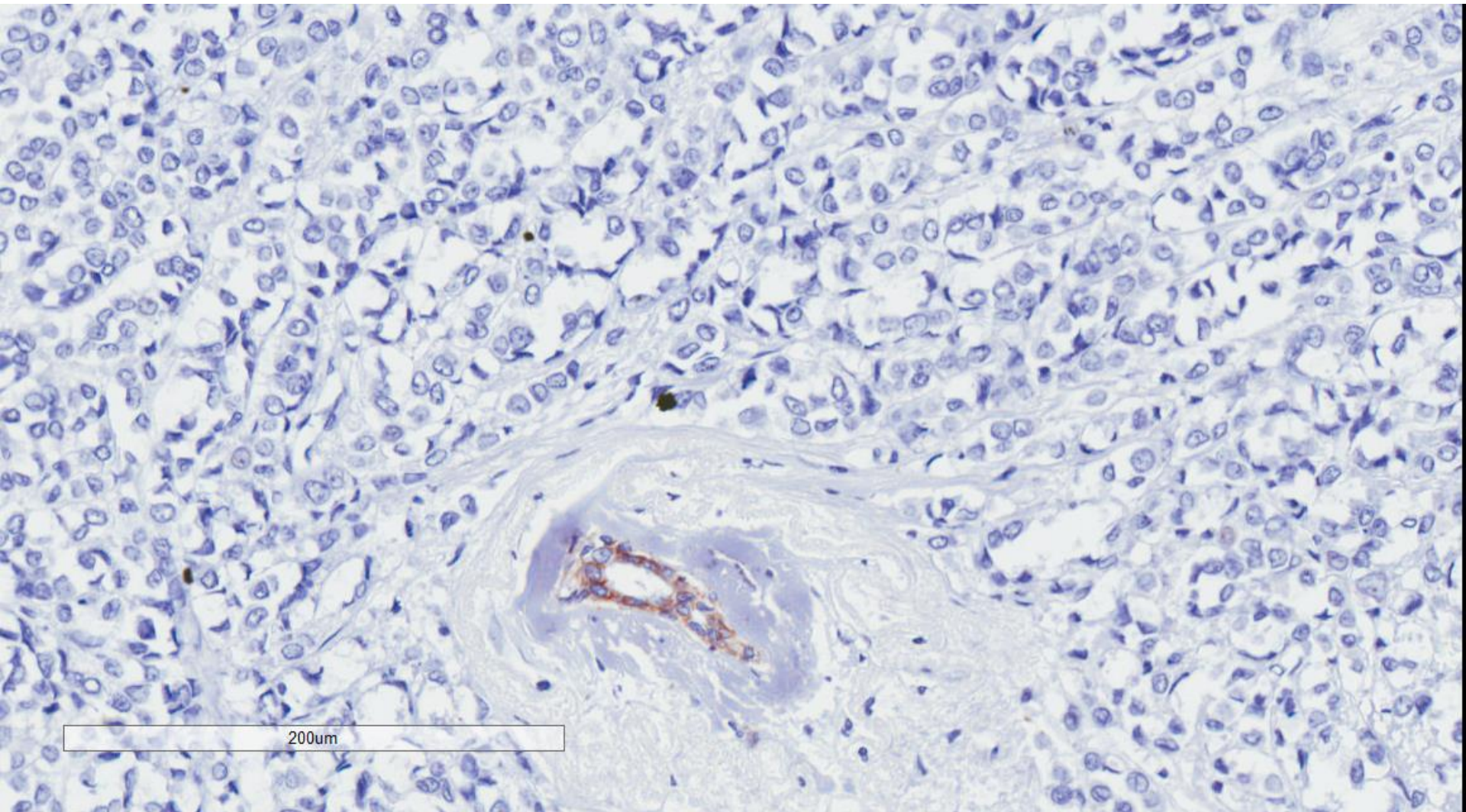




E-cadherin



E-cadherin



Invasive lobular carcinoma, solid variant, grade 2, 33 mm