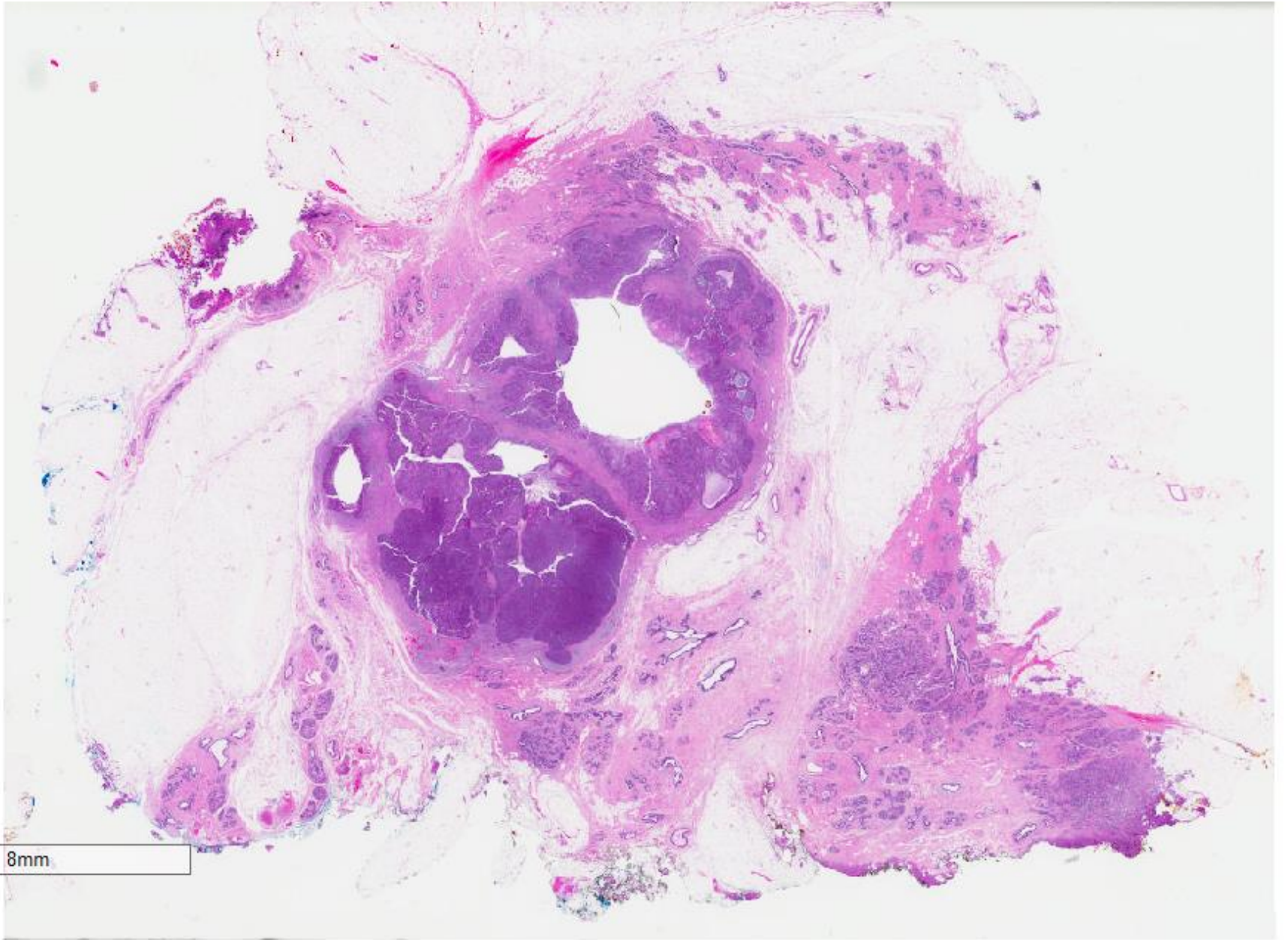
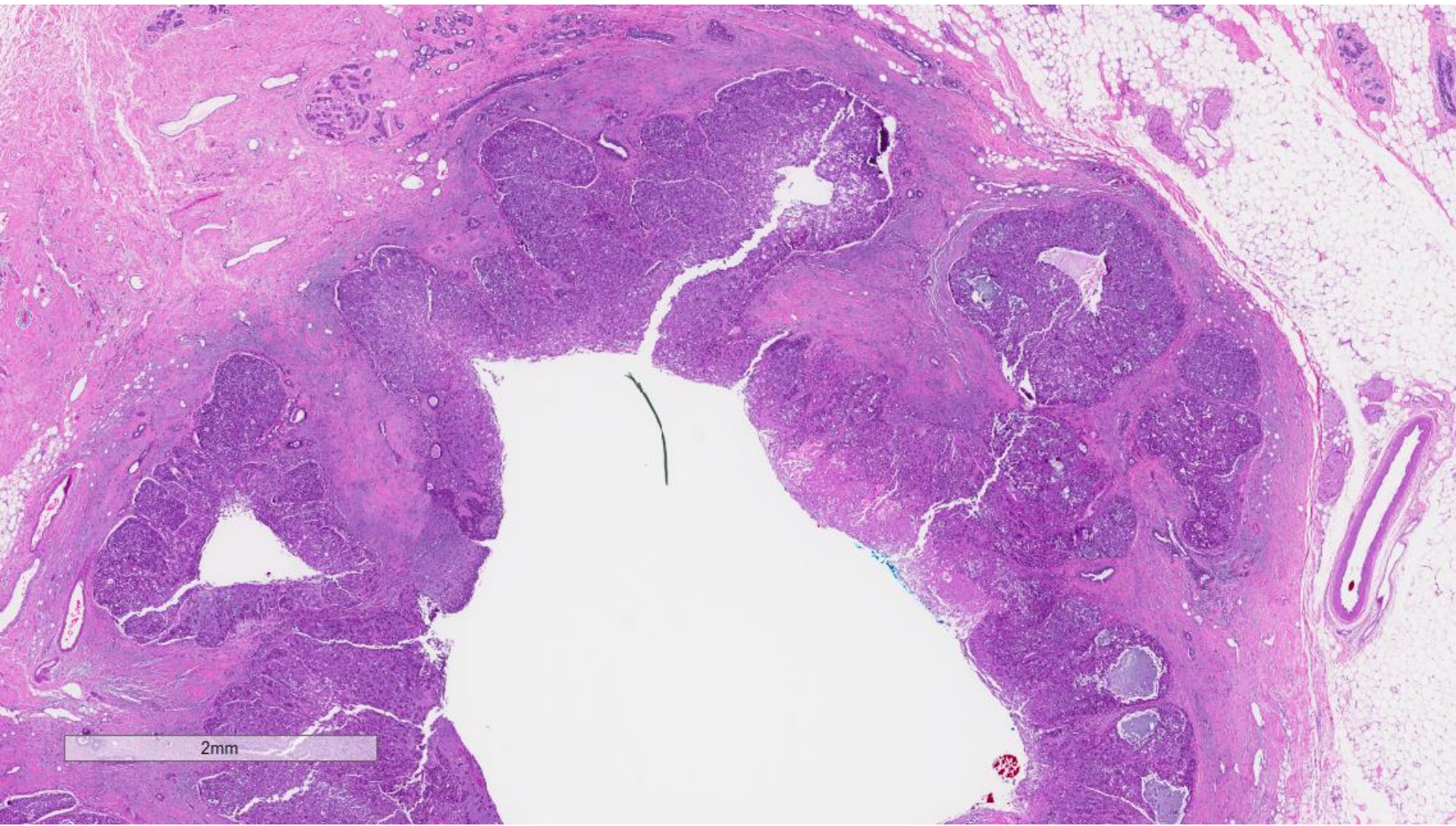


## Case 35

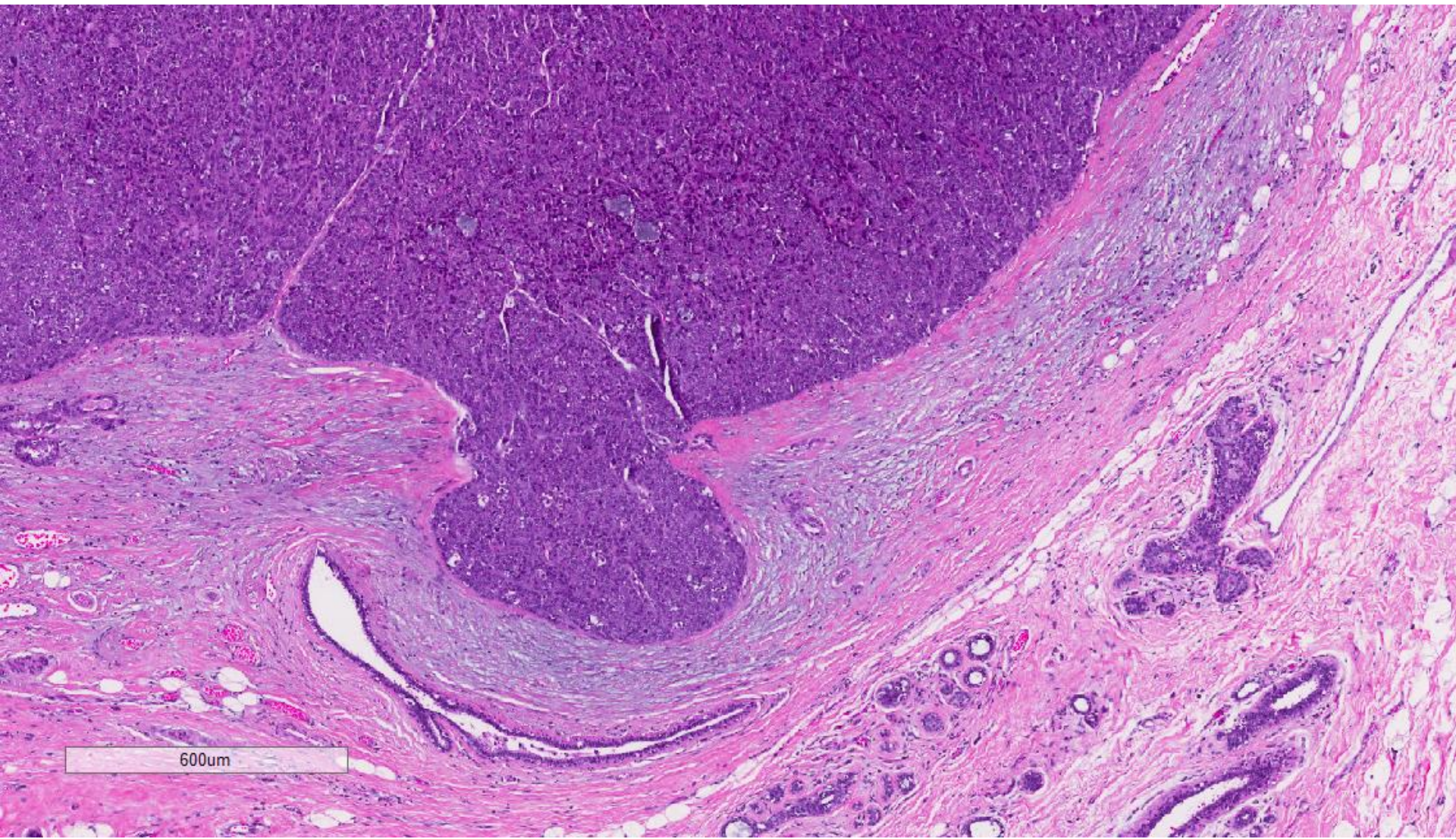
53 year old lady underwent wide excision of a right breast lesion.



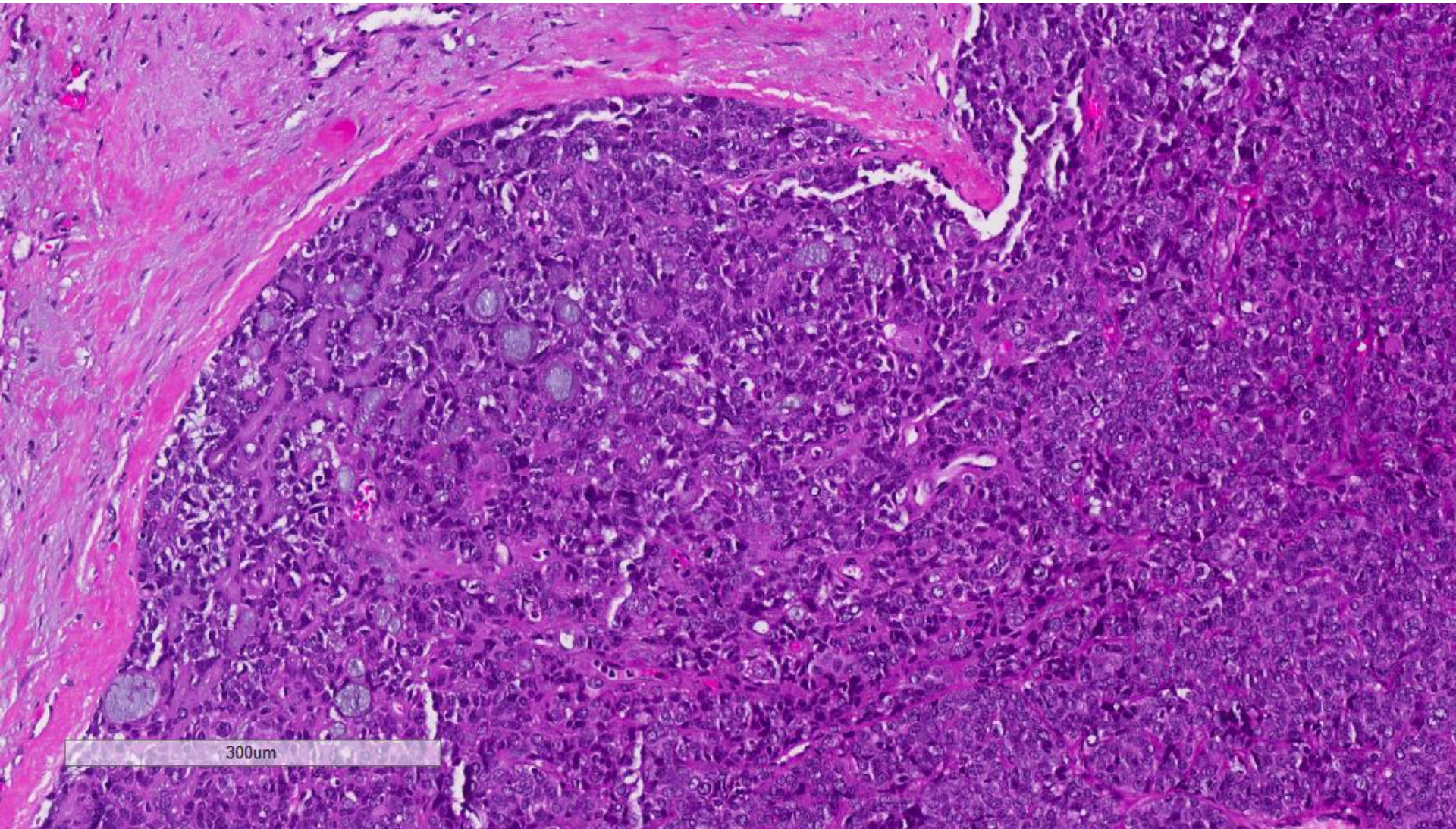
8mm



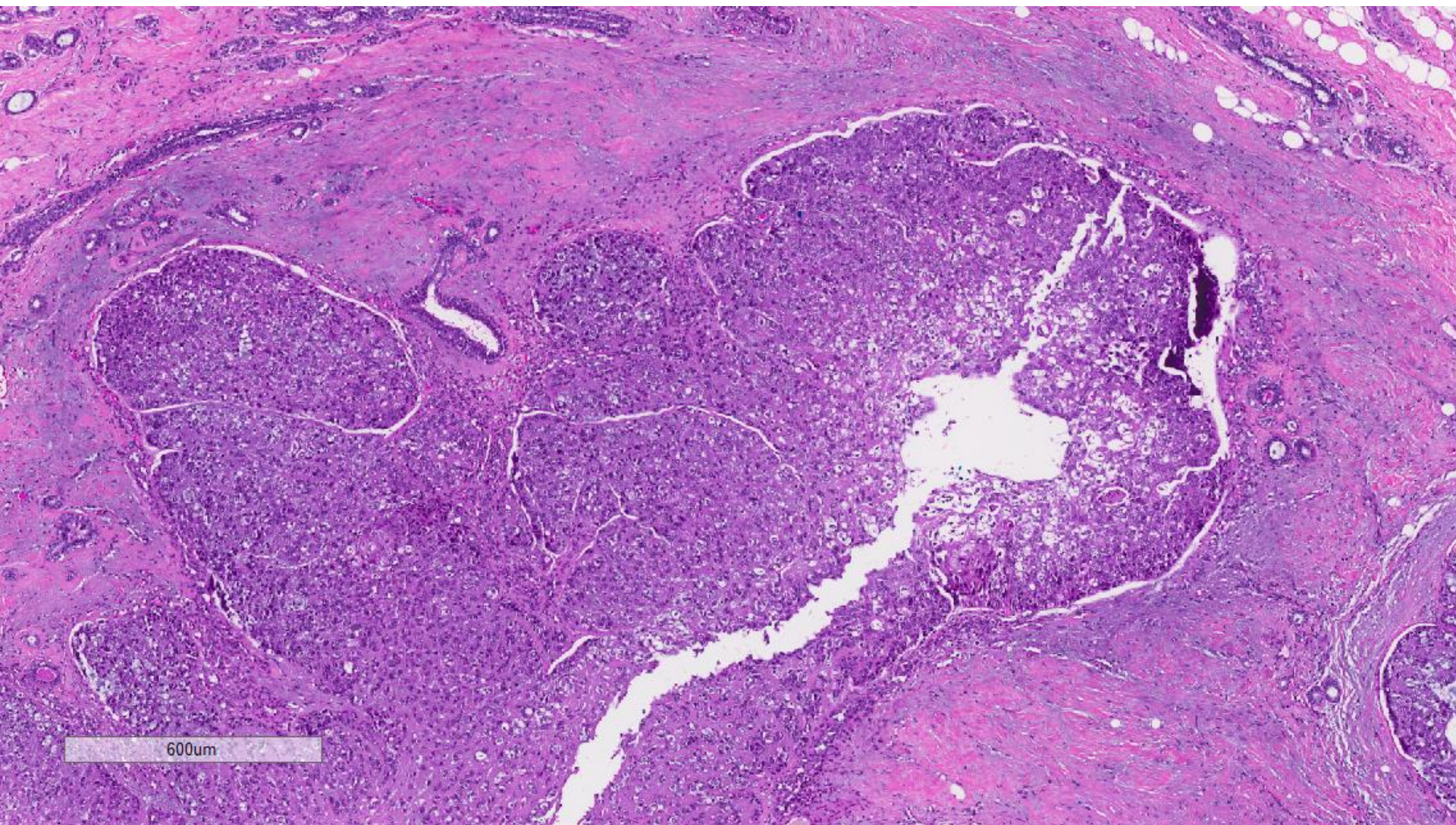
2mm



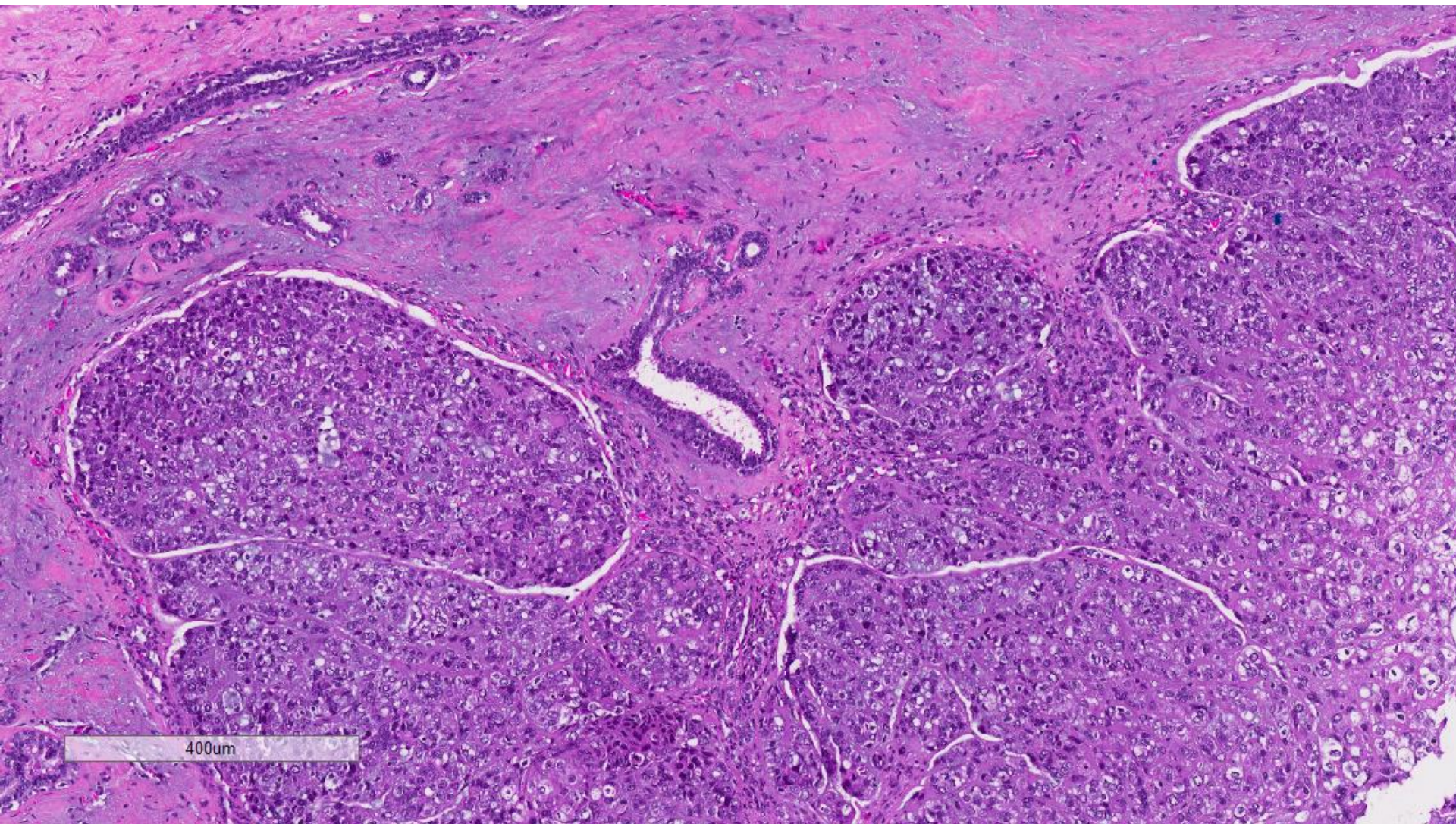
600um

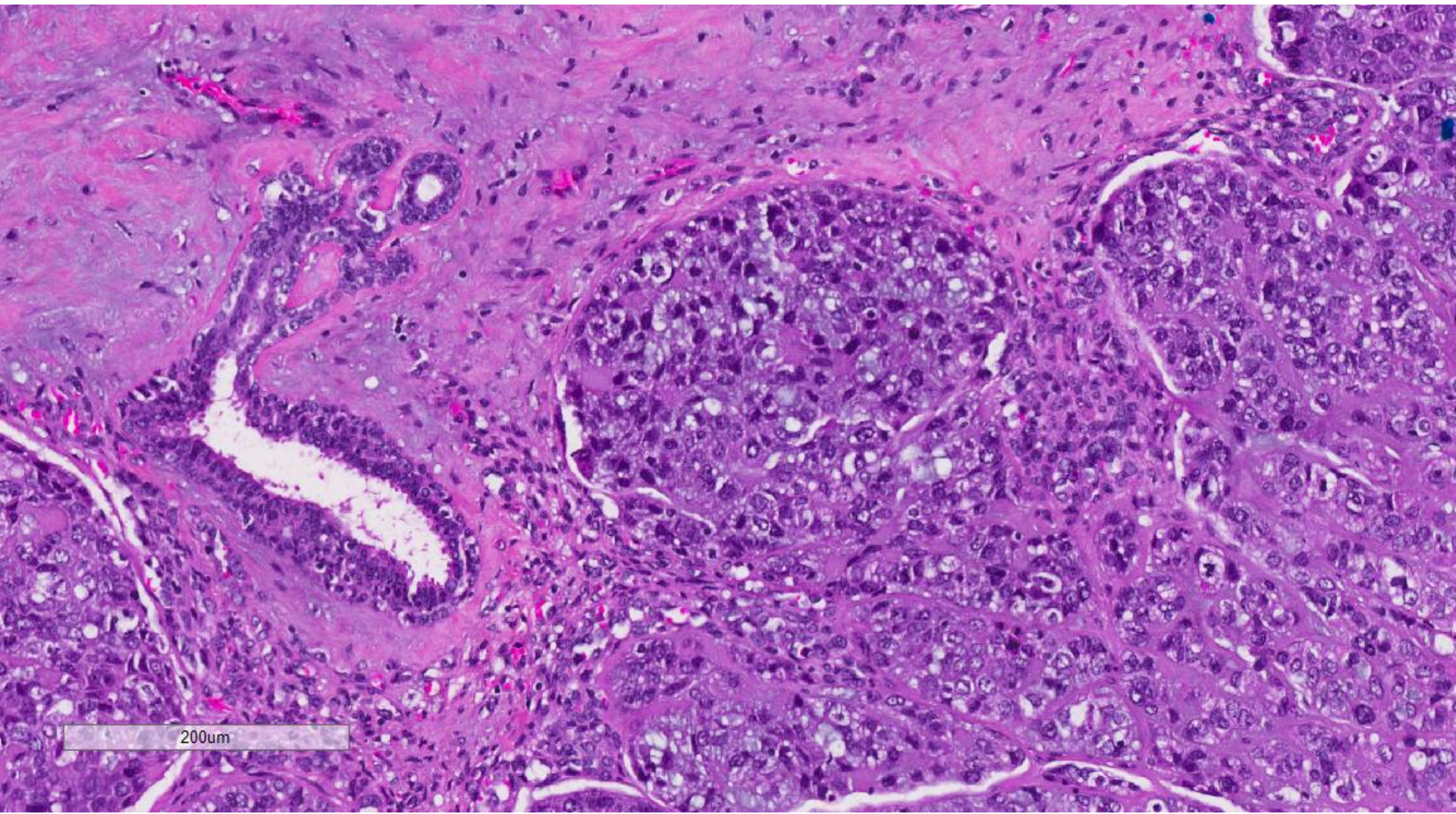


300um



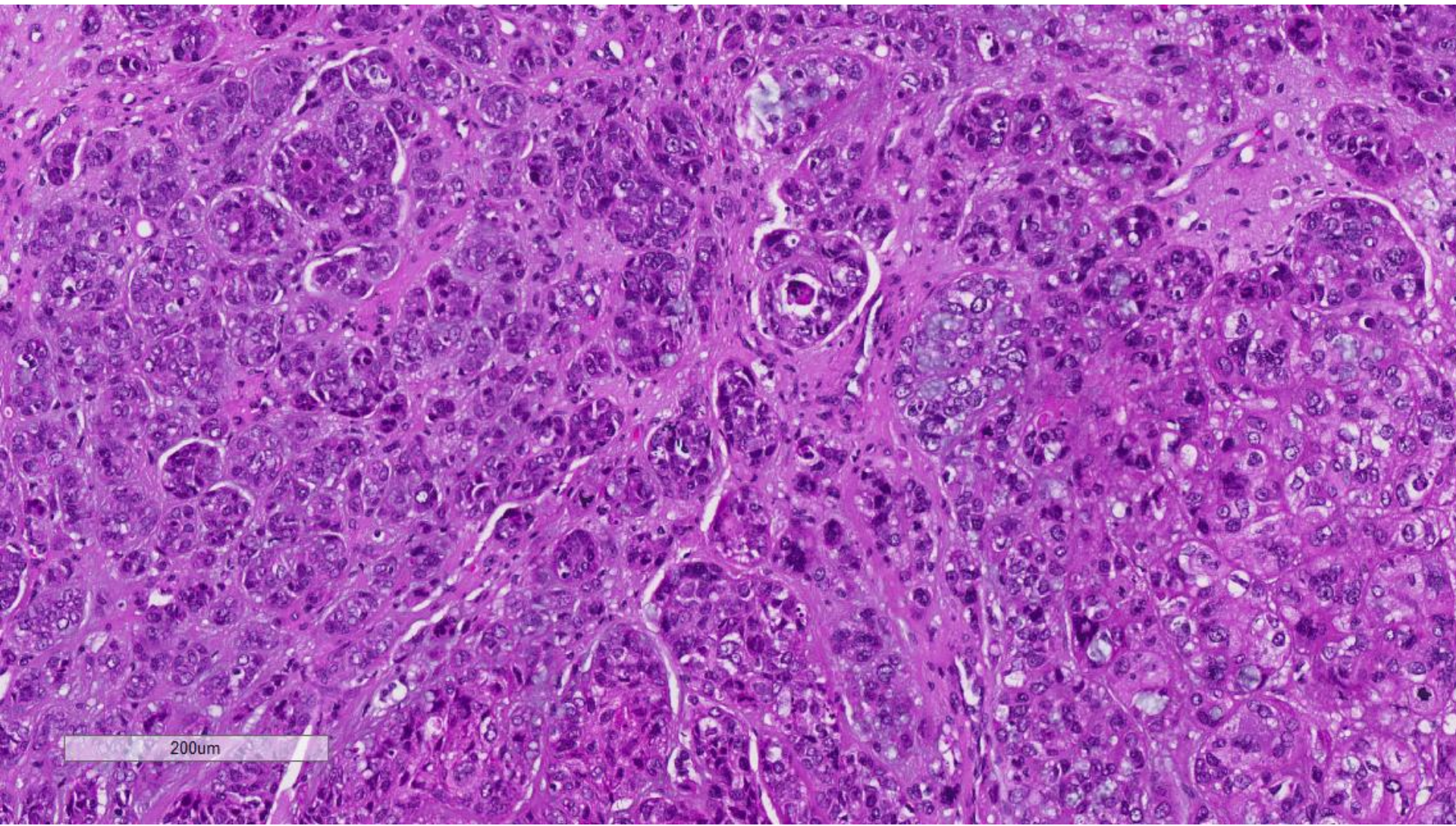
600µm



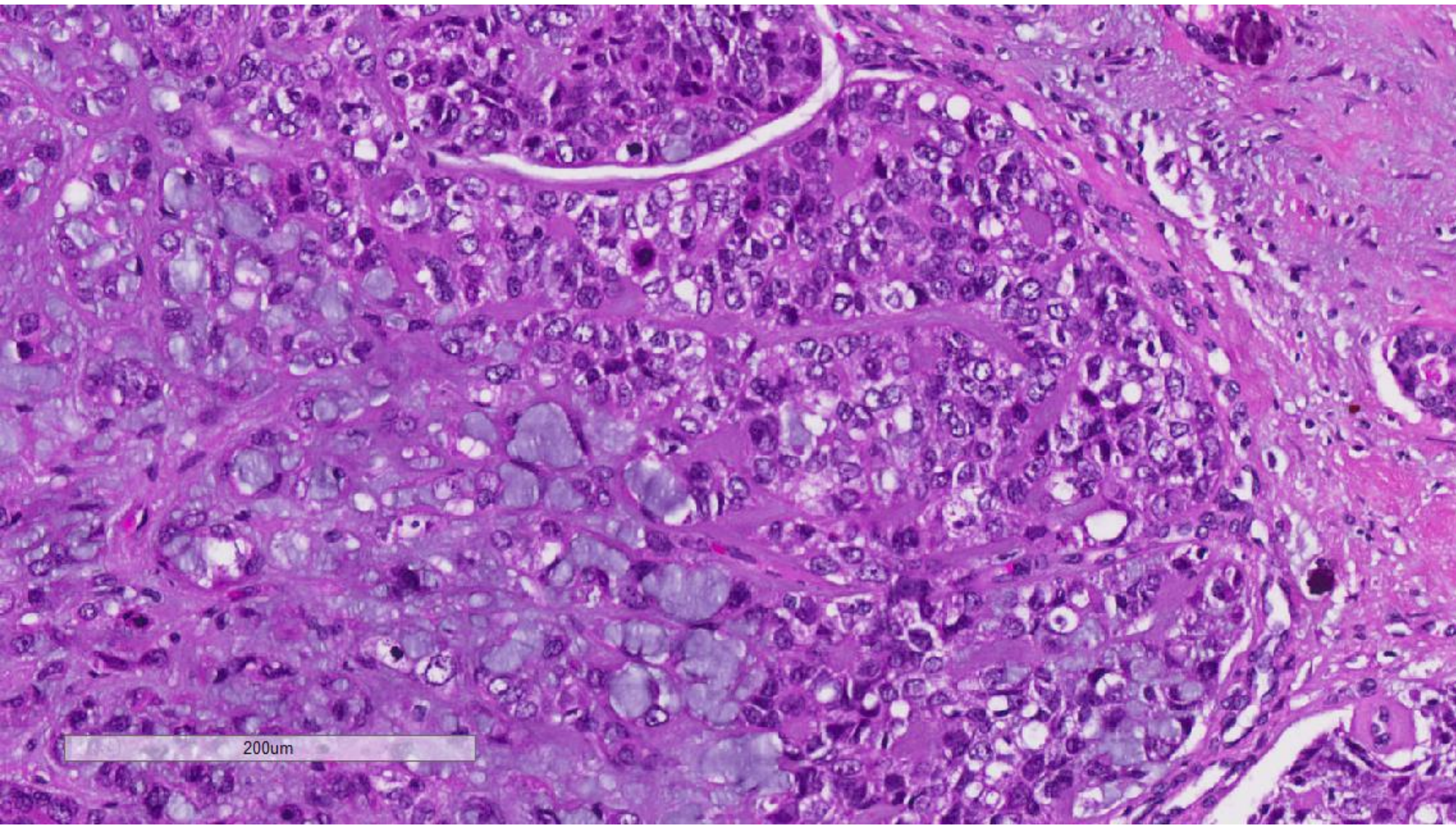


200um

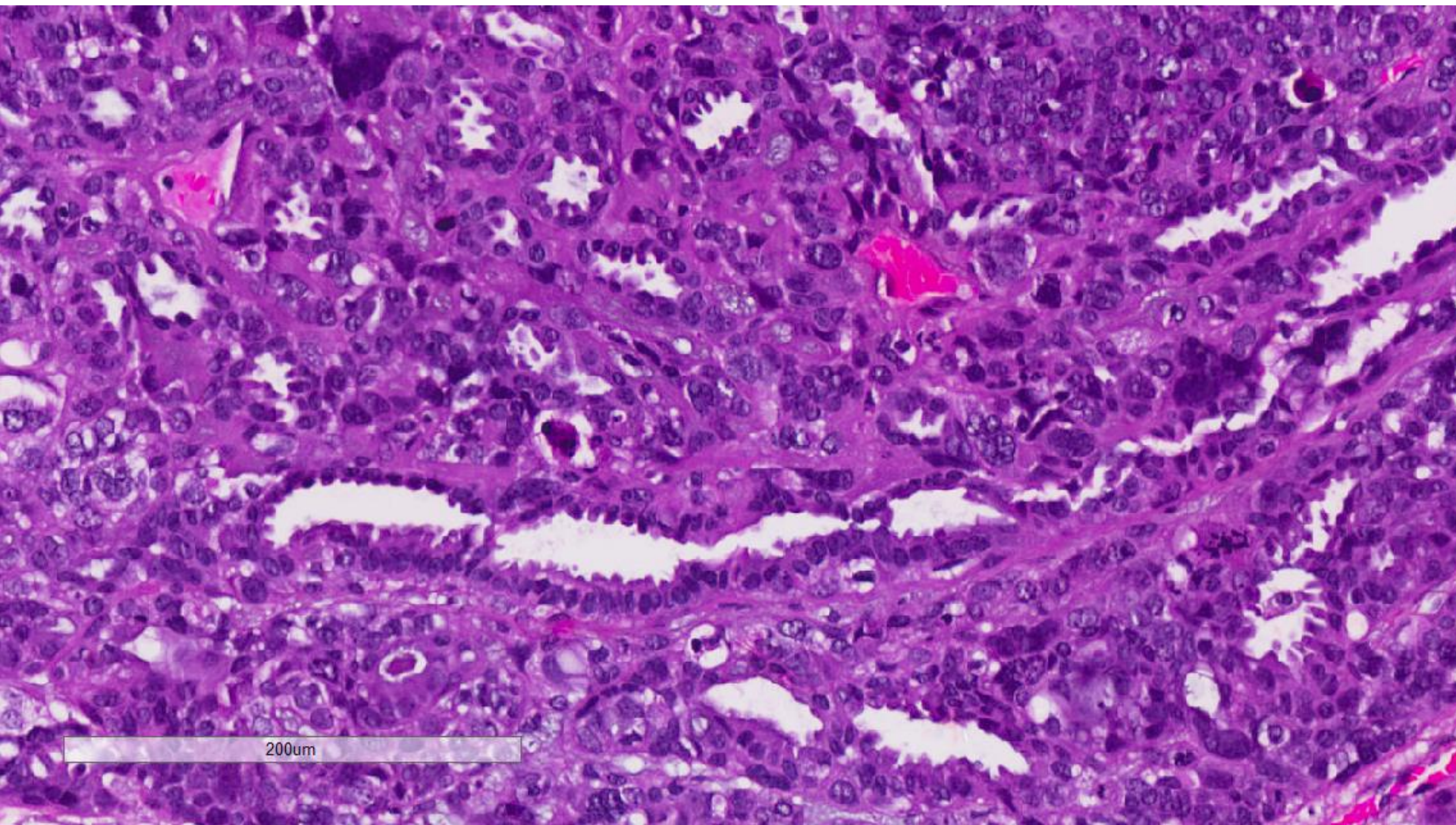




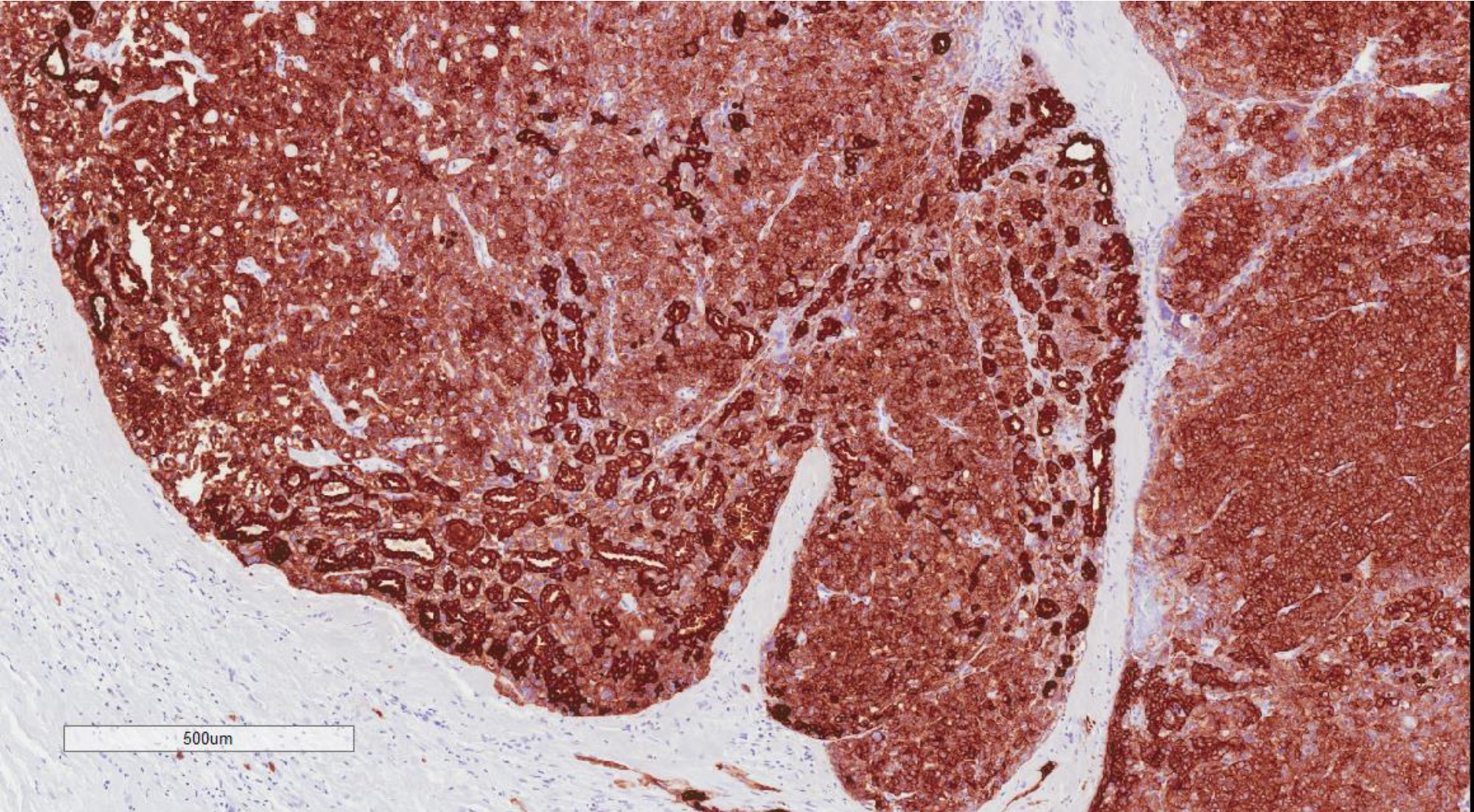
200um



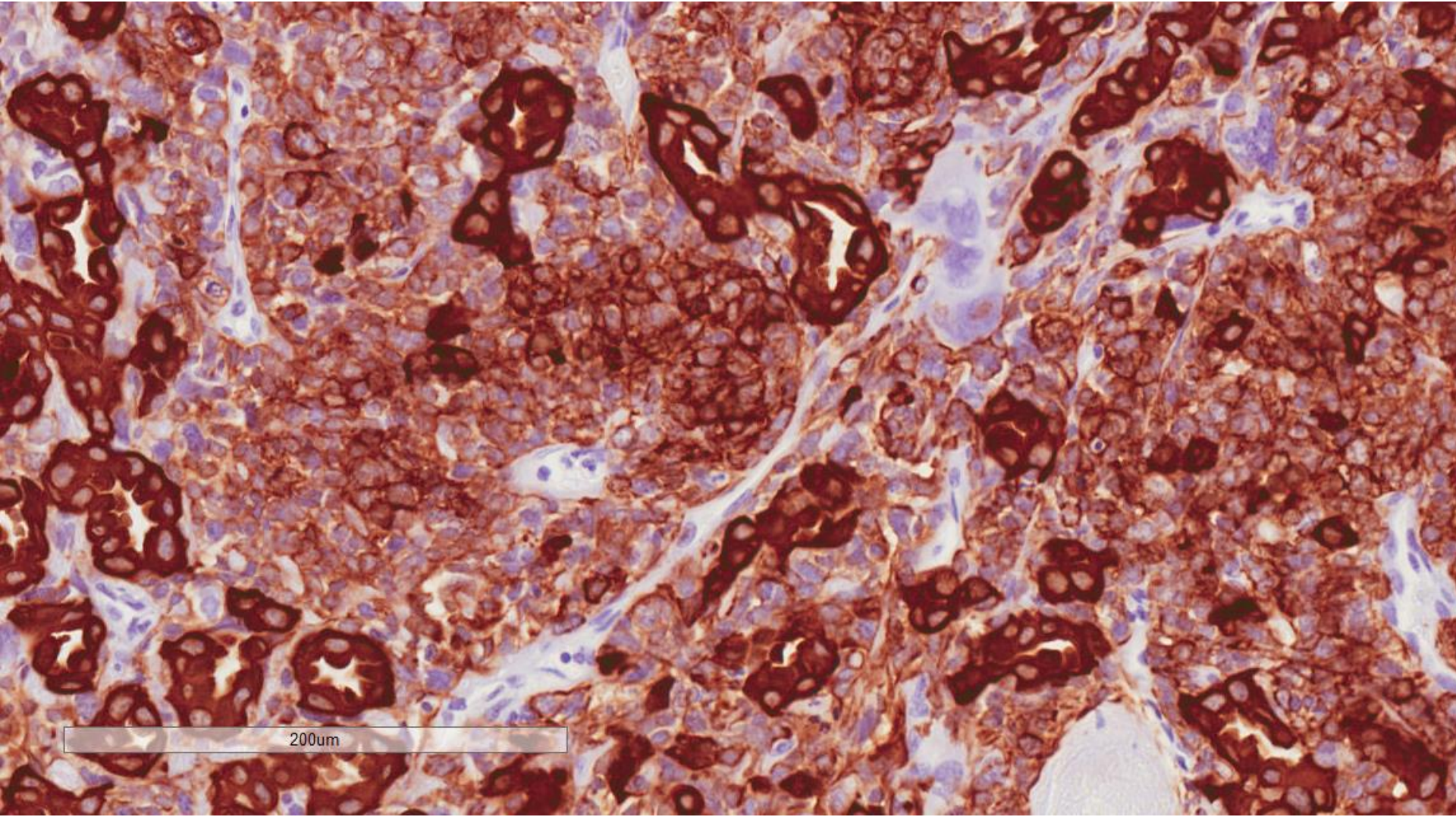
200µm



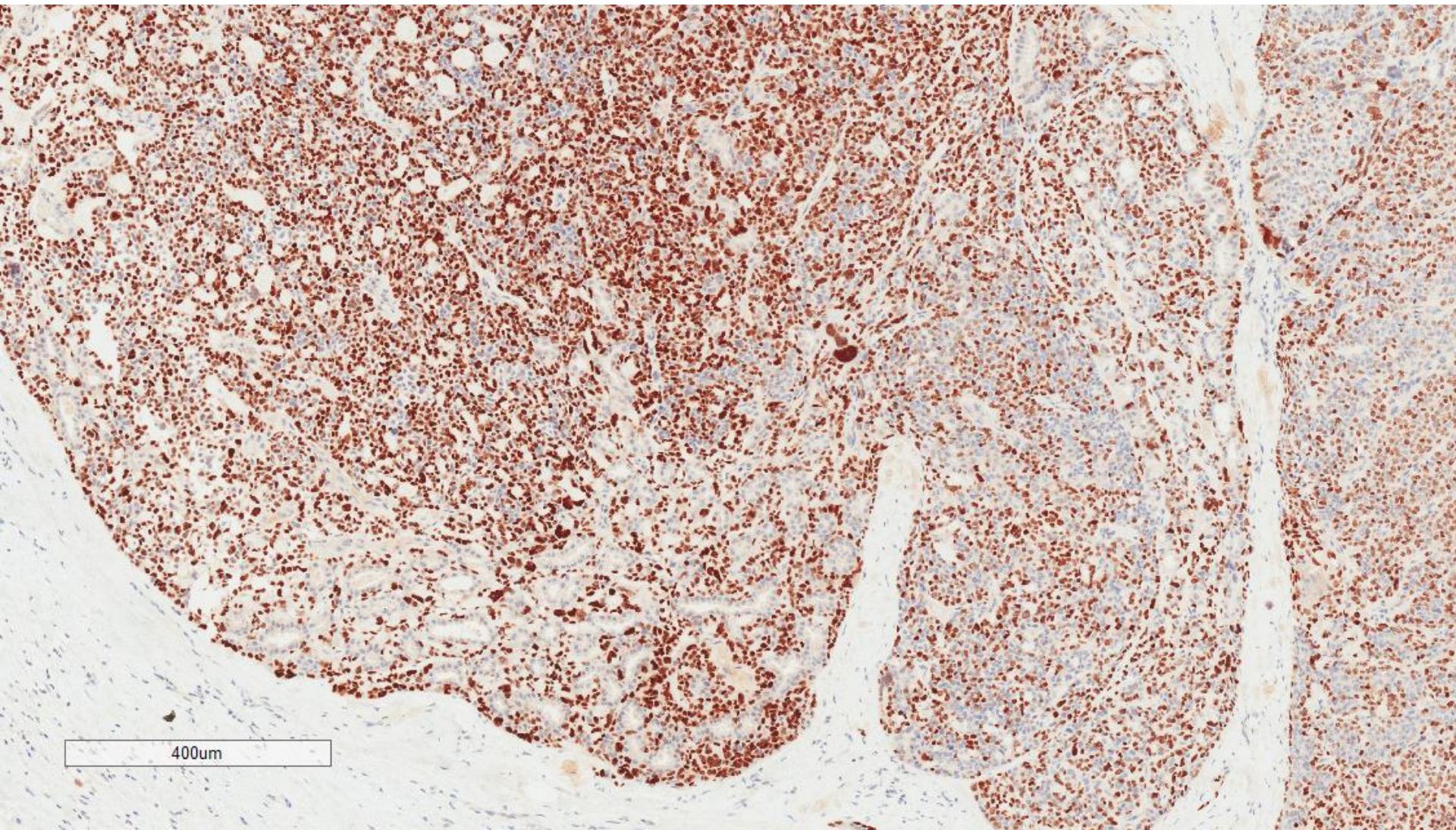
Cam 5.2



# Cam 5.2

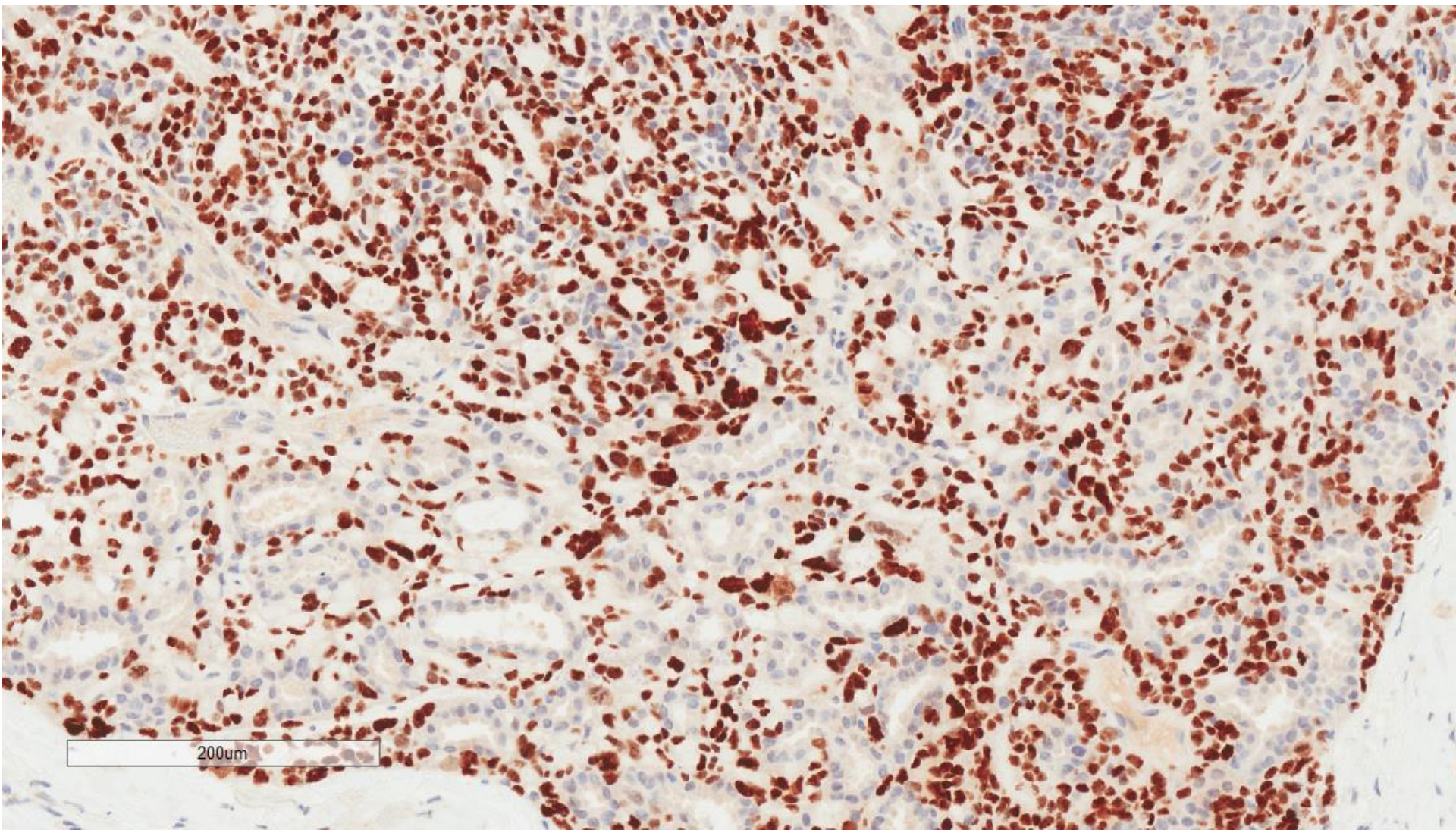


p63

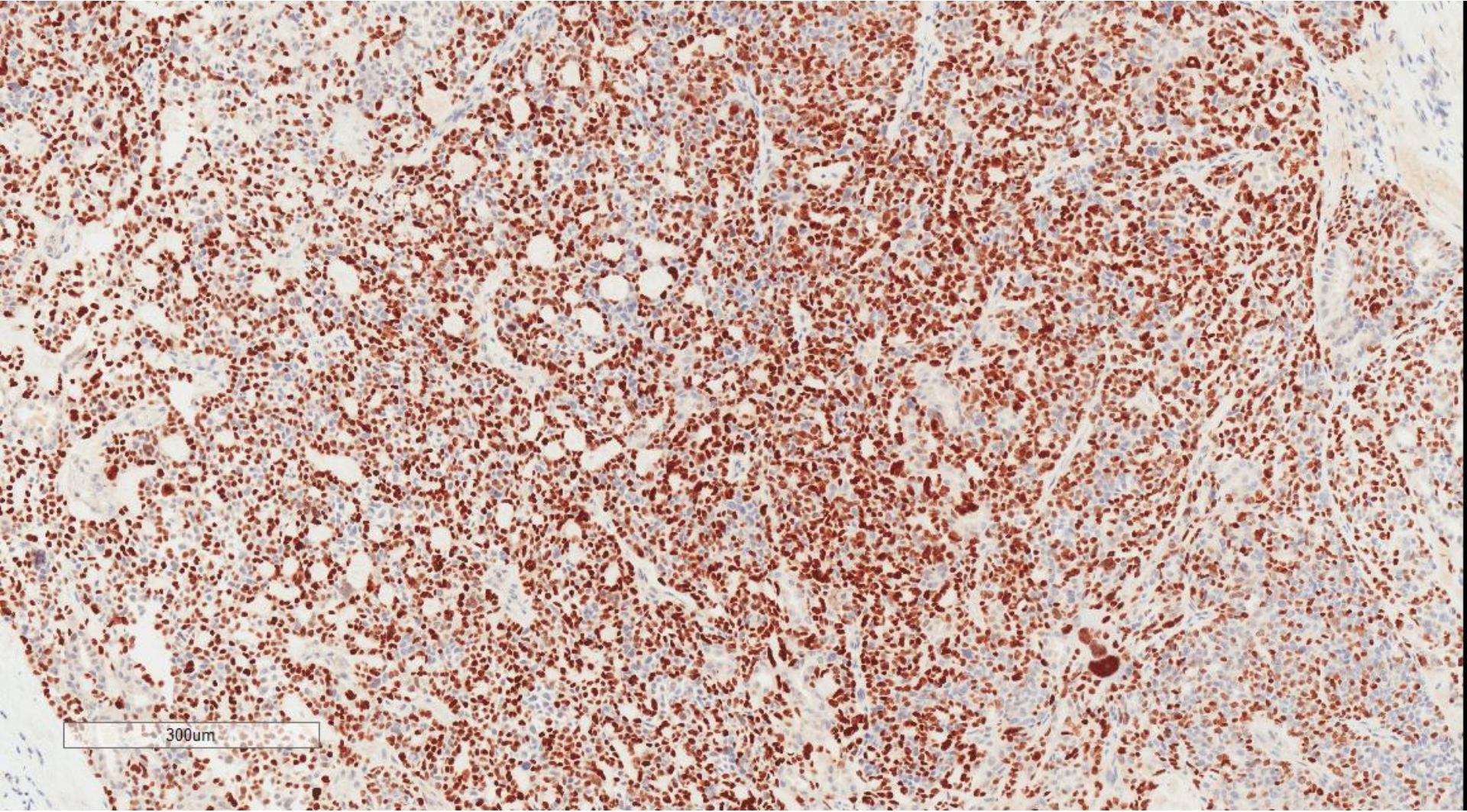


400um

p63



p63





# Metaplastic carcinoma, possibly arising in an adenomyoepithelioma