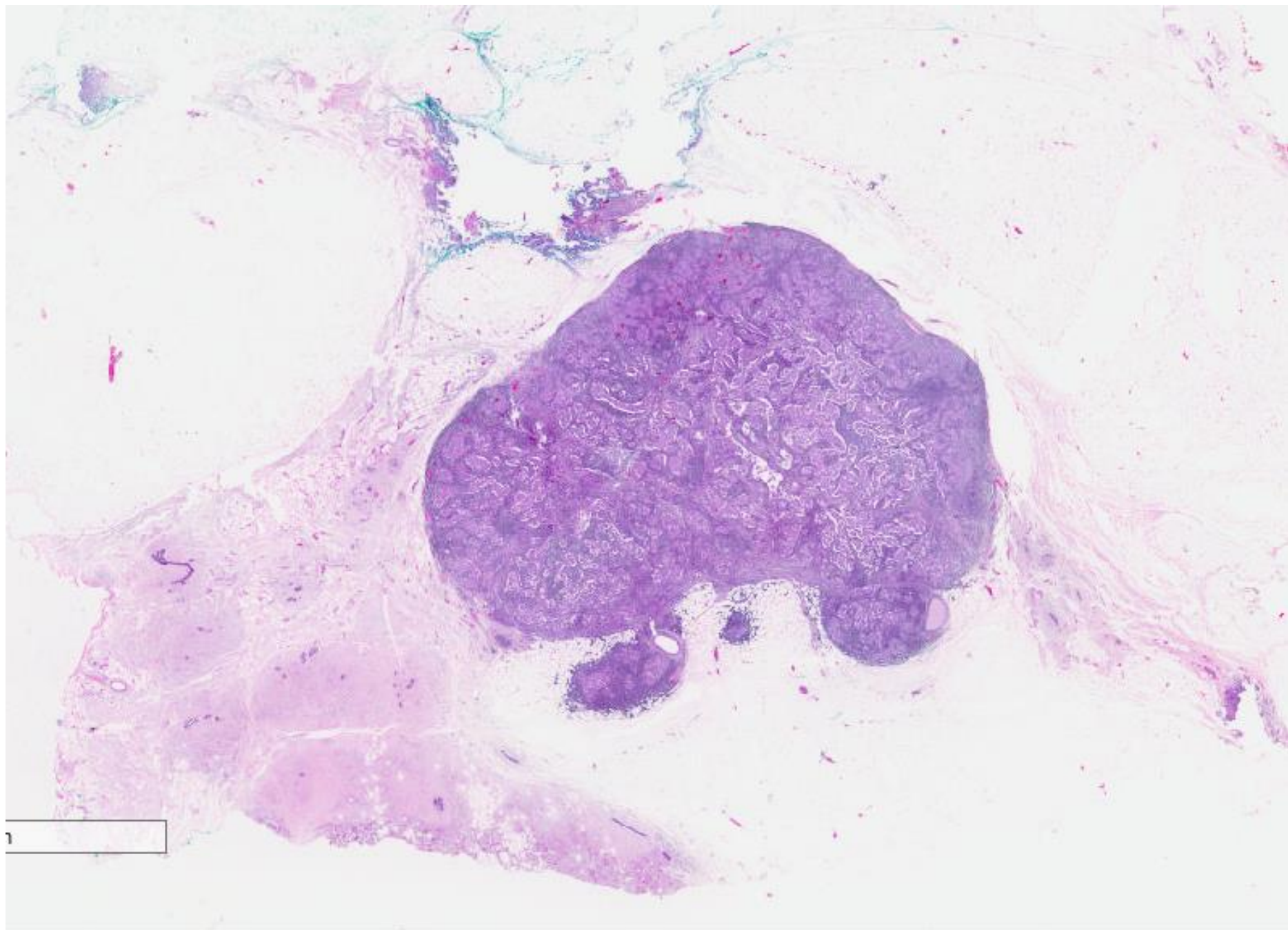
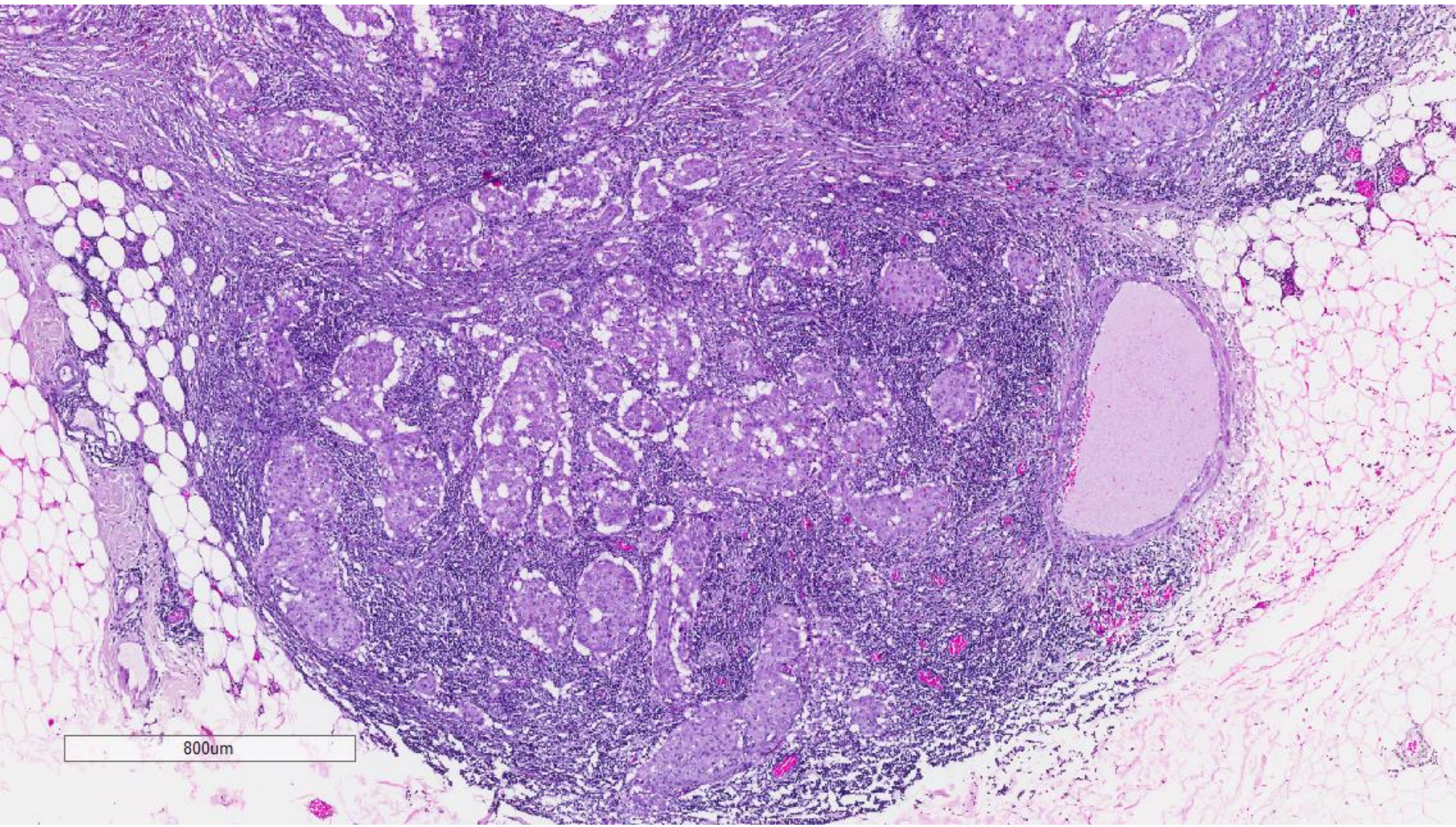


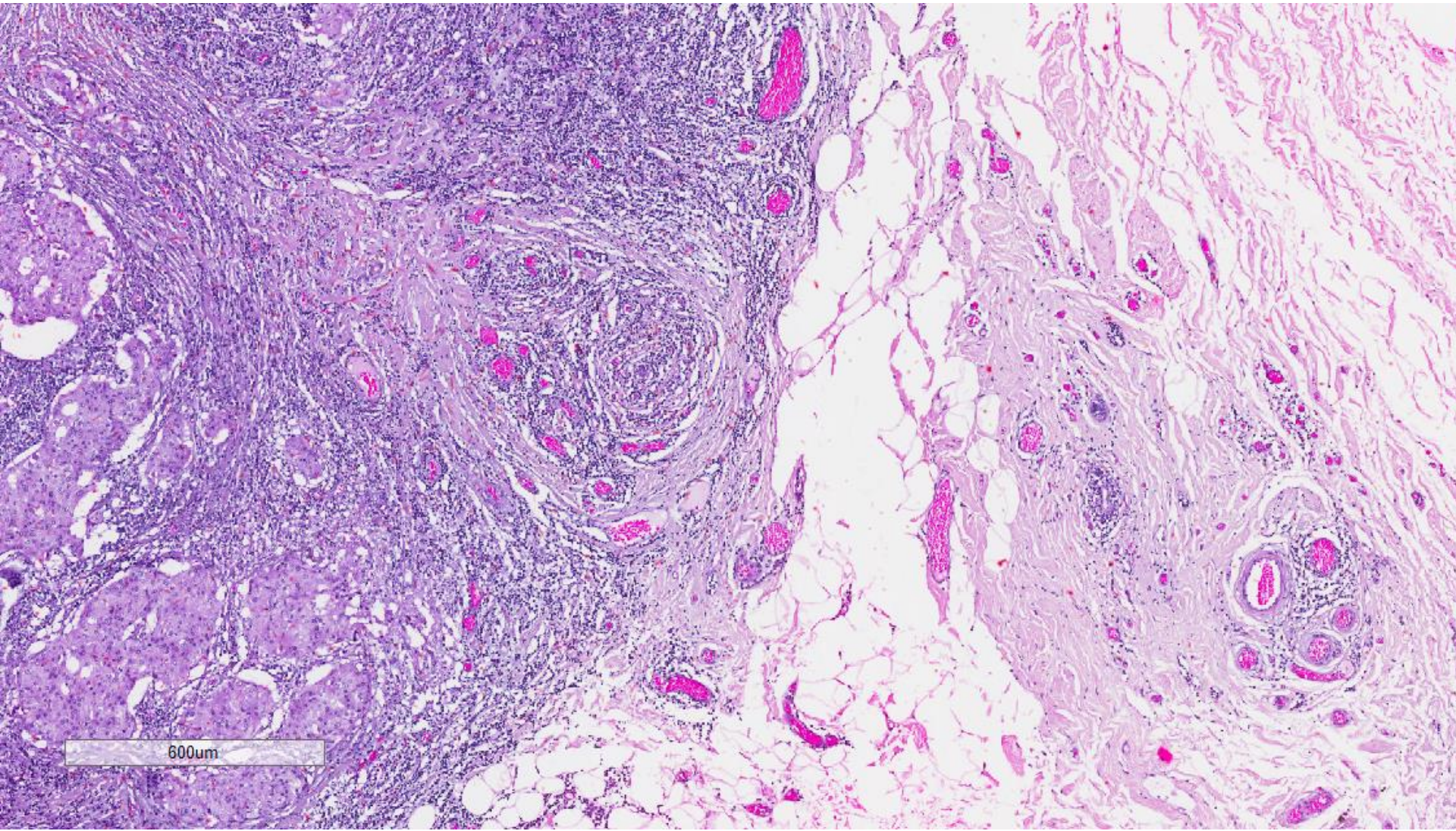
## Case 33

66 year old lady underwent a wide excision of a right breast lesion.

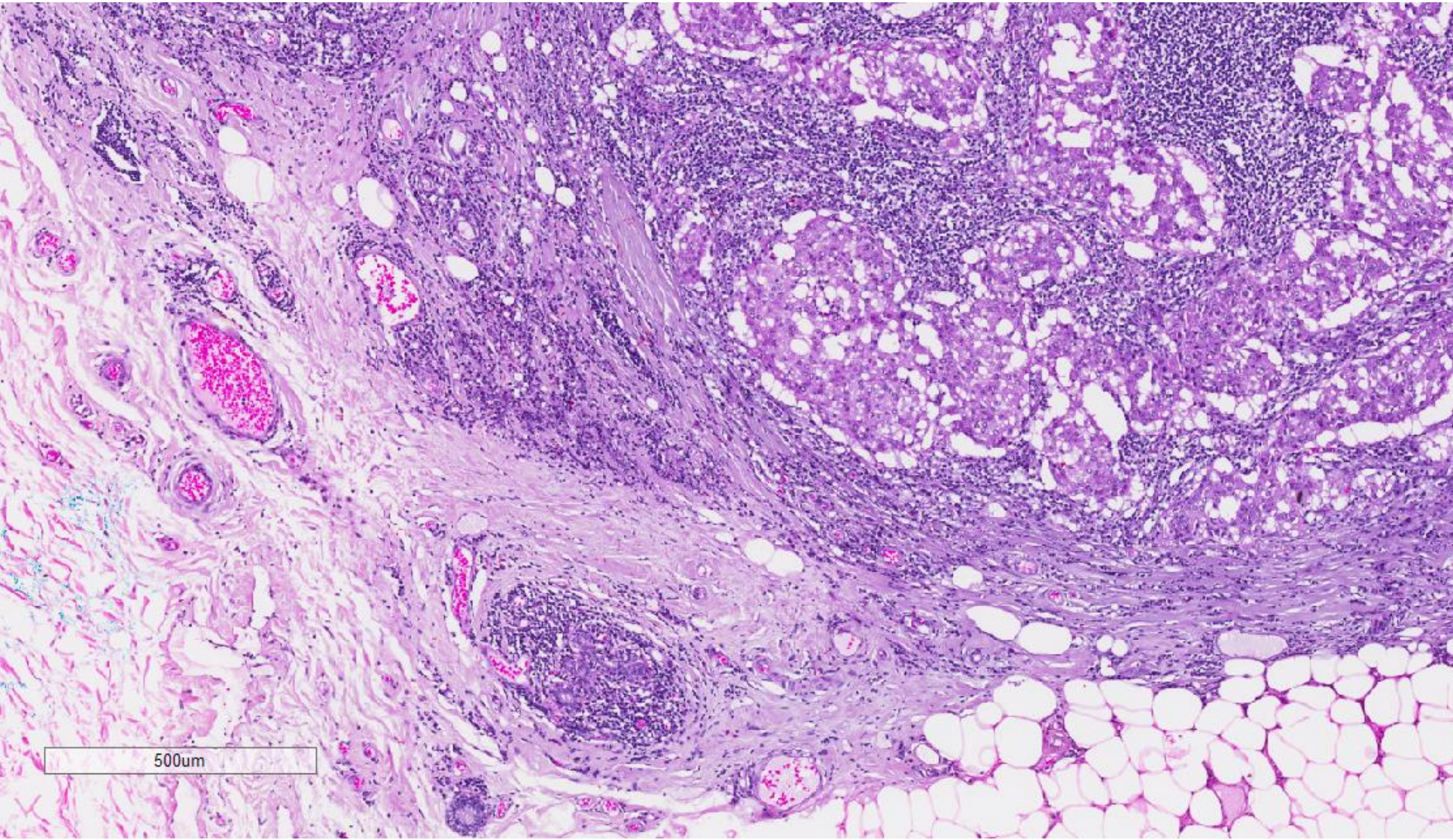




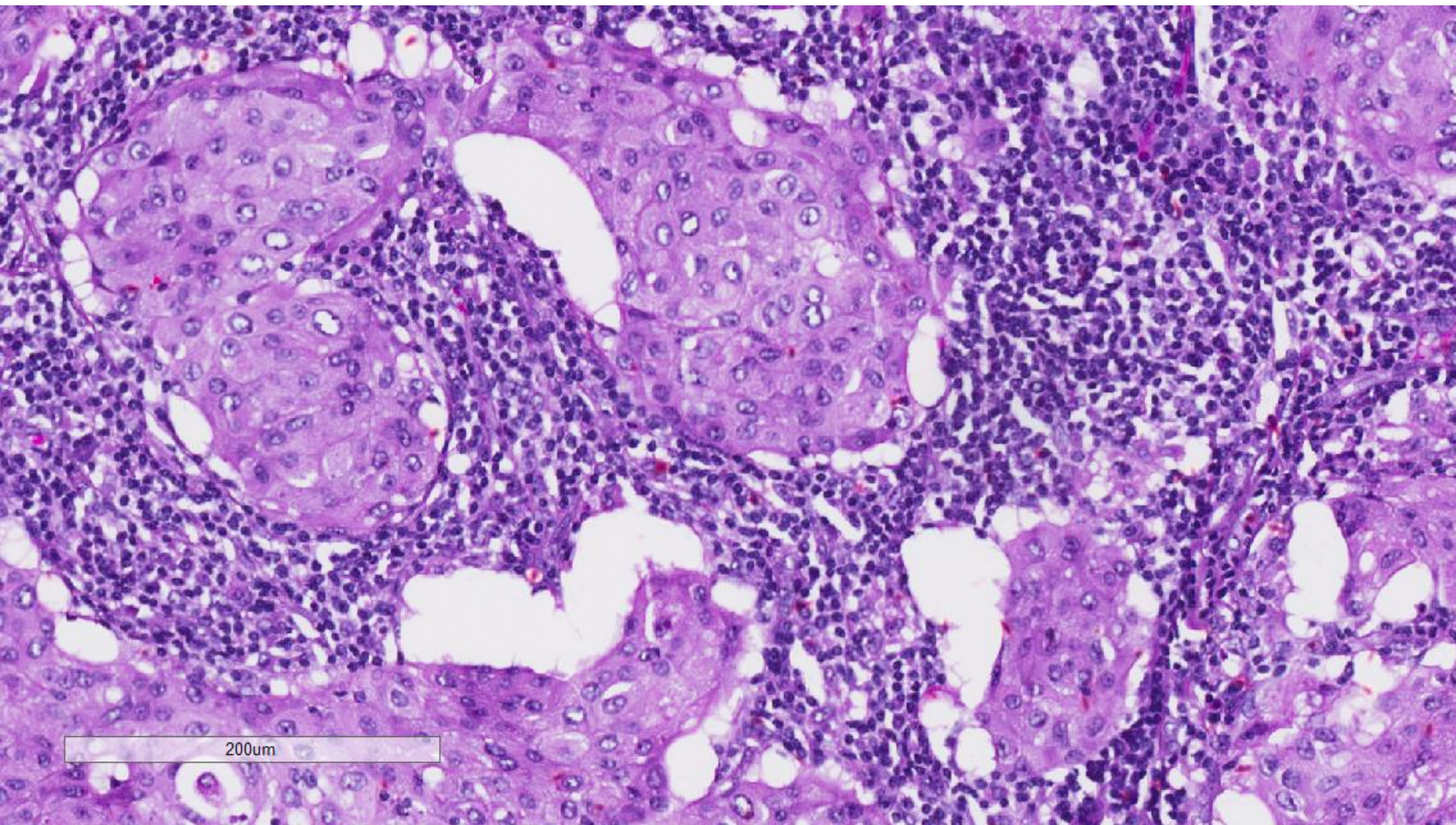
800um



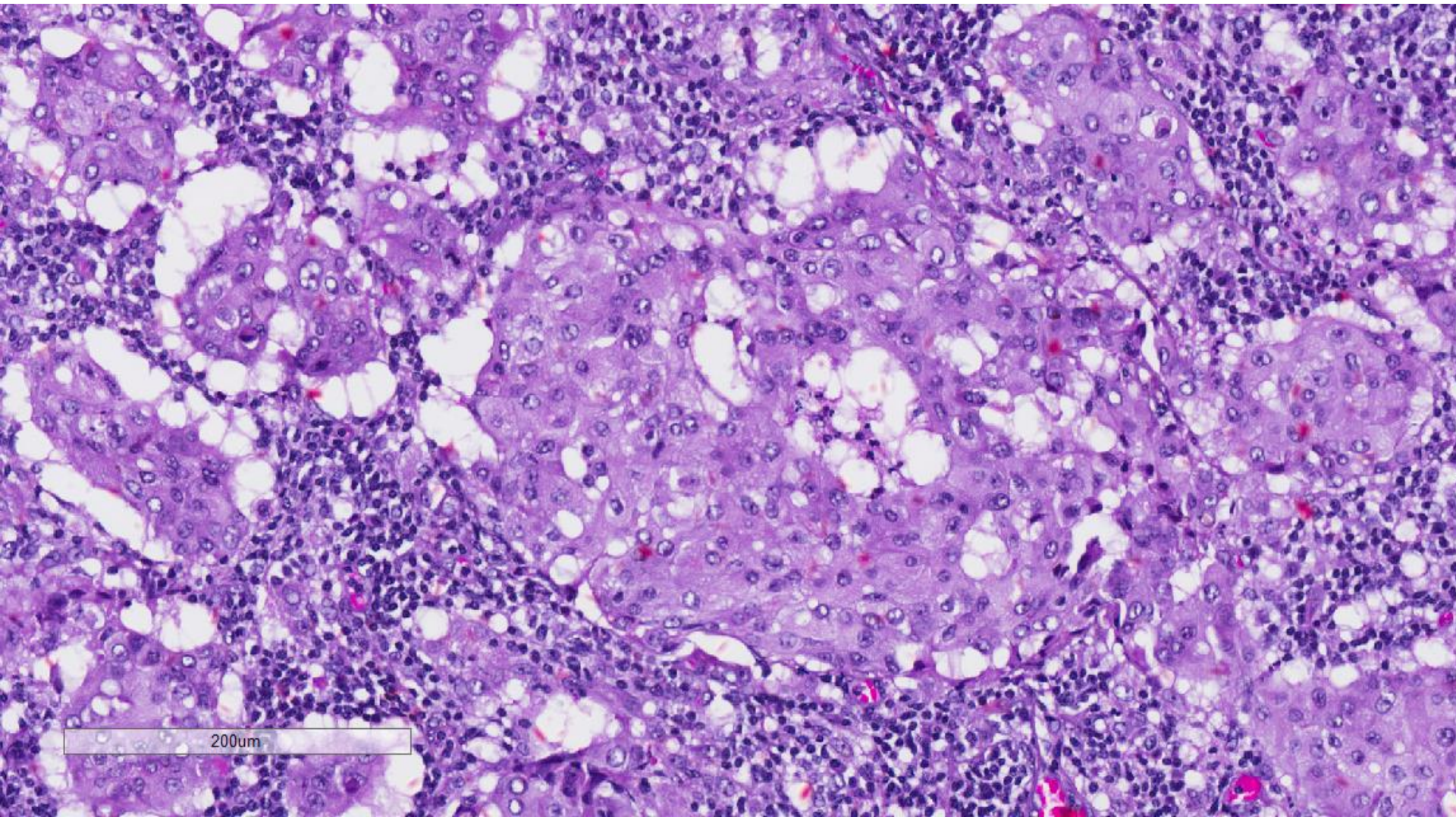
600um



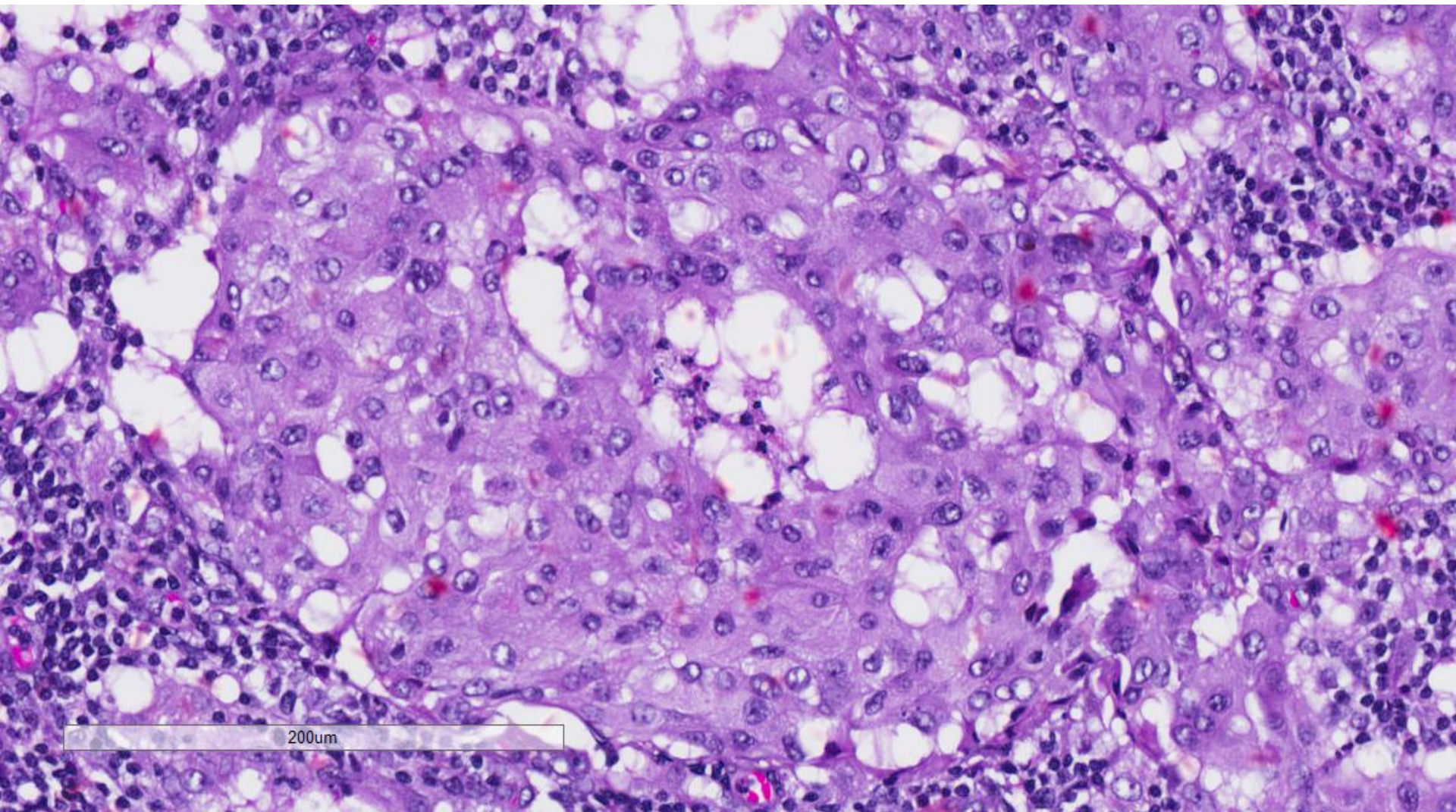
500um



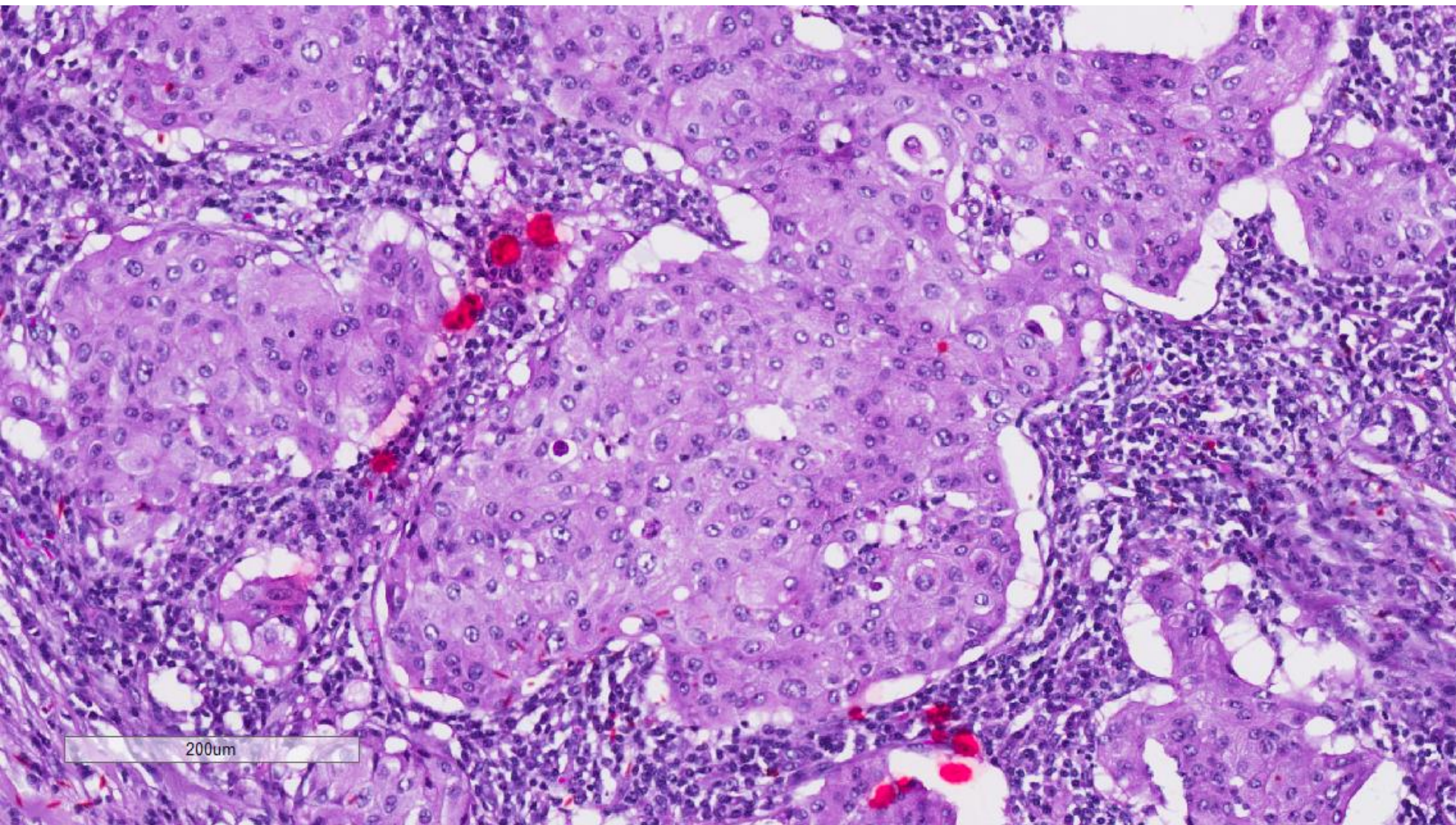
200um



200um







200µm

Invasive ductal carcinoma with apocrine & medullary-like features, grade 2, 10 mm; ER negative, PR negative, cerbB2 positive (3+)