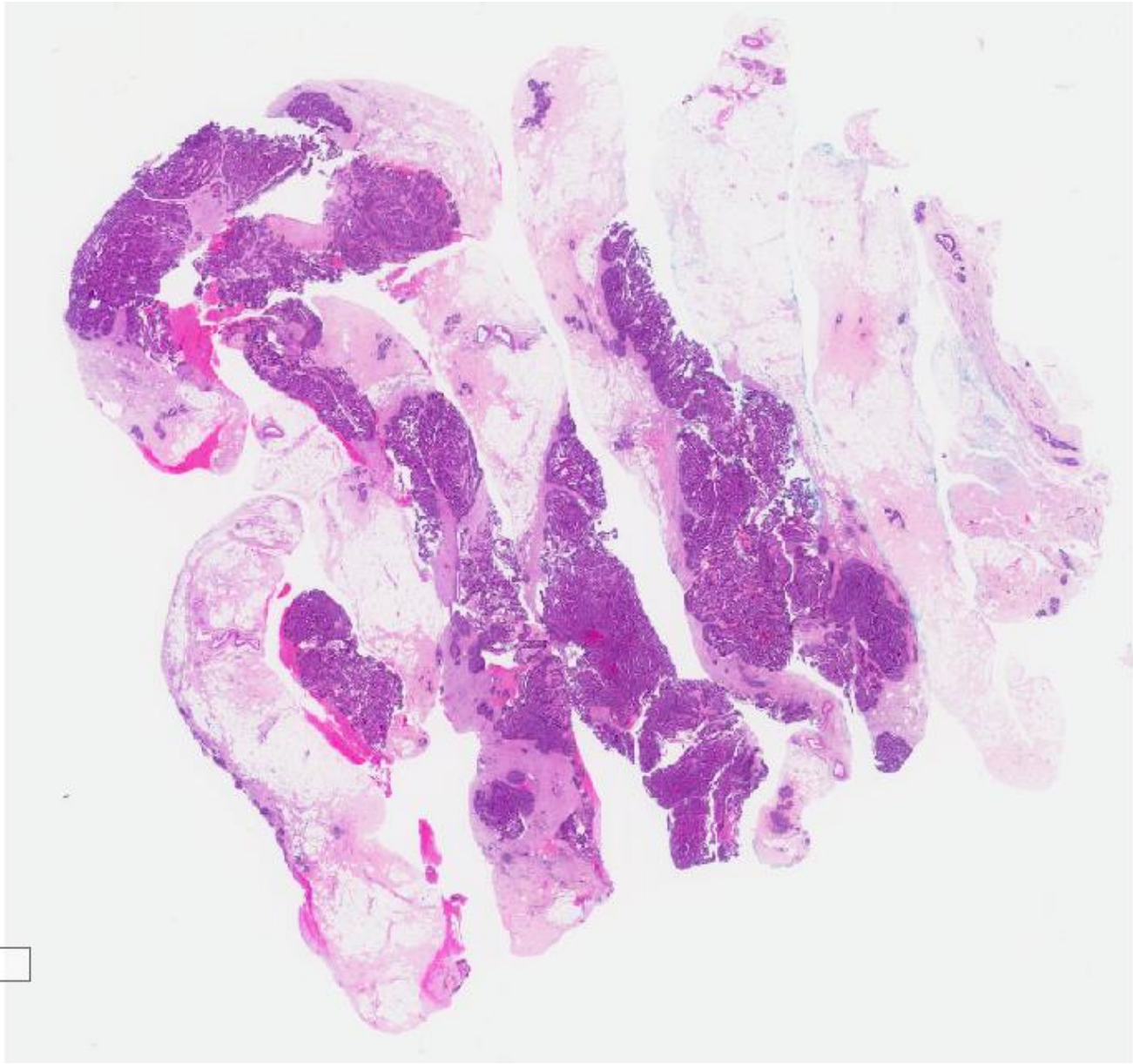


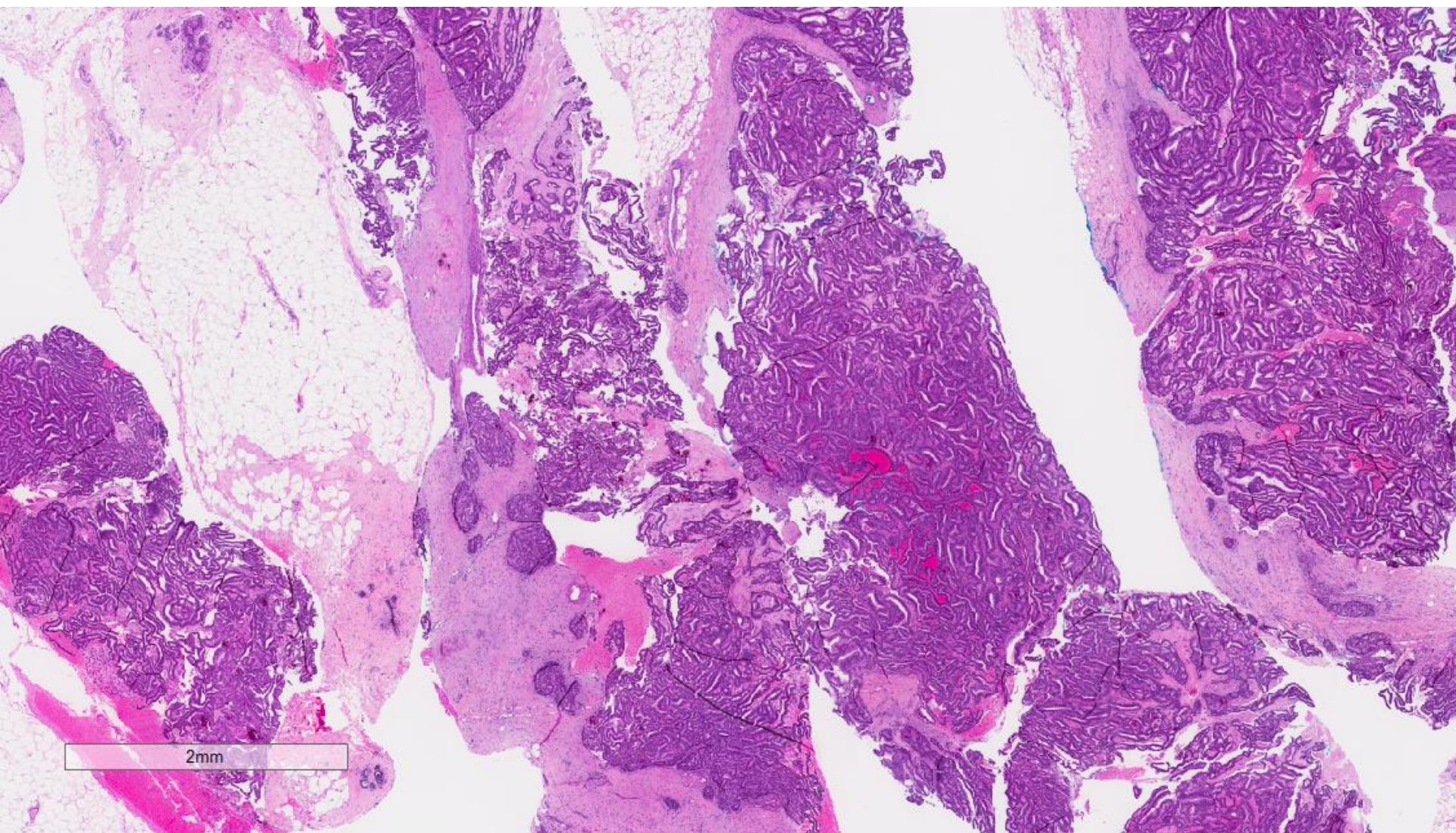
## Case 27

51 year old lady underwent ultrasound mammotome biopsy of a right breast nodule, thought radiologically to be a fibroadenoma.

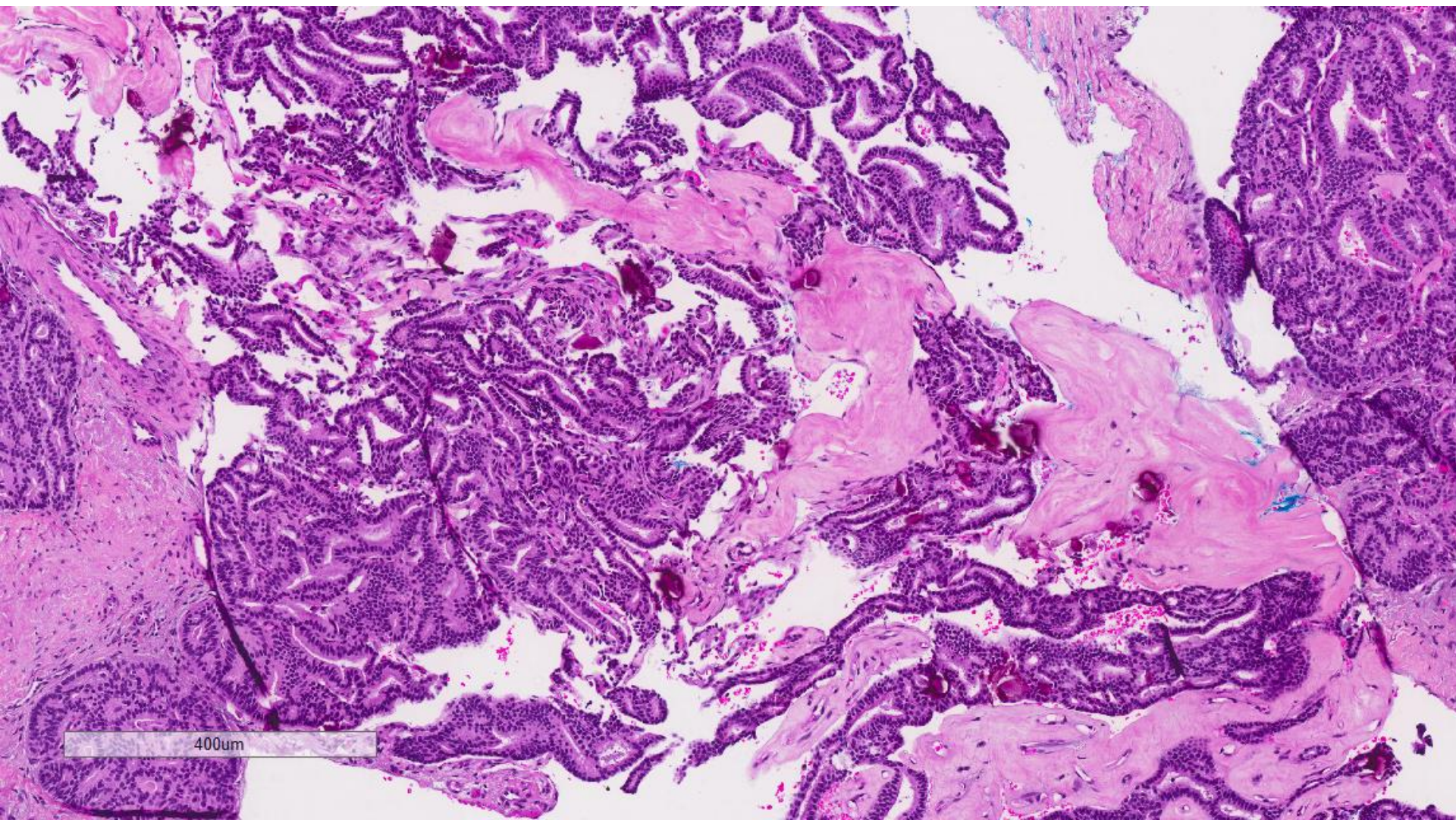


7mm

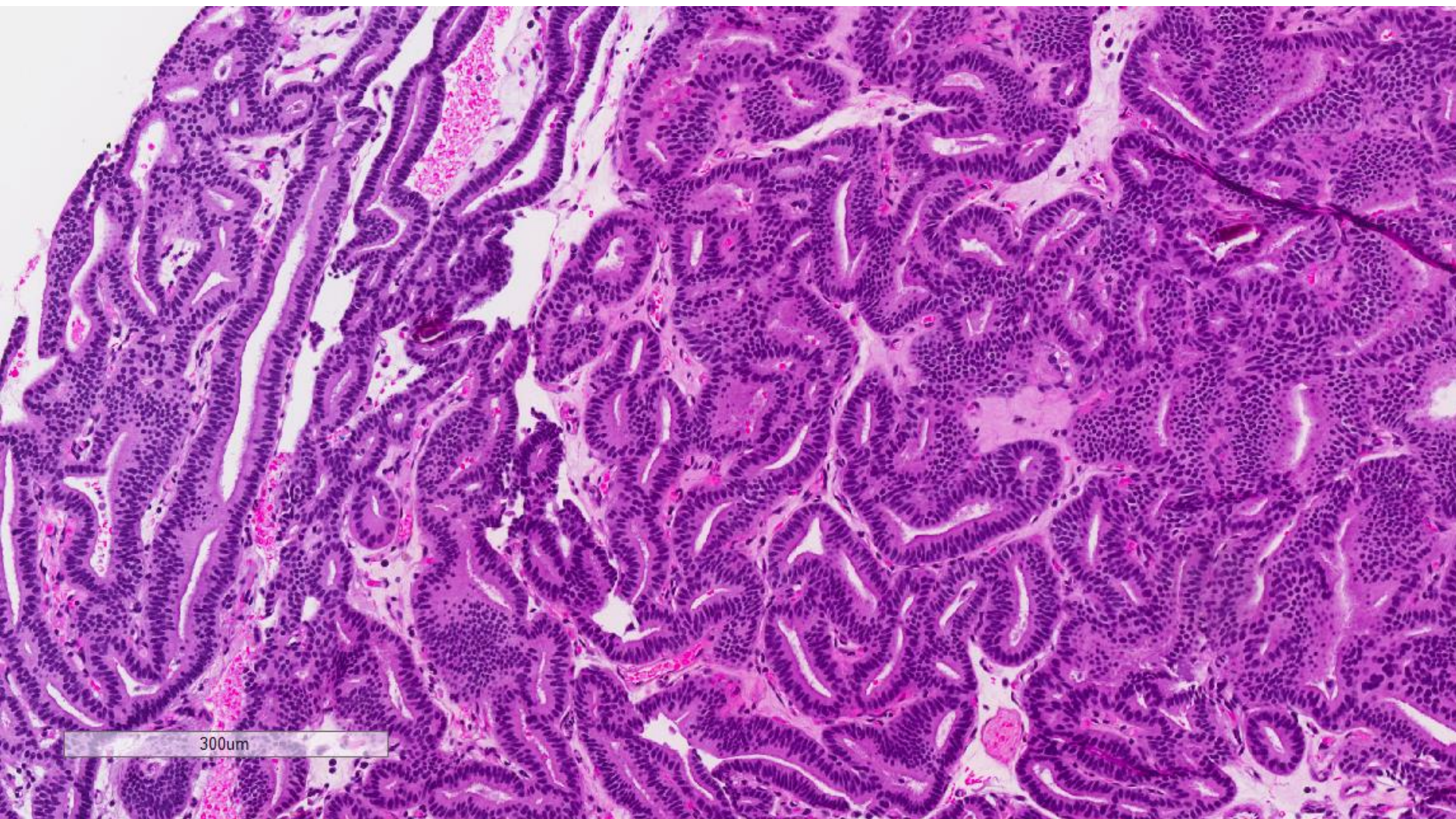




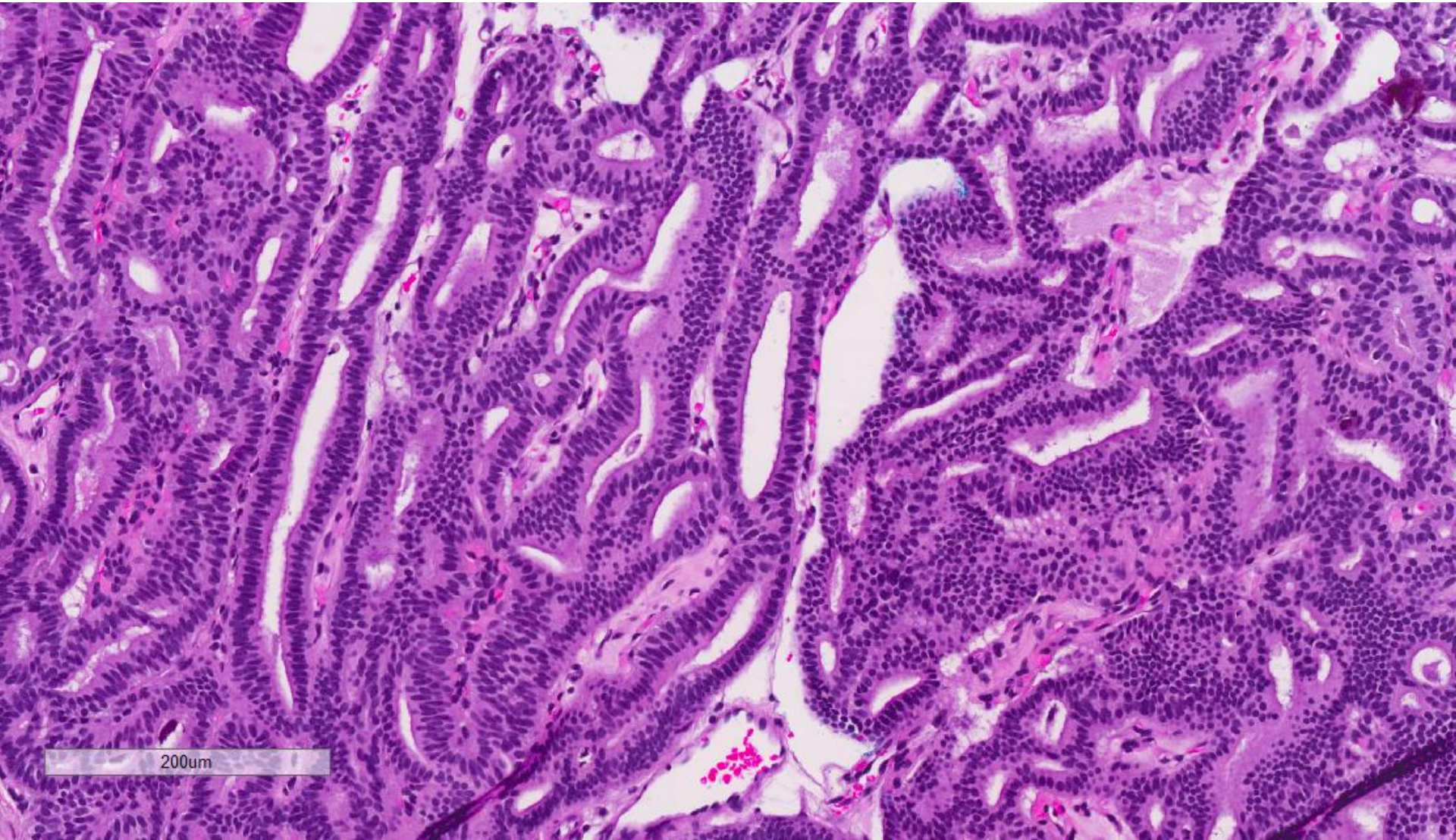






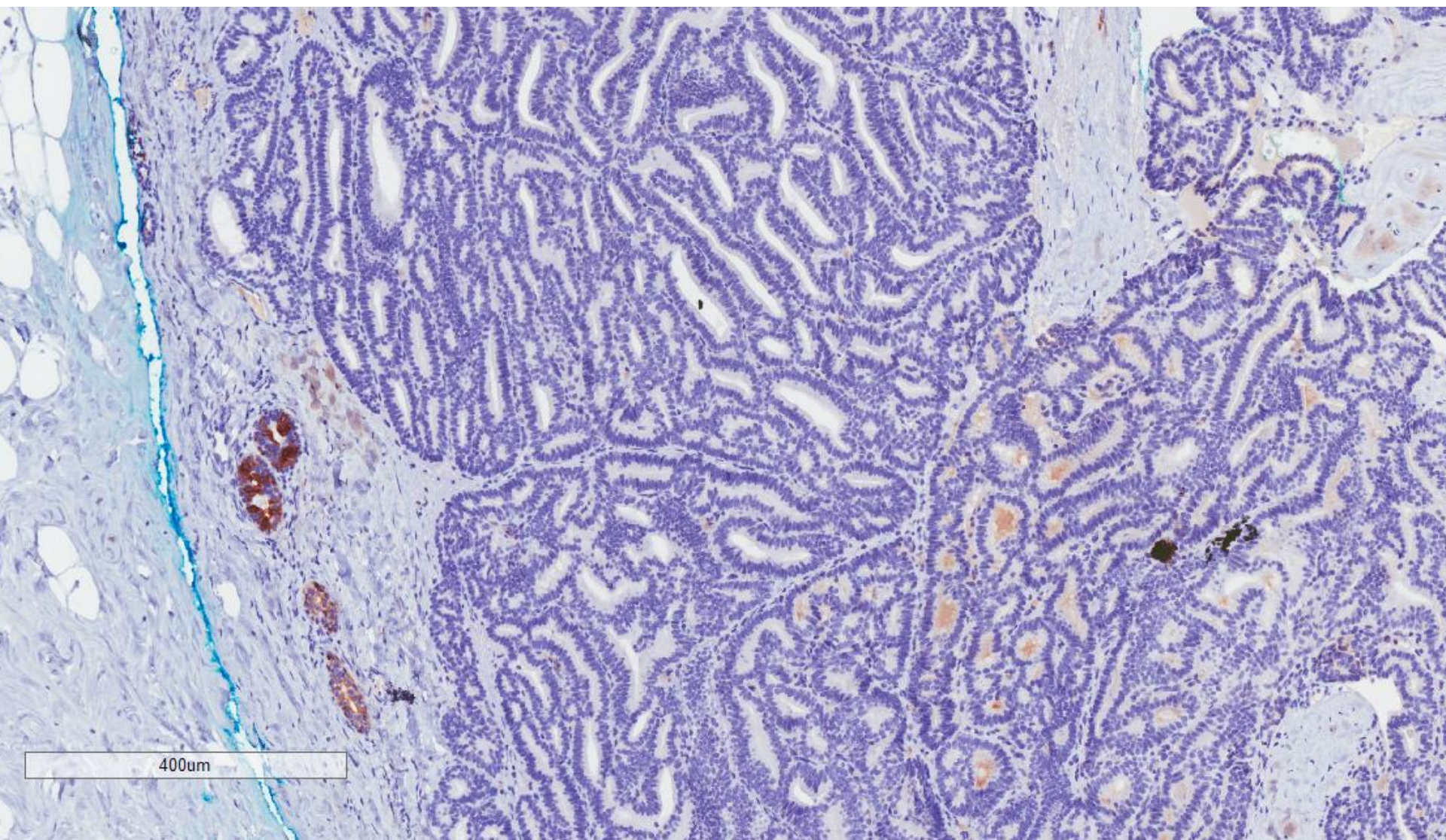






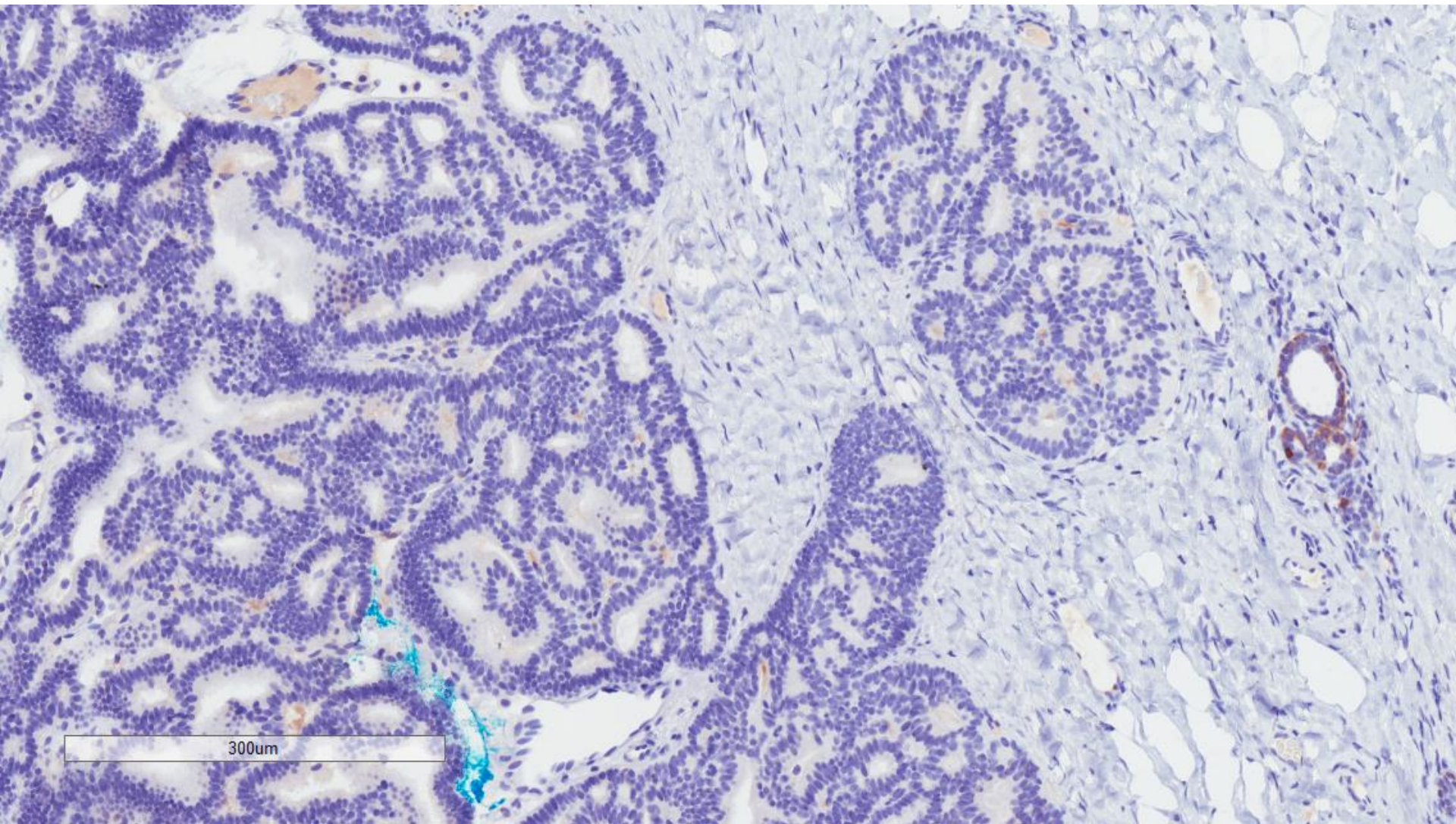


CK5/6



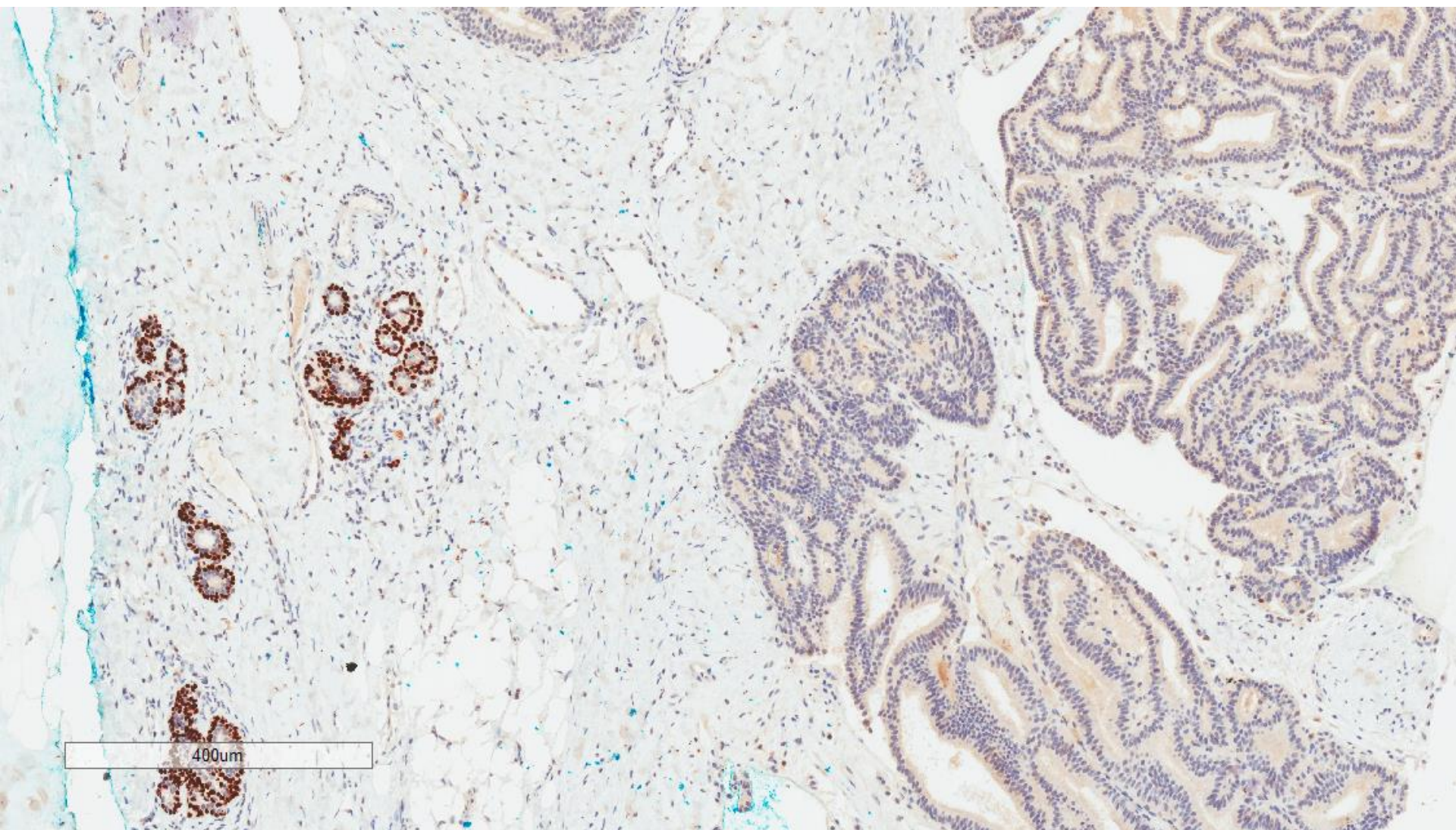


CK5/6



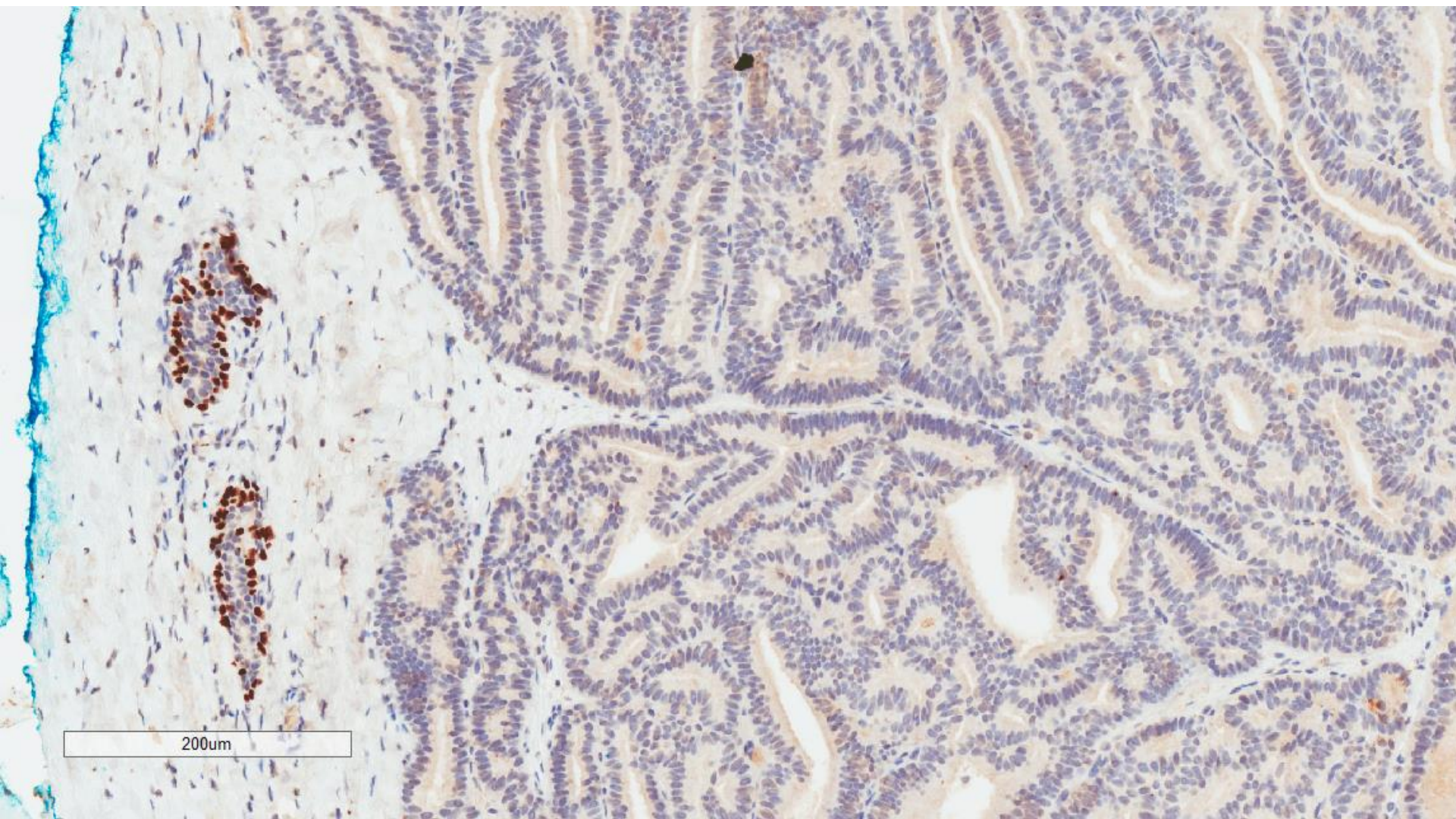


p63



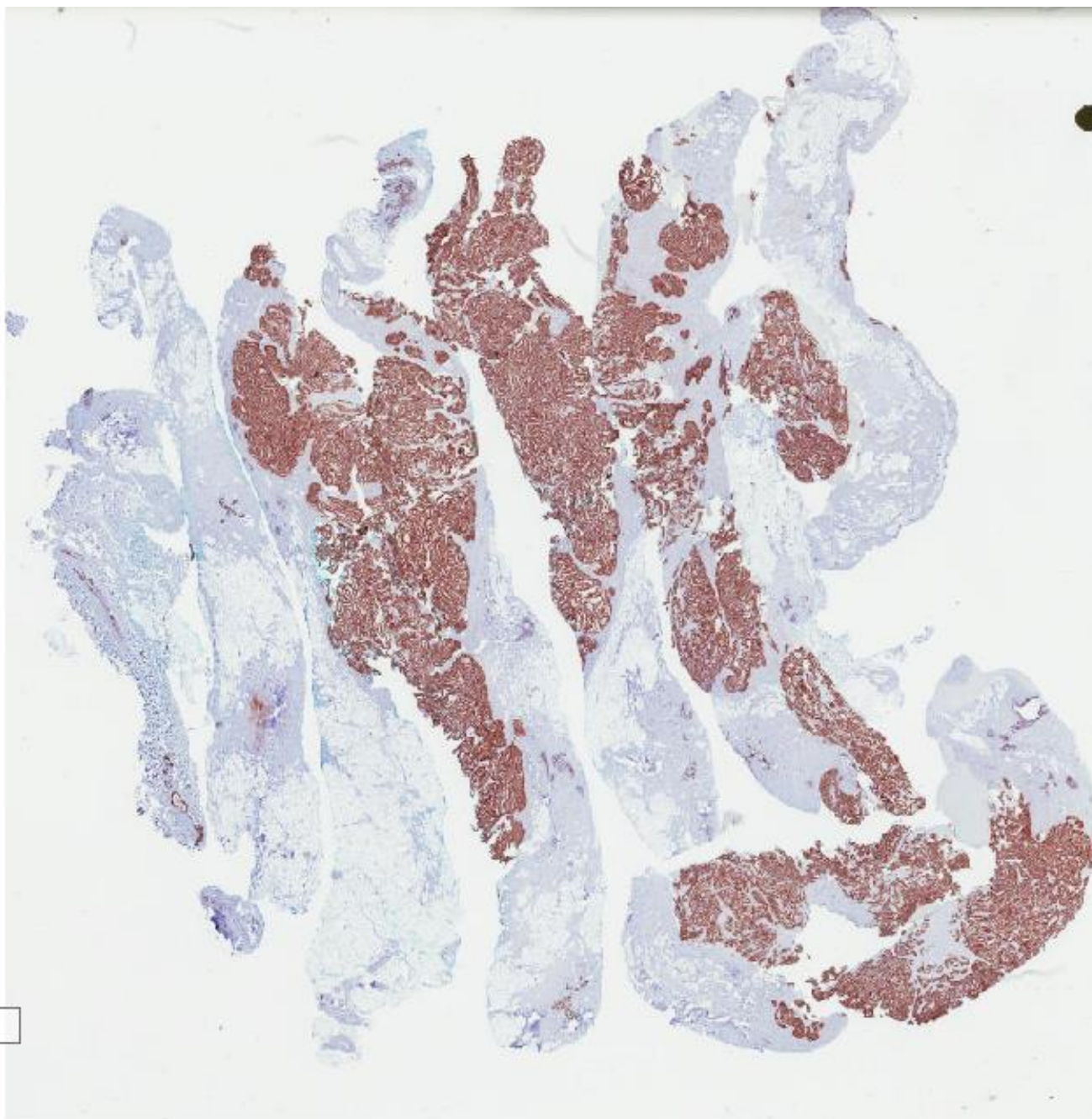


p63





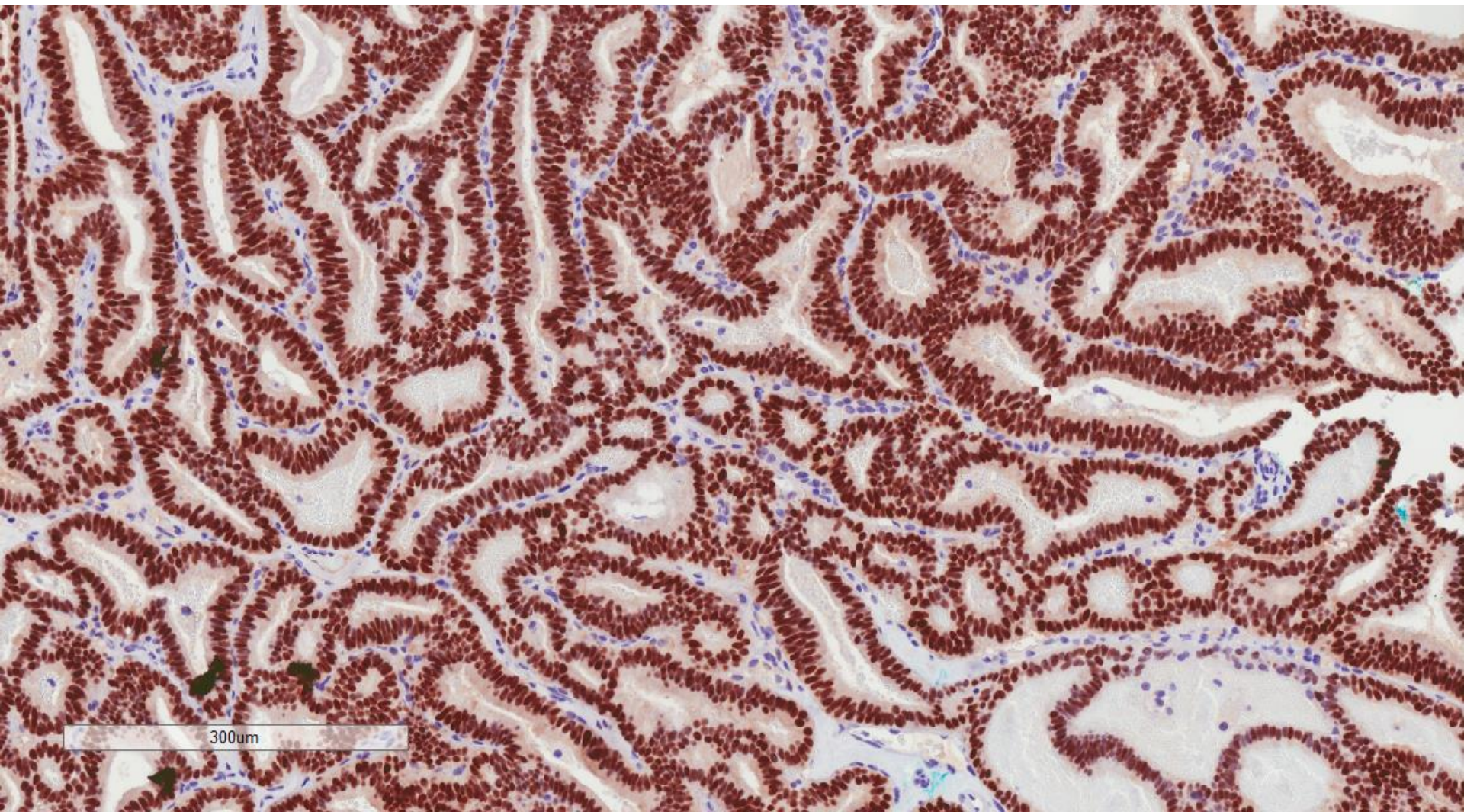
ER



7mm



ER





Ultrasound mammotome biopsy, right  
breast lesion:  
Consistent with encapsulated papillary  
carcinoma



# *Subsequent wide excision of the right breast lesion*

- Residual encapsulated papillary carcinoma, 1.2 cm.
- Resection margins are clear.