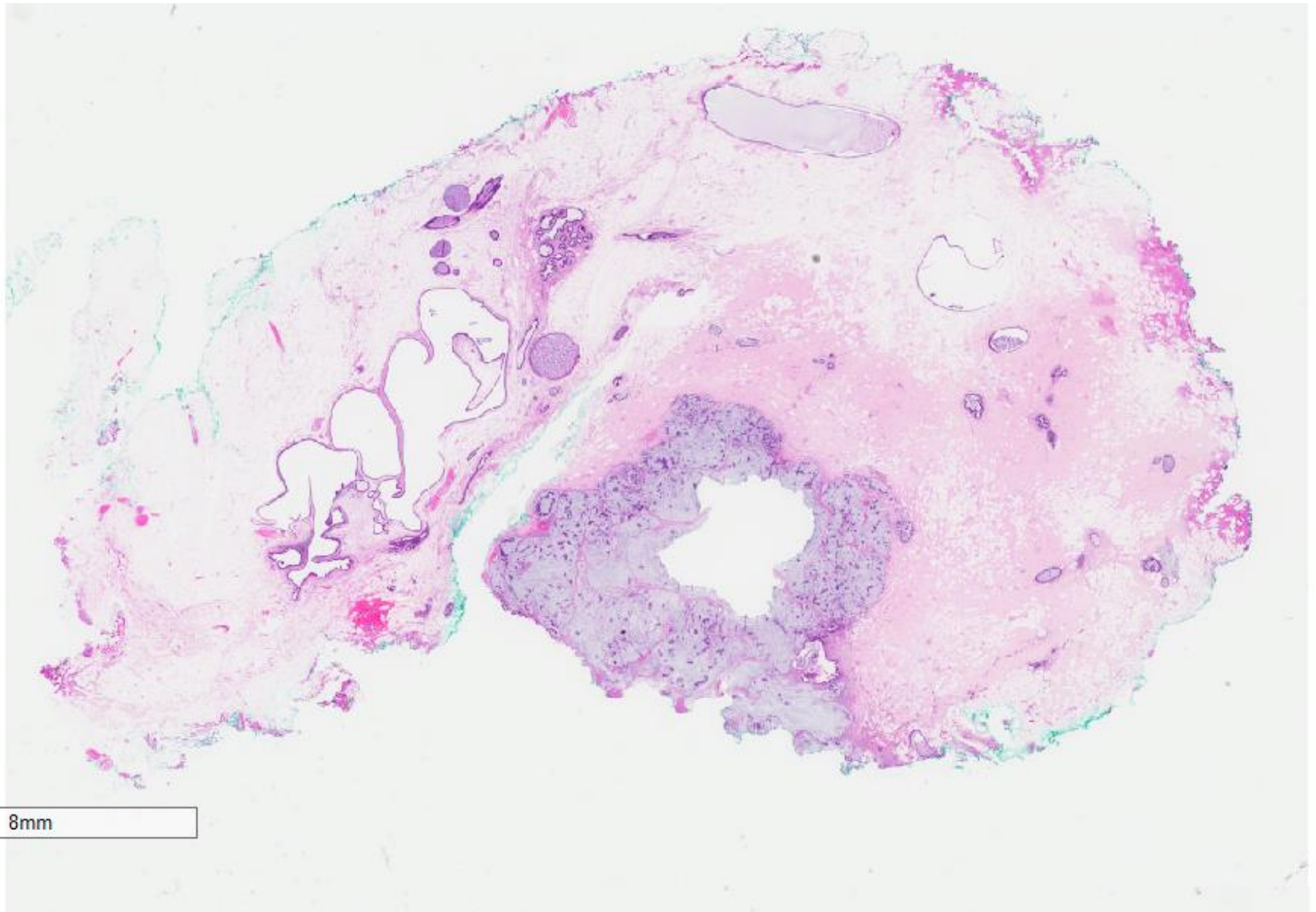


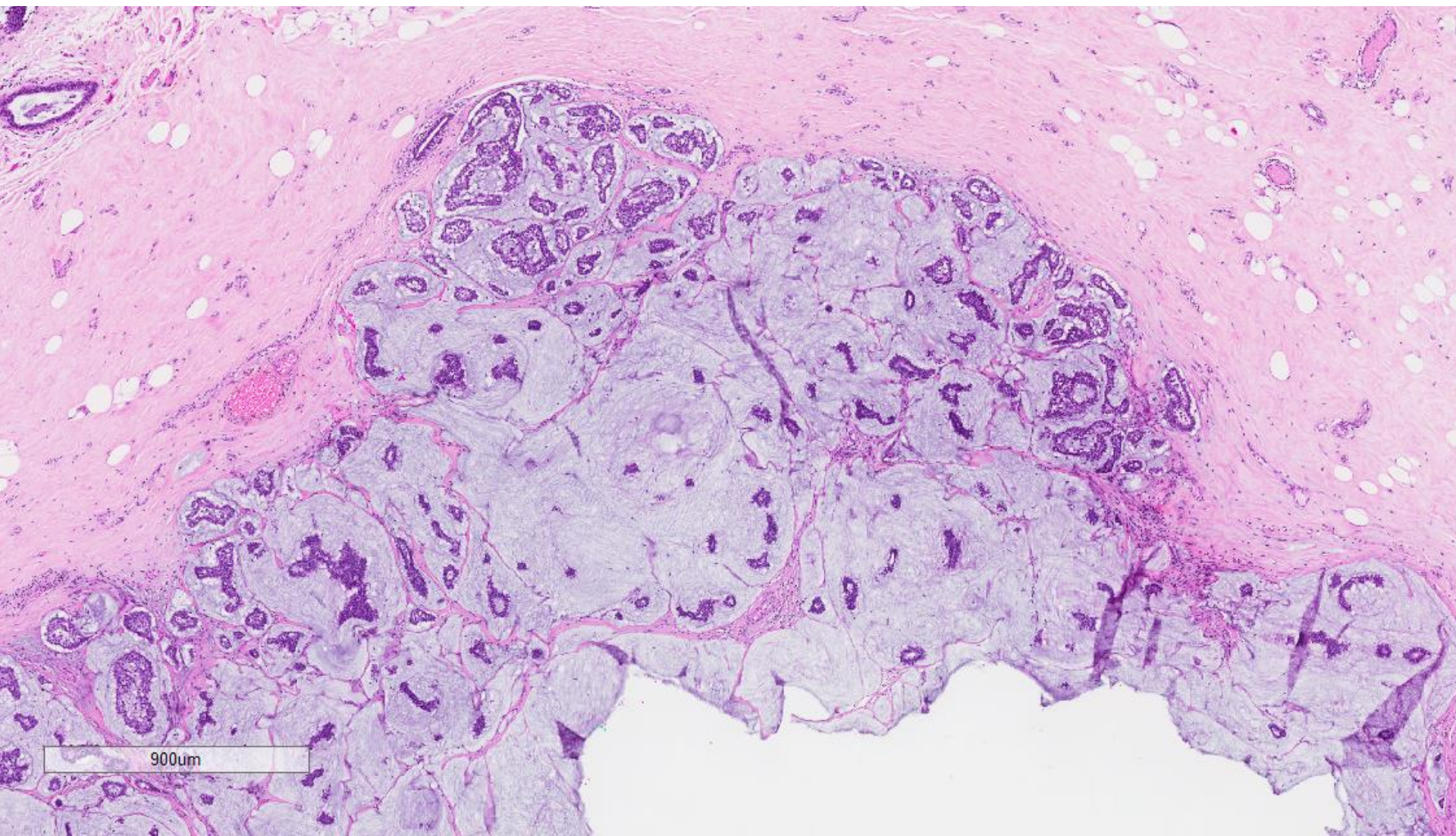
Case 25

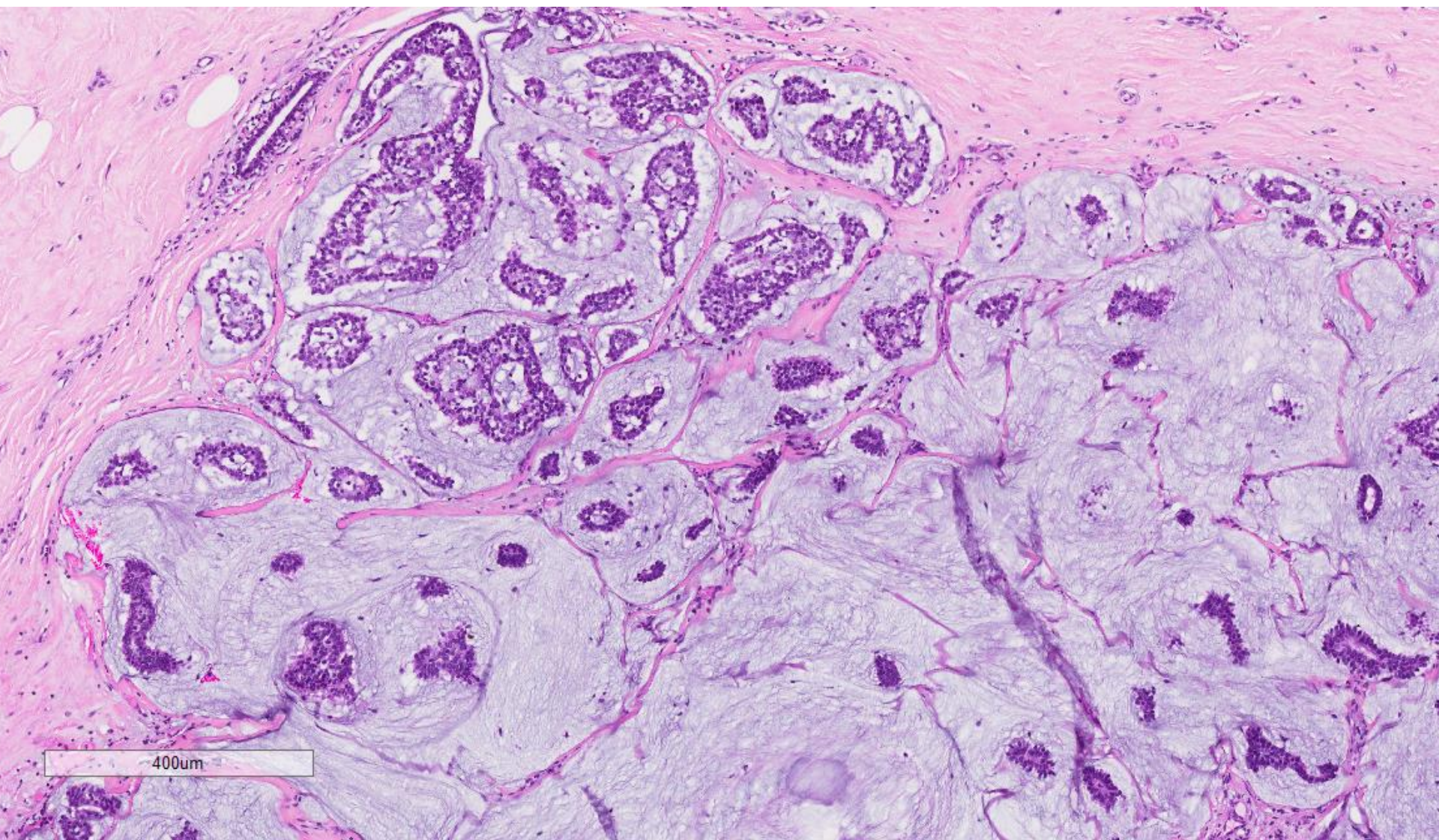
49 year old lady was previously diagnosed (in 2006) with mucocele-like lesion with atypical ductal hyperplasia of the right breast which was excised. She was found to have new calcifications (in 2013) in the vicinity of the previous biopsy on screening mammography.

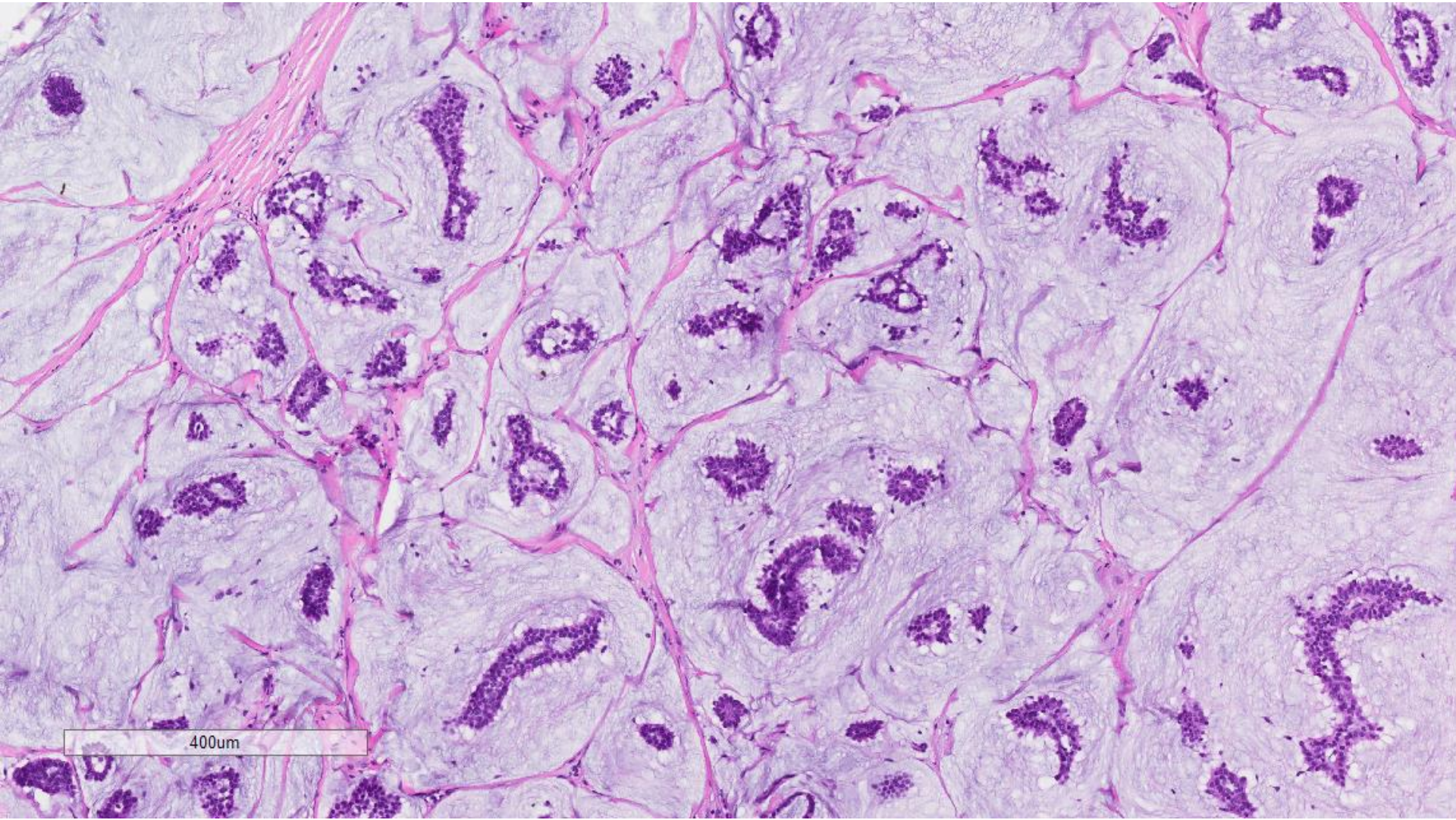
A hookwire localisation excision of the right breast calcifications followed.



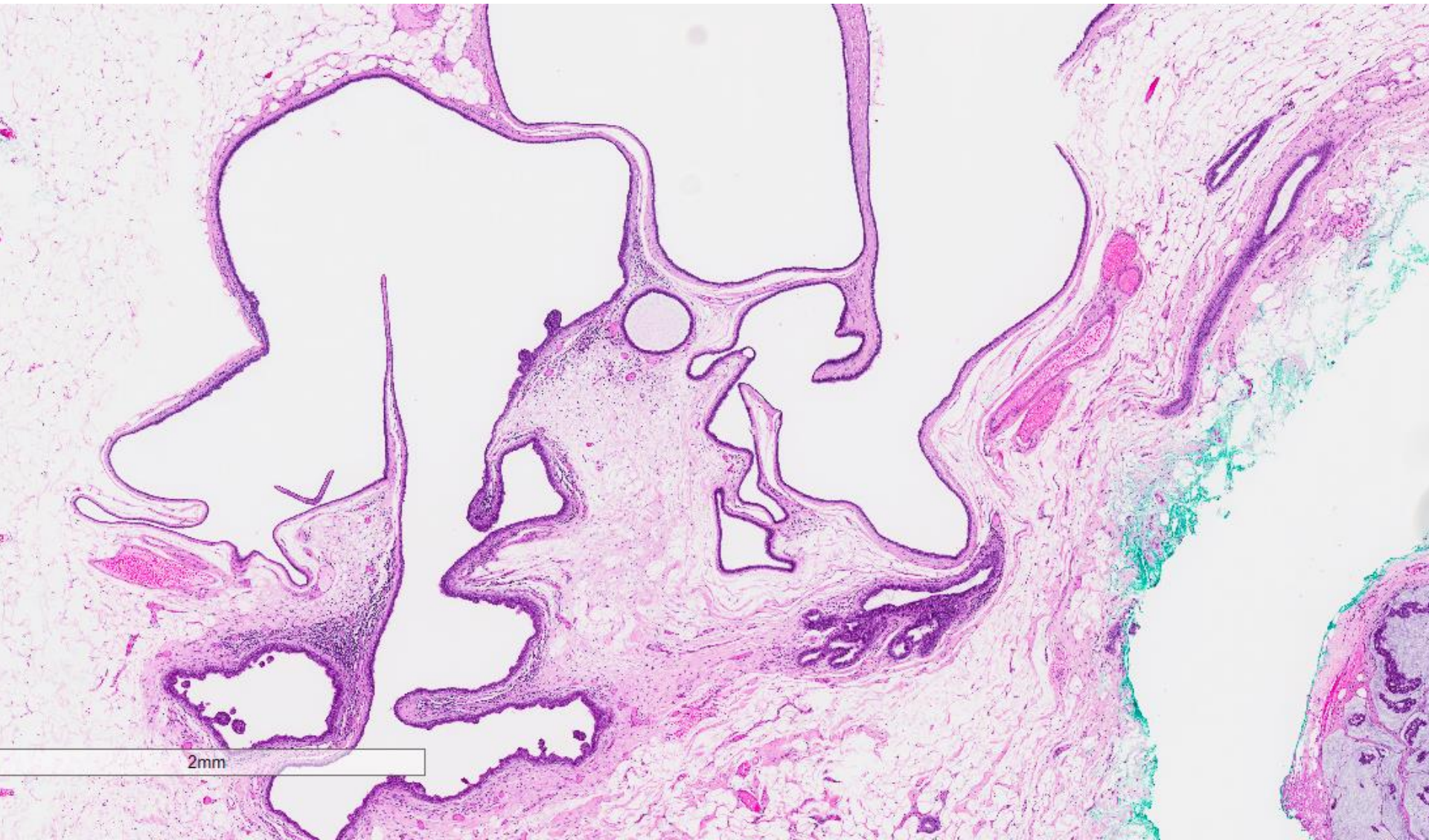
8mm

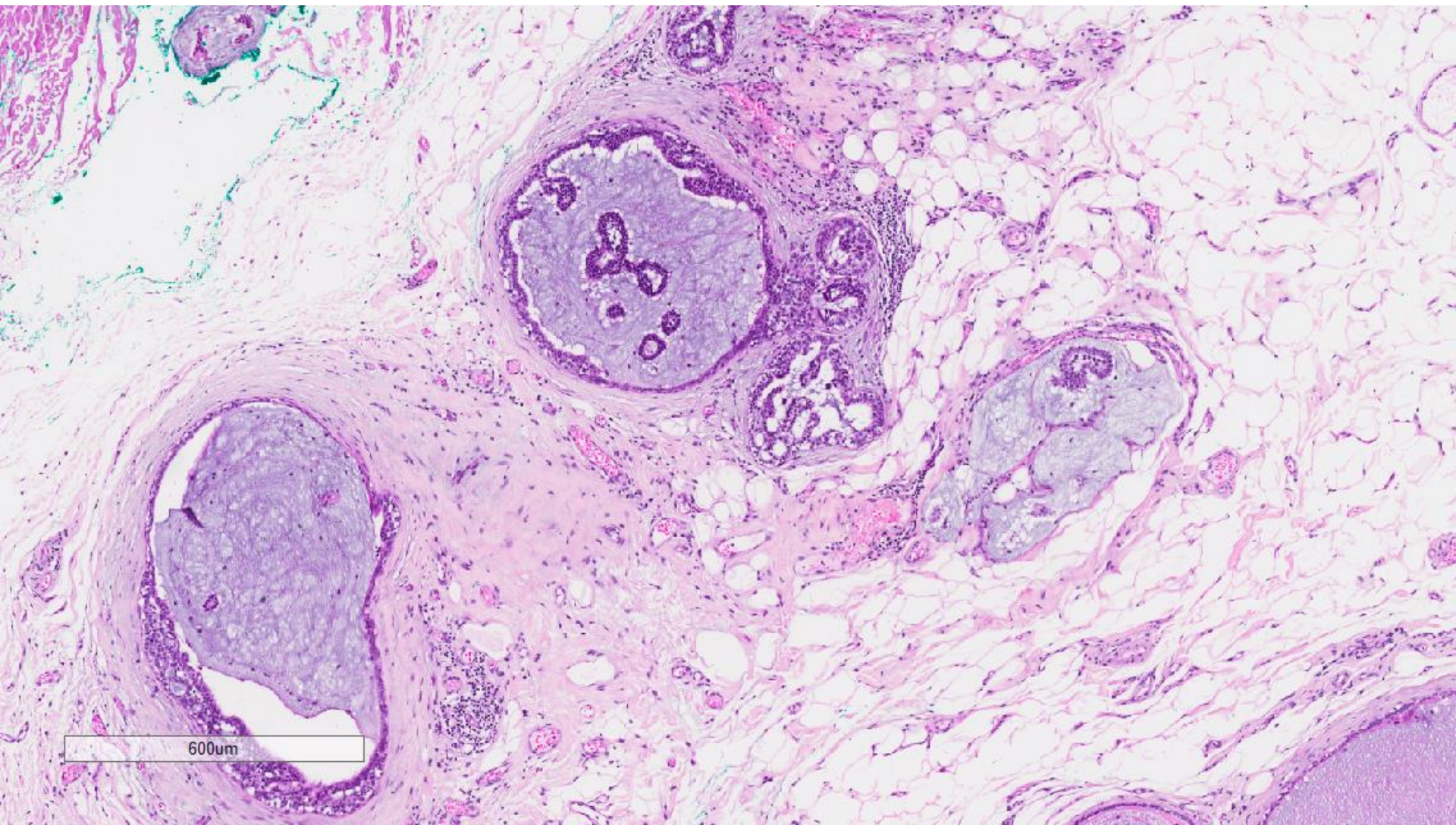




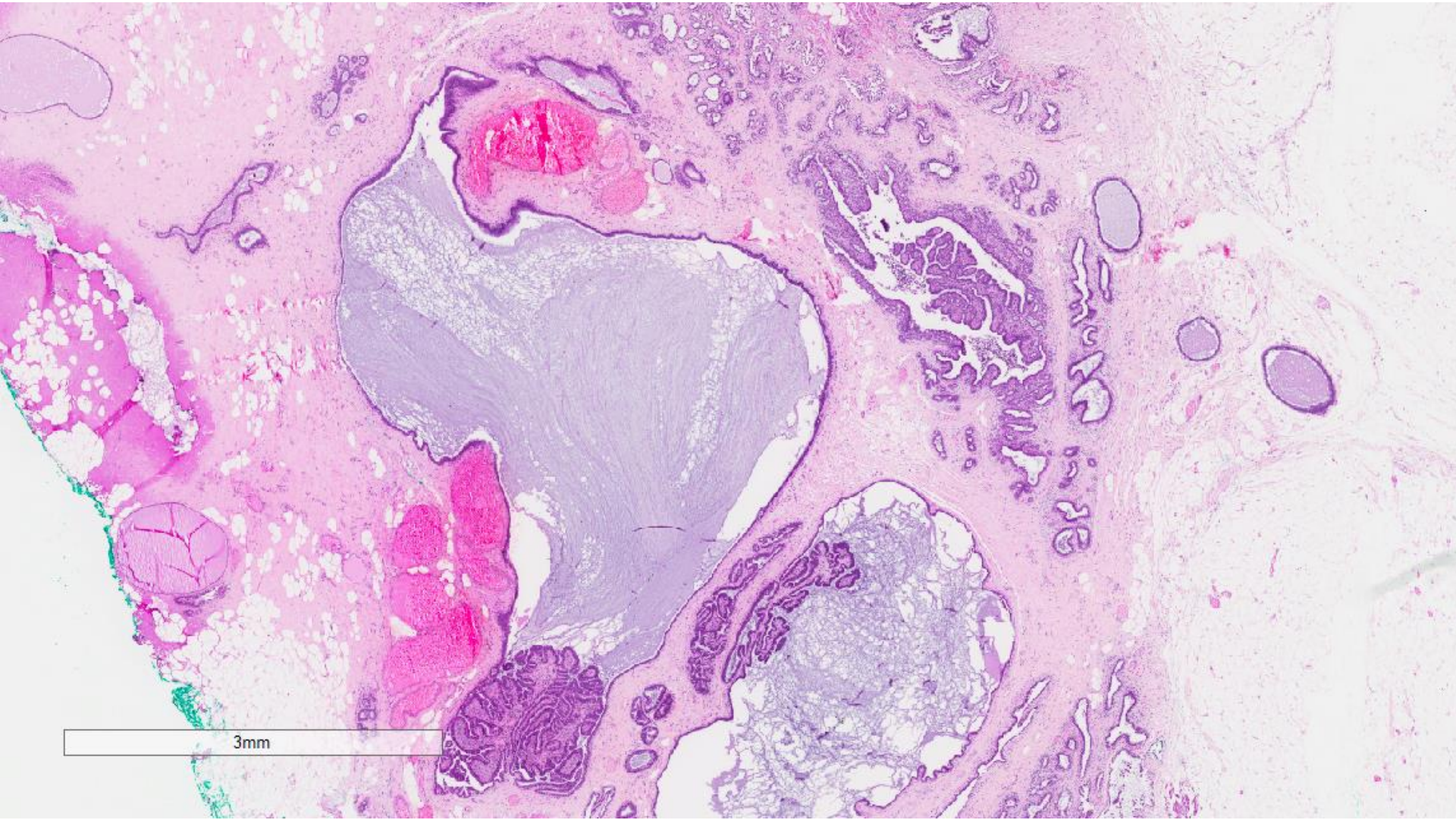


400um

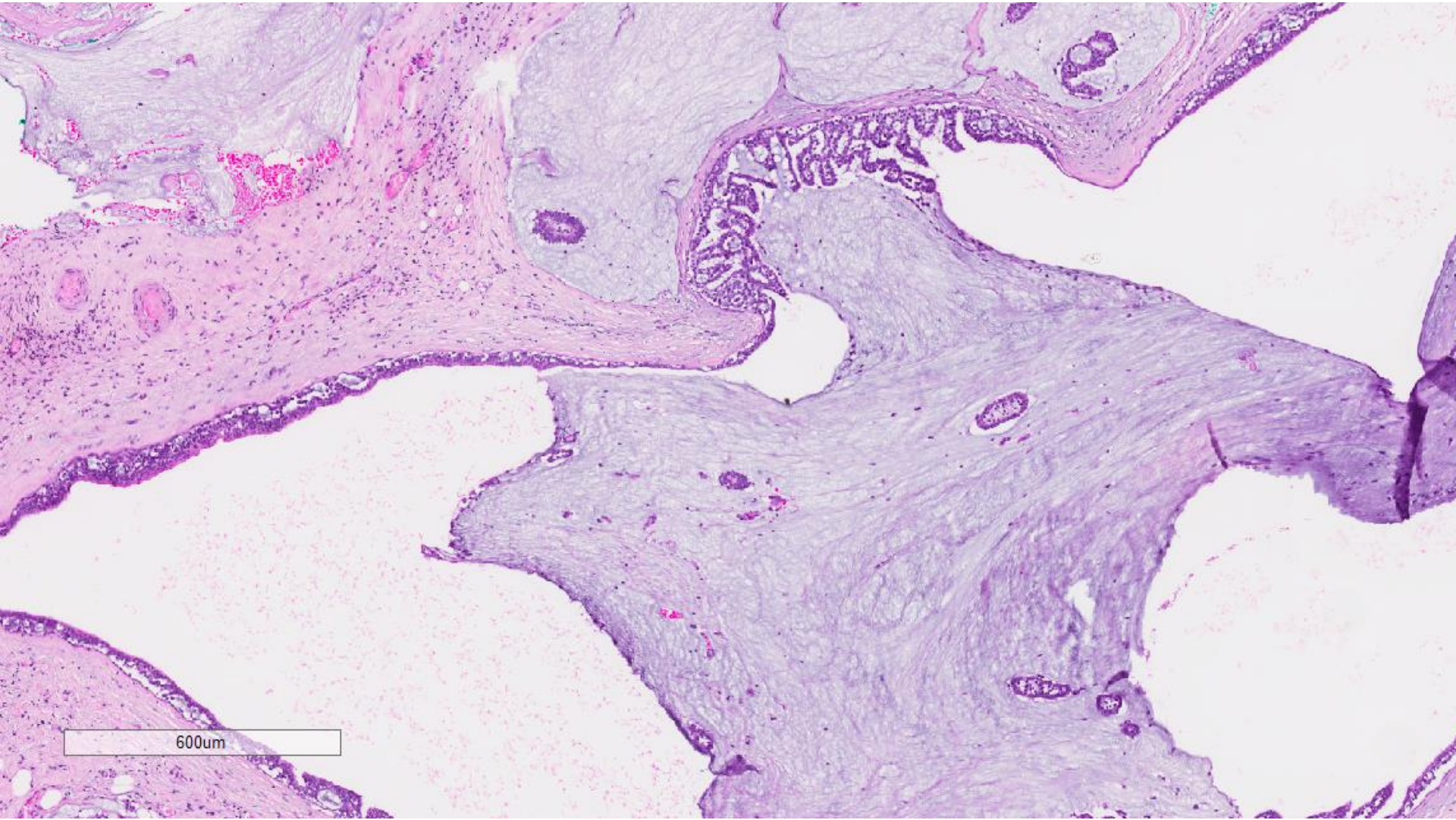




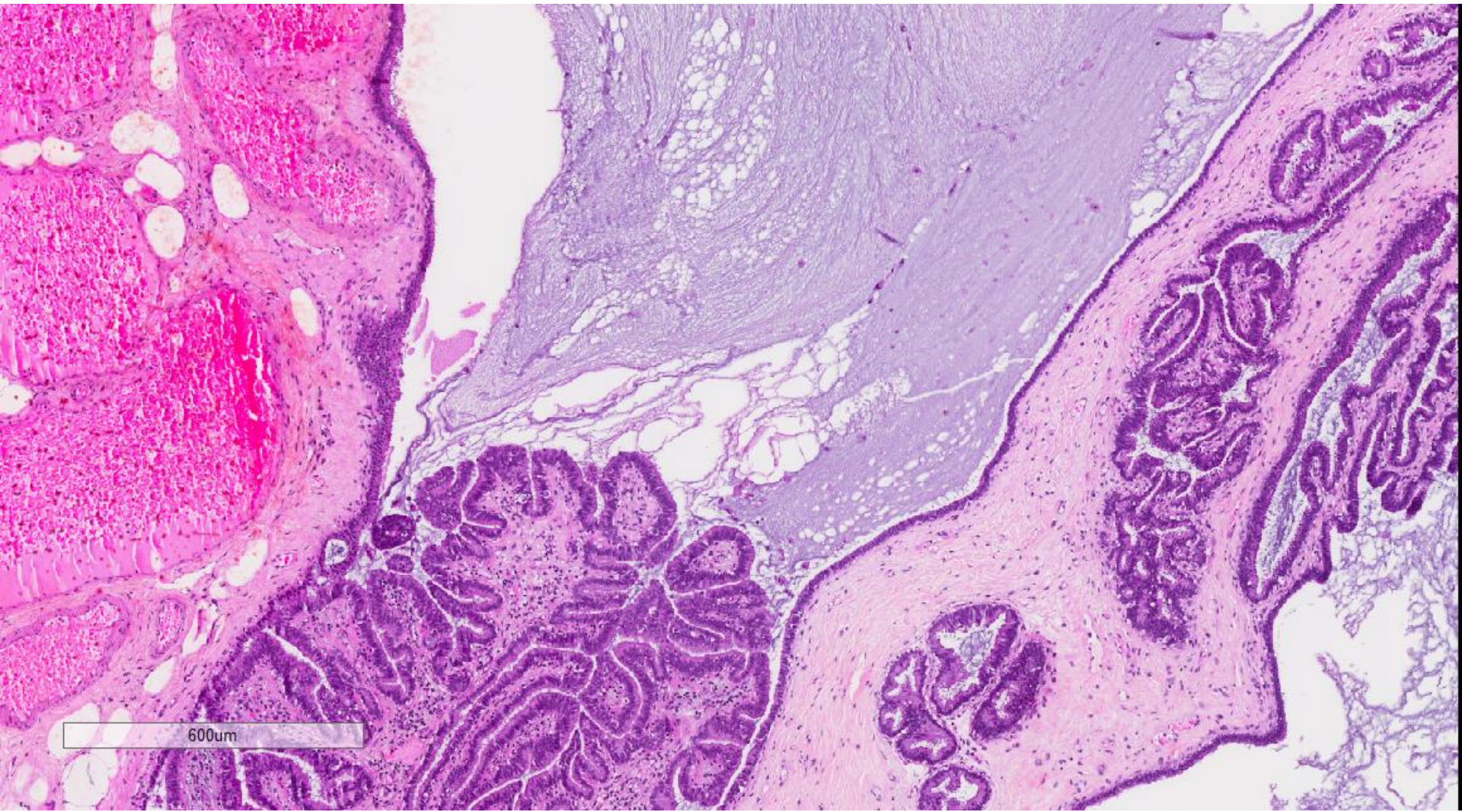
600µm



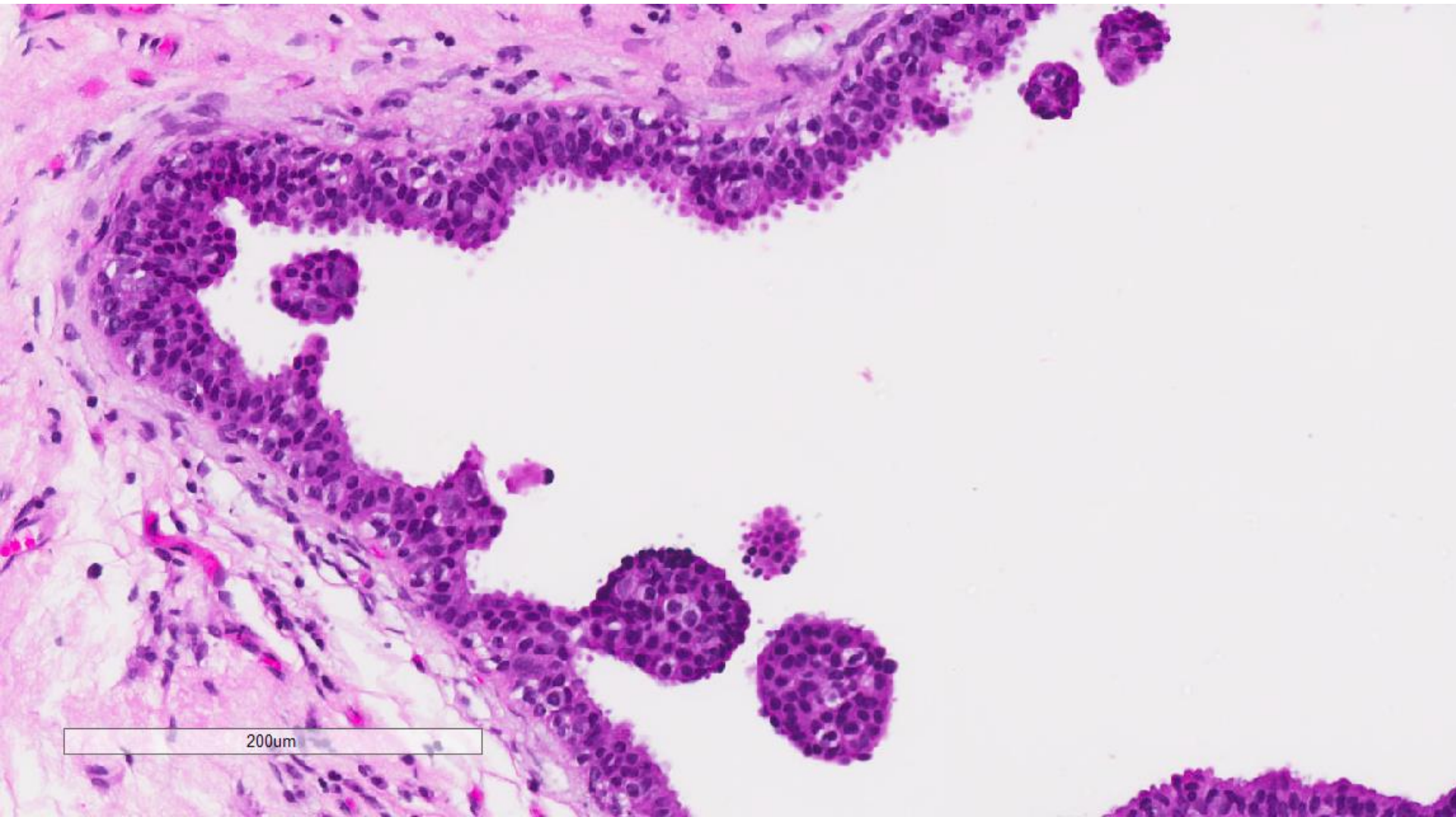
3mm



600um



600um



Mucinous carcinoma, grade 1, 10 mm, ER positive, PR positive, cerbB2 negative; DCIS, low nuclear grade, associated with mucocele like lesion