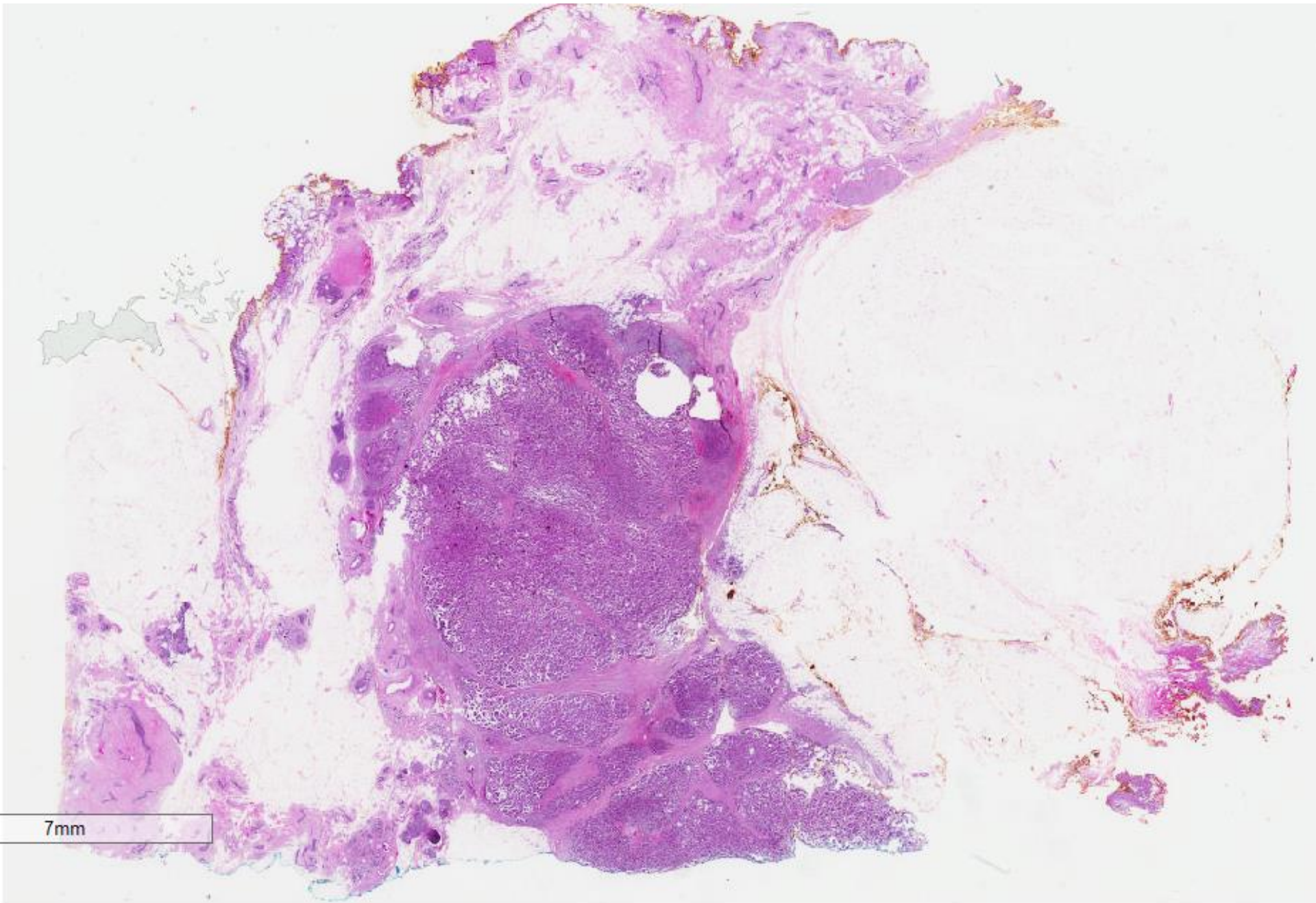
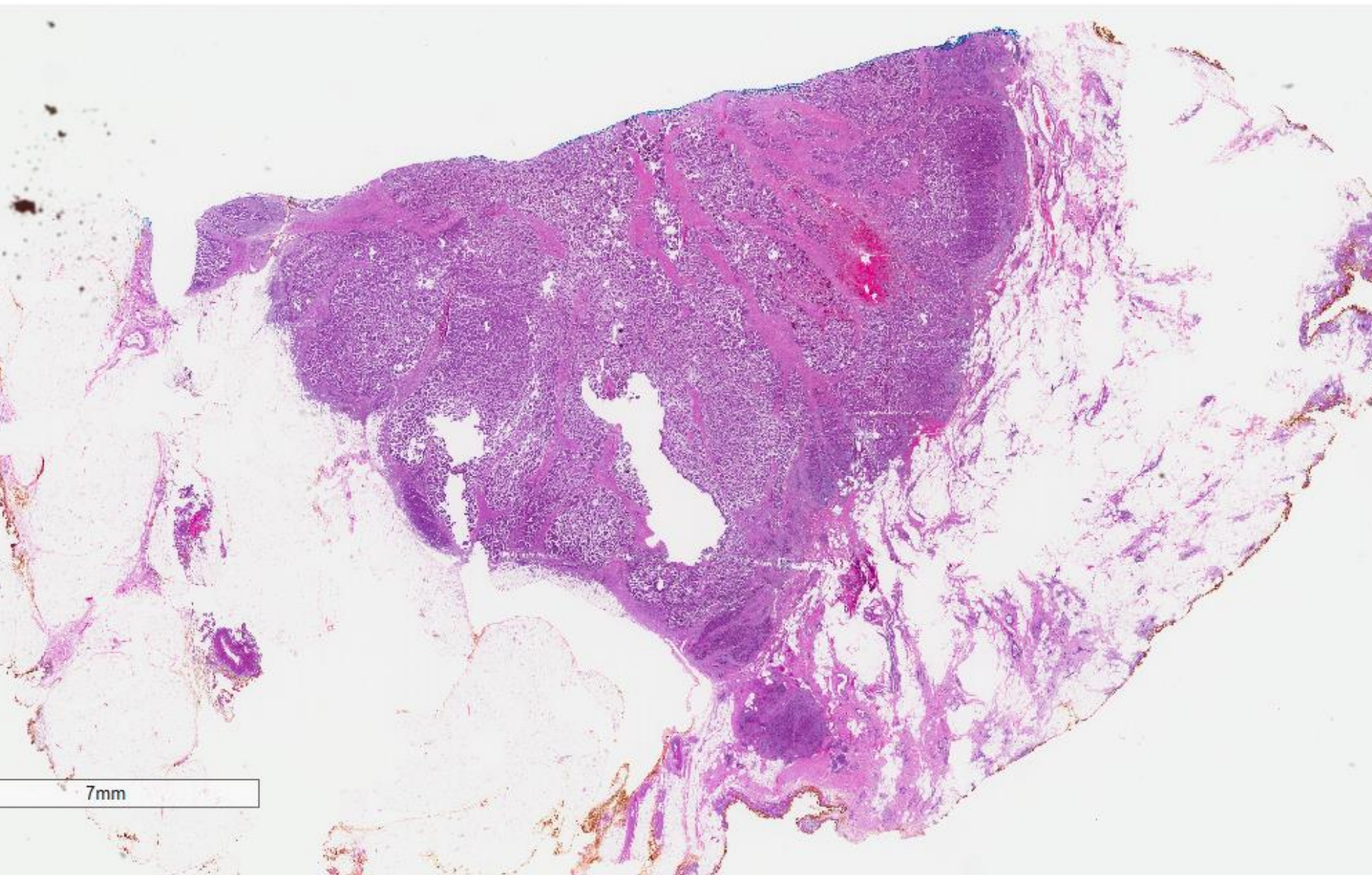


Case 23

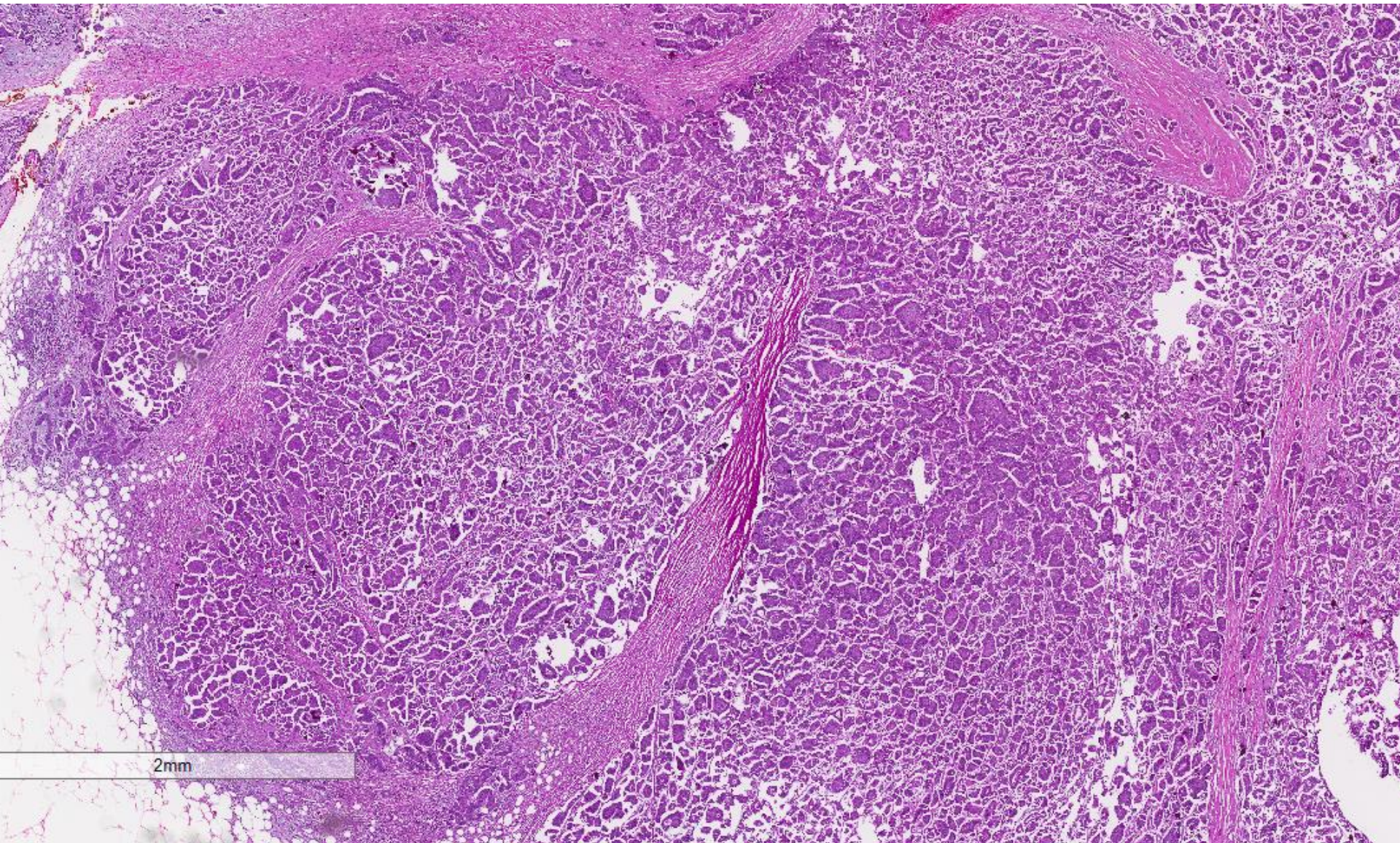
76 year old lady underwent mastectomy
of a right breast mass.



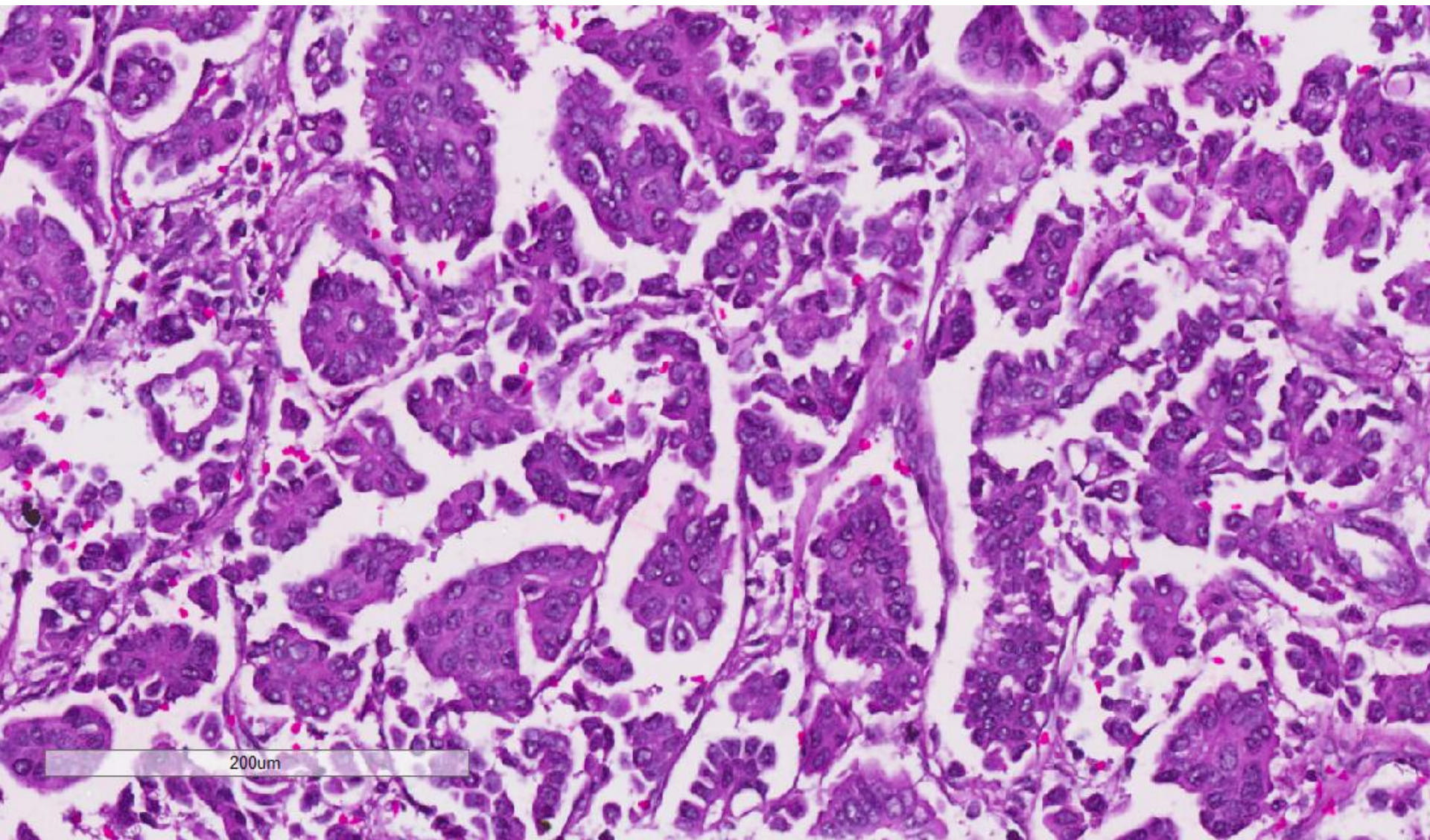
7mm

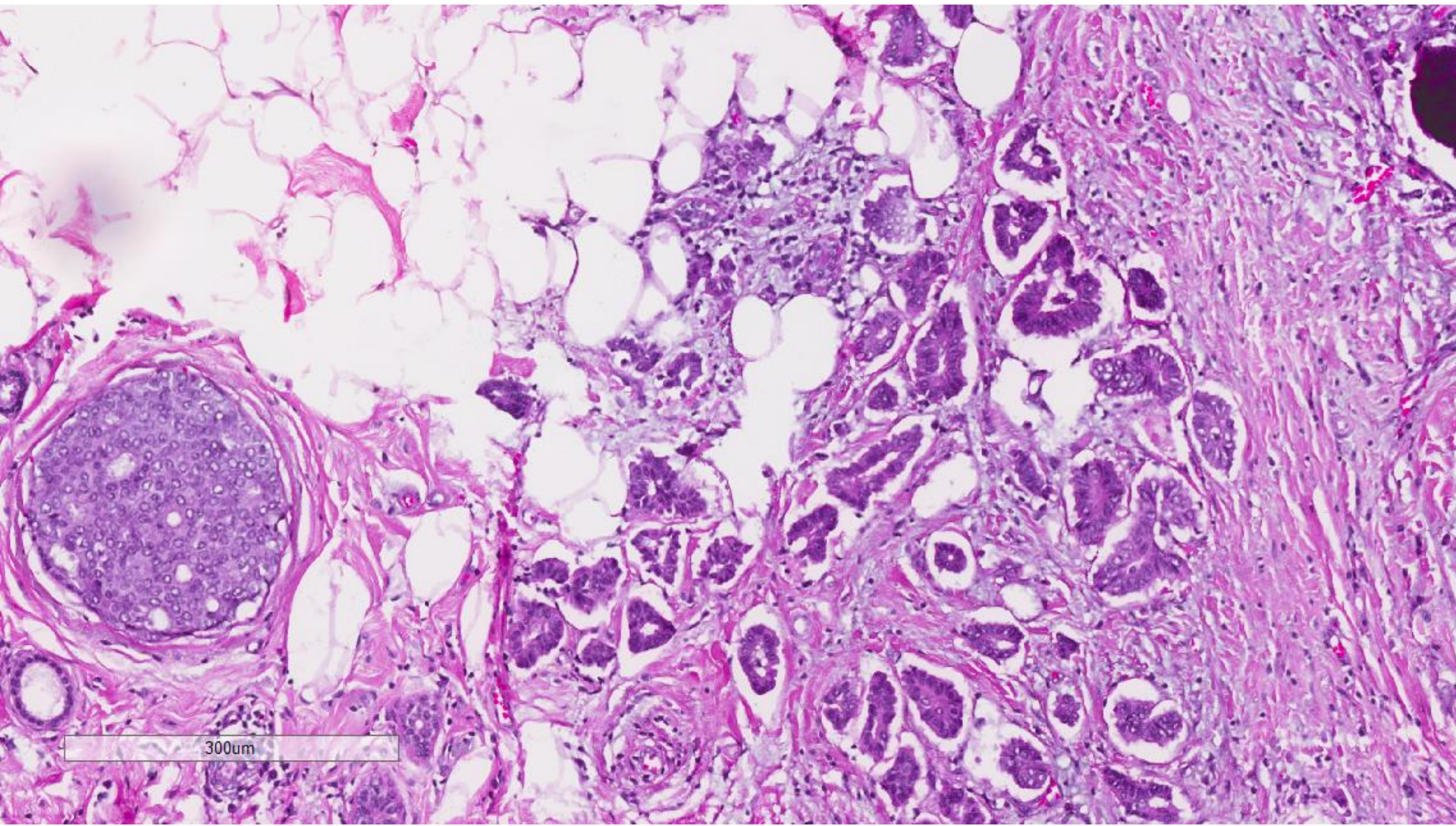


7mm

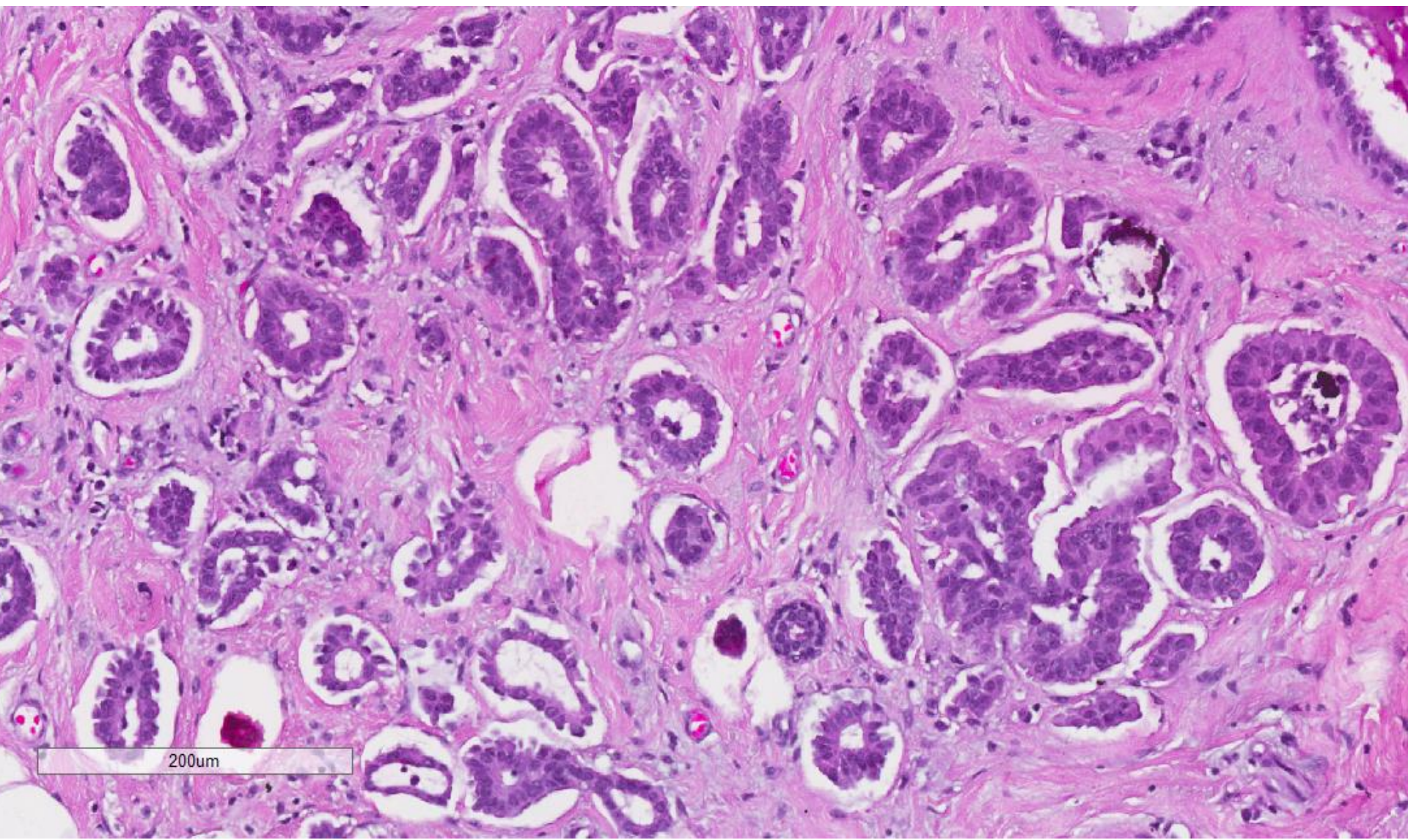


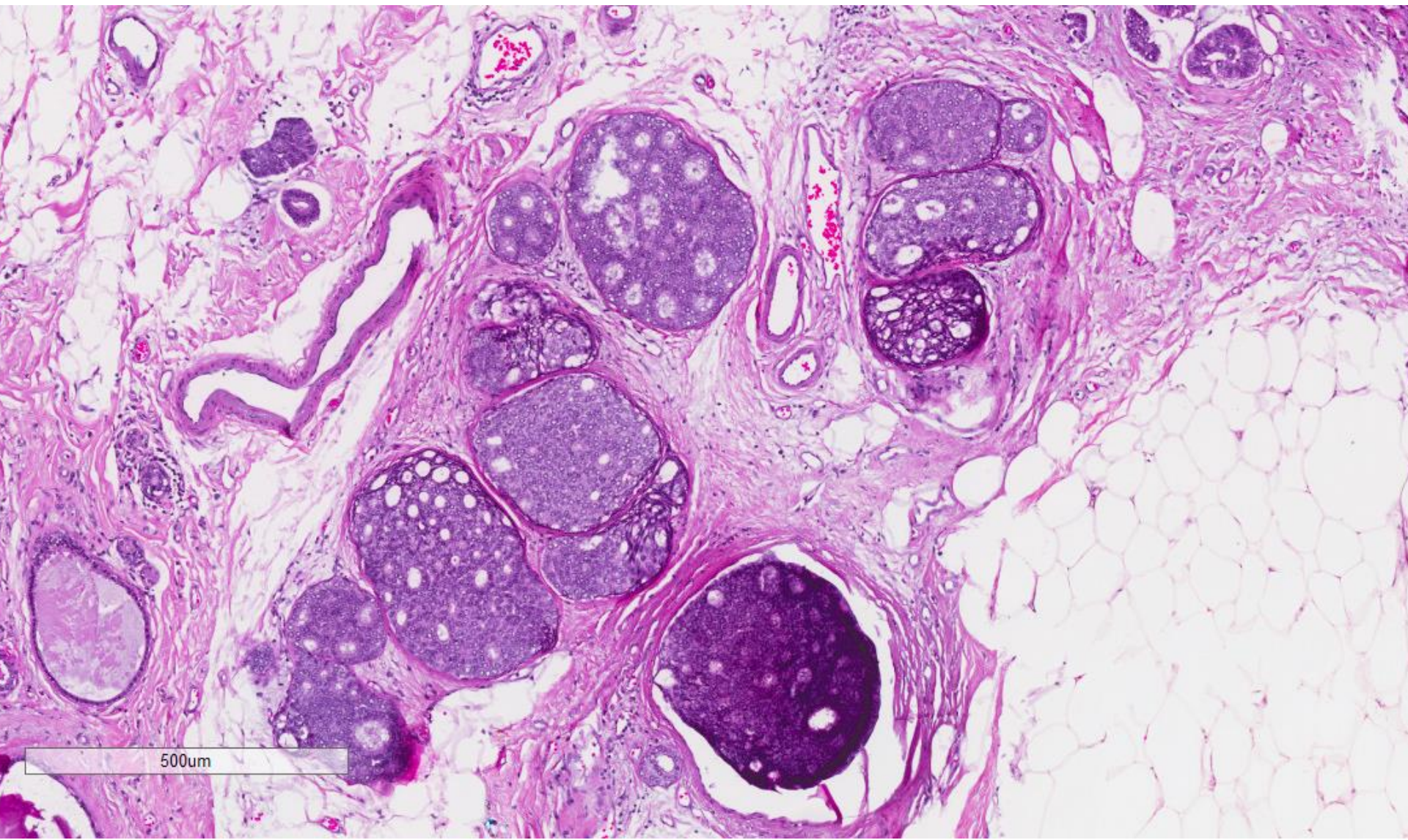
2mm



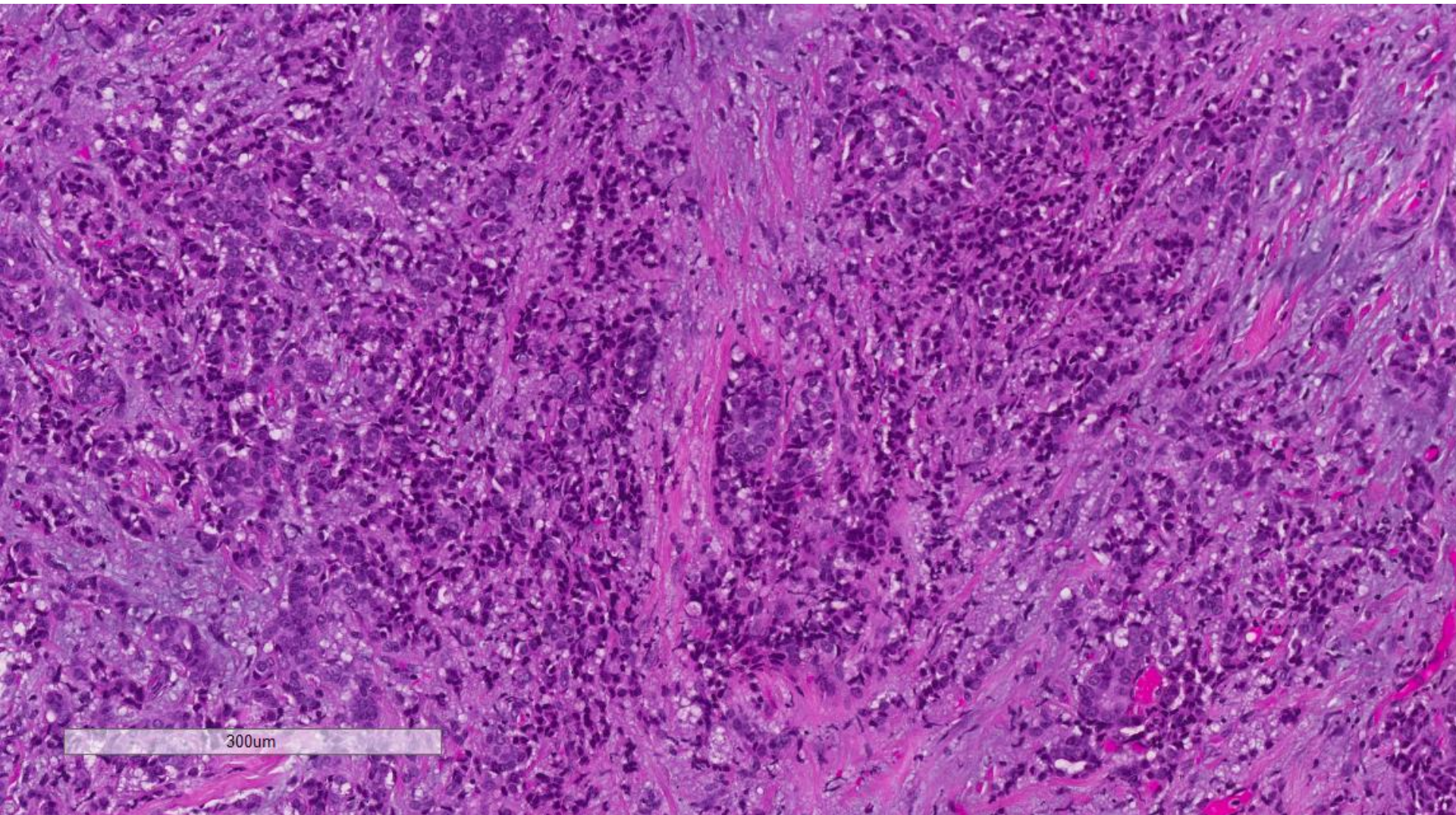


300um

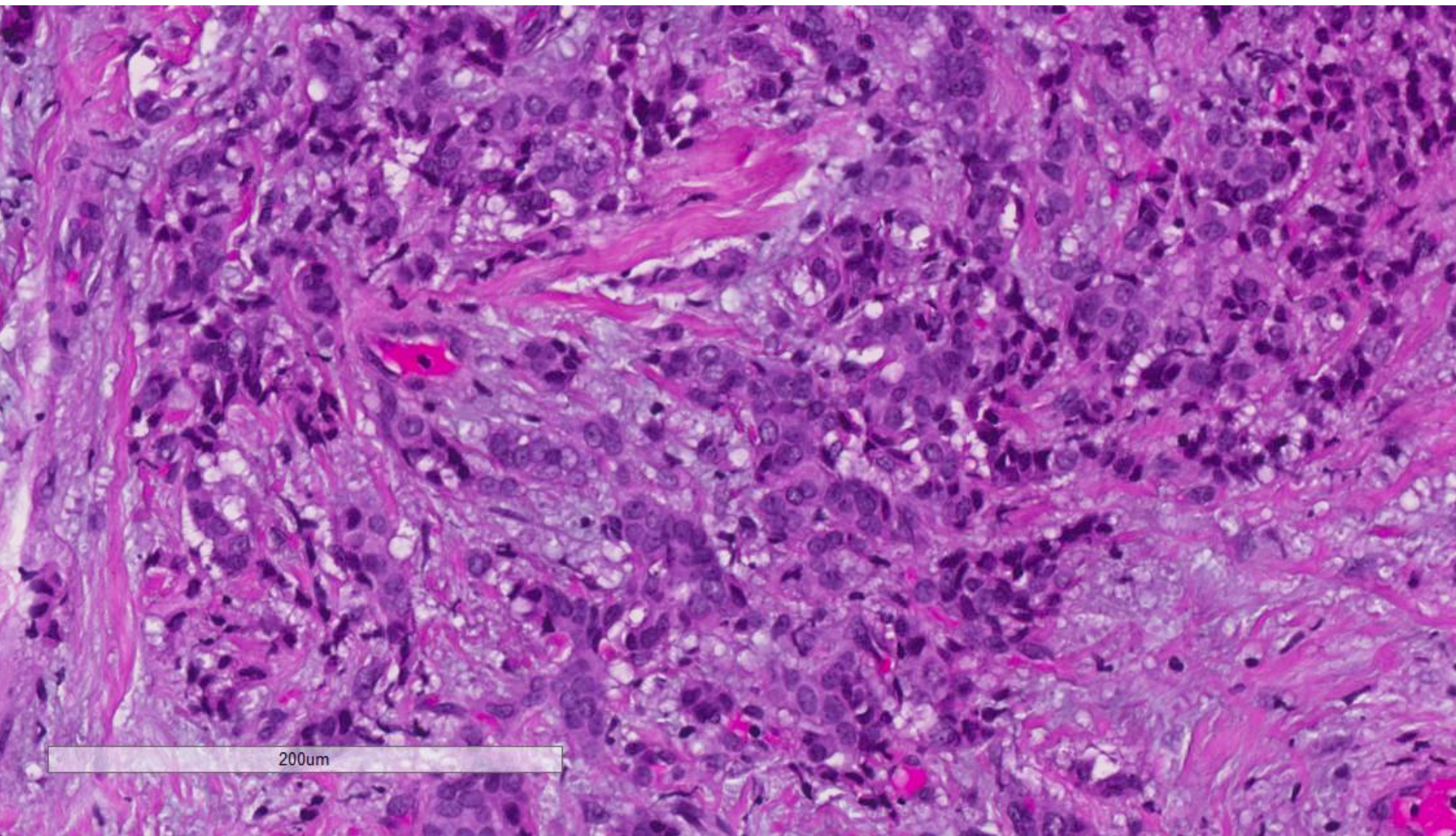


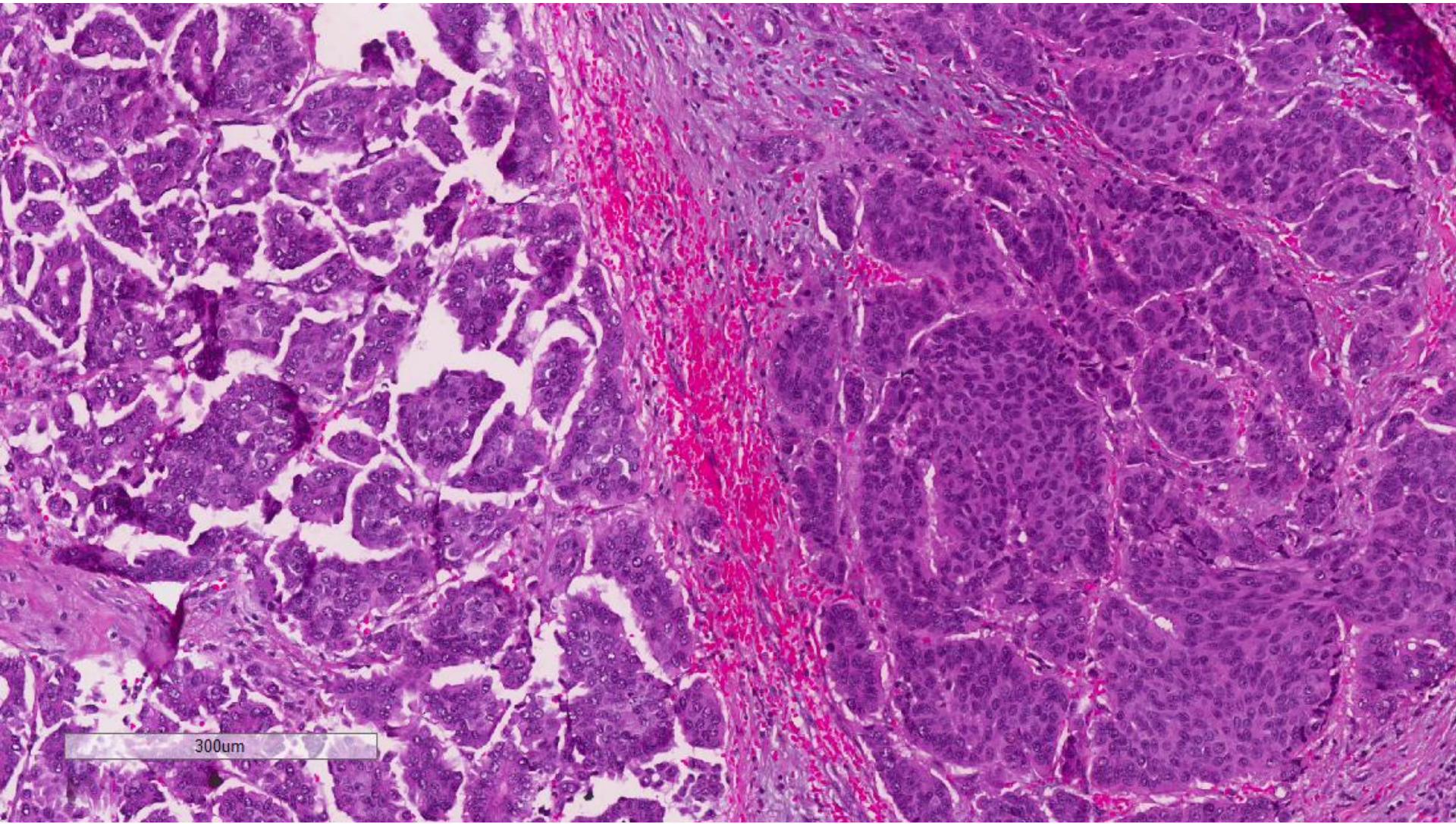


500um



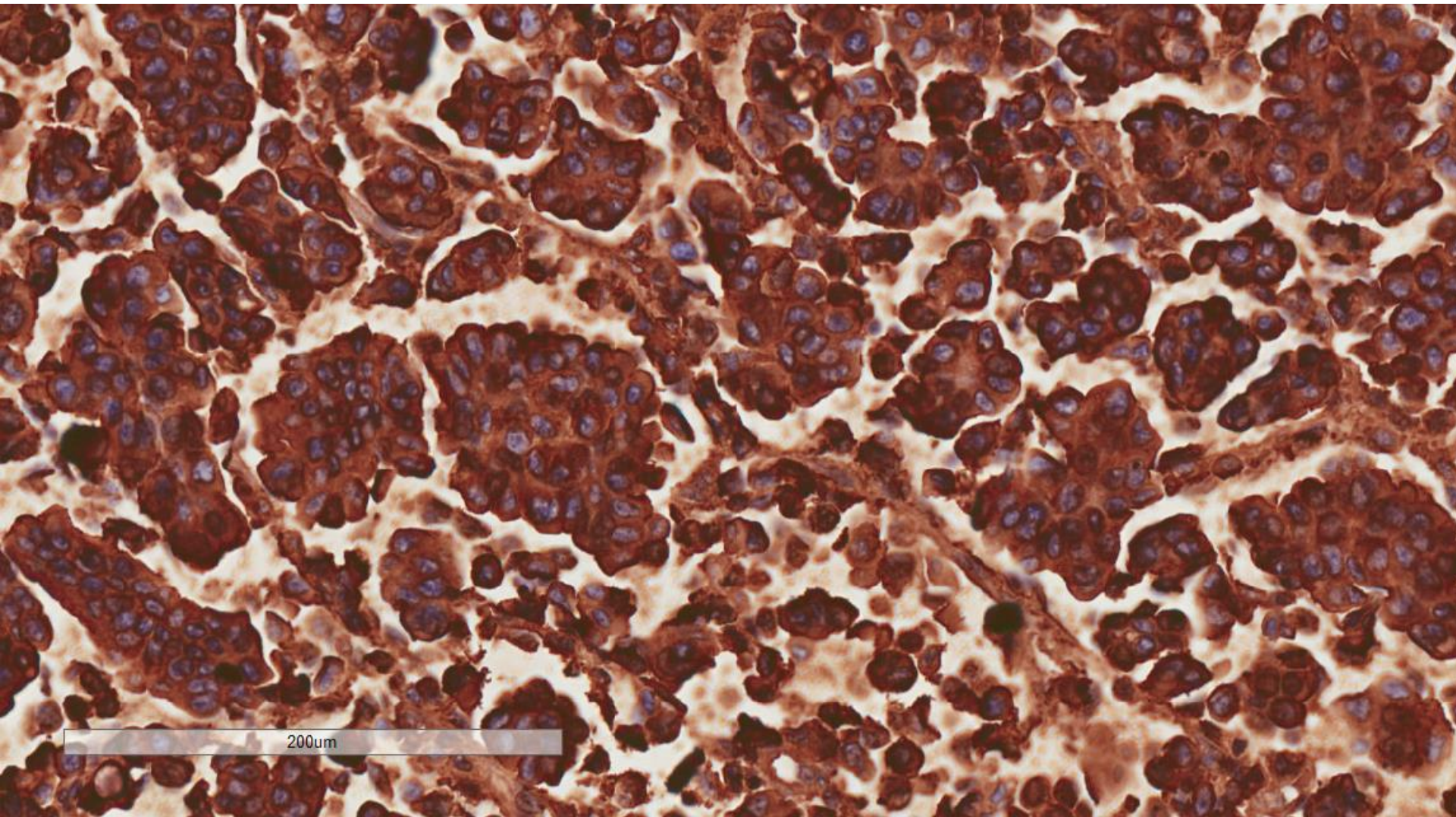
300um



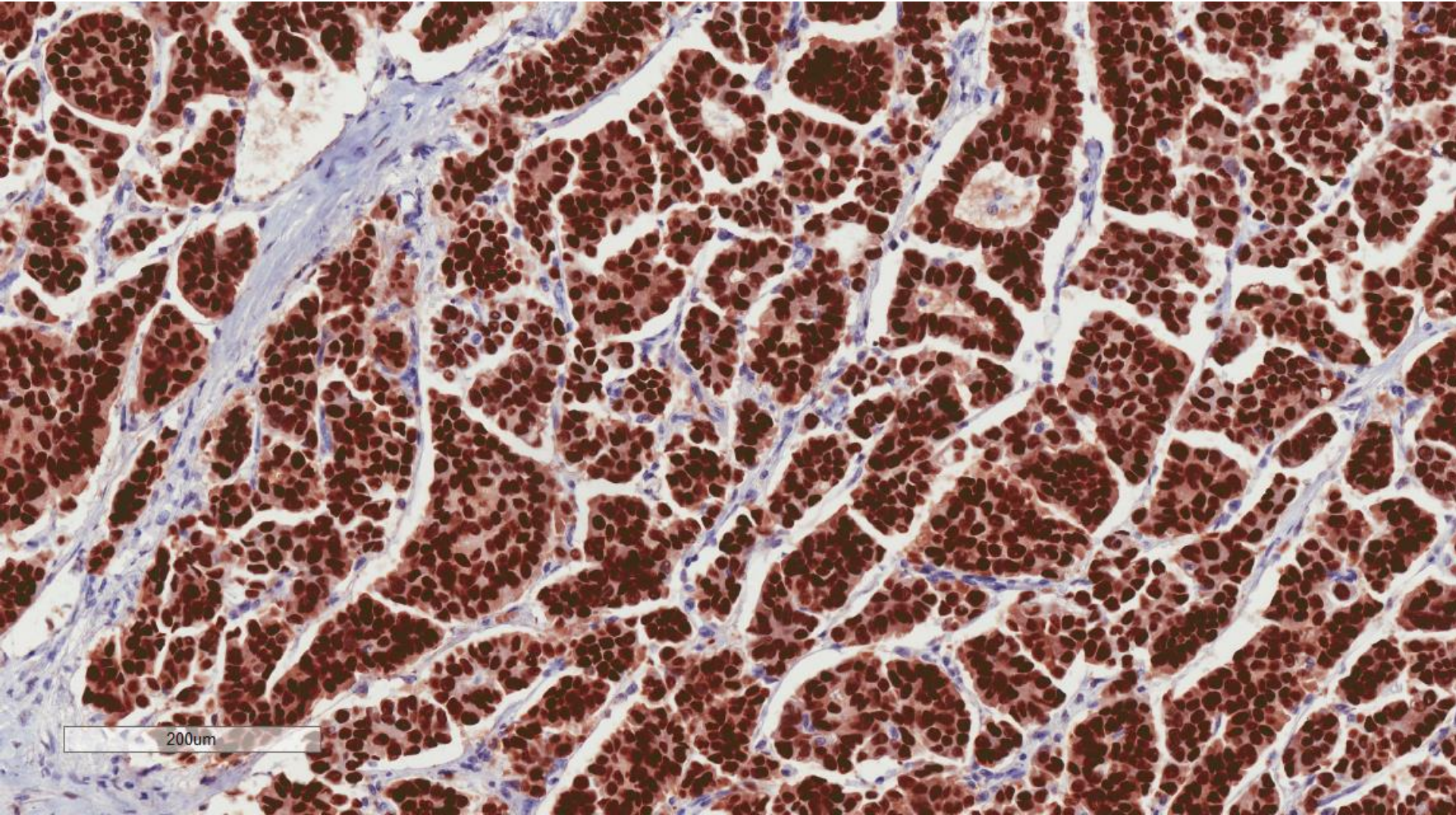


300µm

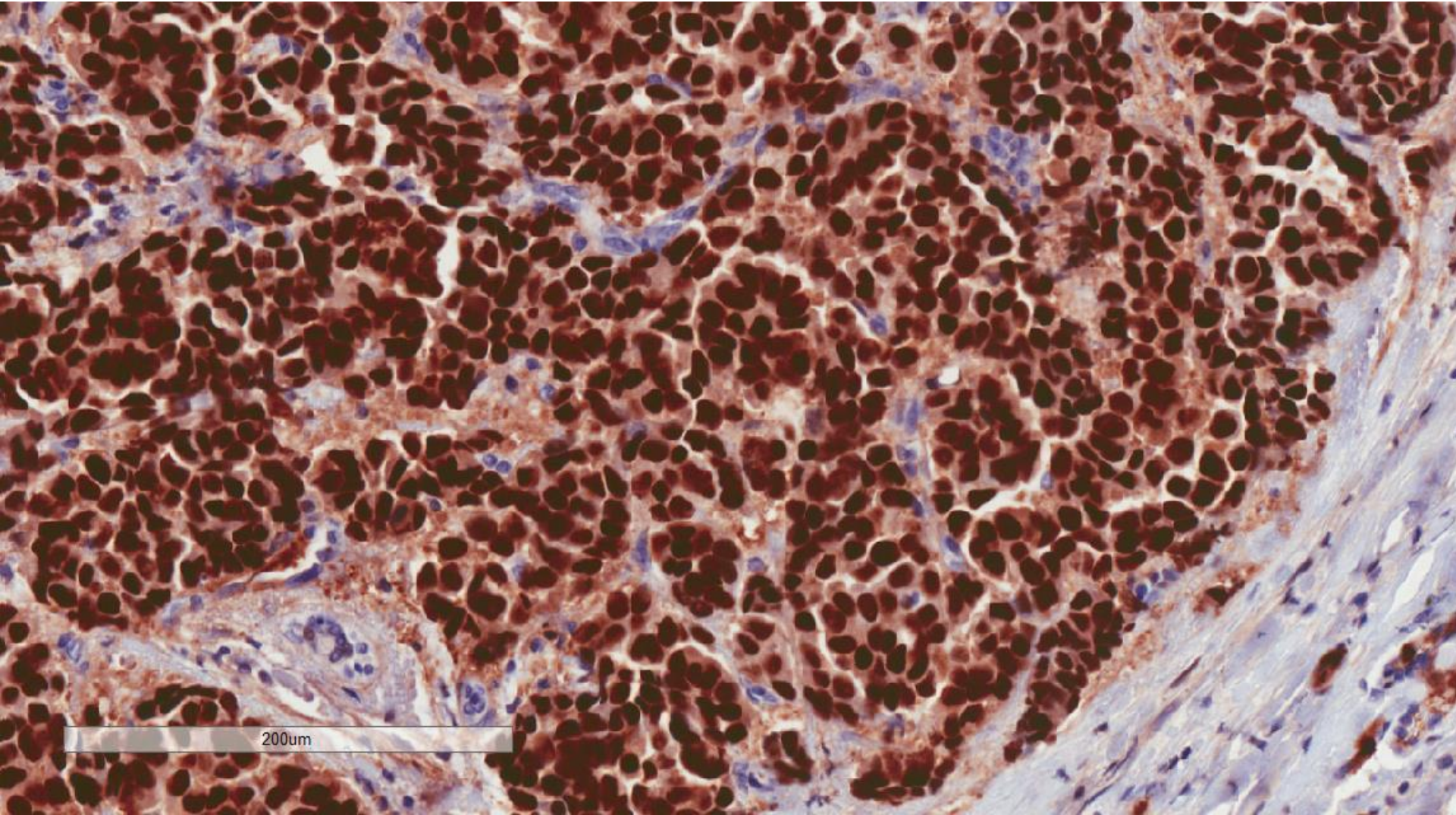
EMA



ER



ER



Invasive carcinoma with micropapillary
features, grade 2, 40mm
ER positive, PR positive, cerbB2 negative
All 4 sentinel lymph nodes show metastatic
carcinoma