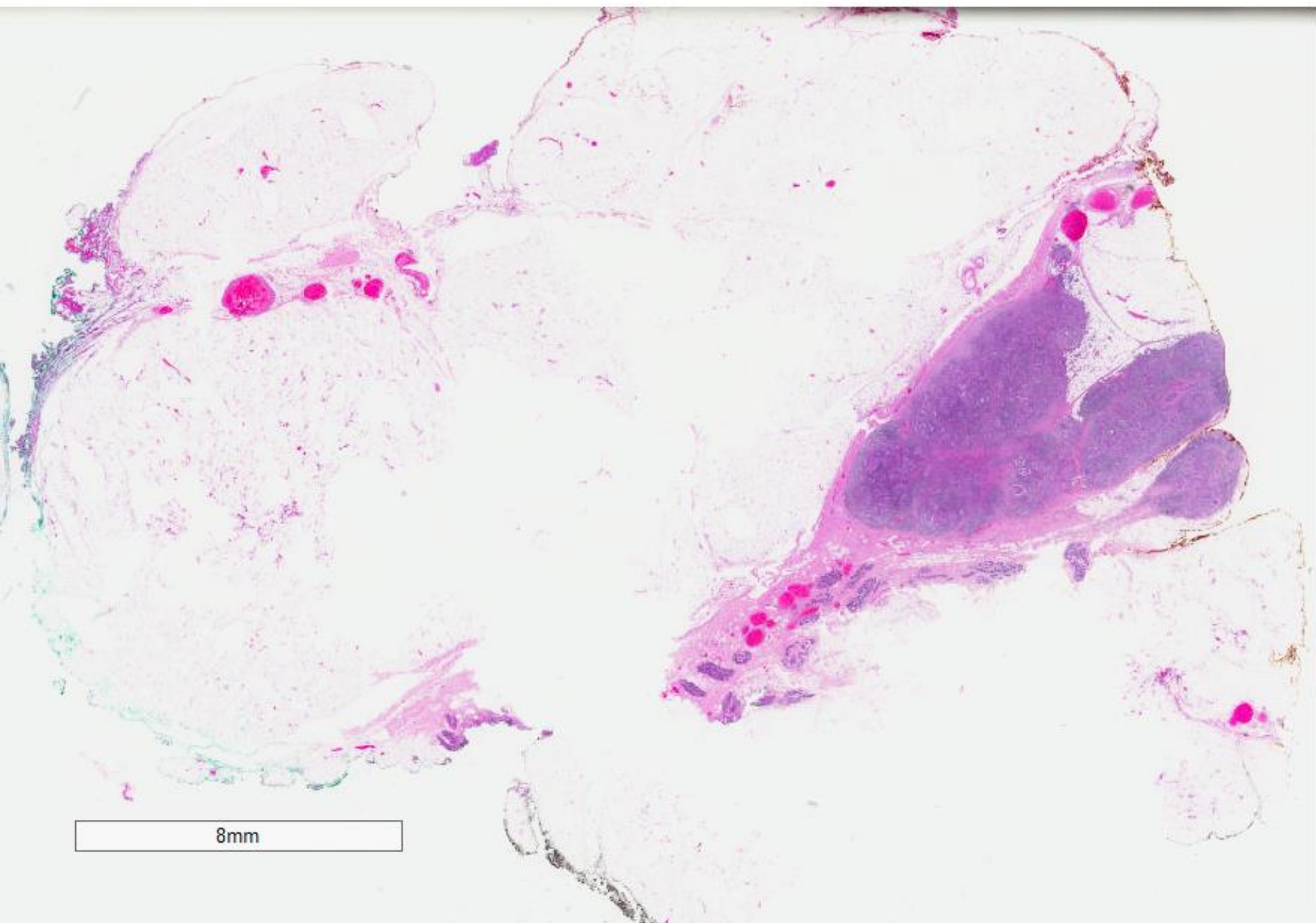
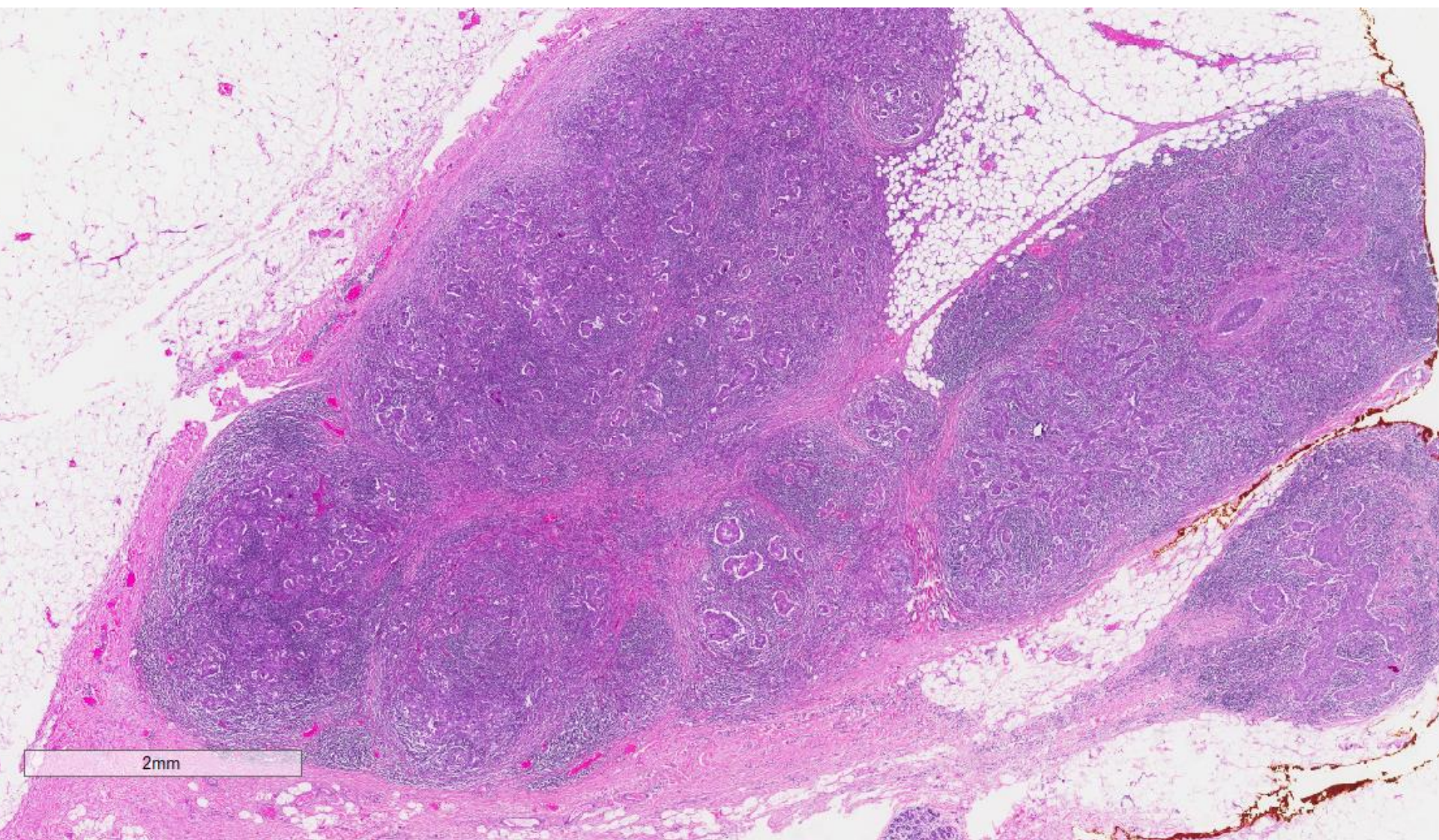
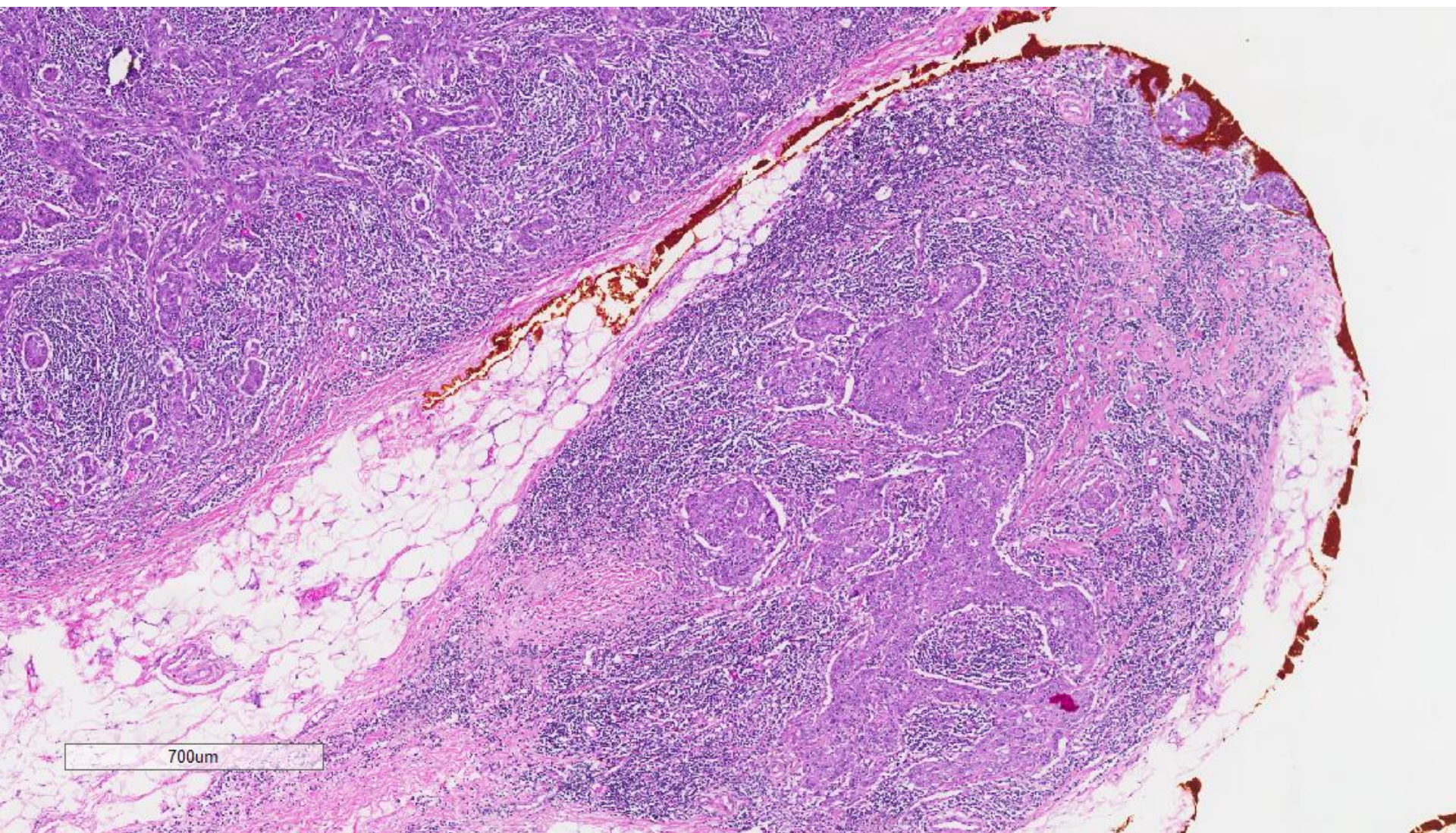


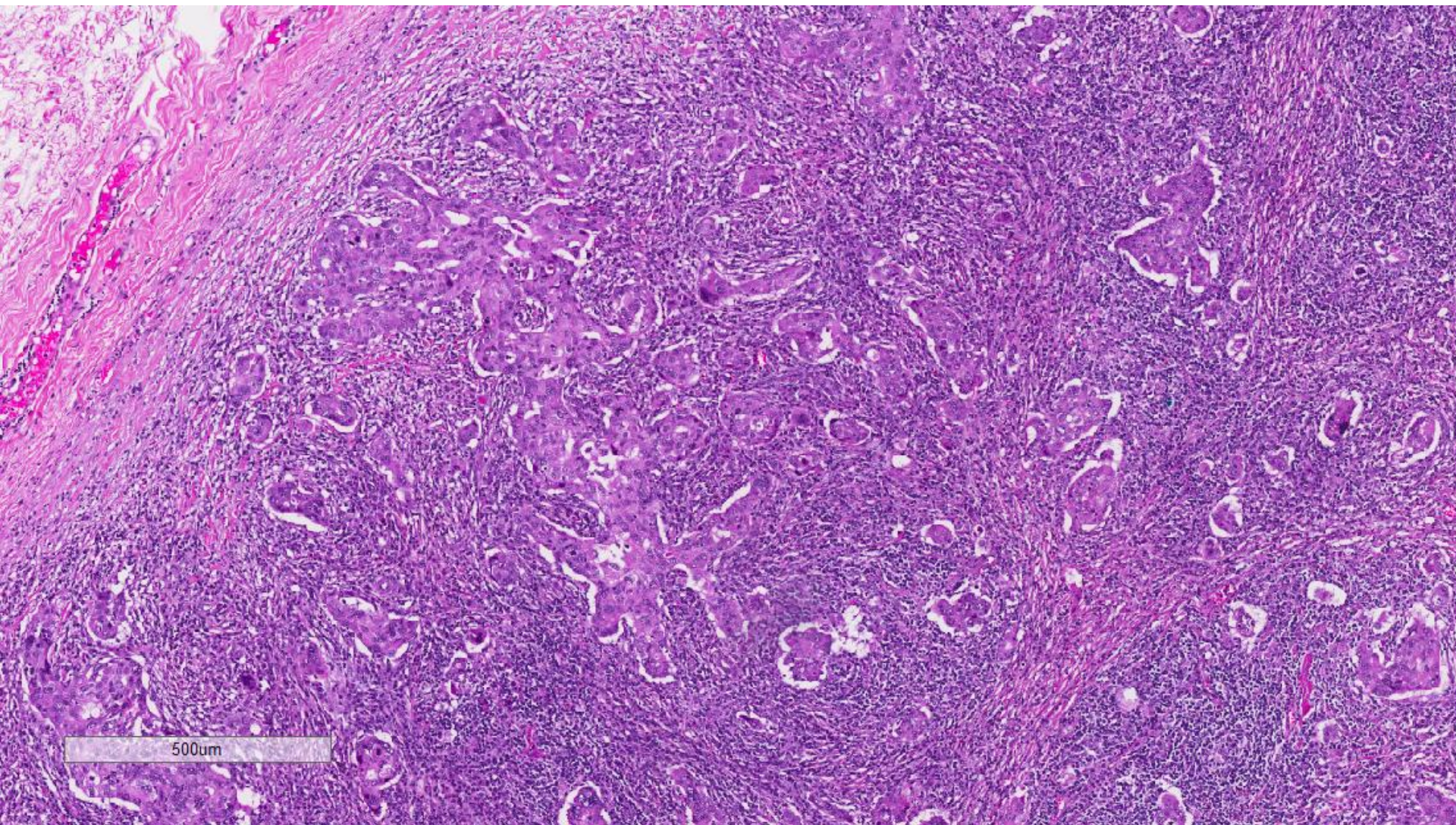
Case 22

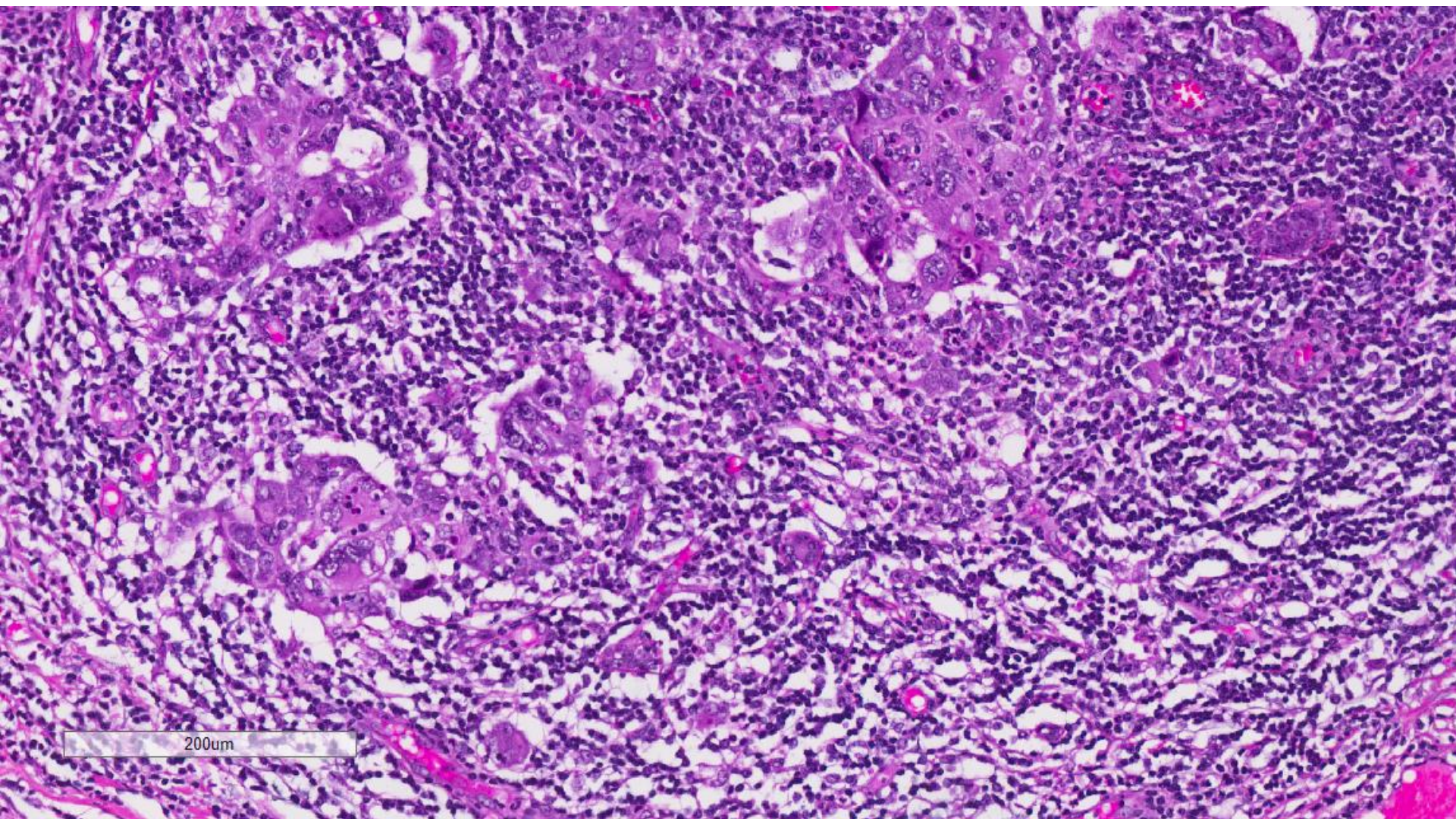
40 year old lady underwent a wide excision of left breast mass, after a core biopsy confirmed carcinoma.

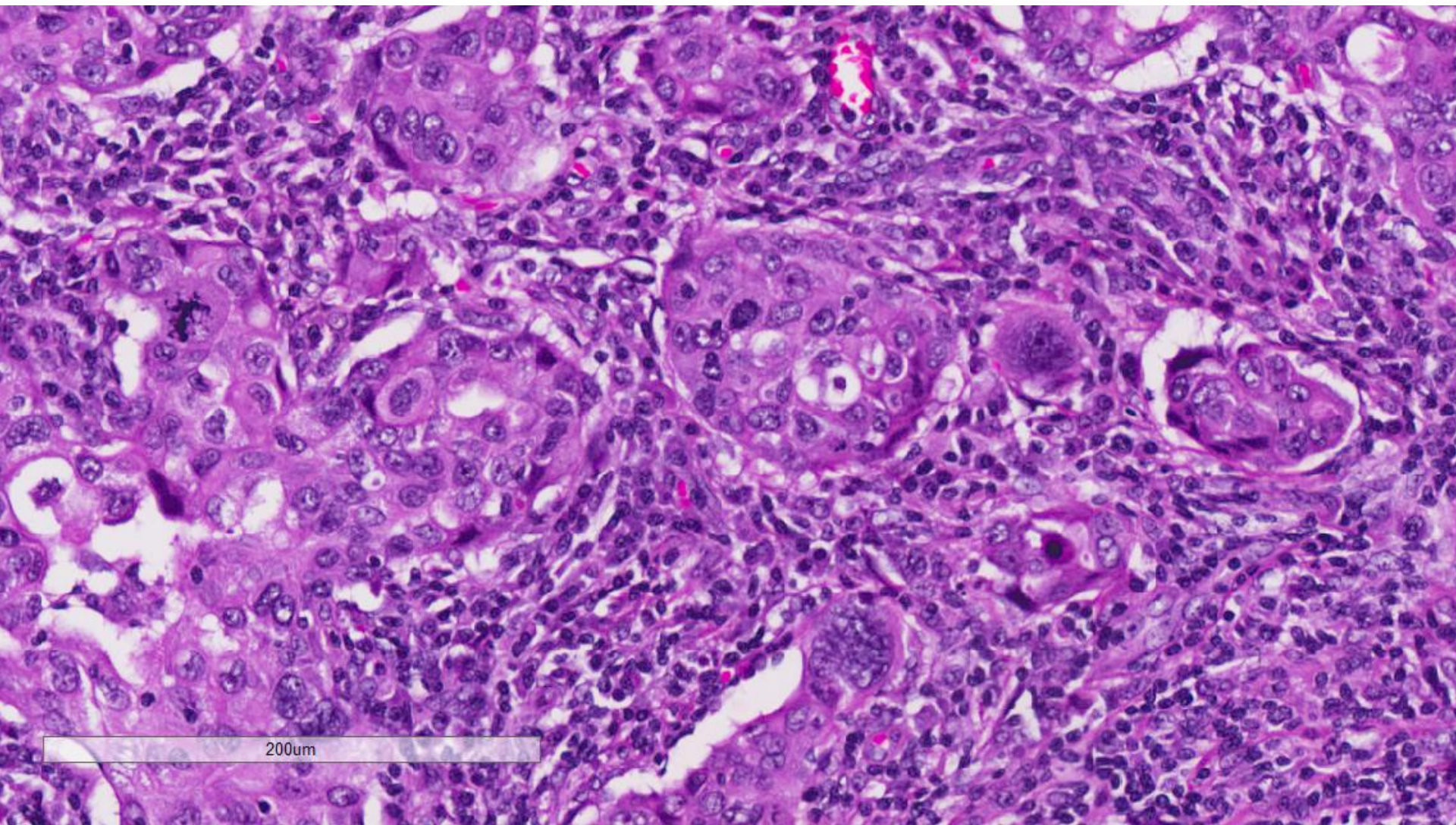


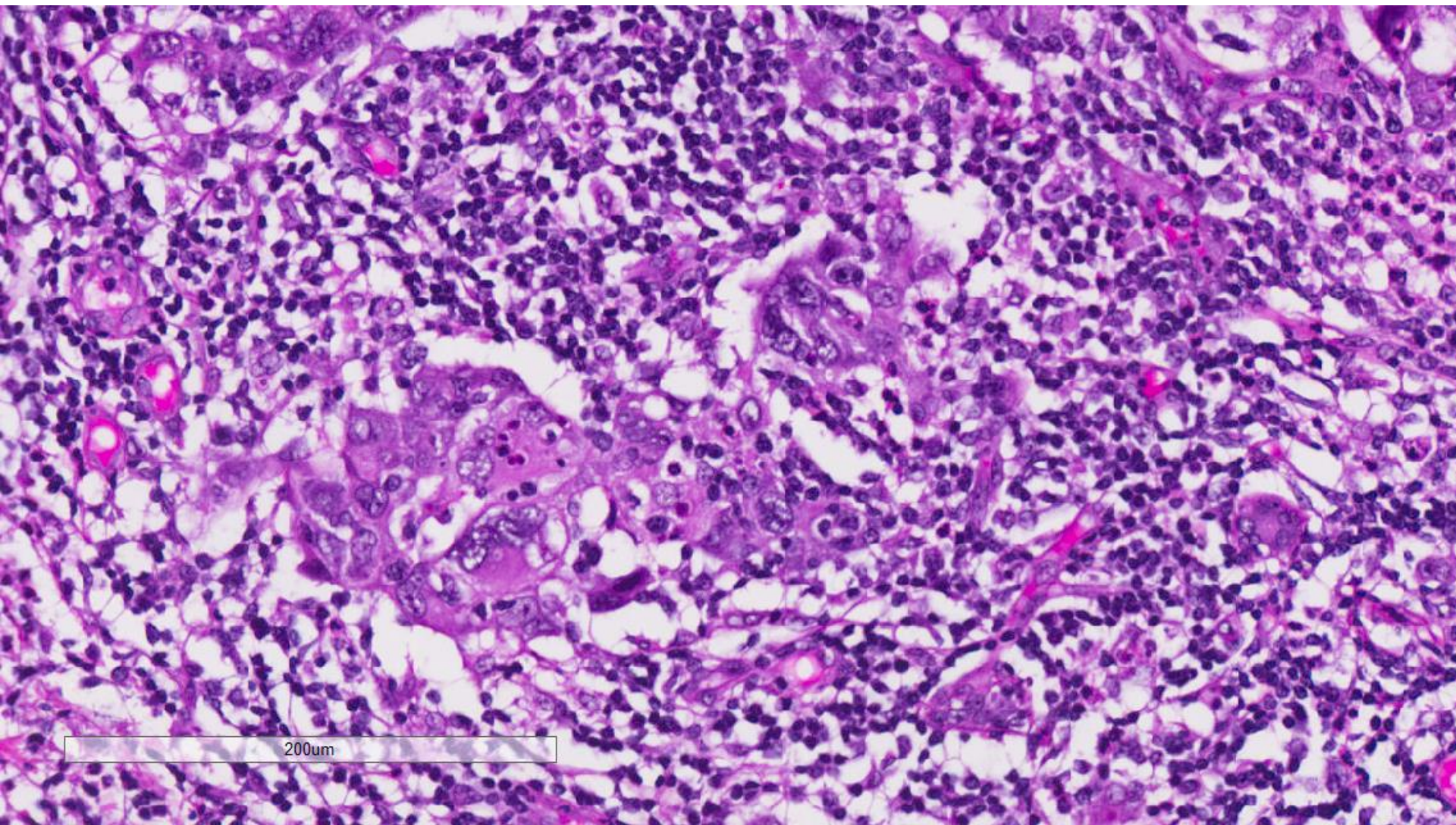












Invasive carcinoma with medullary-like
features,
ER negative, PR negative, cerbB2 negative