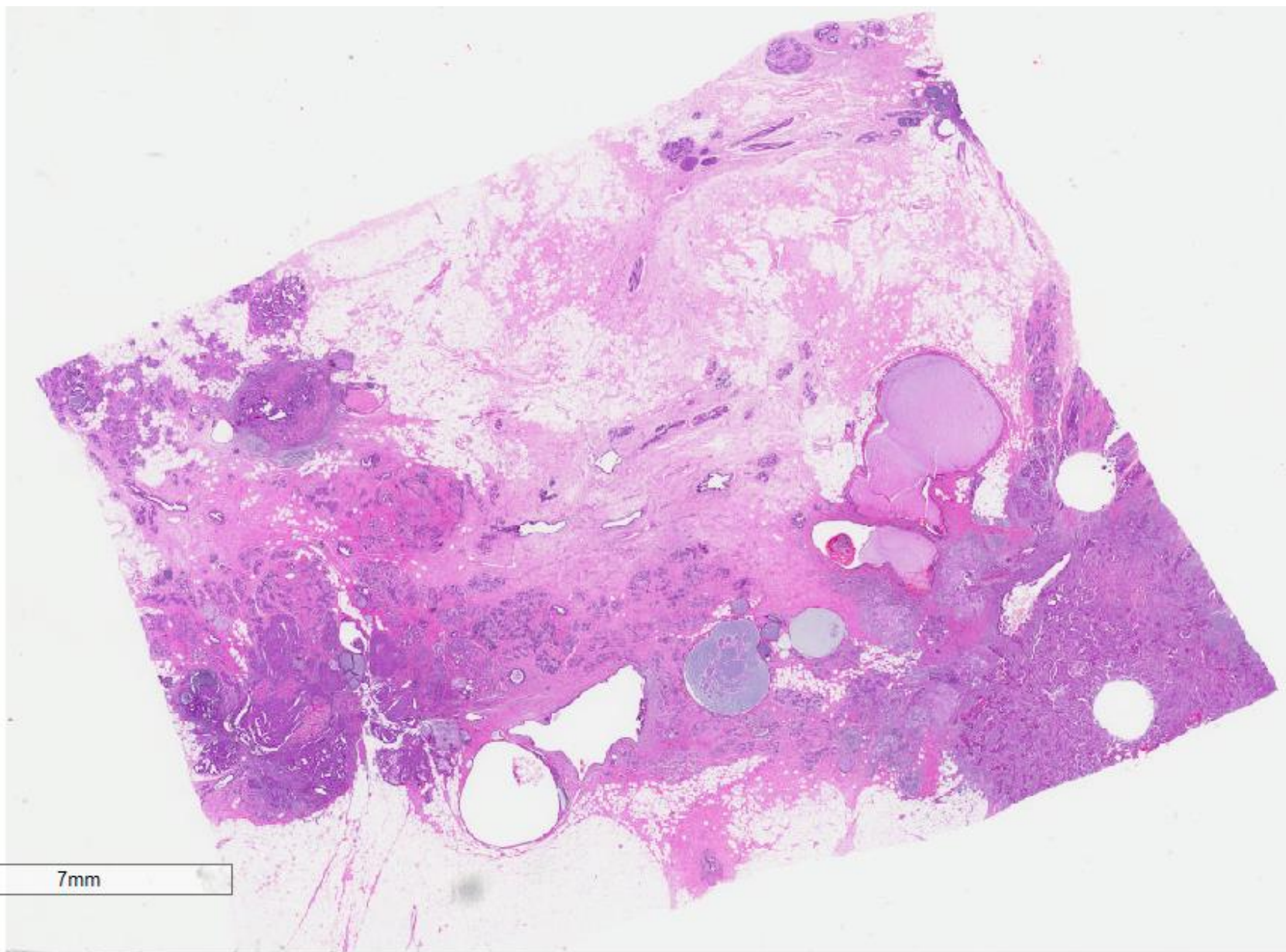


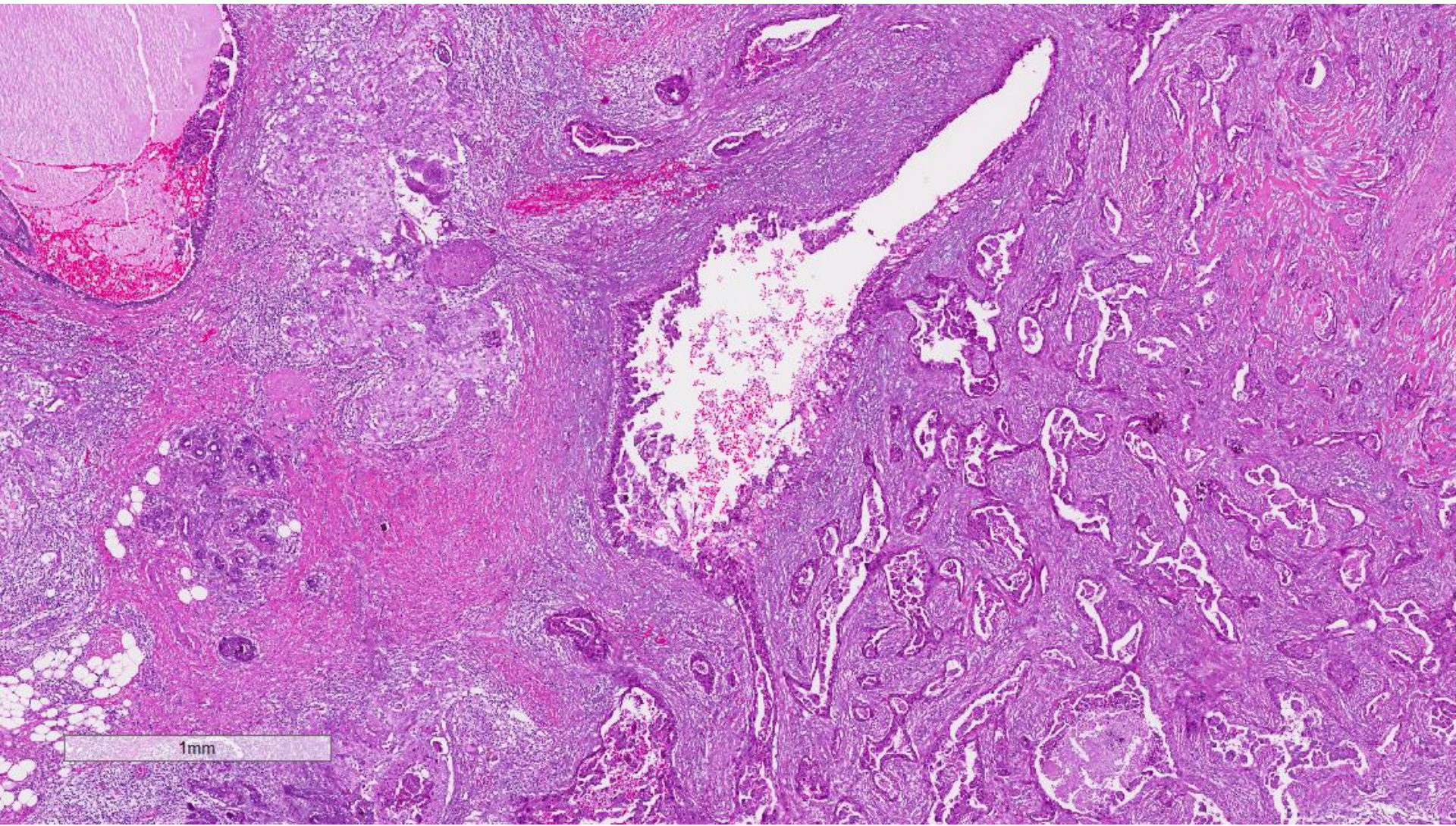
# Case 21

47 year old lady underwent a wide excision of a left breast mass.

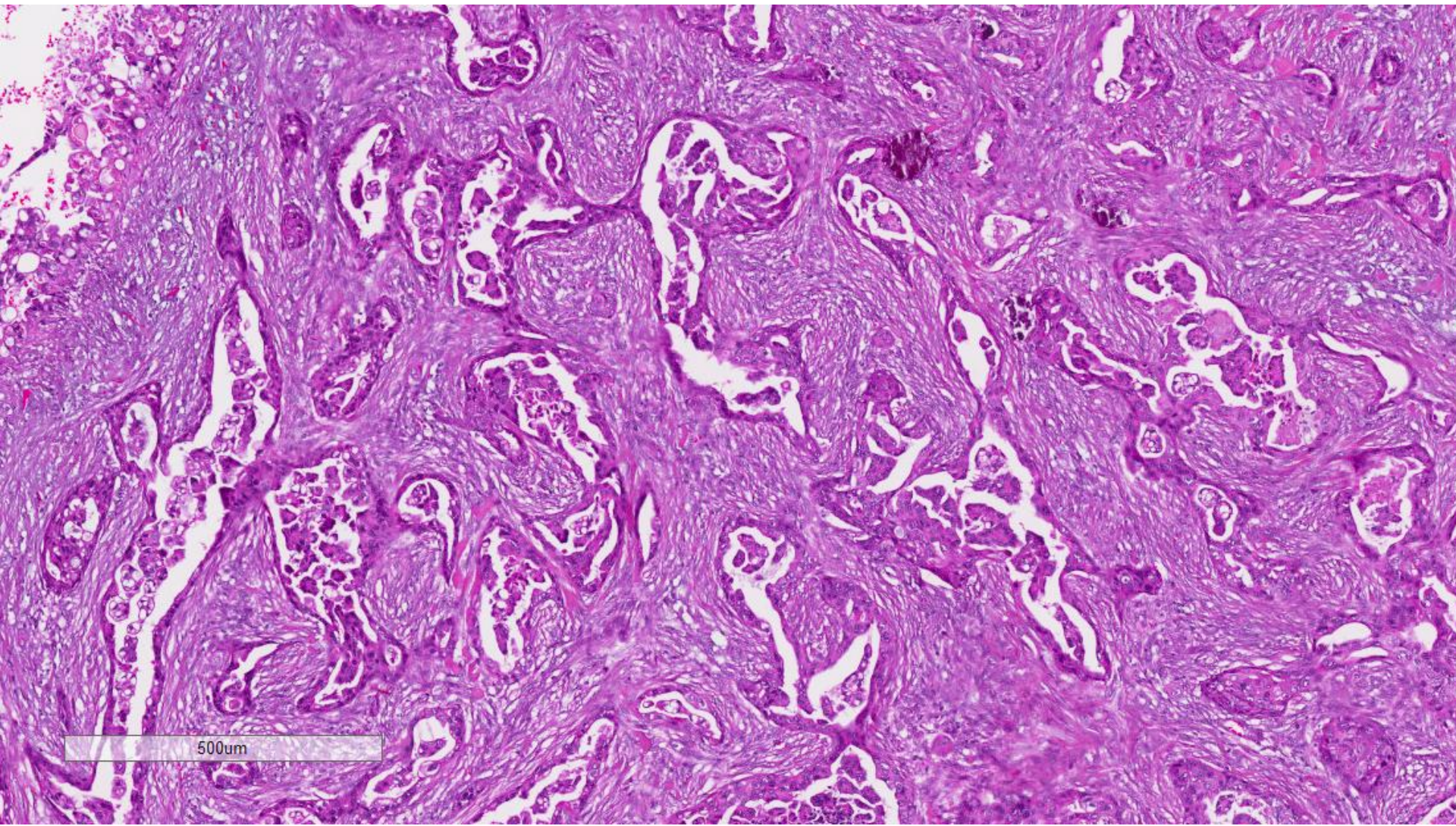


7mm



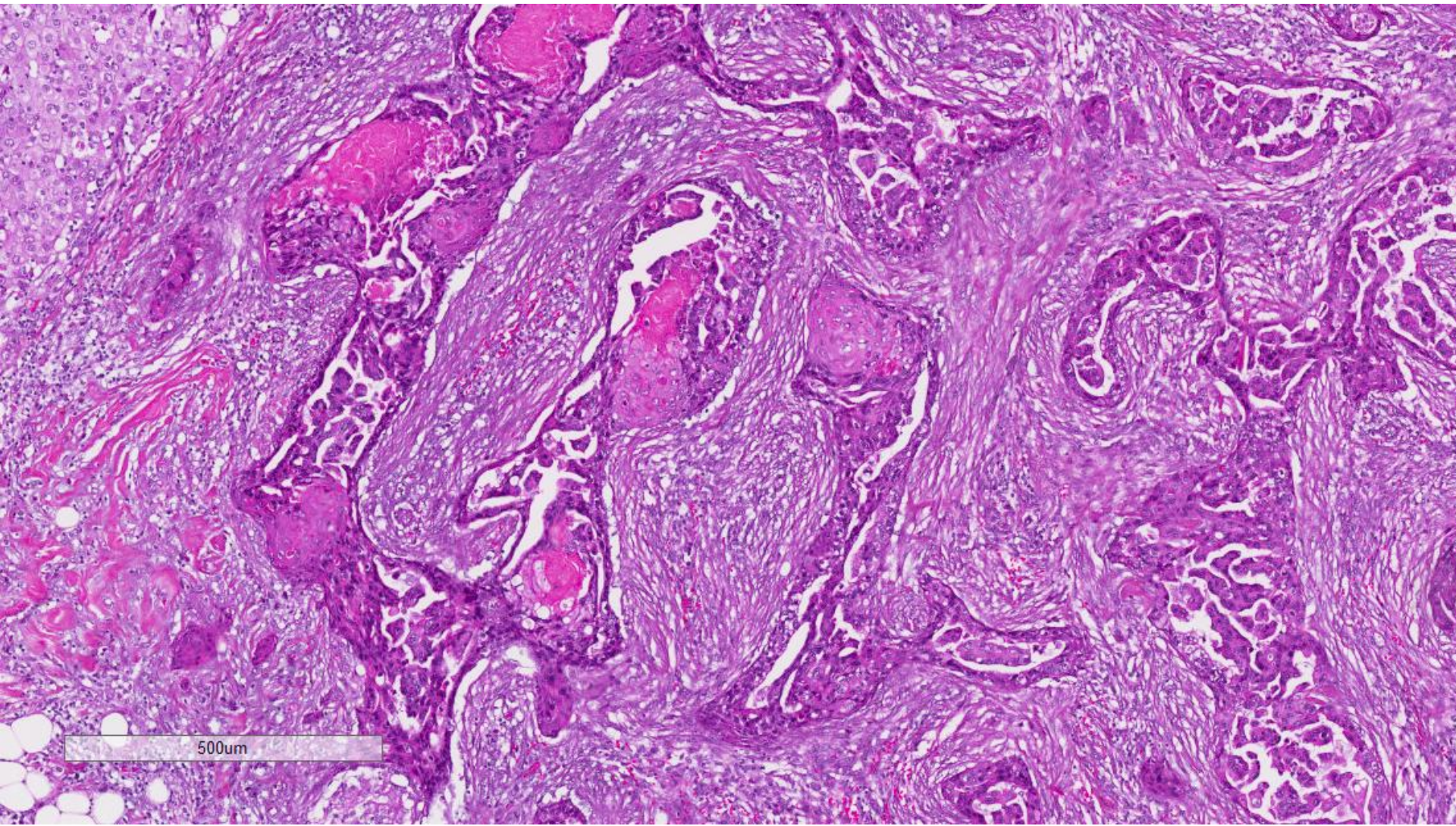






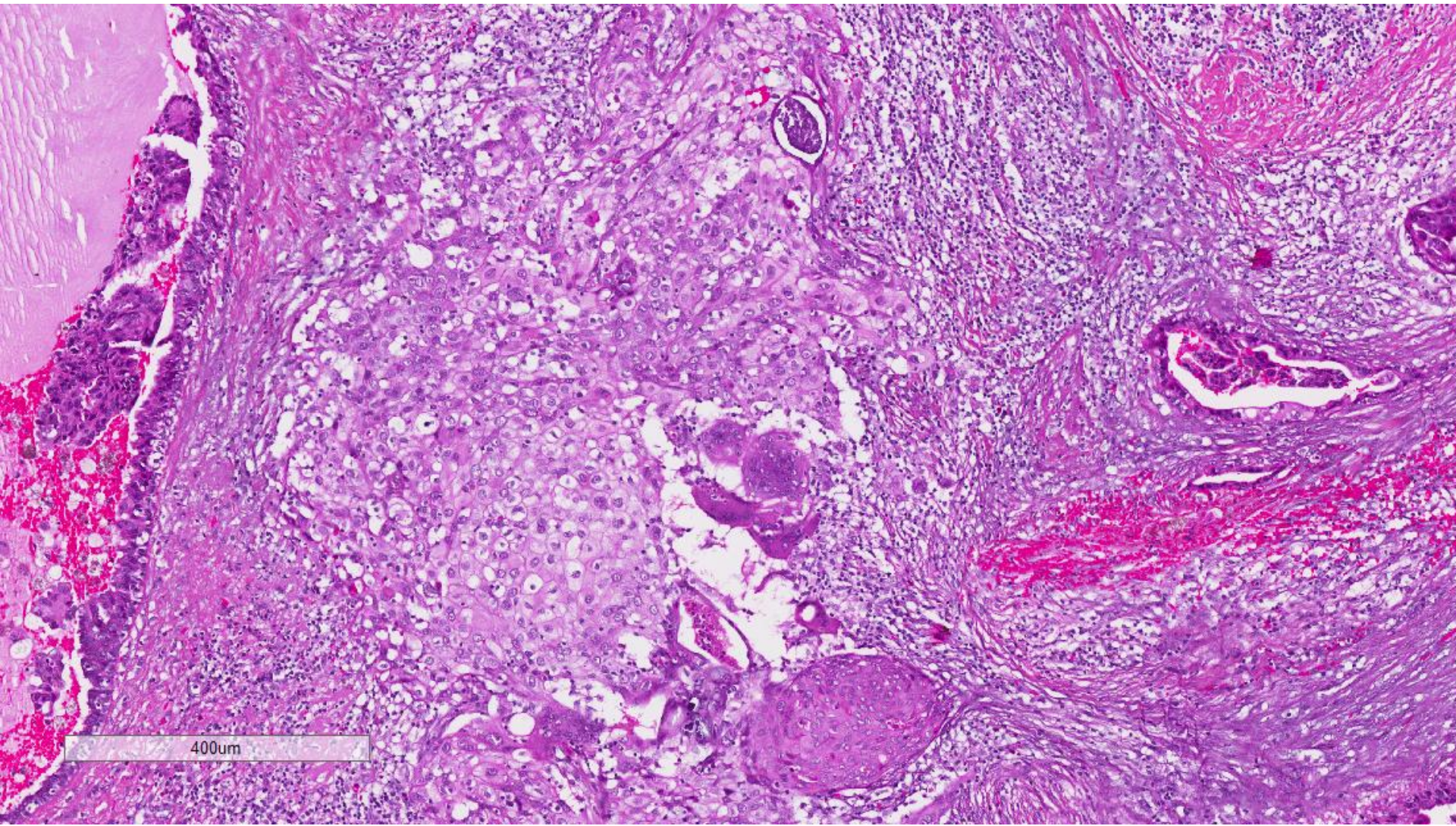
500um





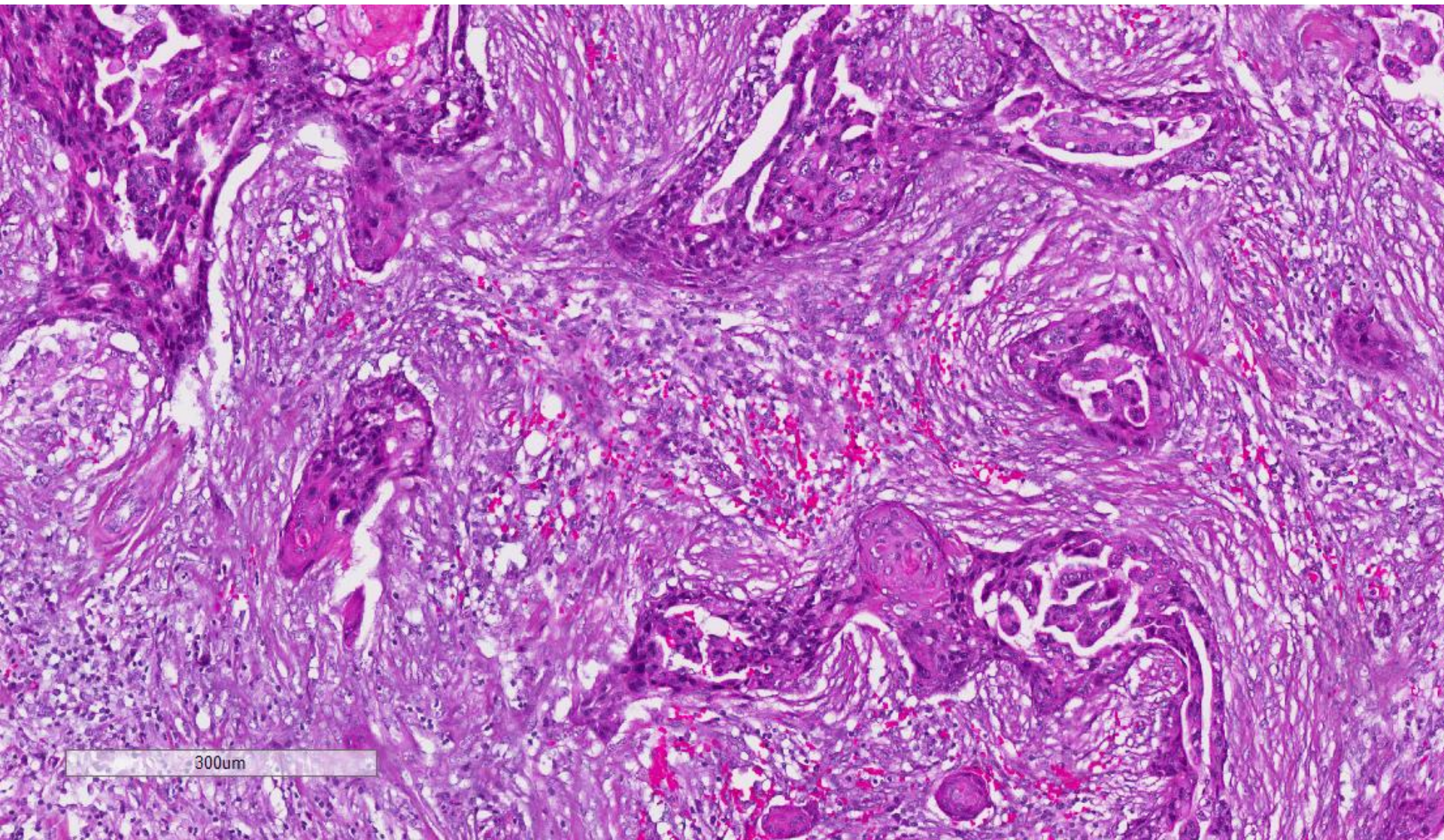
500um





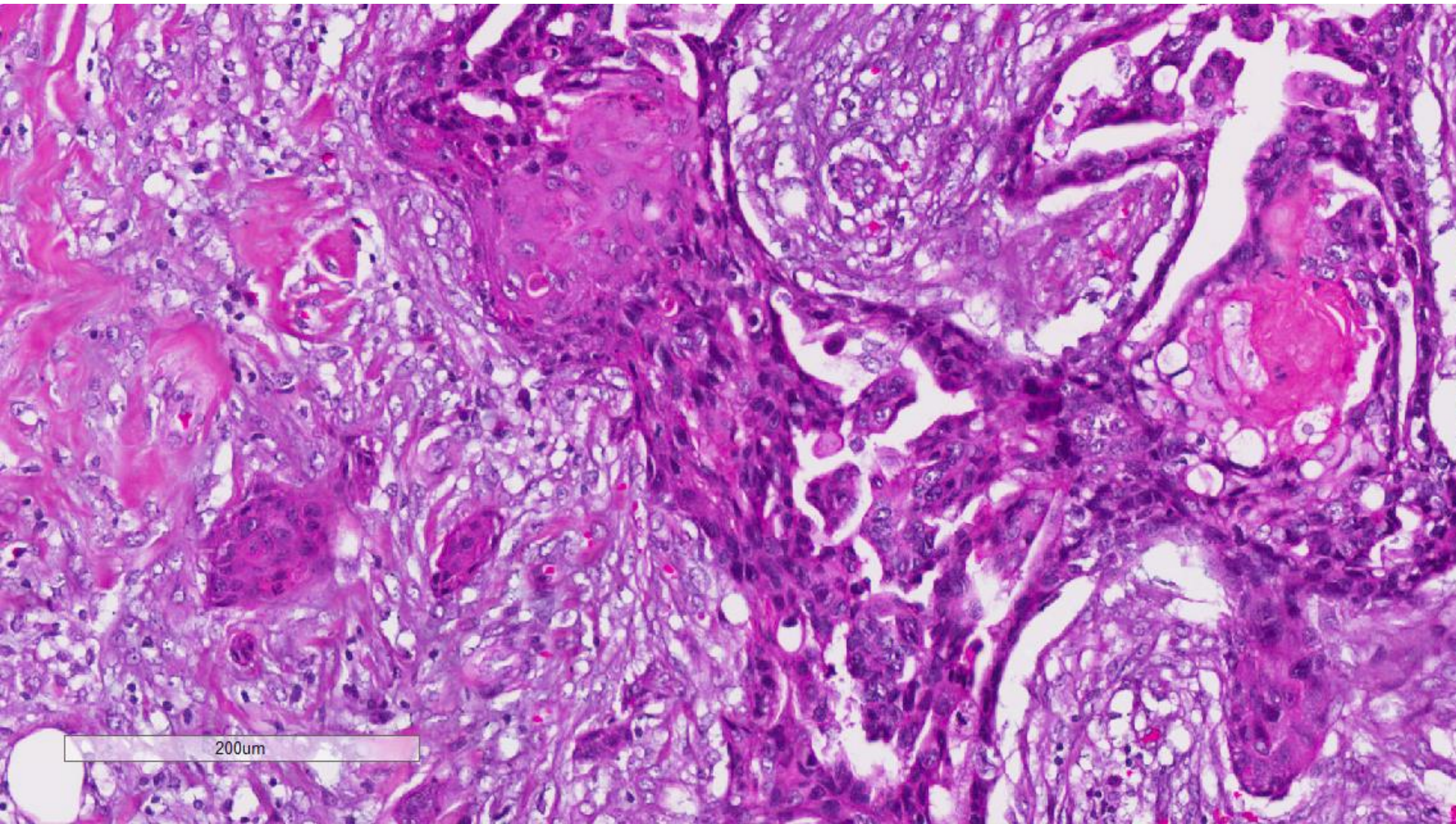
400um



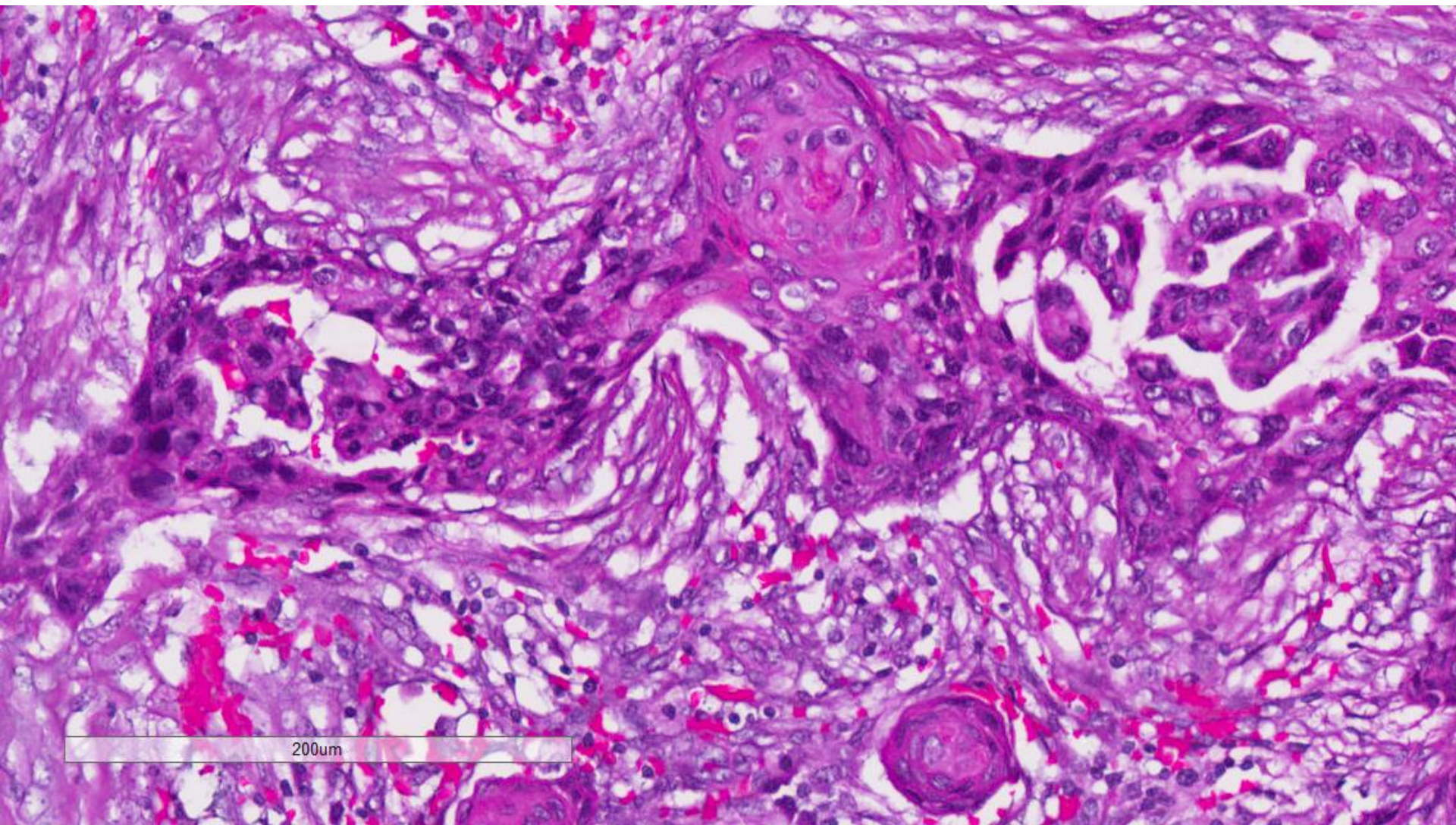


300um









200µm



# Metaplastic carcinoma (squamous differentiation)