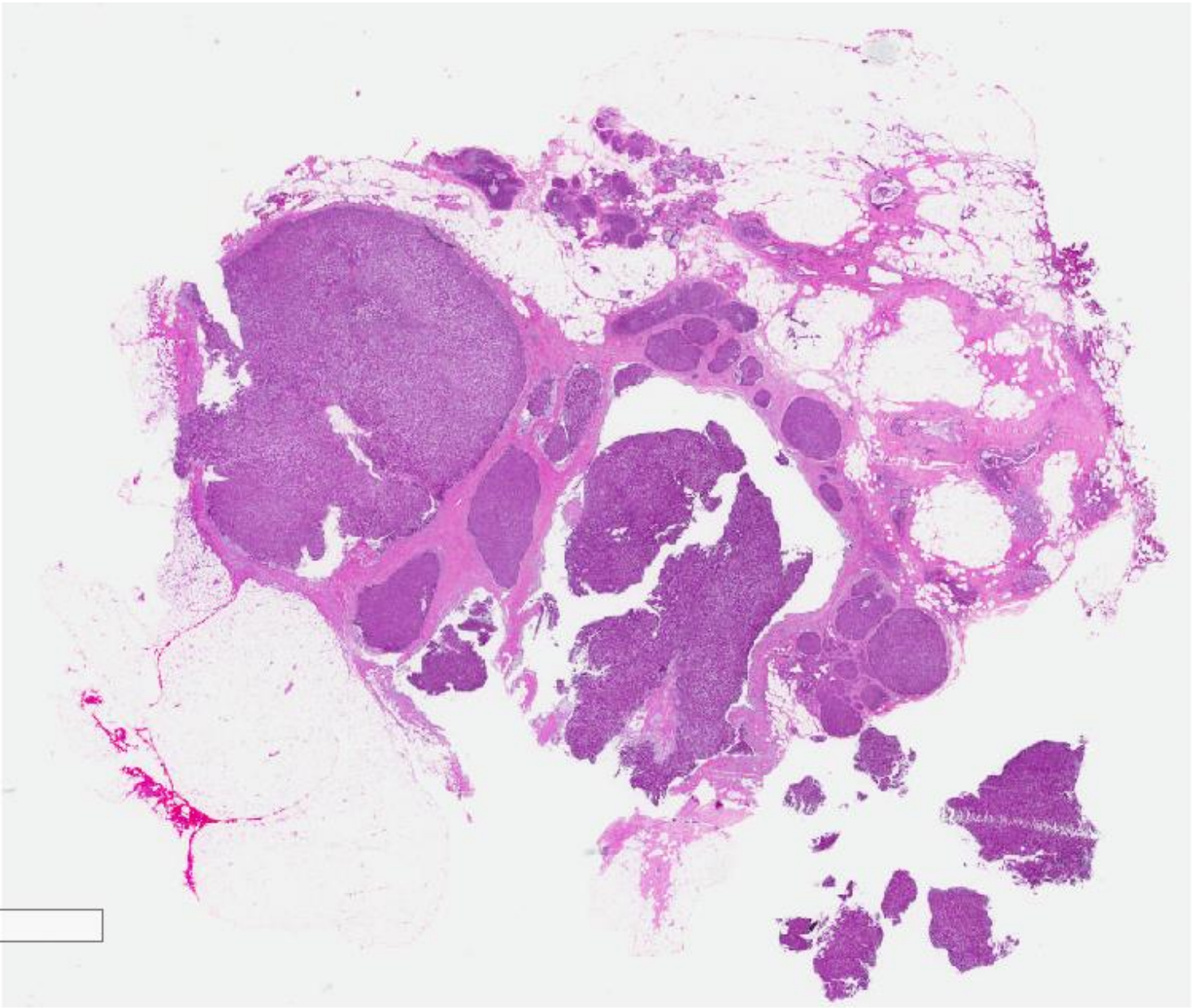
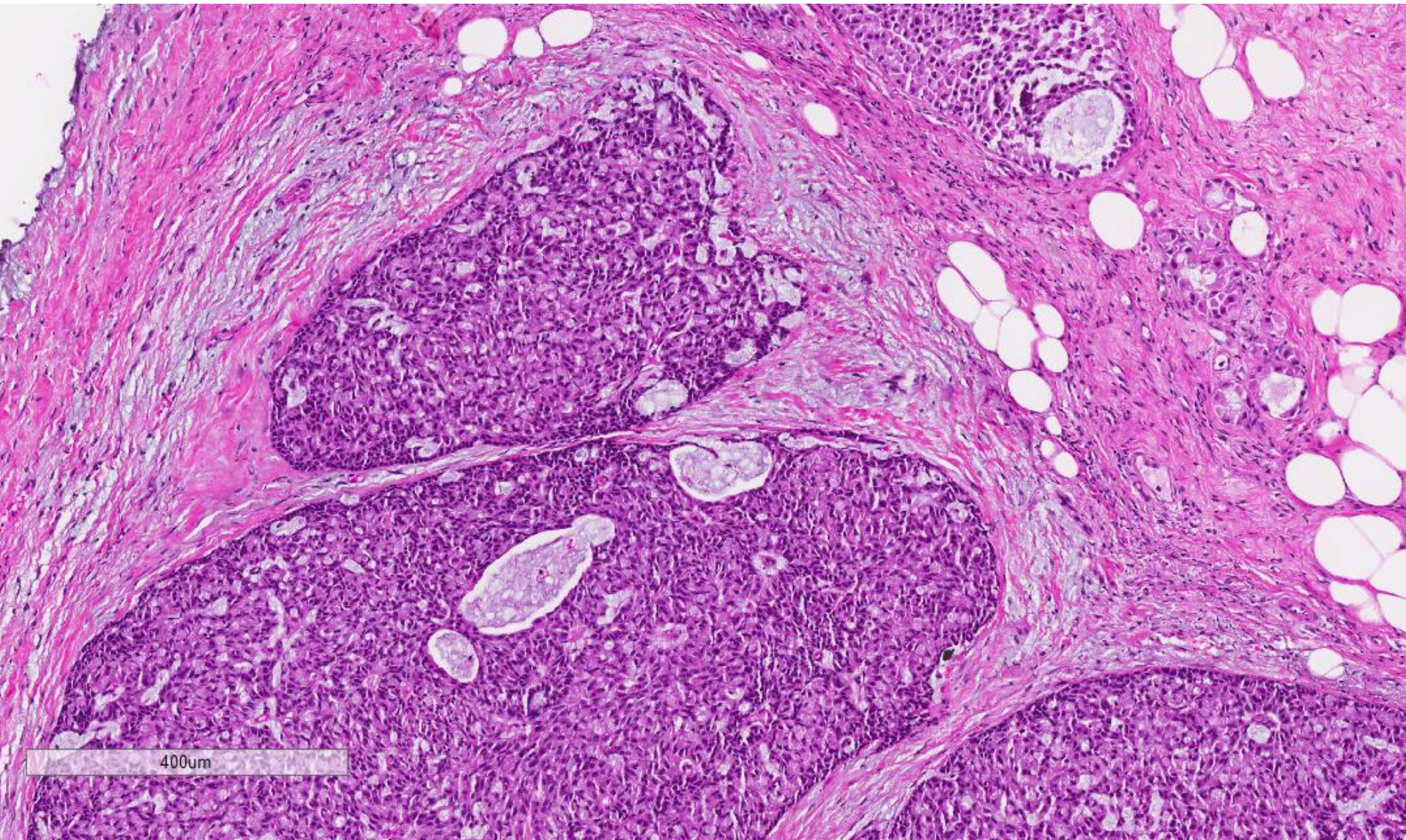


Case 14

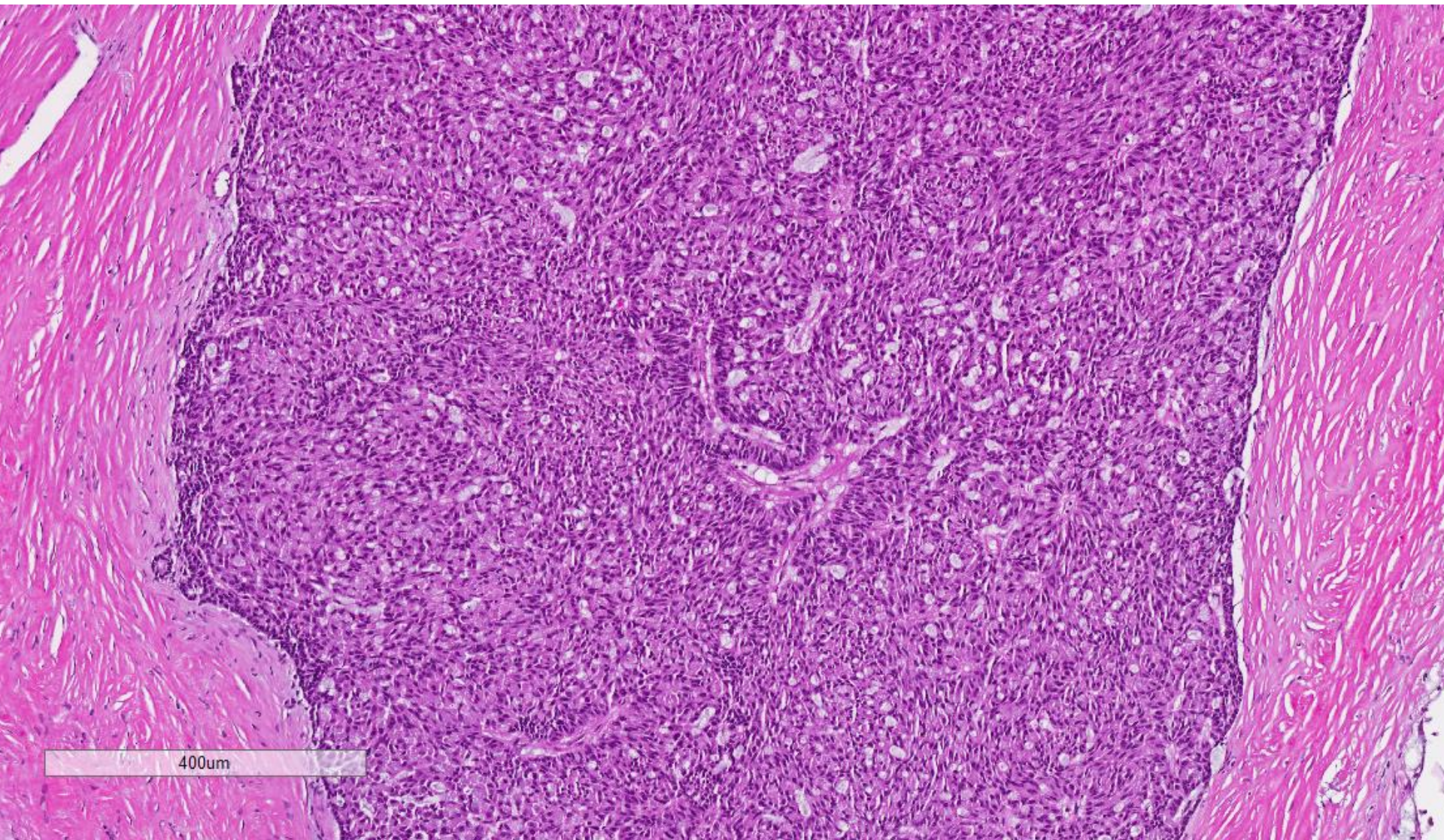
71 year old lady underwent mastectomy
for a right breast mass.



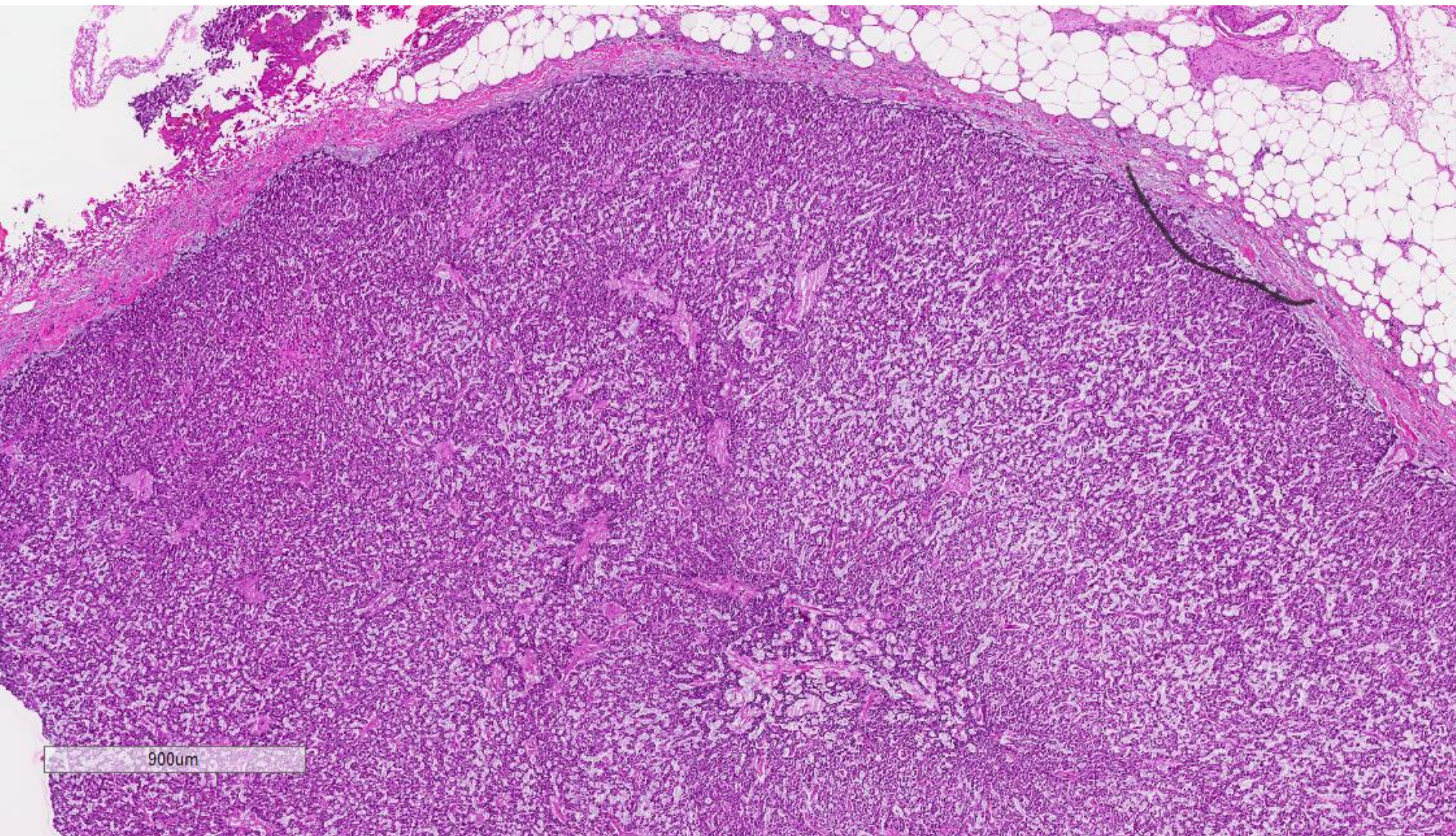
7mm



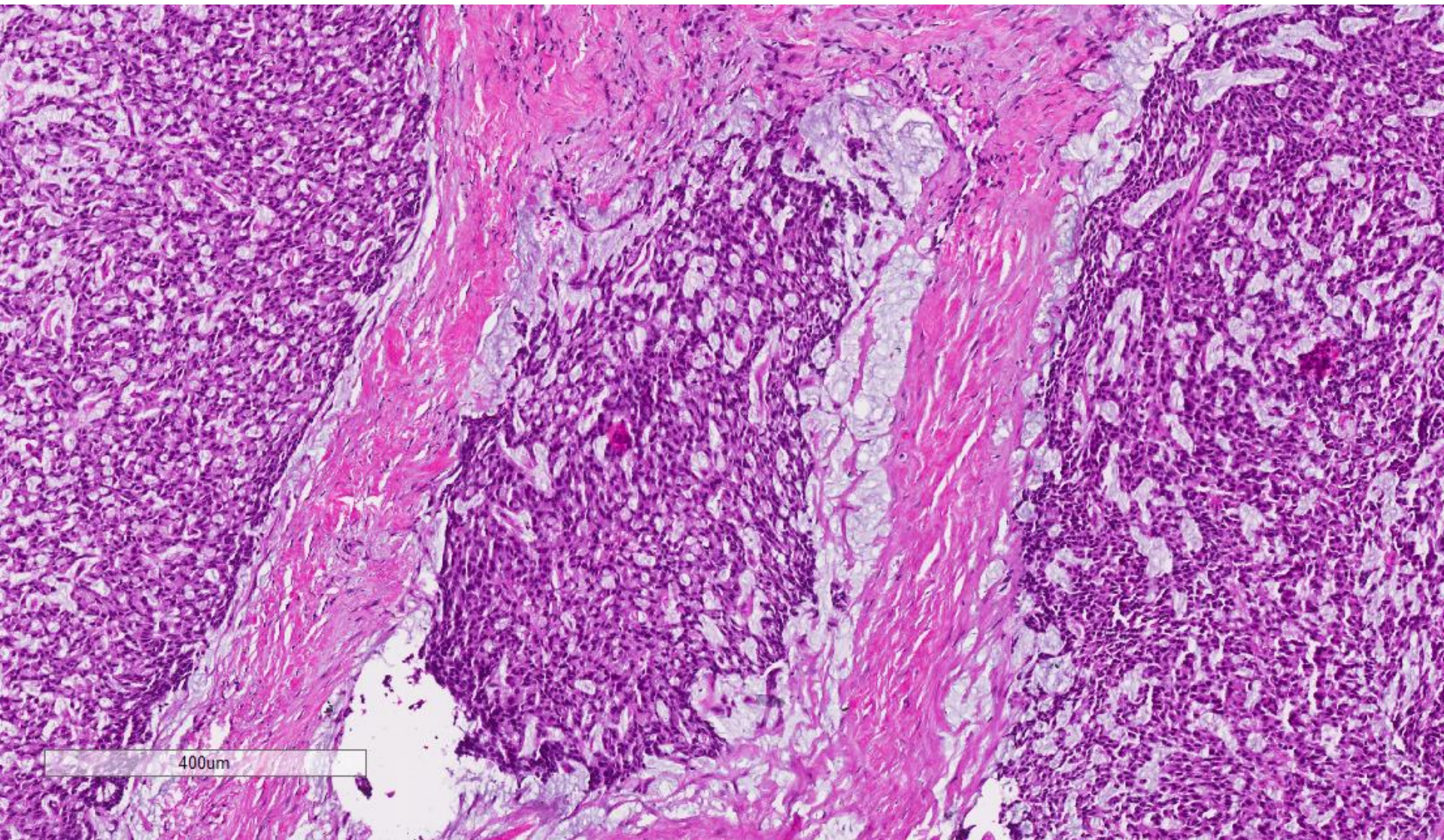
400um

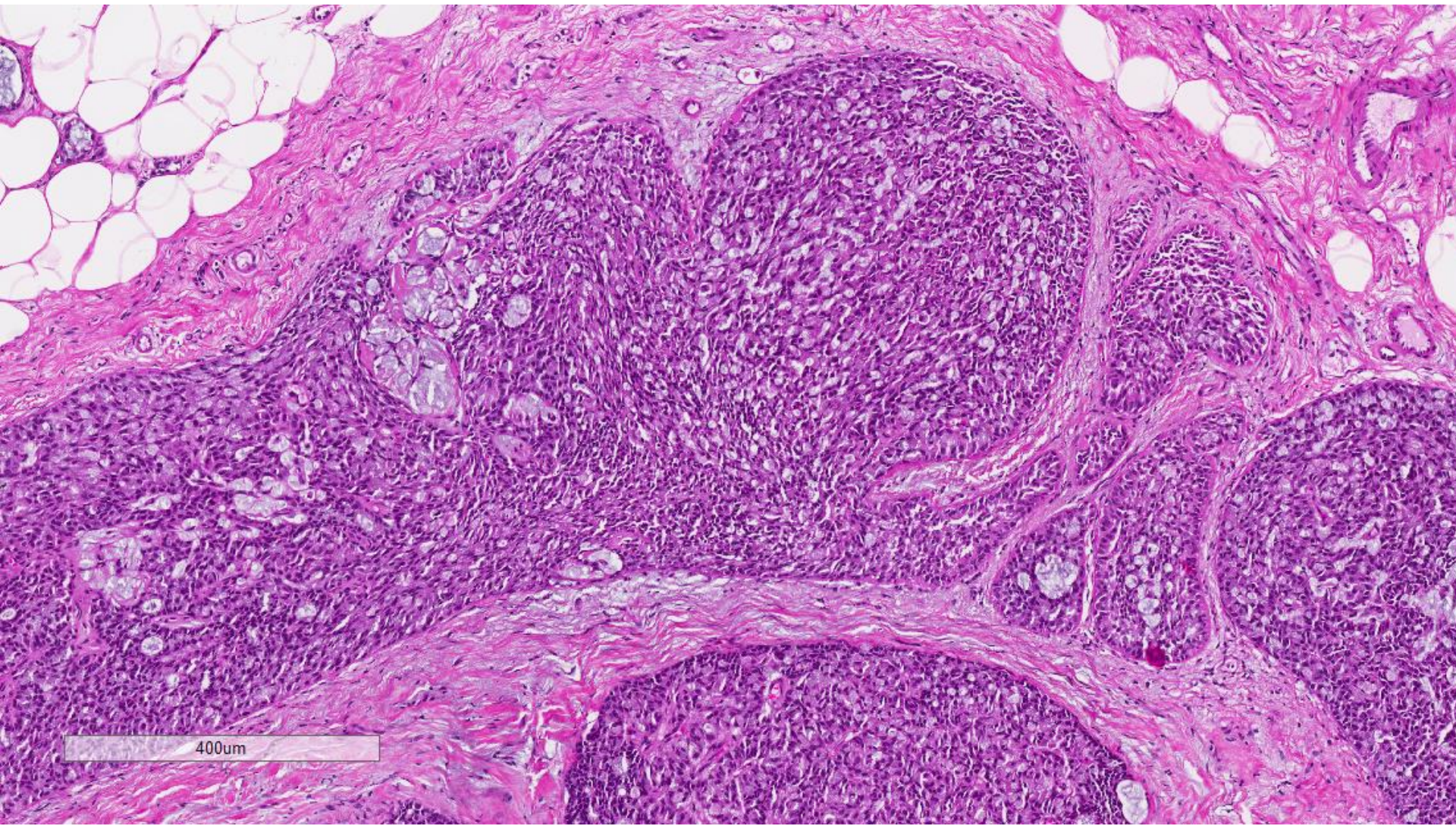


400um

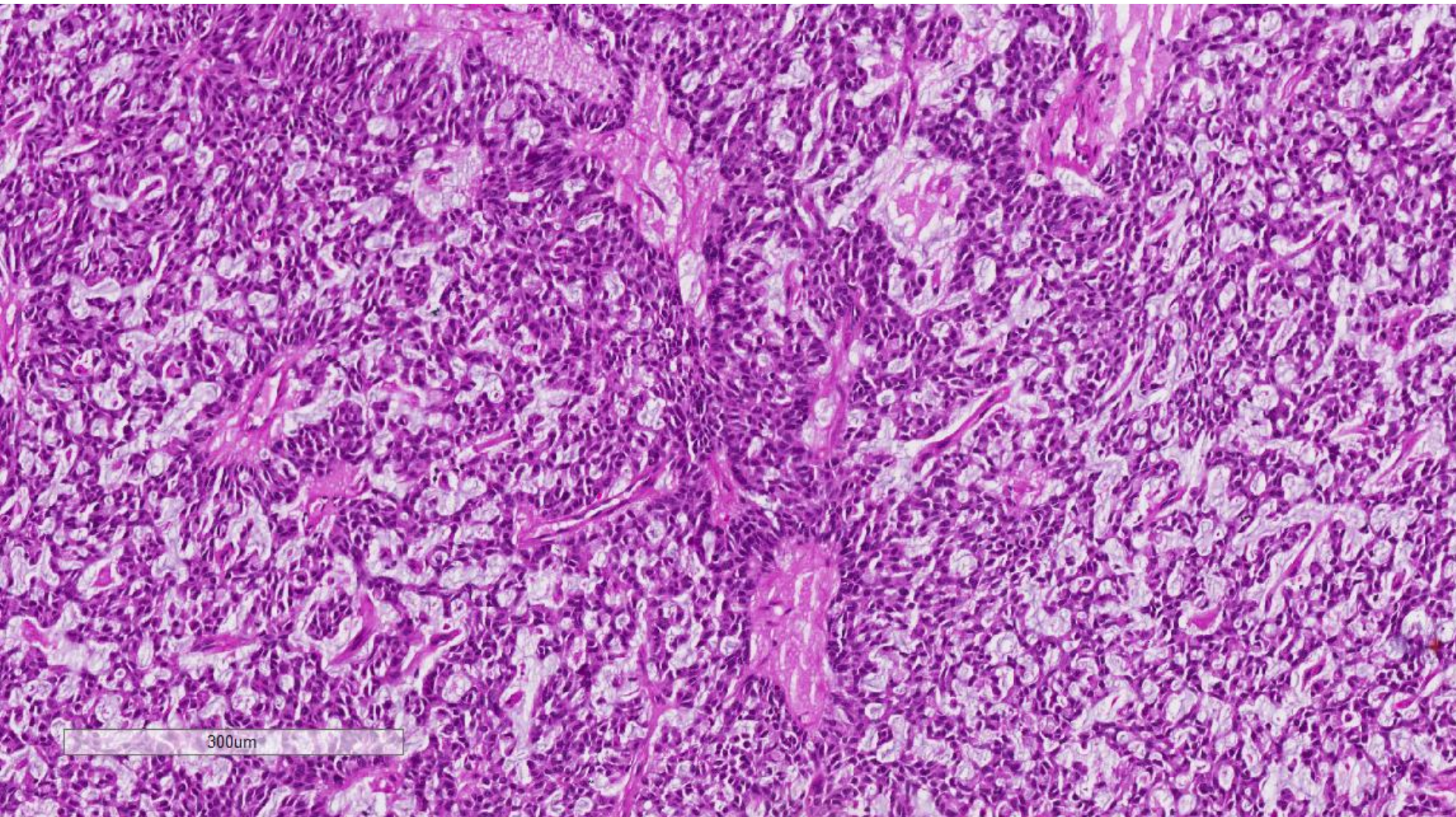


900um



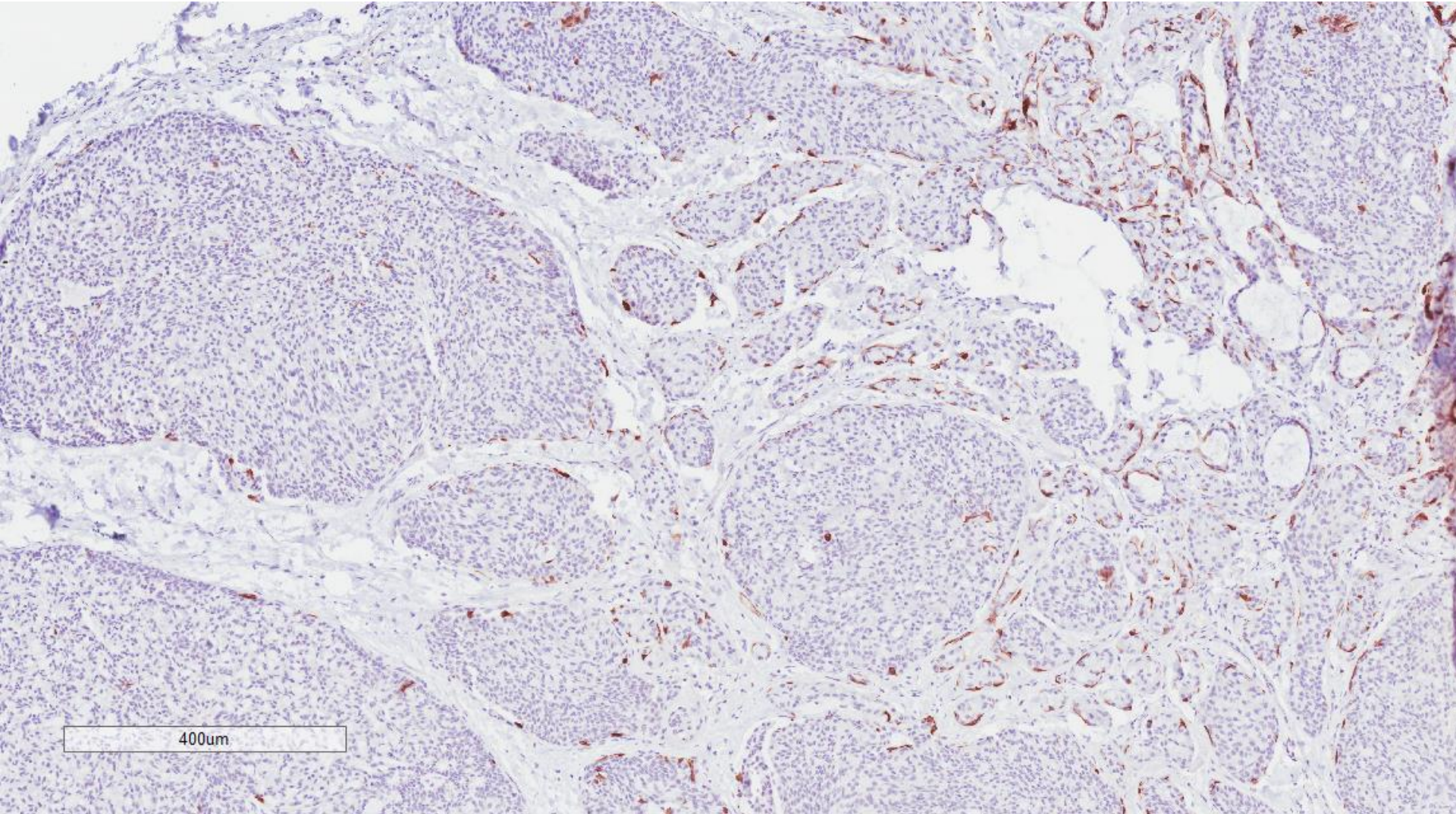


400um

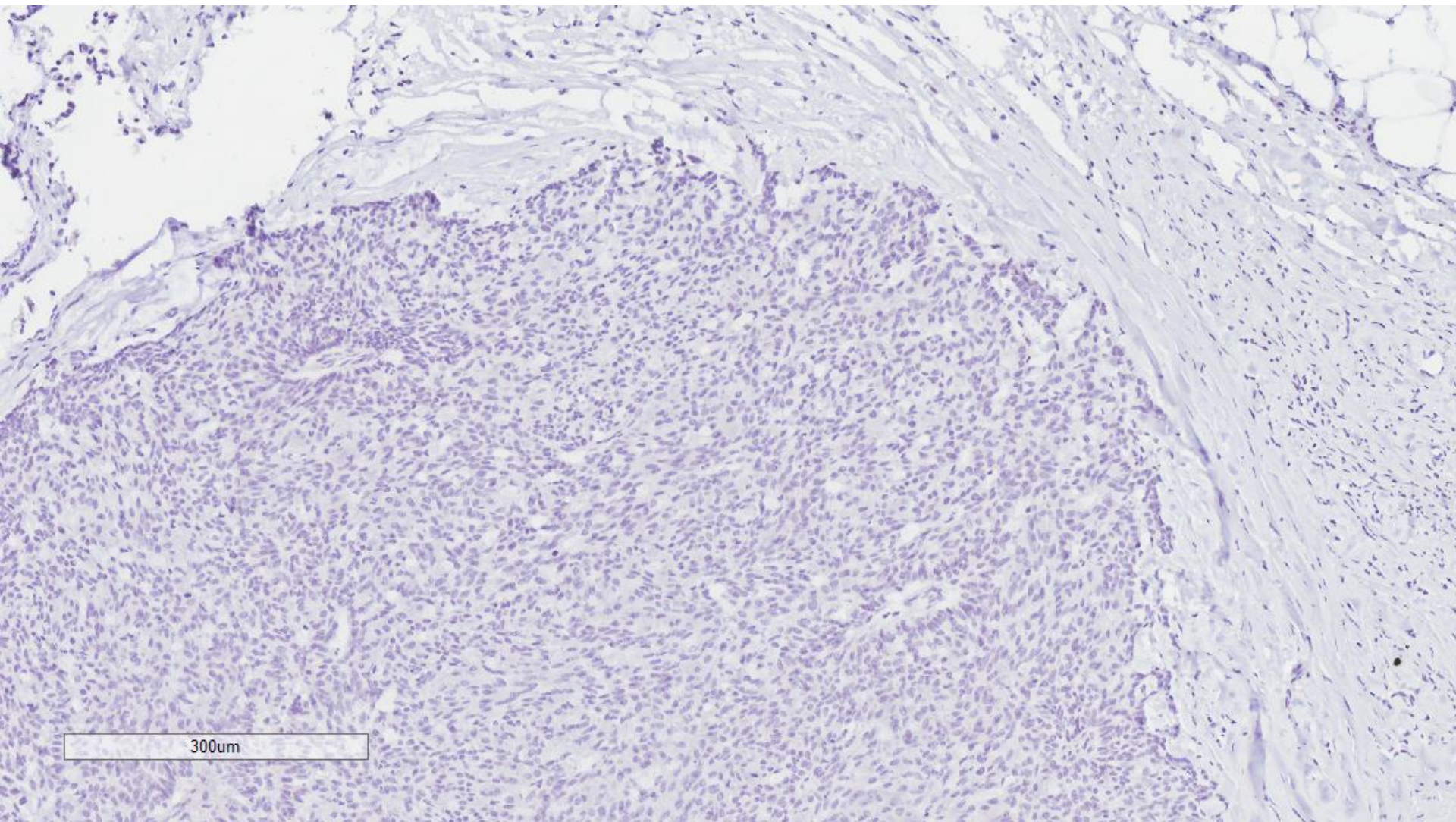


300um

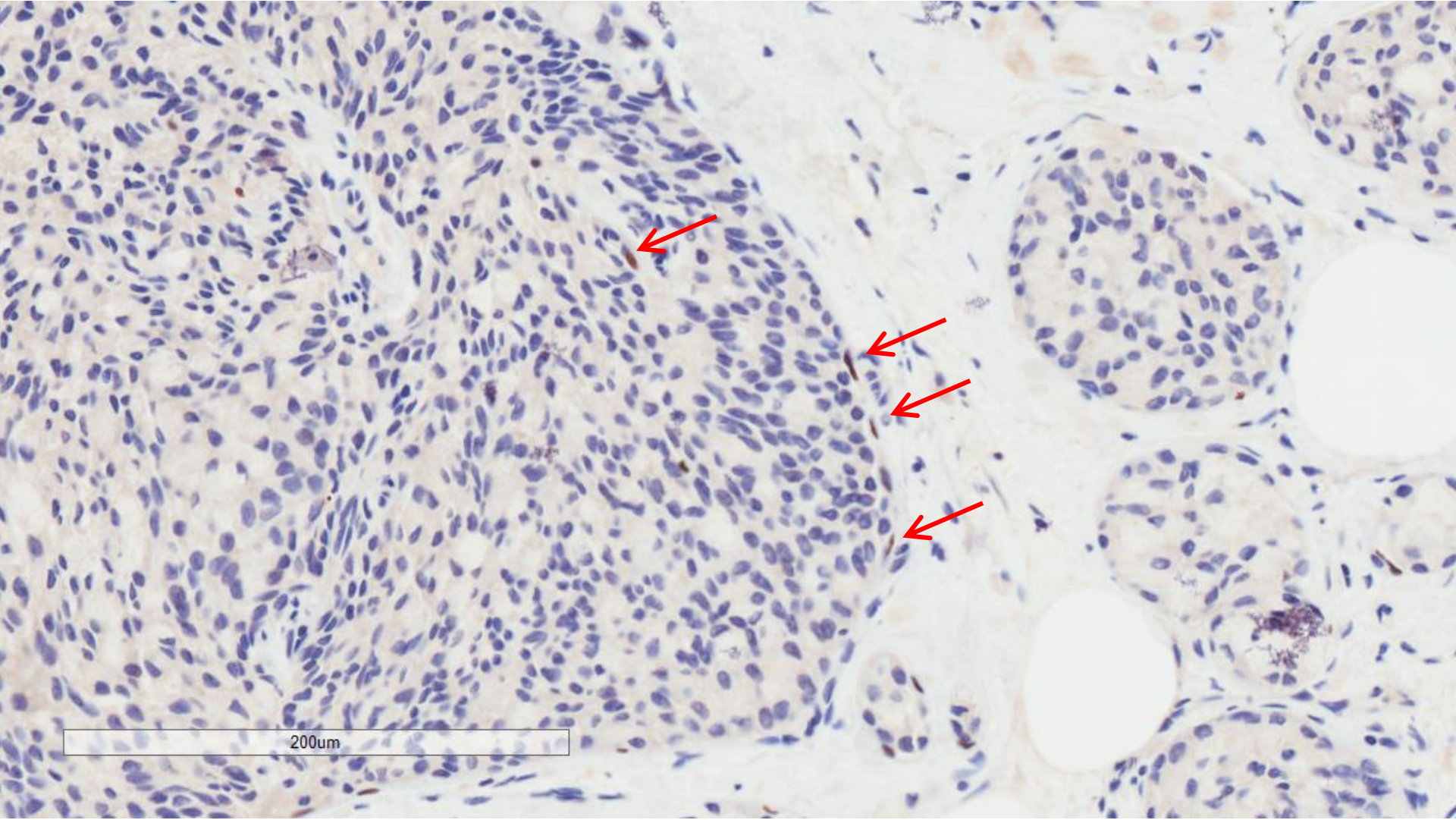
CK5/6



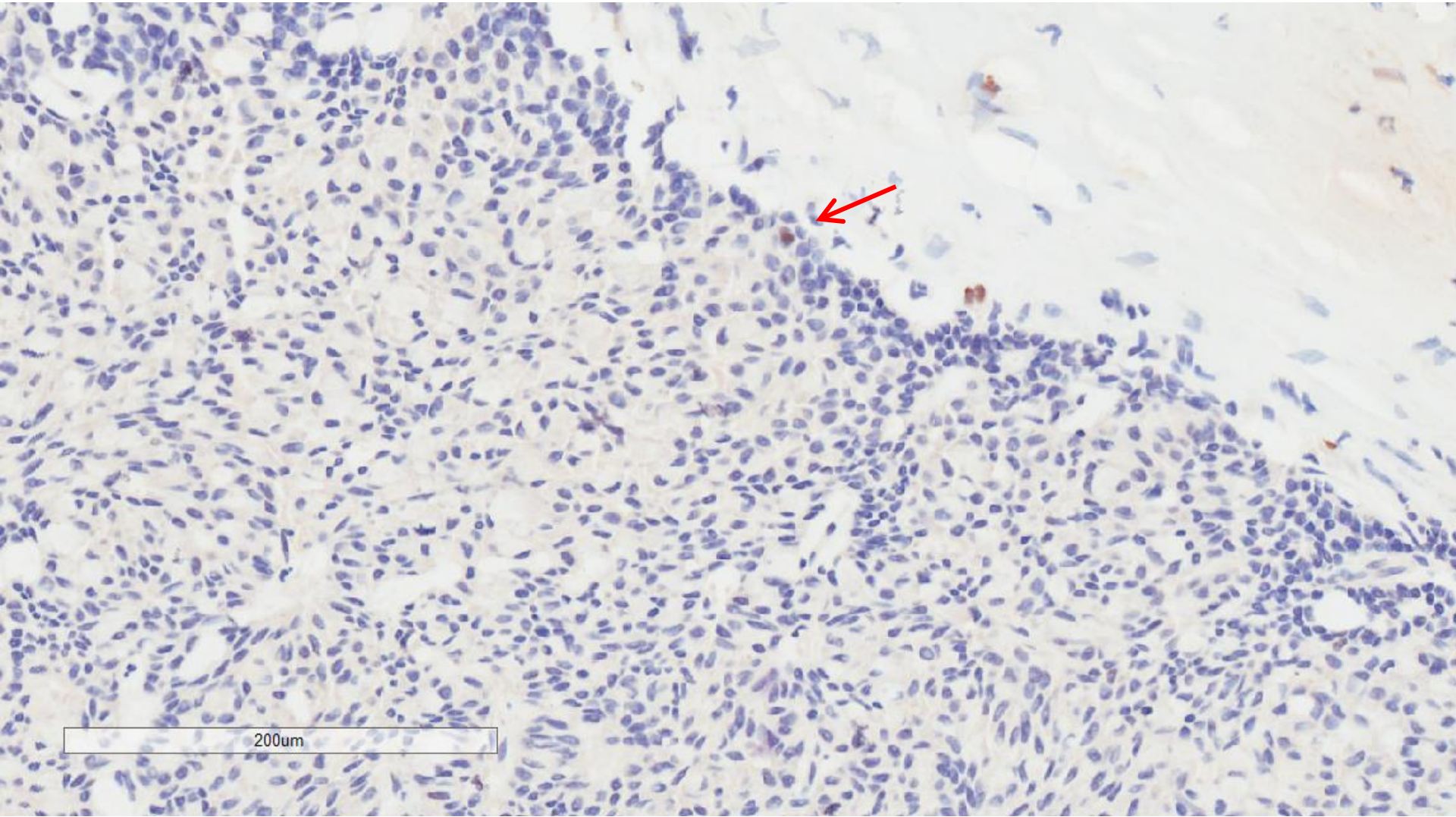
CK5/6



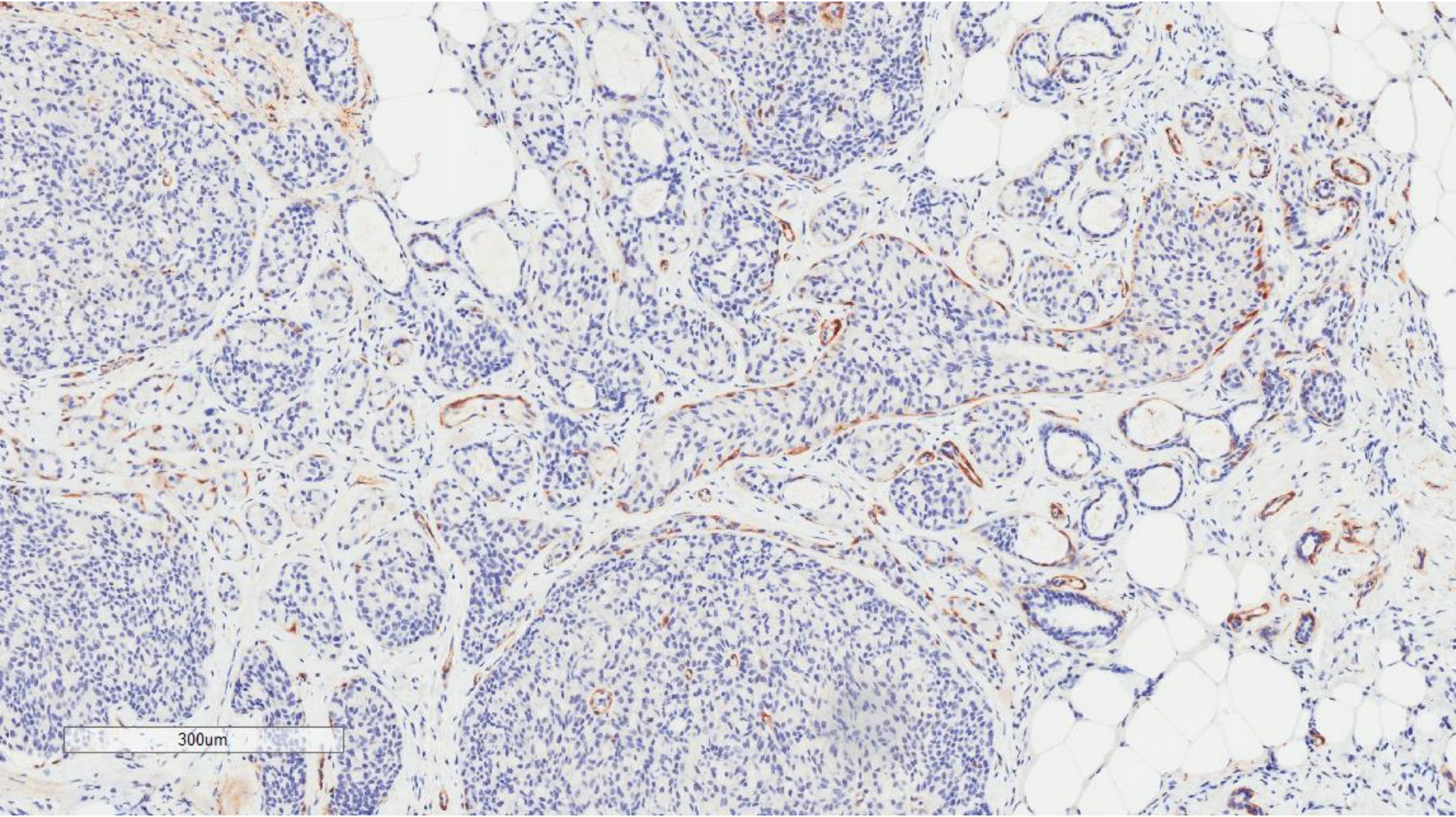
p63



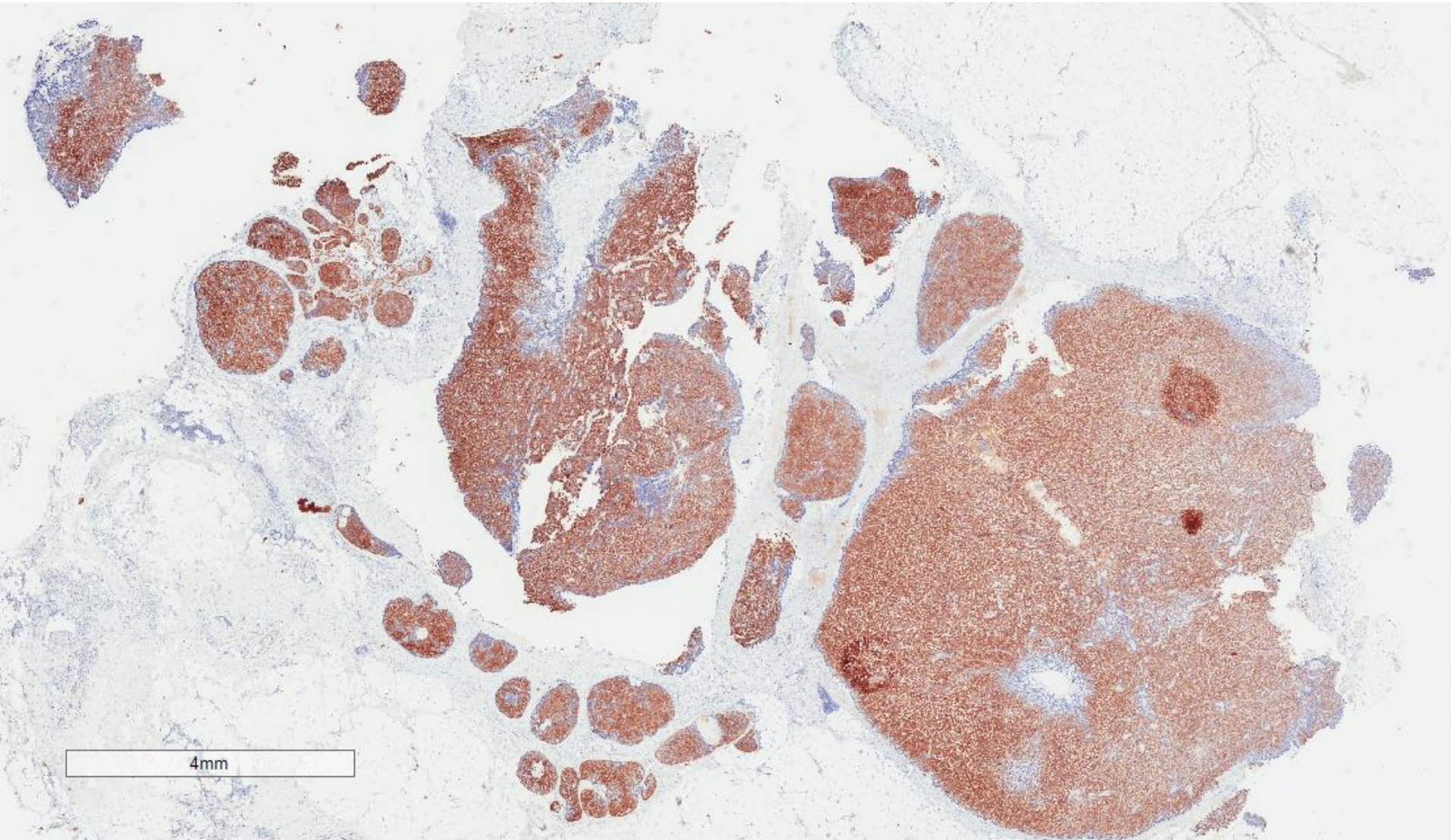
p63



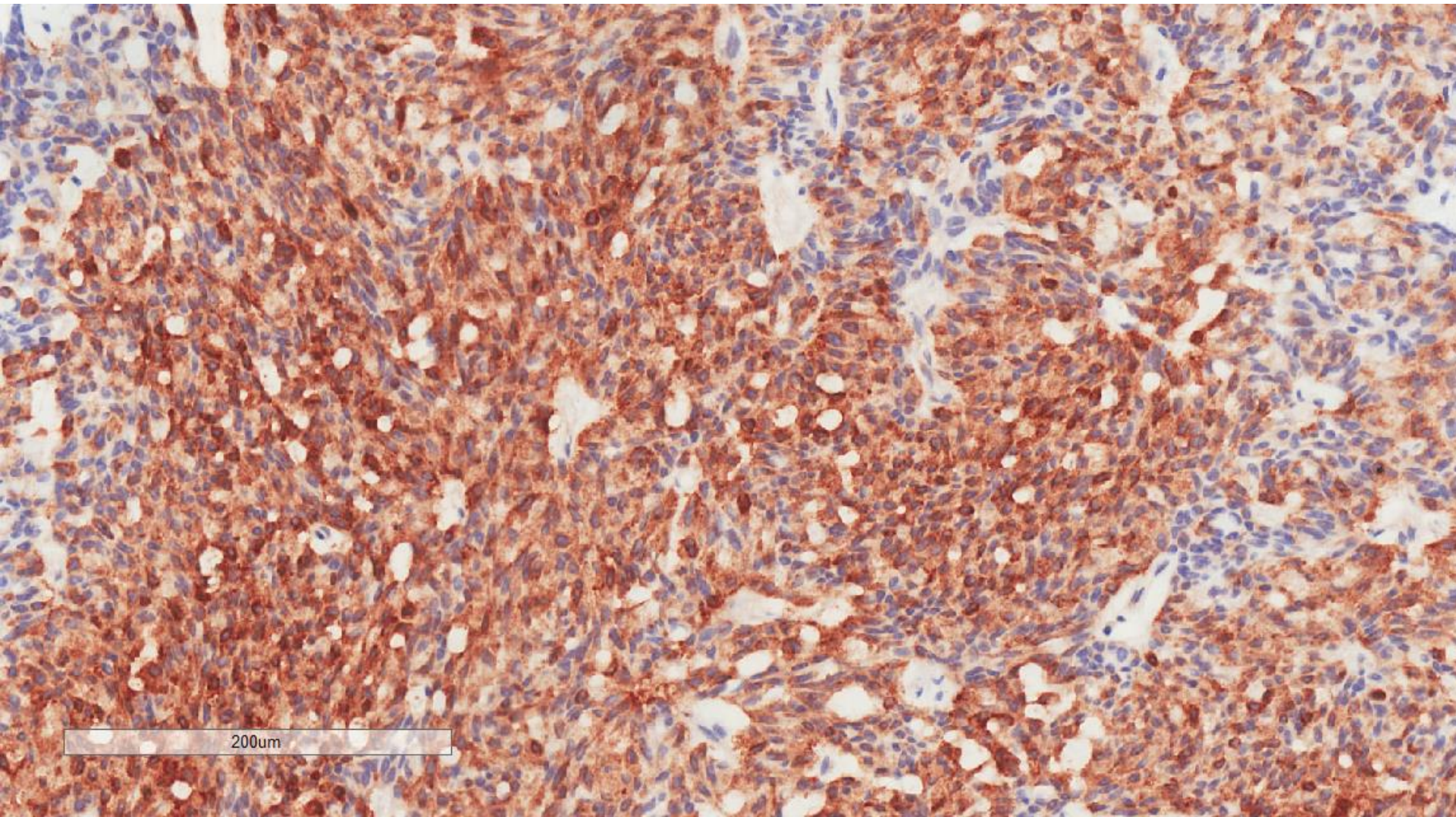
SMMHC



synaptophysin



synaptophysin



Solid-papillary carcinoma, with focal invasion