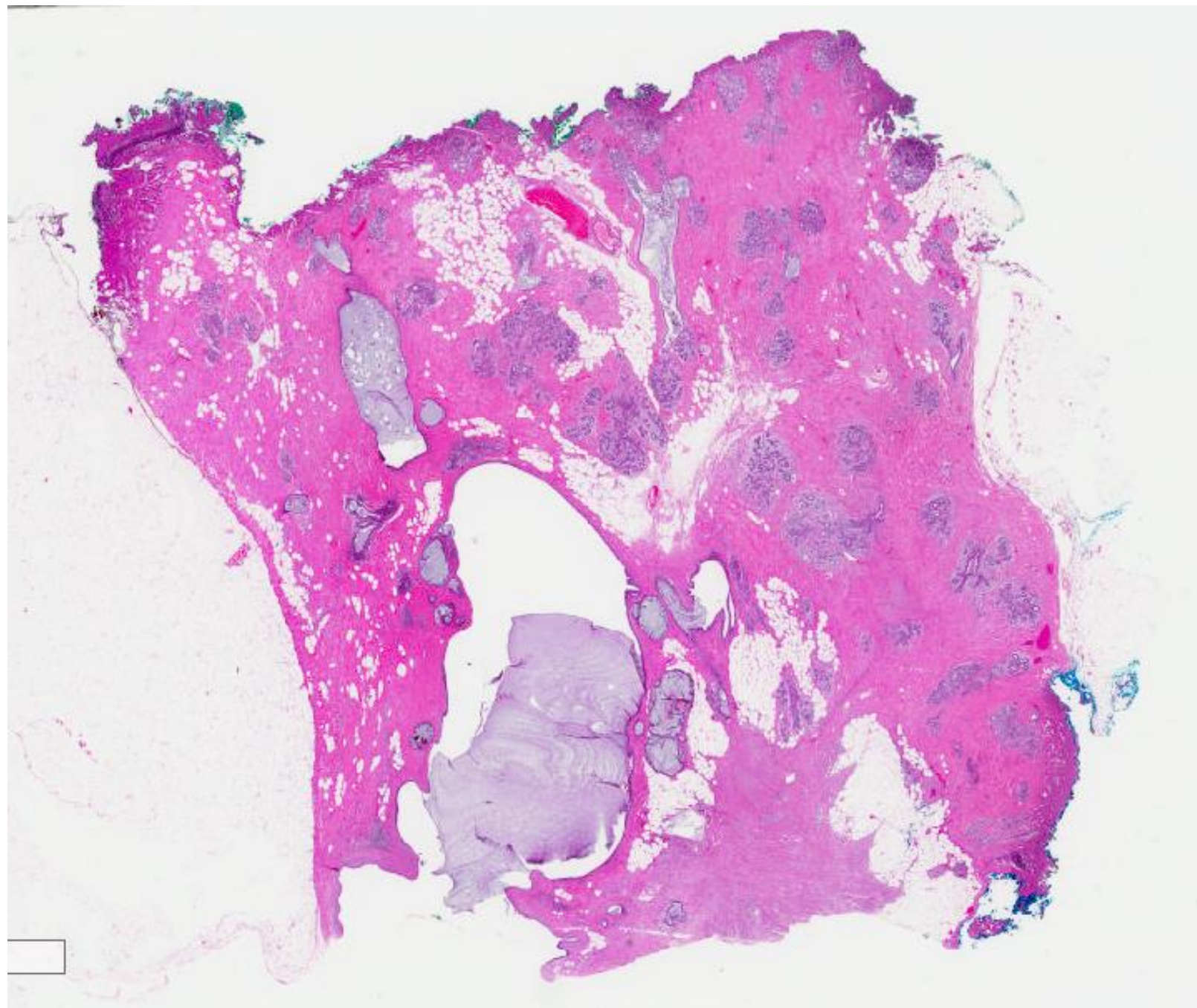
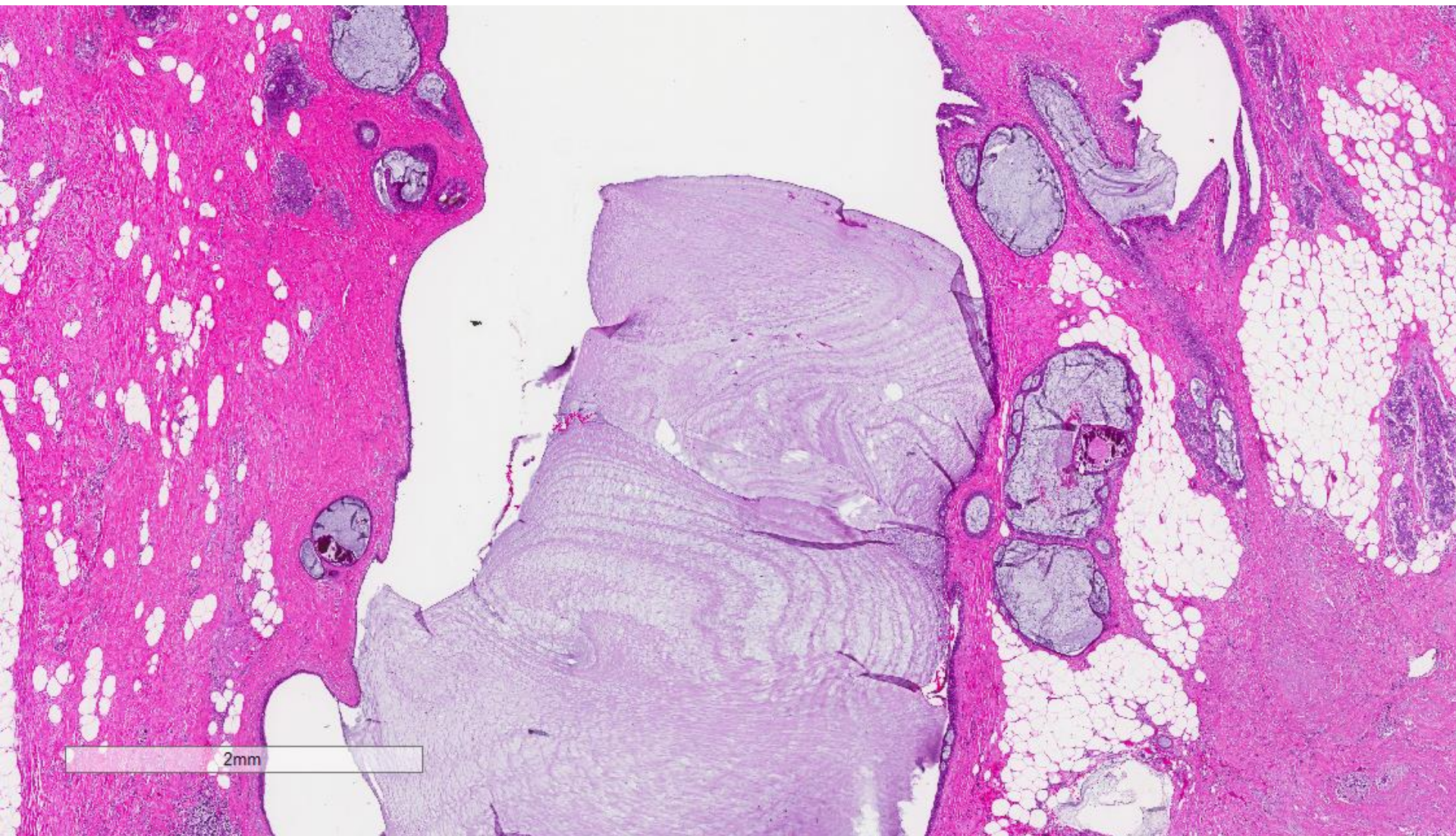


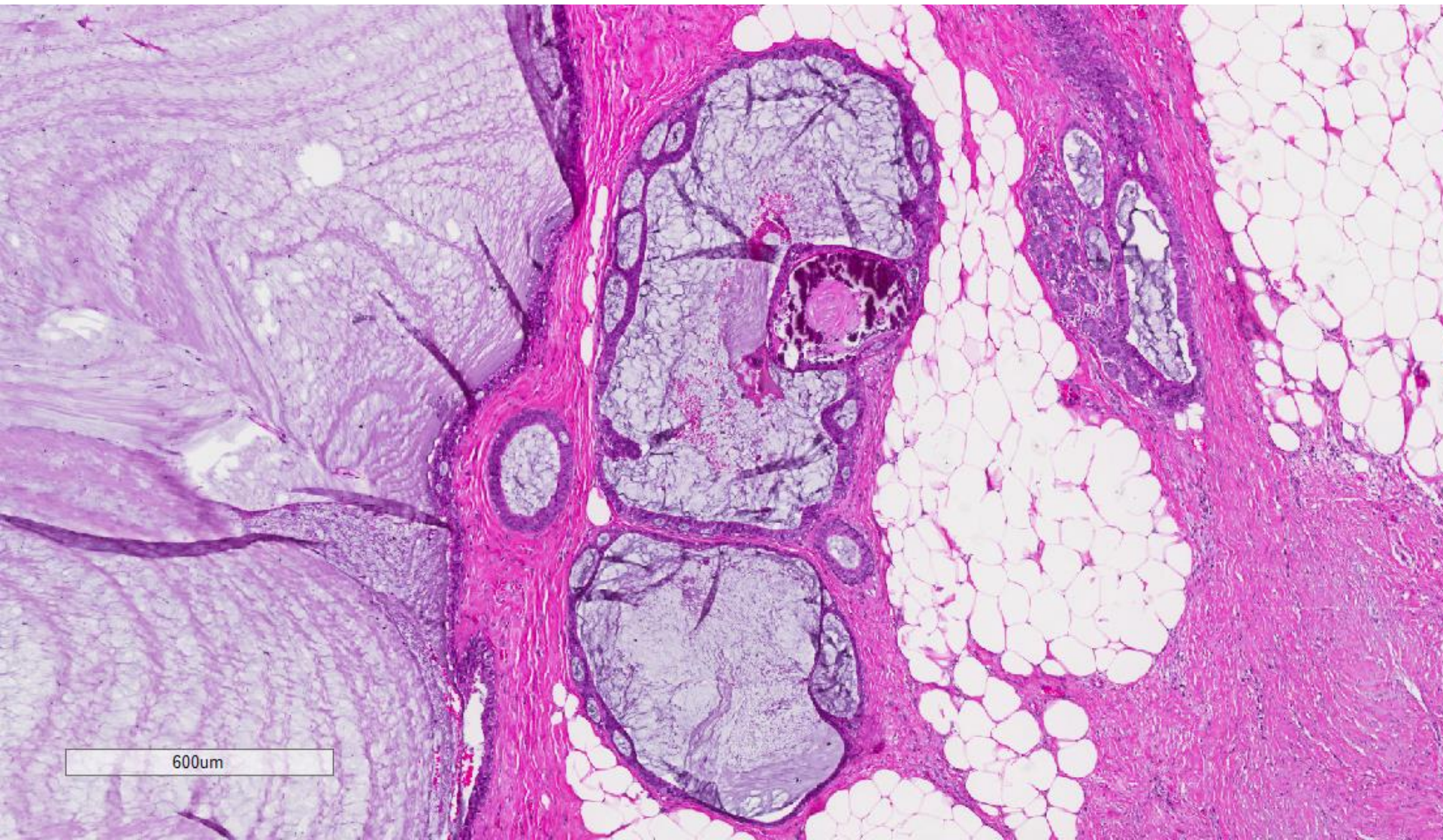
Case 13

42 year old lady underwent excision of
screen detected calcifications.

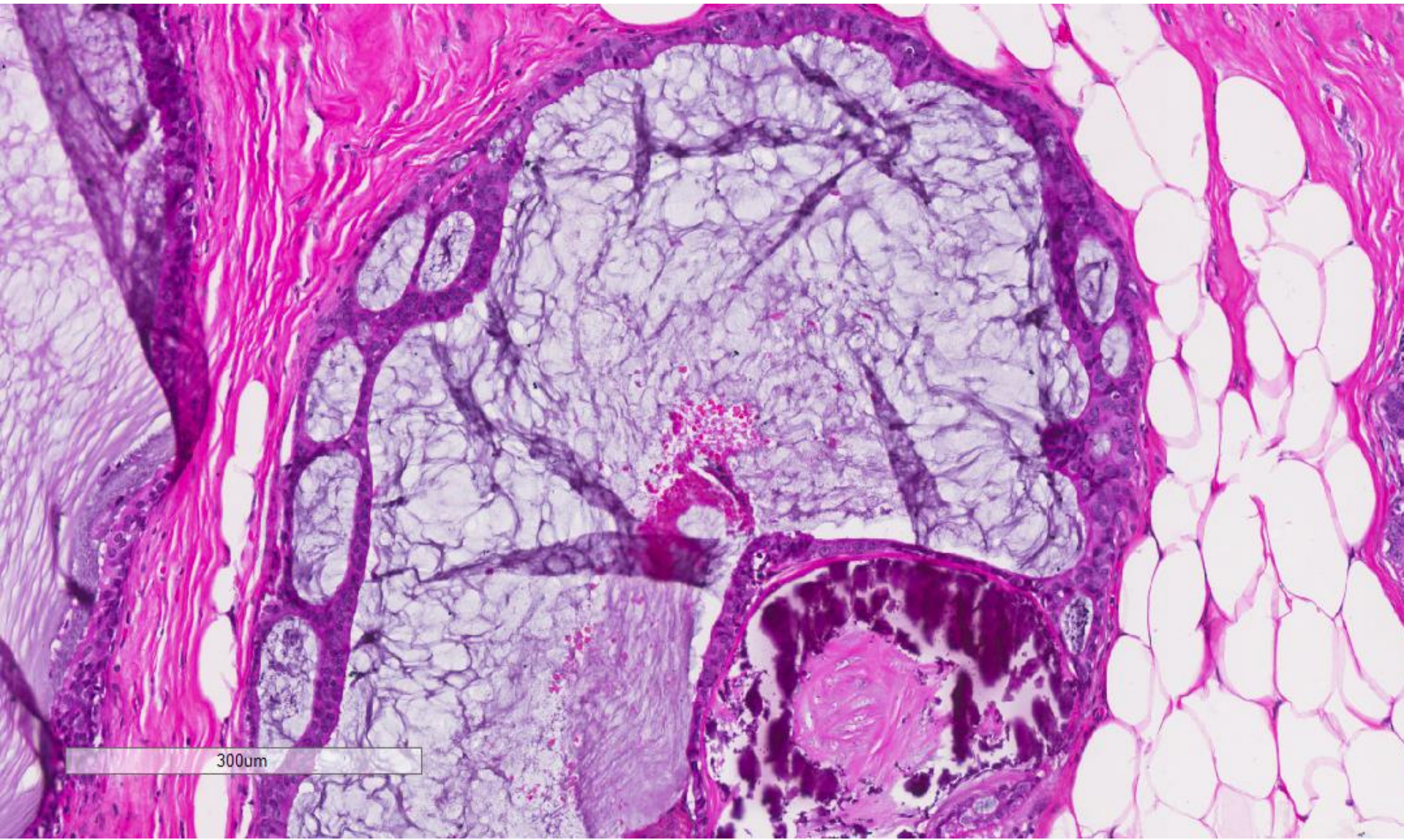



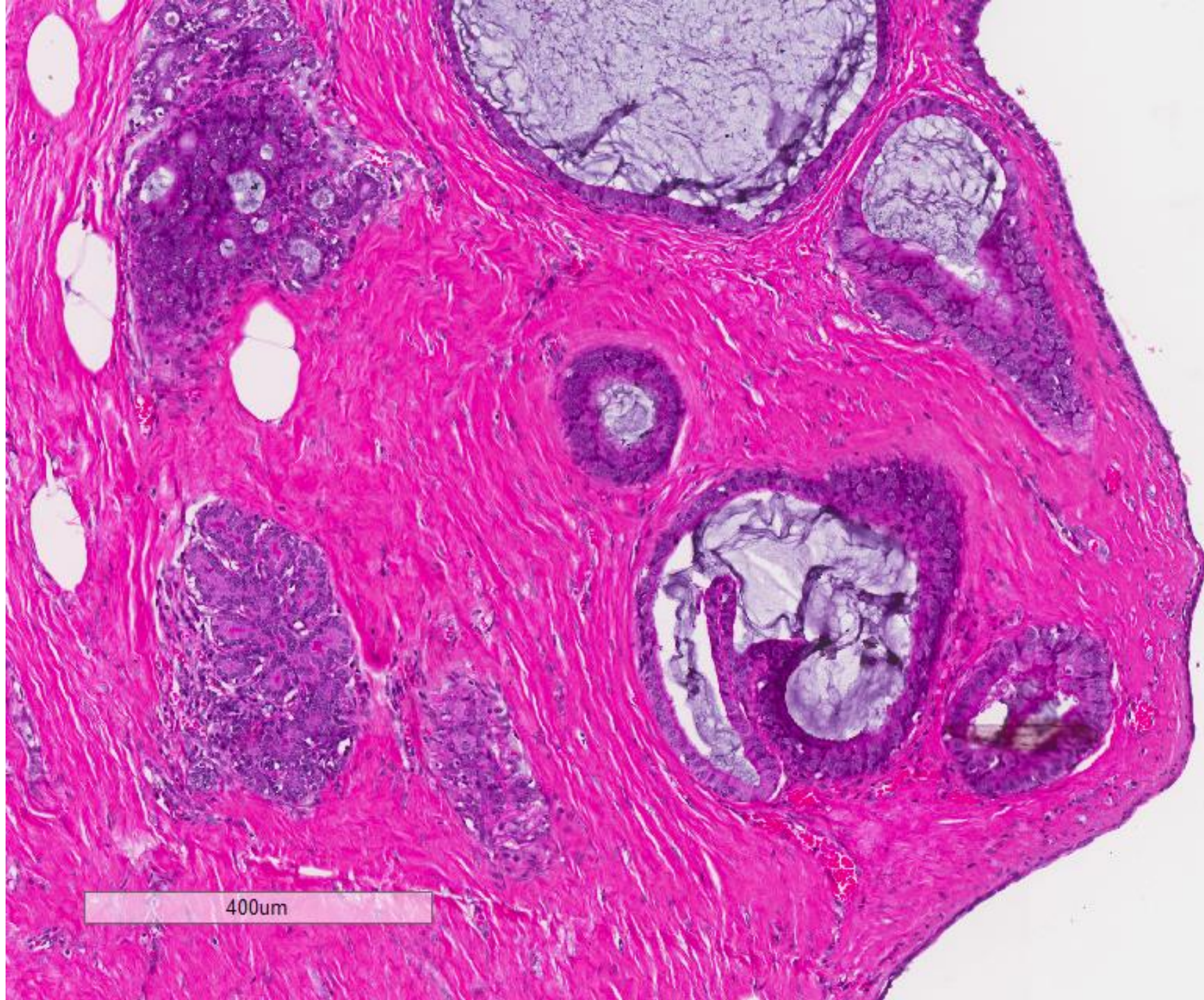
2mm



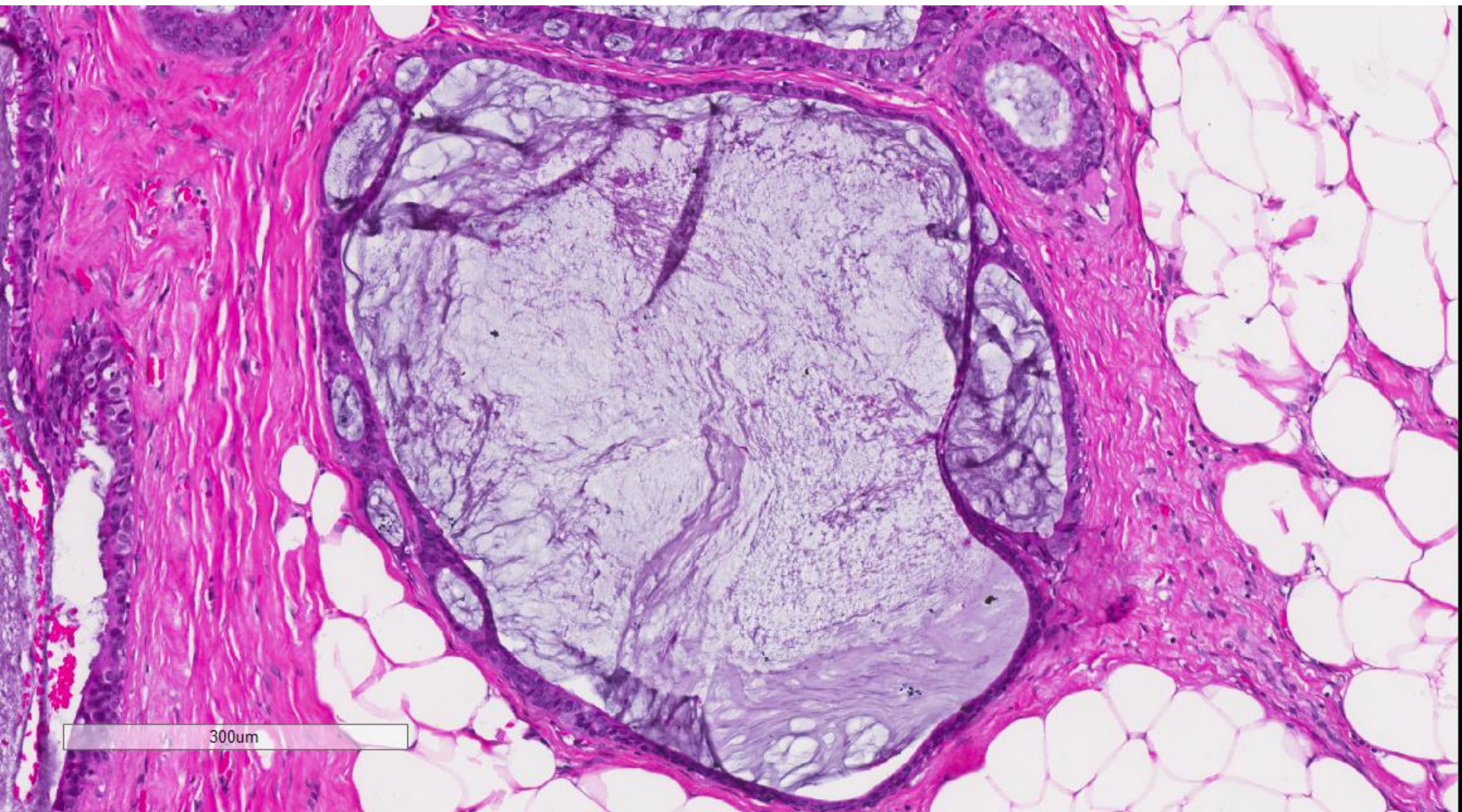
600um



300um



400um



Small focus (6 mm) of low nuclear grade ductal carcinoma in situ associated with a mucocele-like lesion, ER positive, PR positive