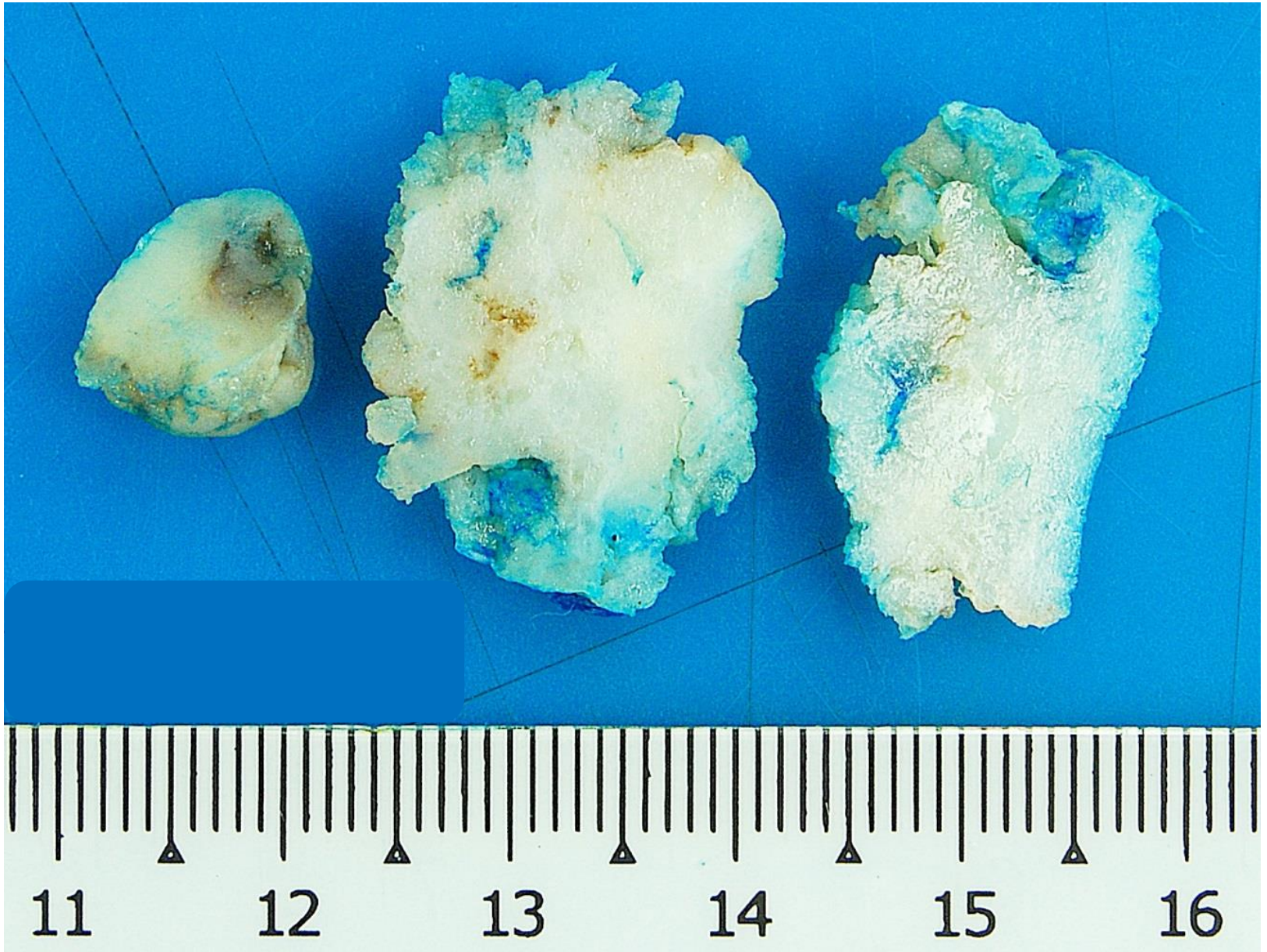
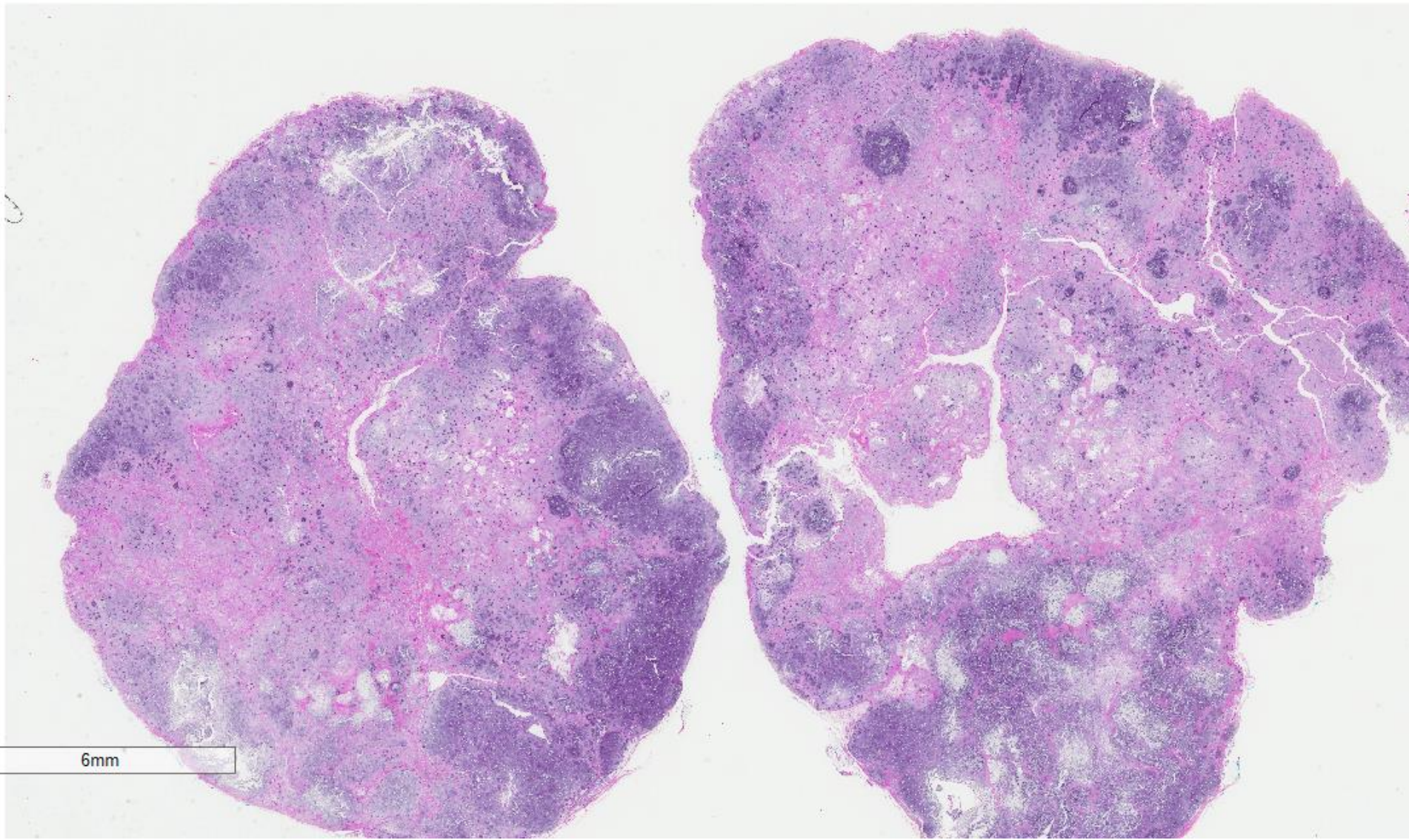


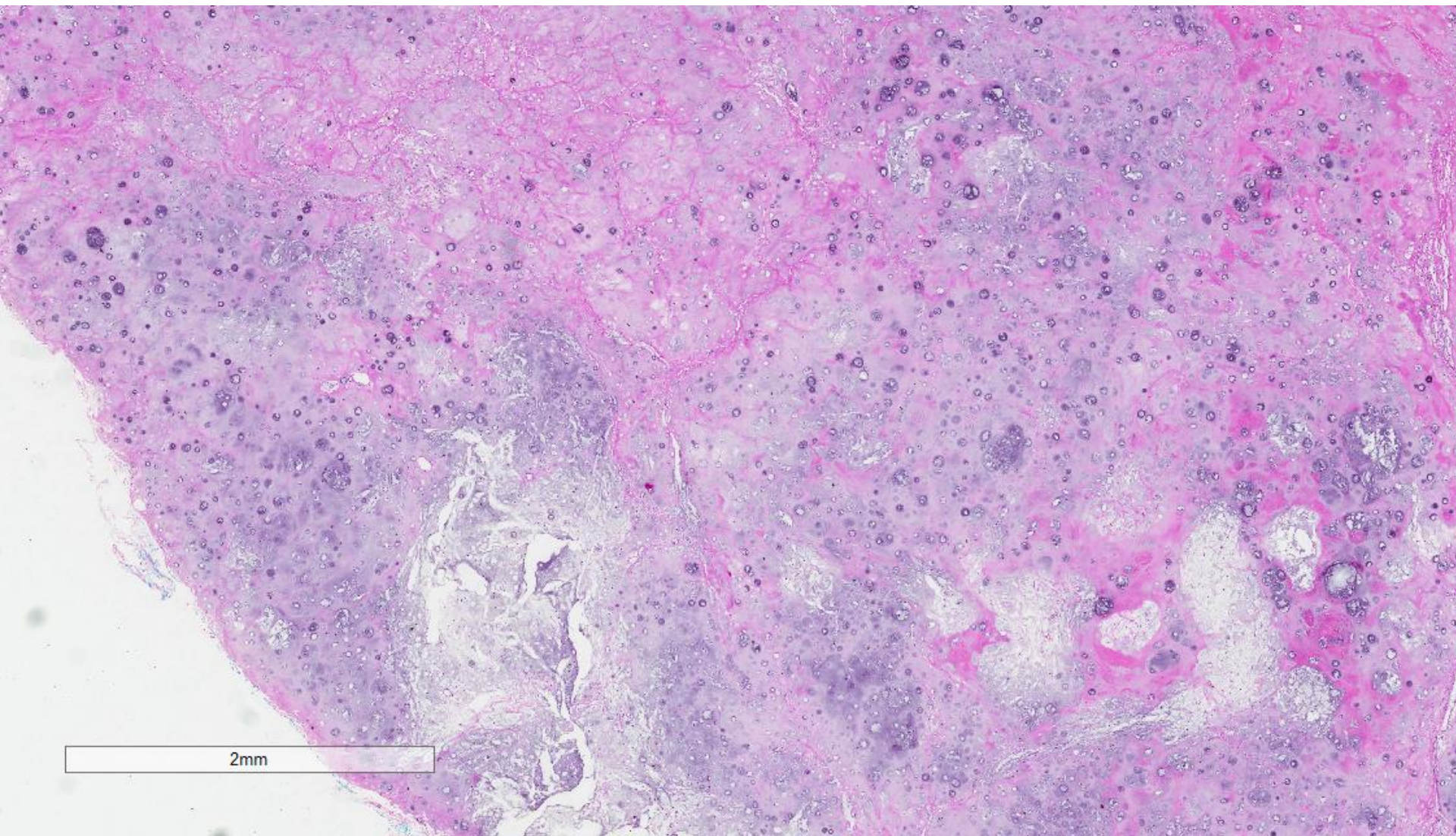
Case 11

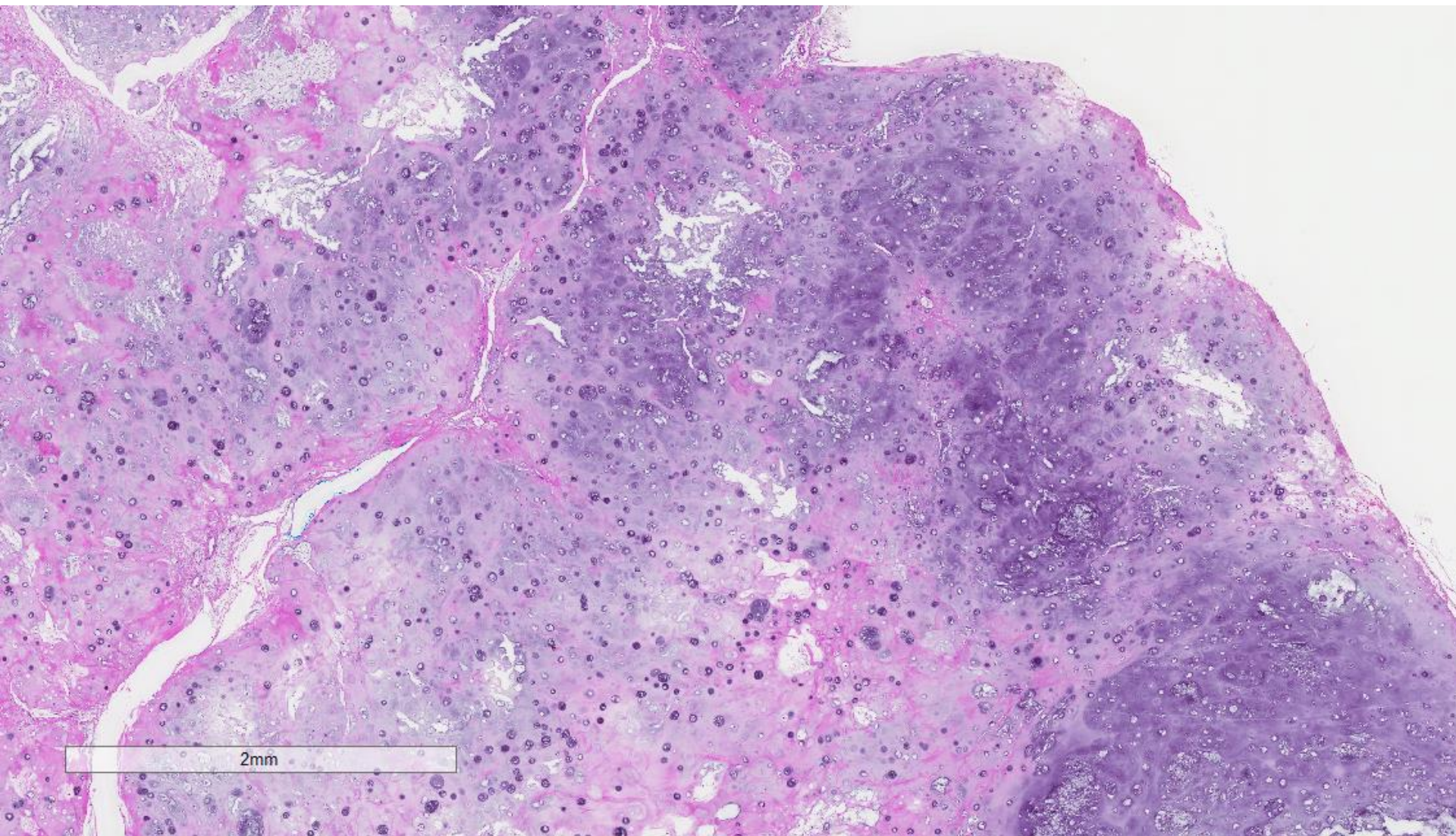
41 year old lady presented with a mass in the left breast. Excision biopsy was performed.

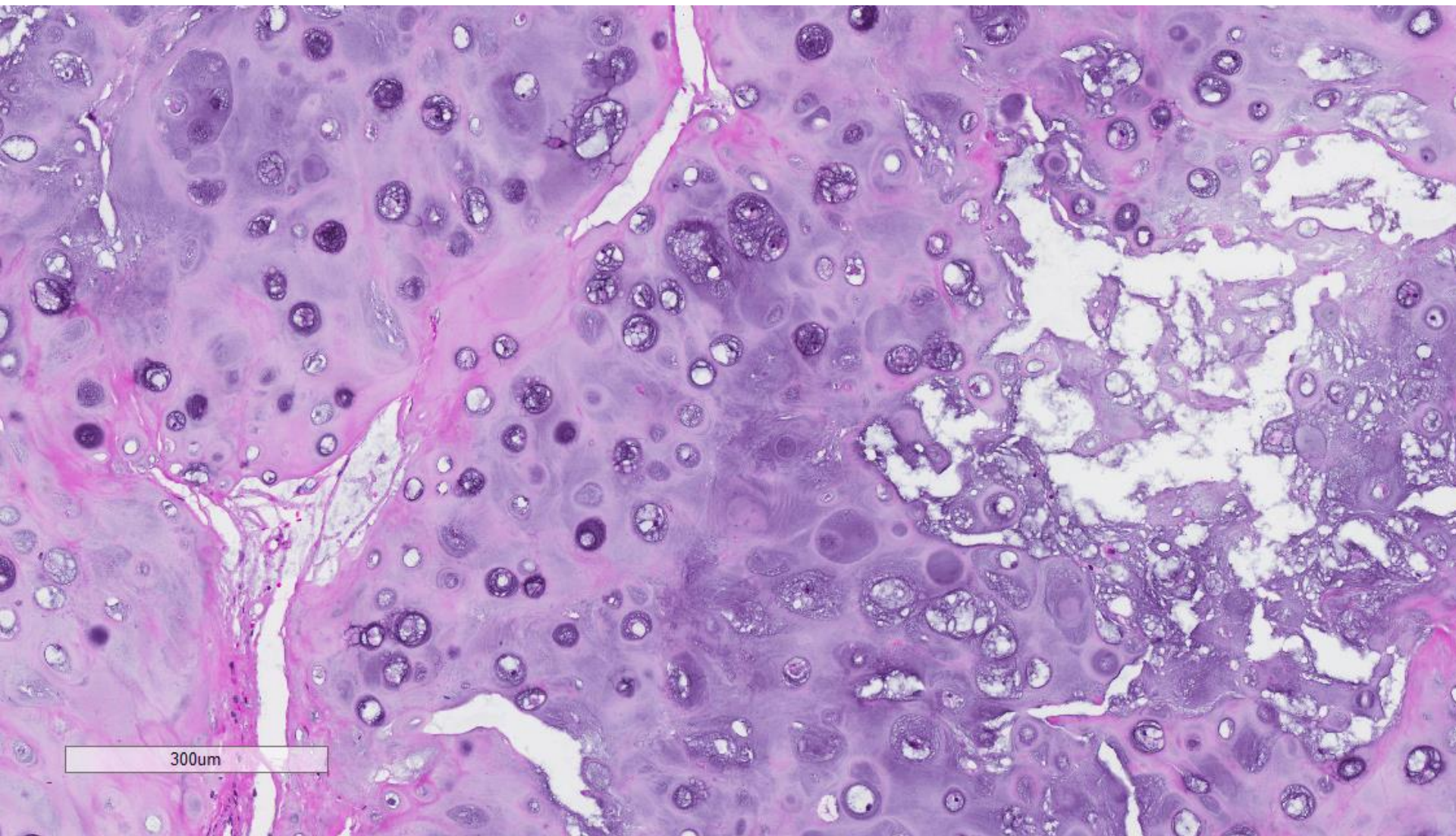




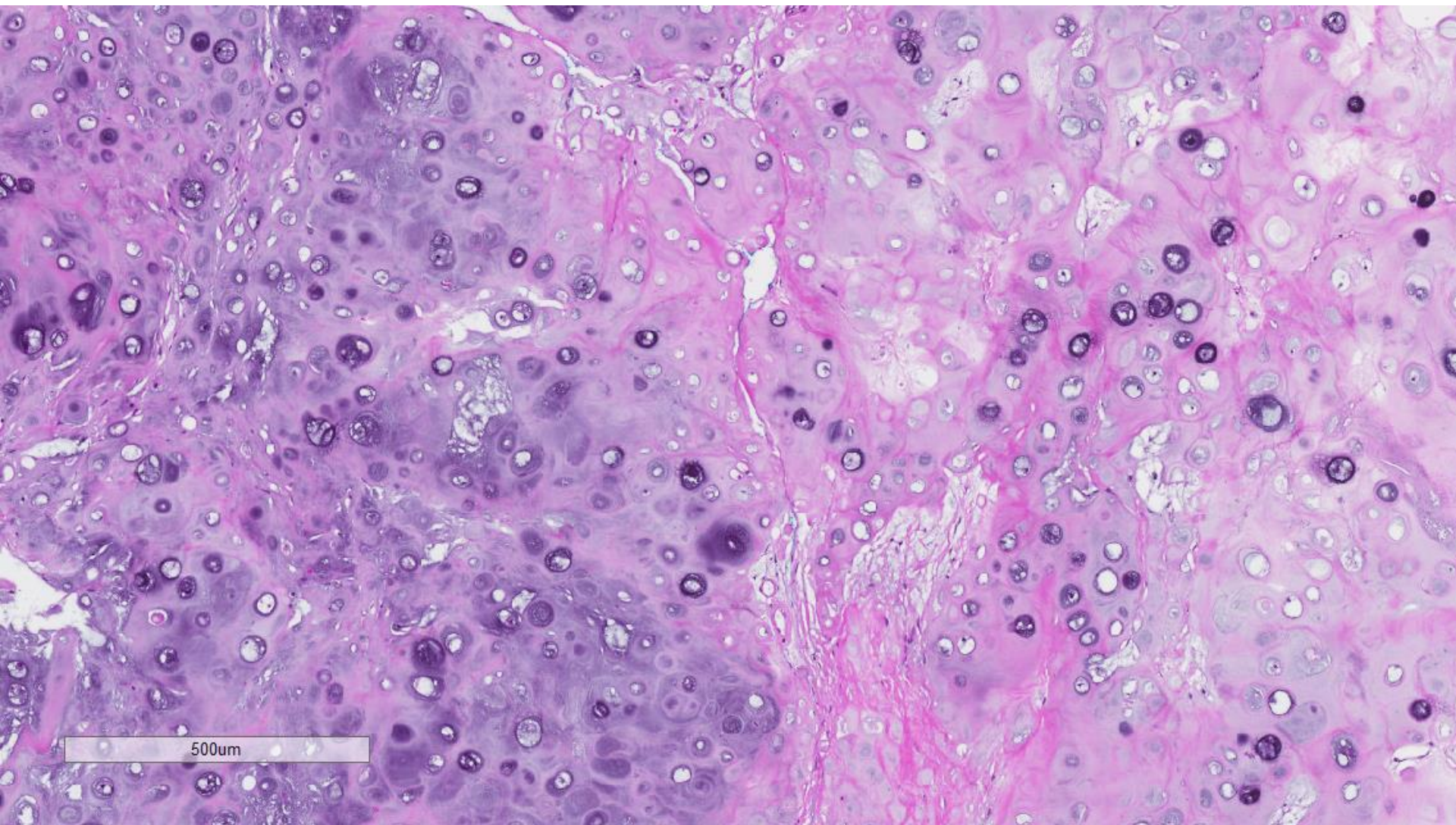
6mm







300um



Soft tissue chondroma

- Further discussion with the surgeon revealed that the lesion was close to the skeletal muscle of the chest wall, in between the ribs.
- The mass was not located within the breast parenchyma intraoperatively.