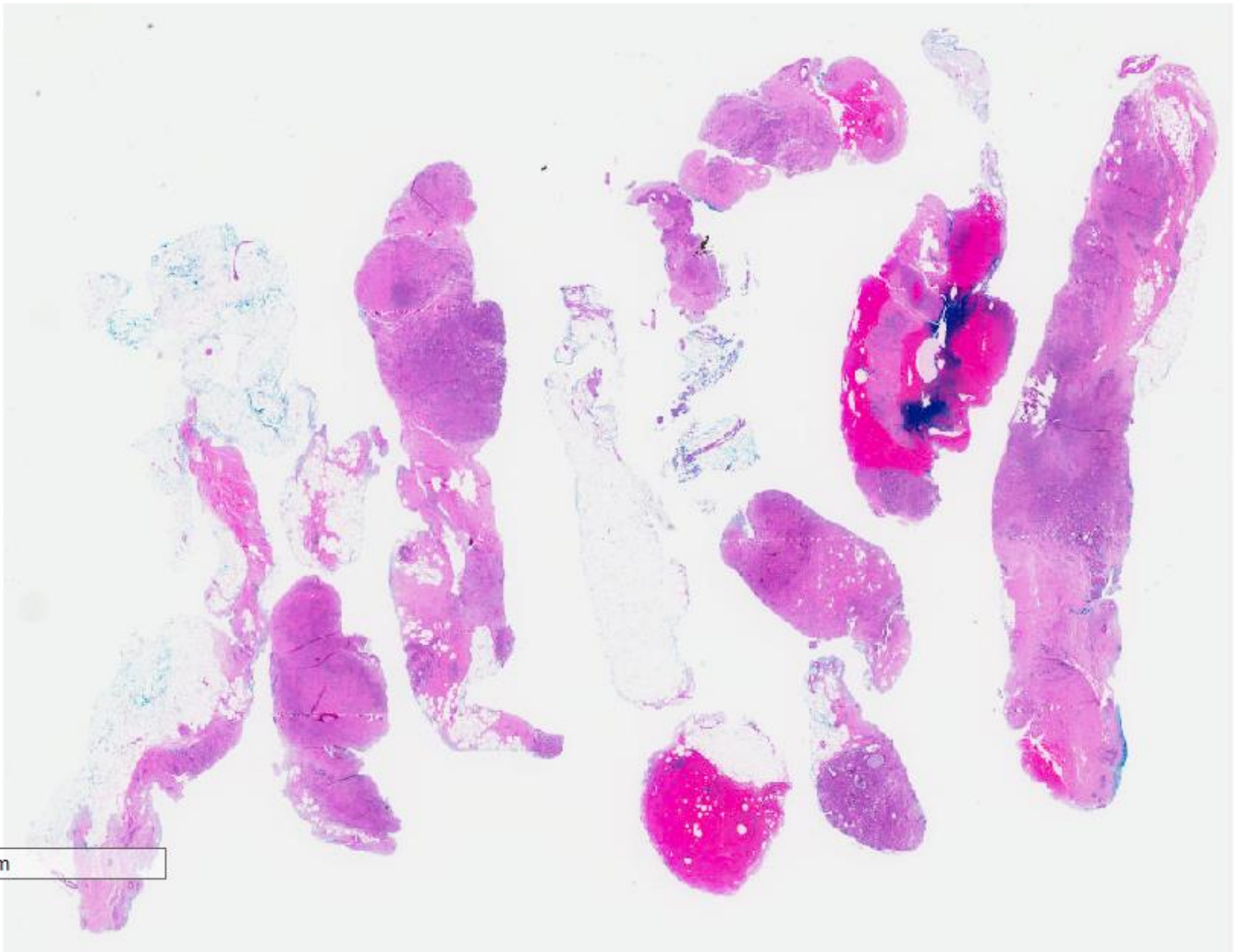


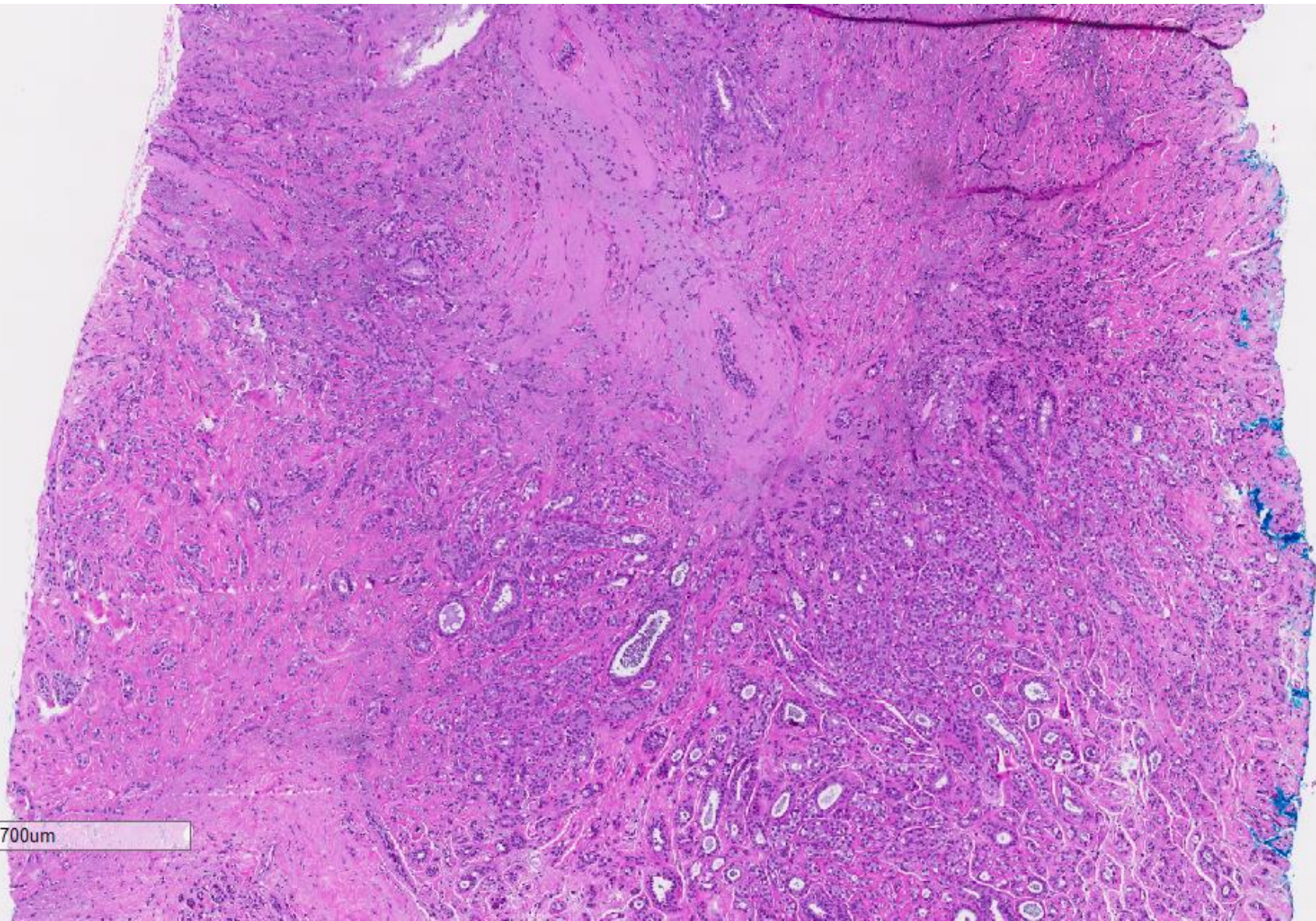
Case 6

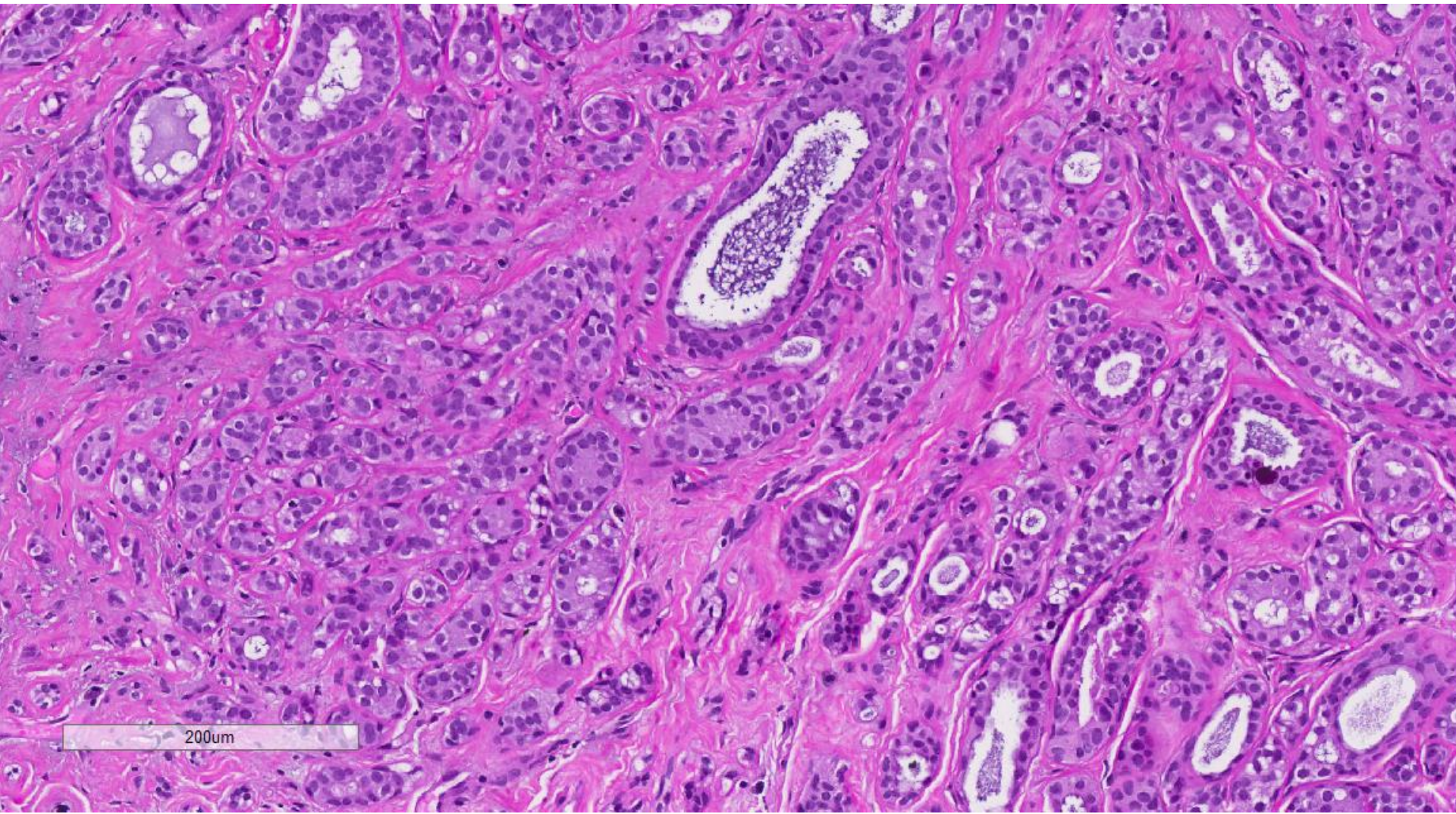
55 year old lady underwent core biopsy of a screen detected nodule in the right breast.



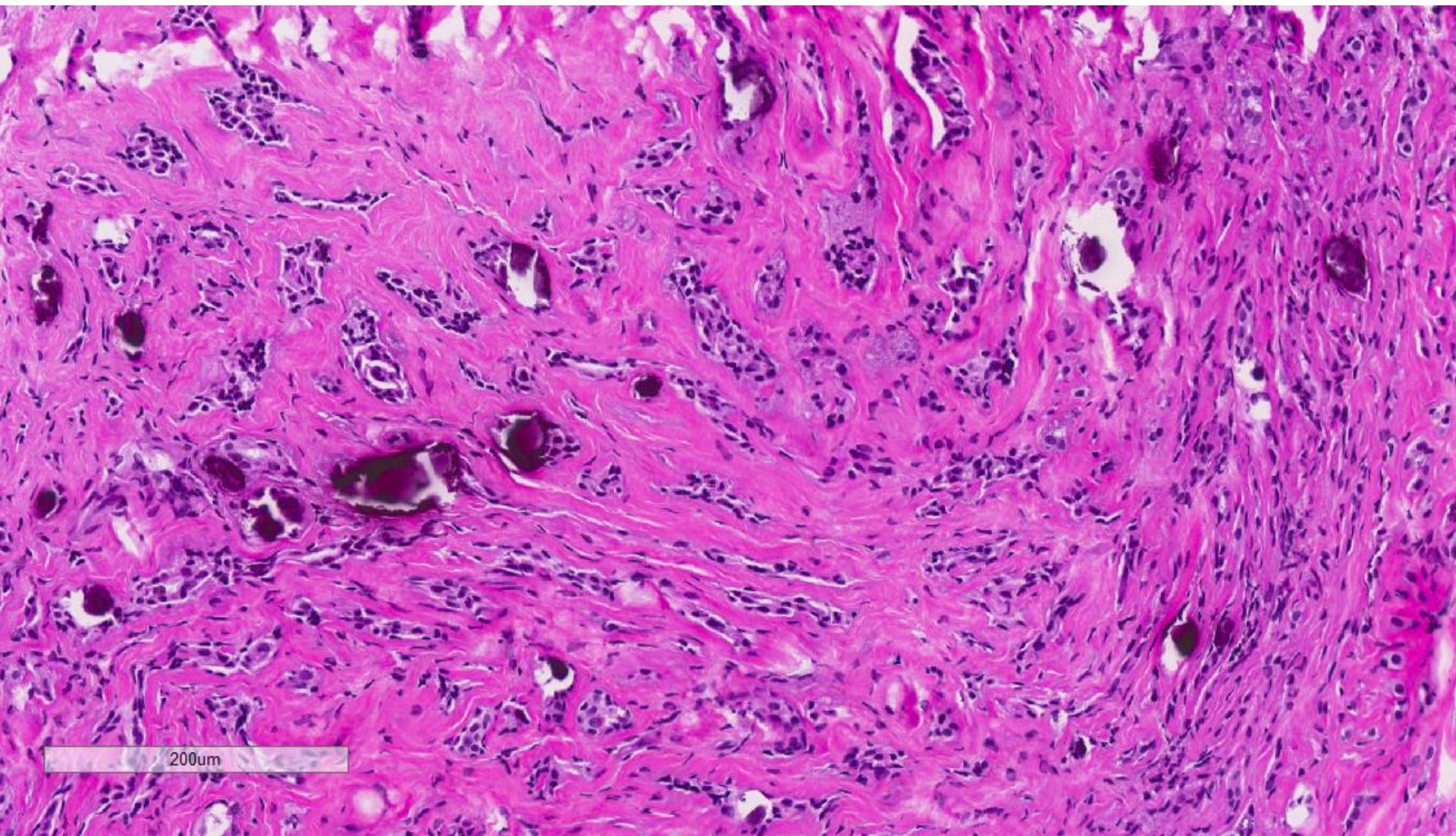
7mm

700um

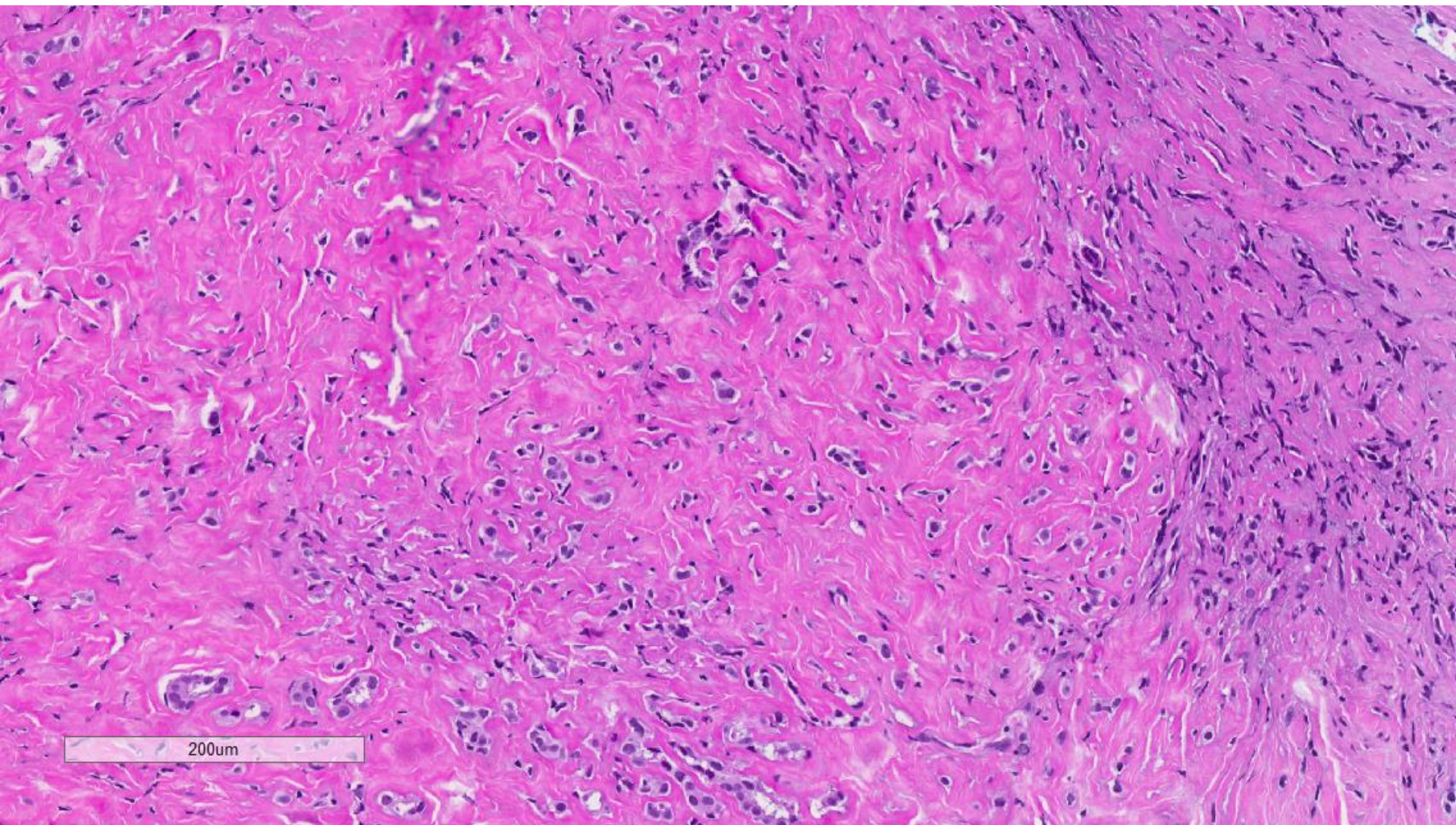


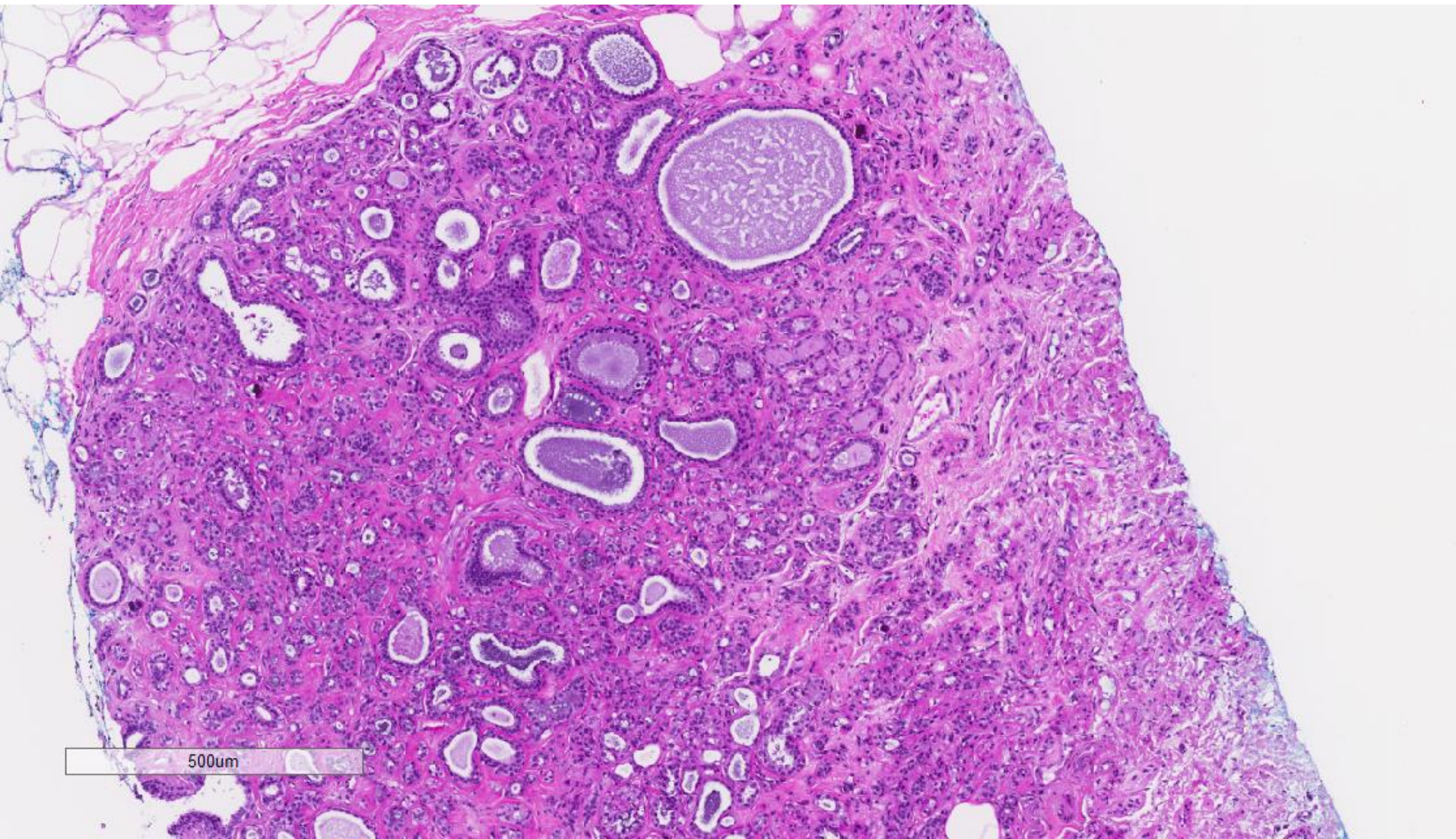


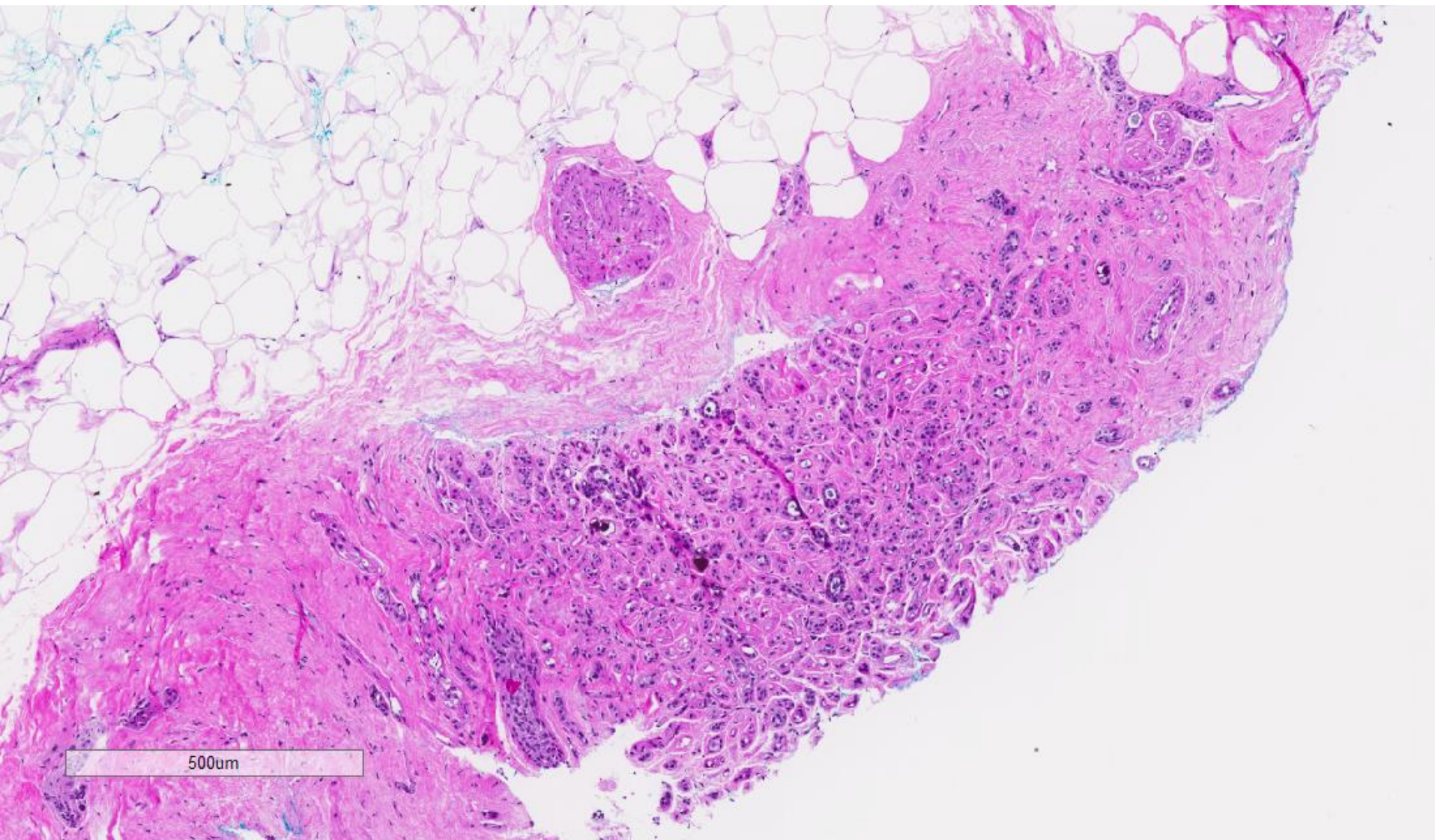
200um

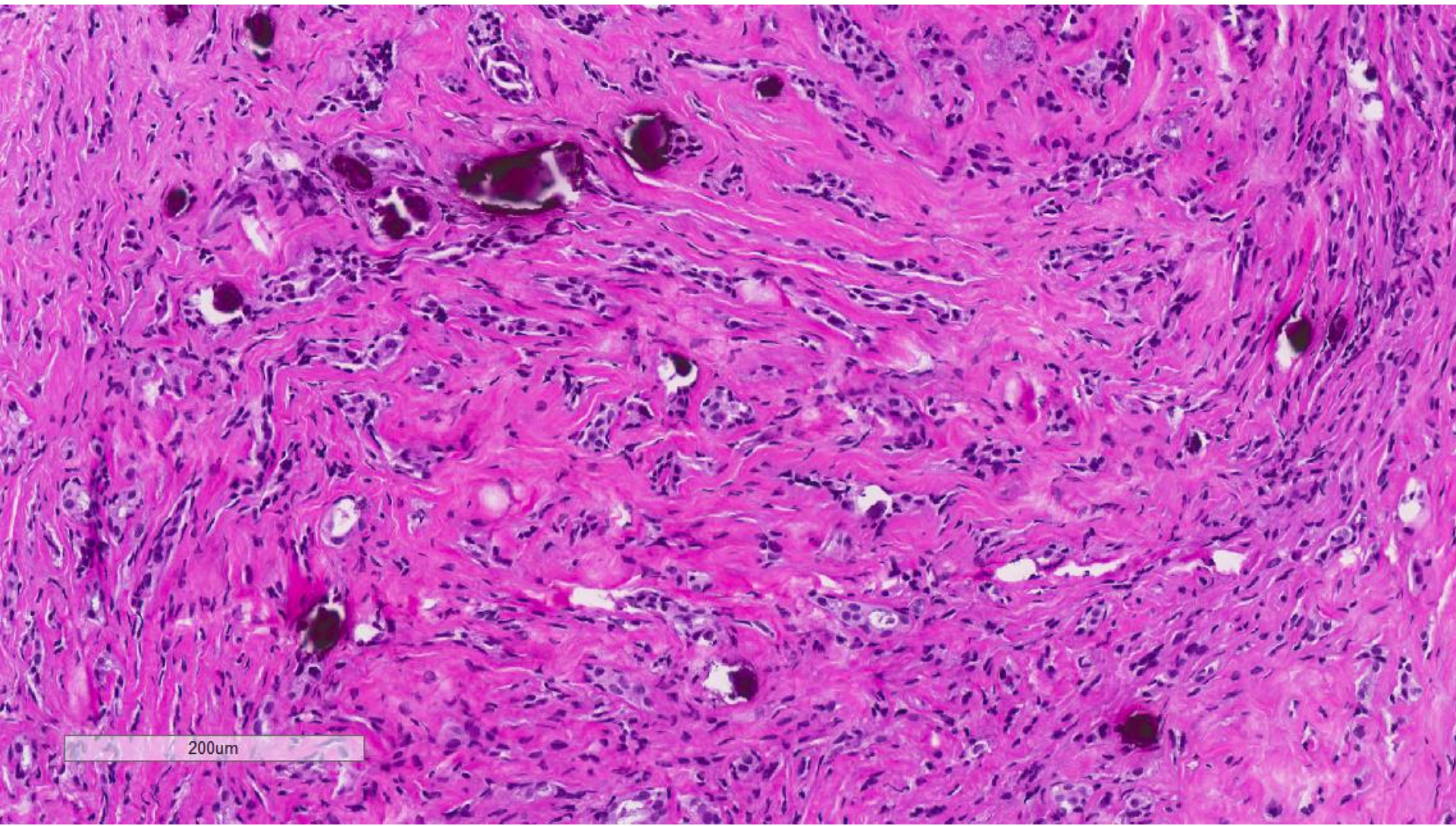


200um



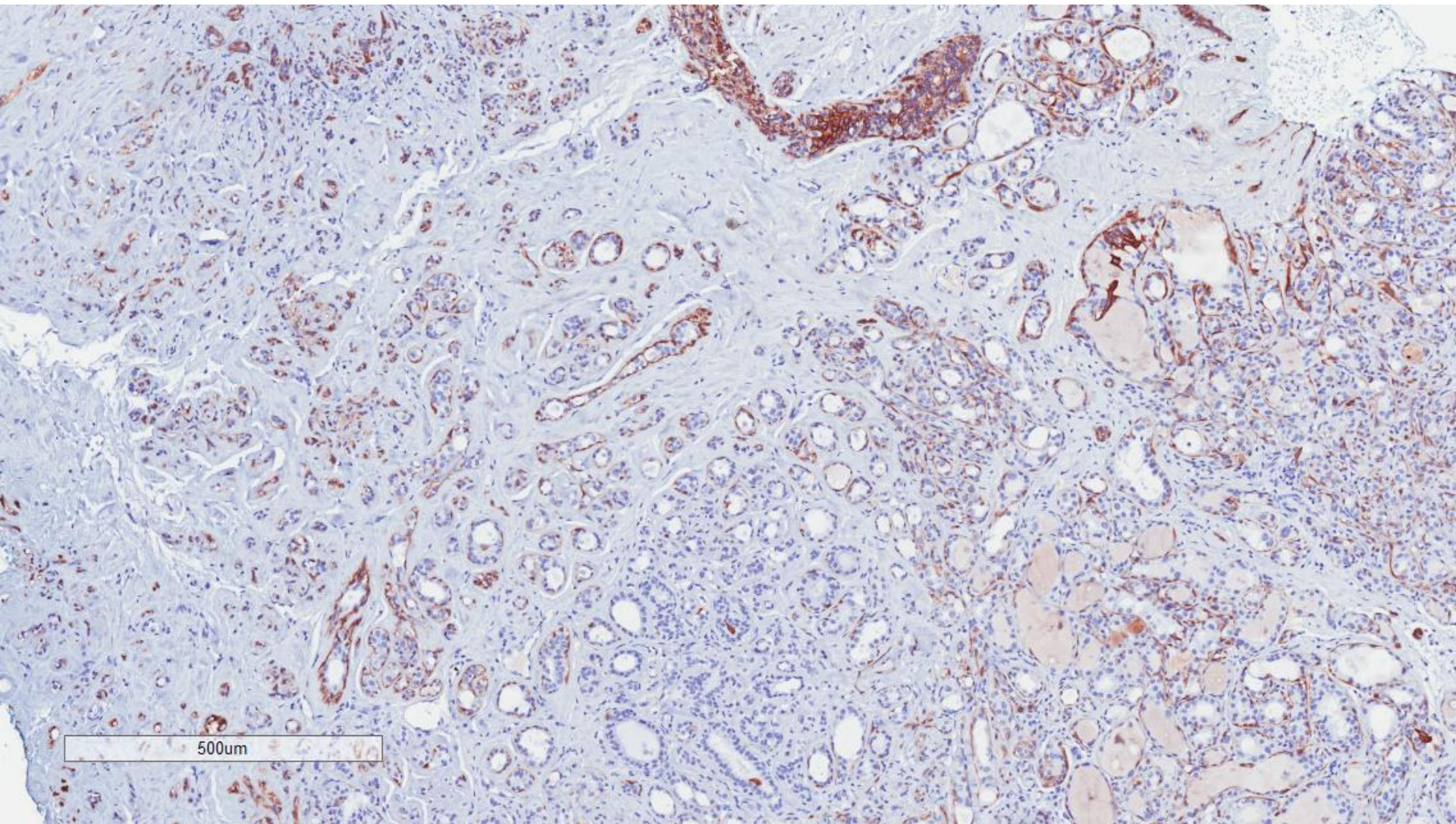




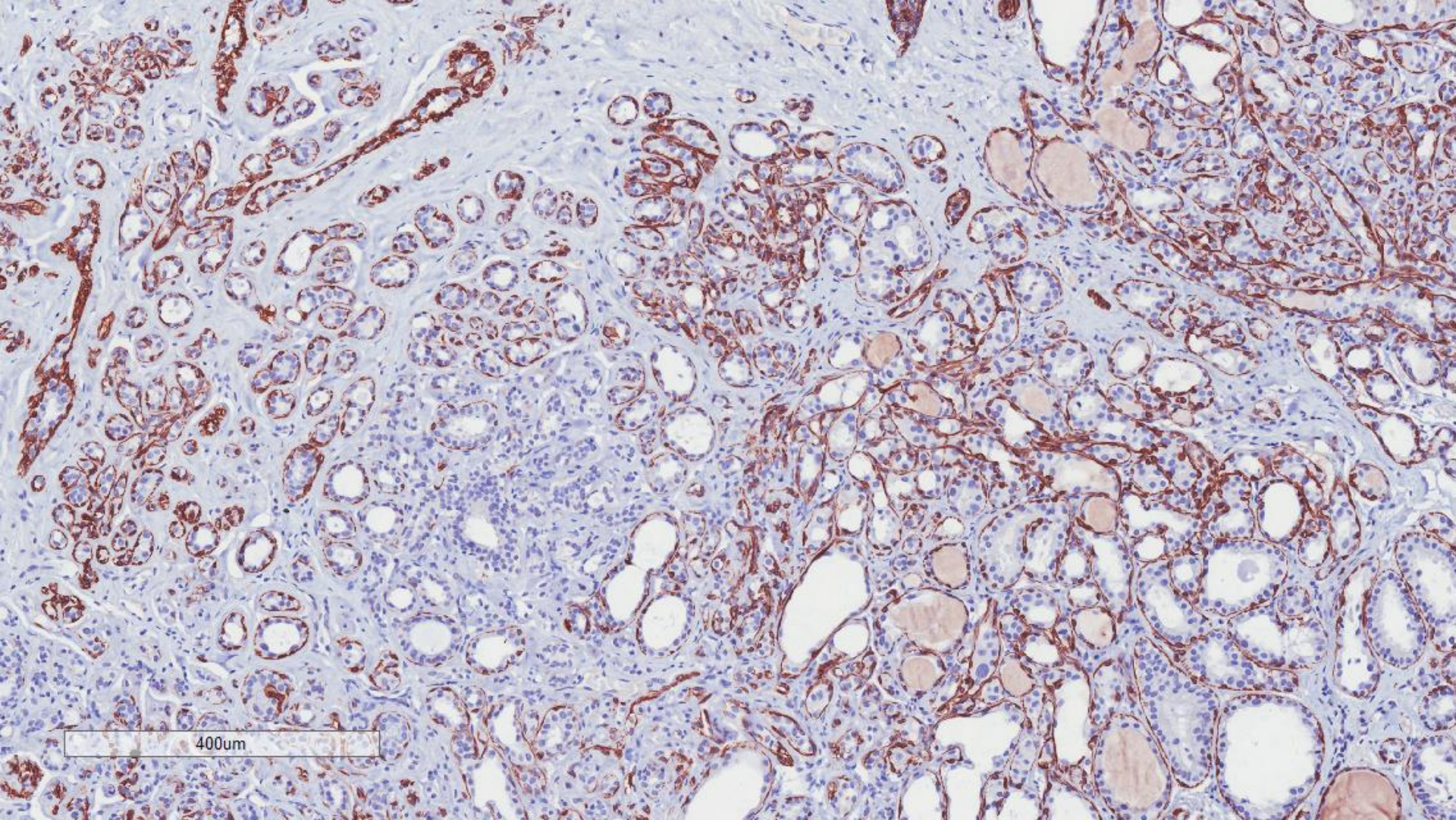


200um

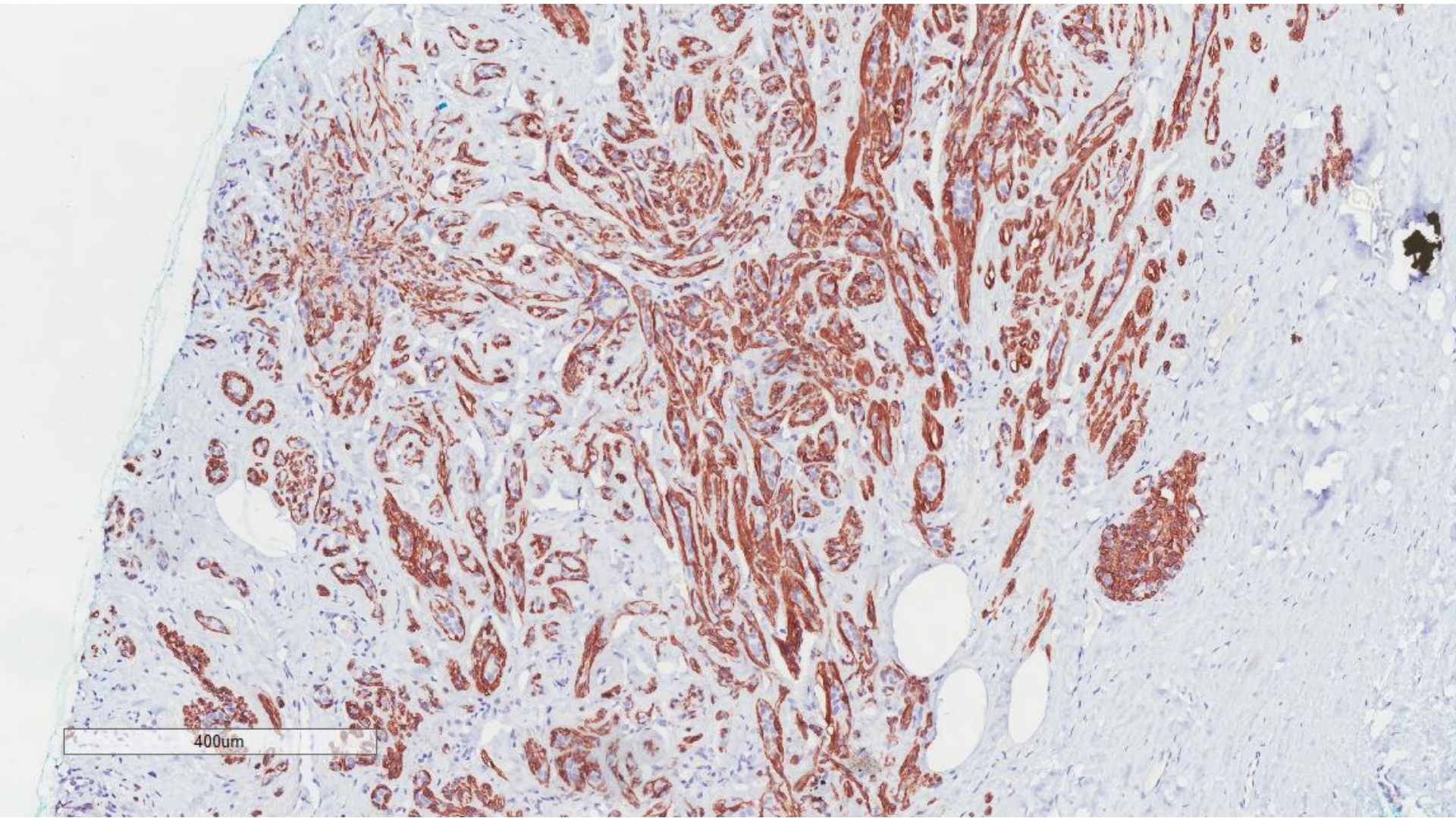
CK5/6



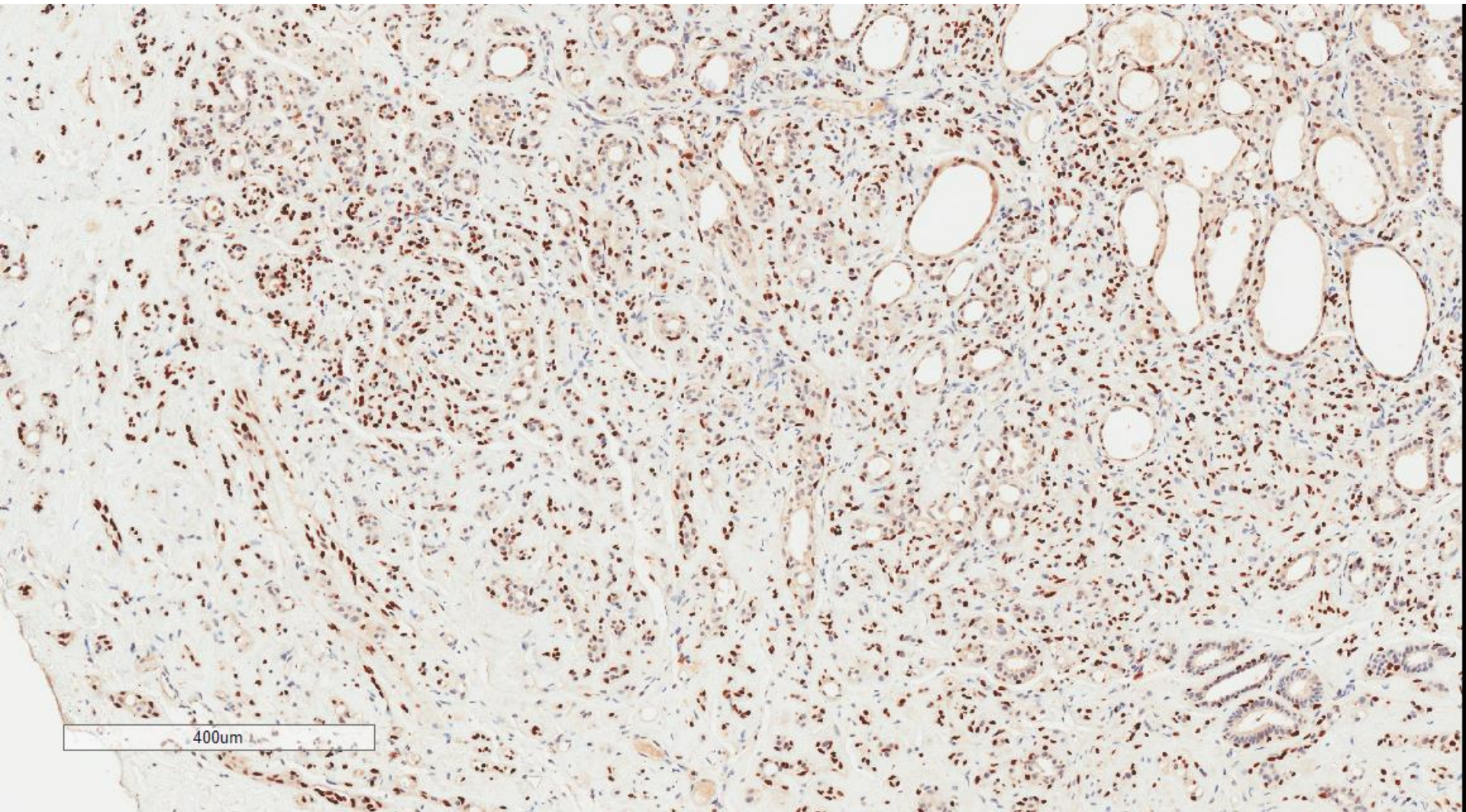
CK14



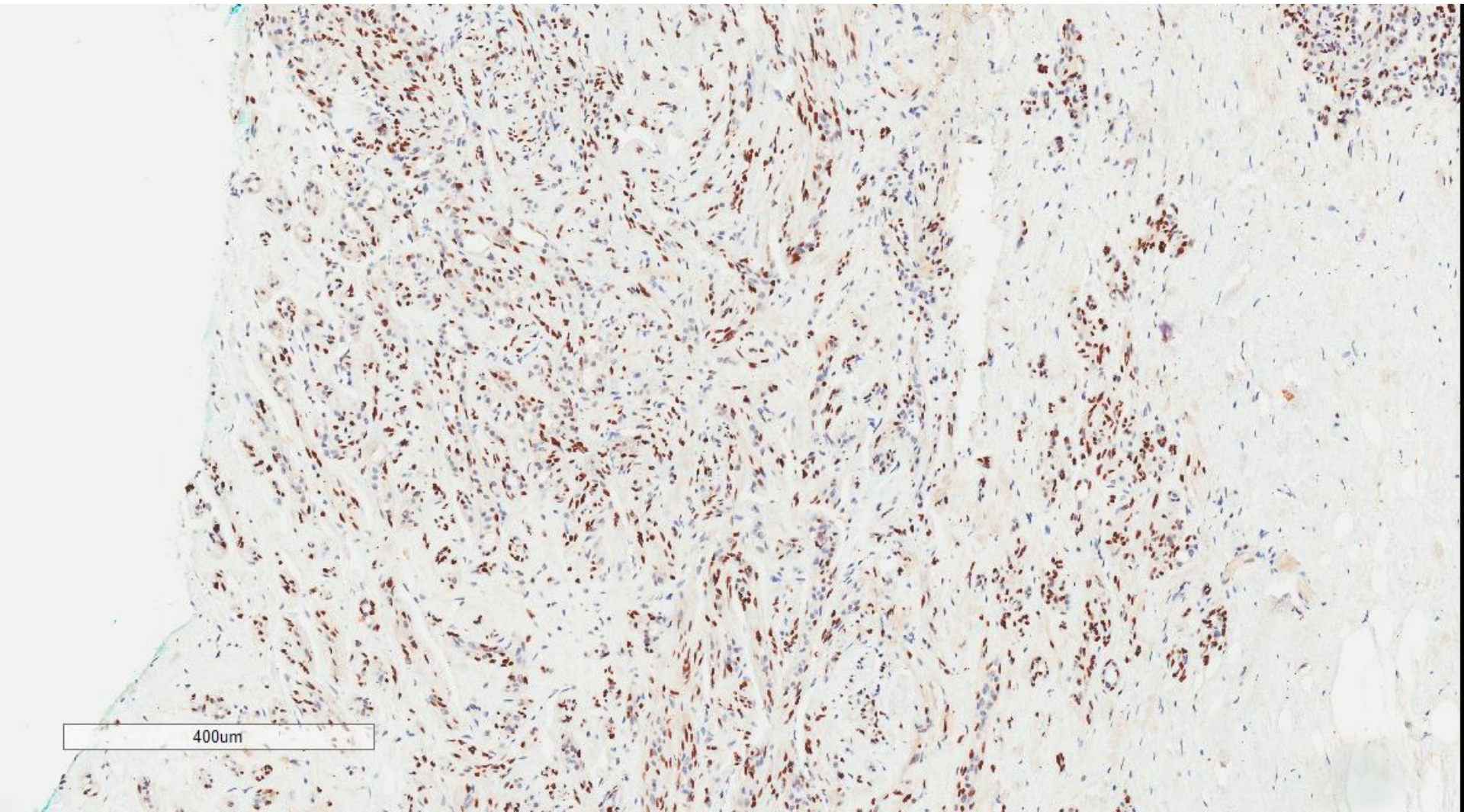
CK14



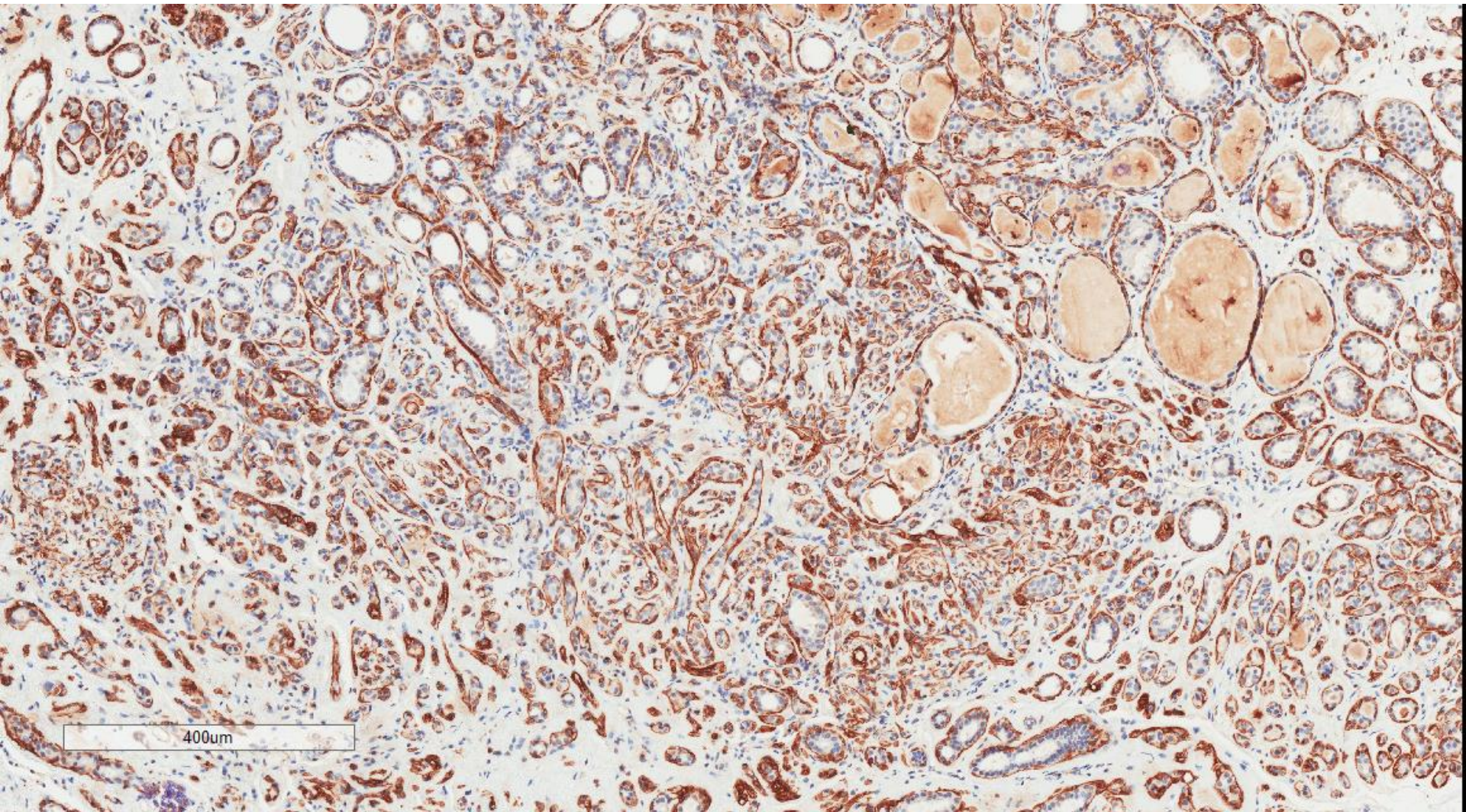
p63



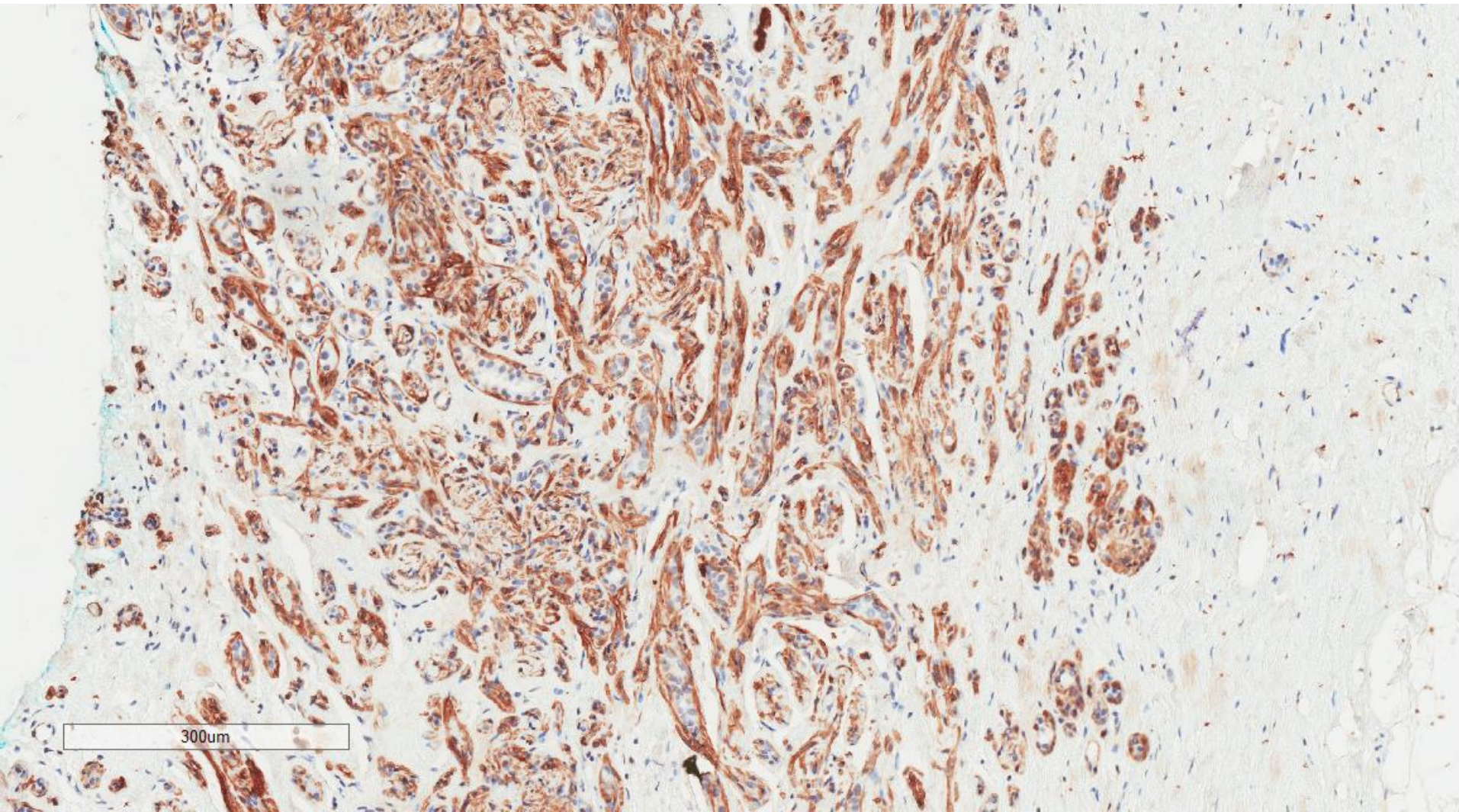
p63



SMMHC



SMMHC



Benign breast tissue with nodular sclerosing adenosis