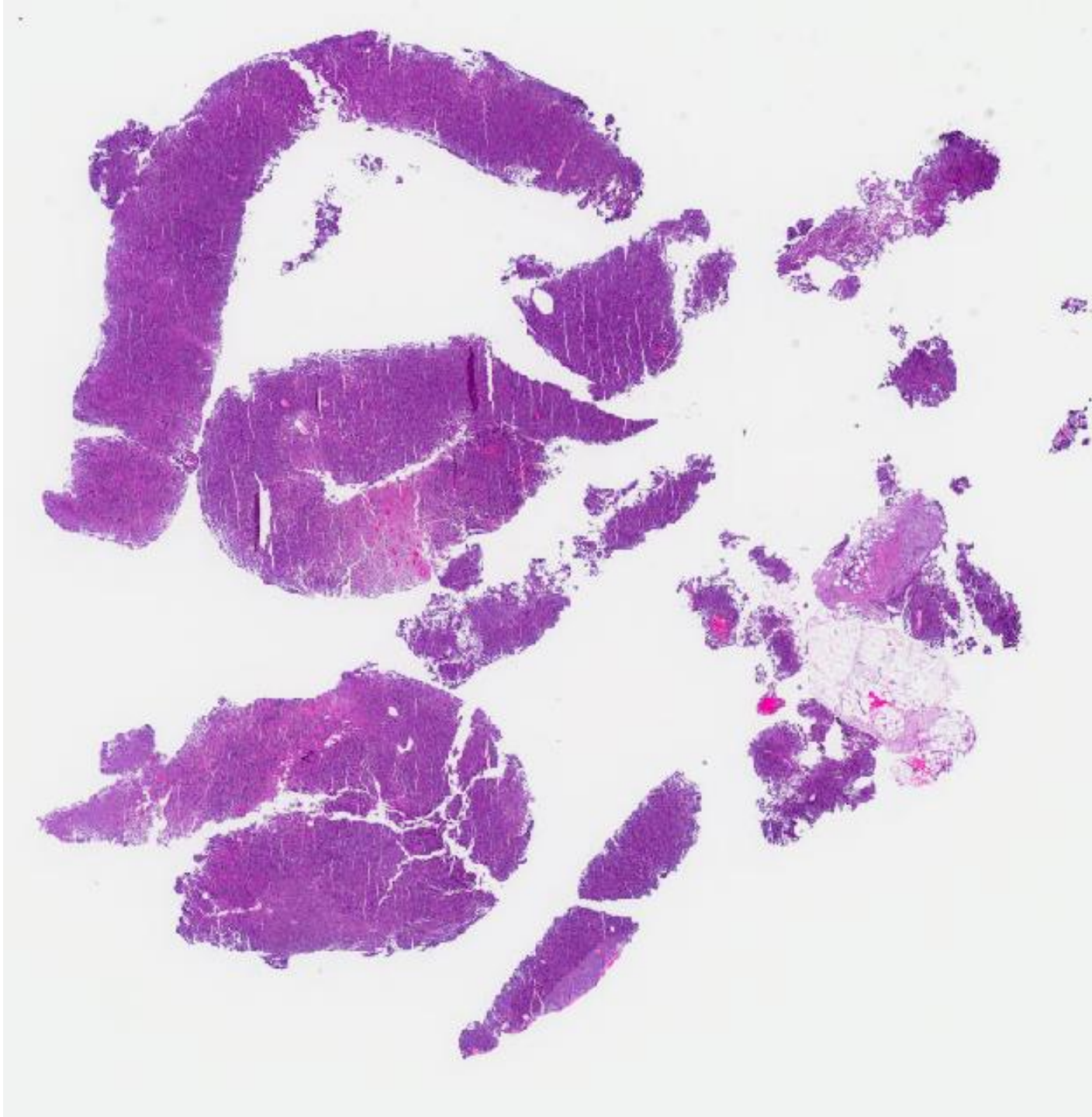
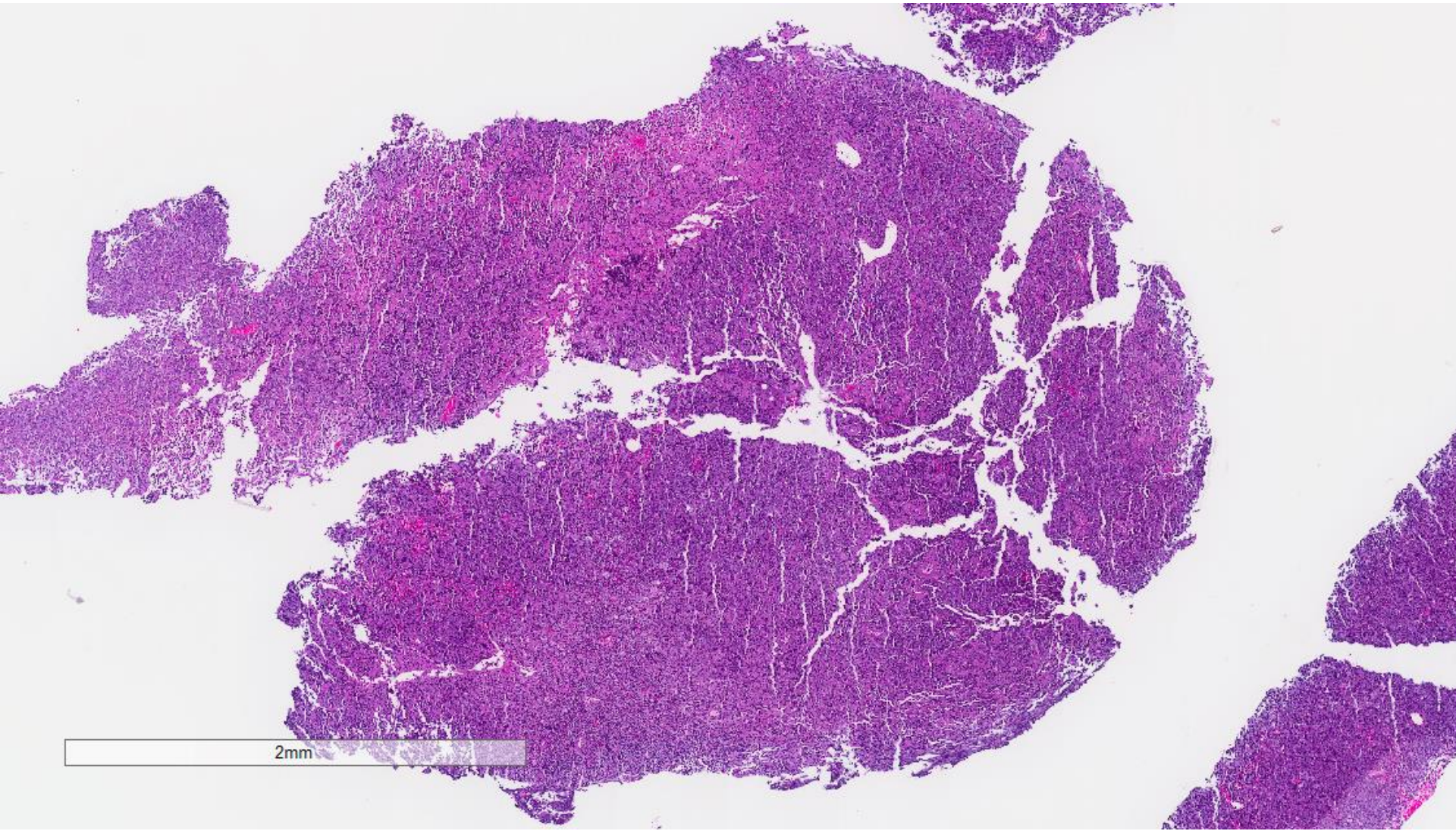


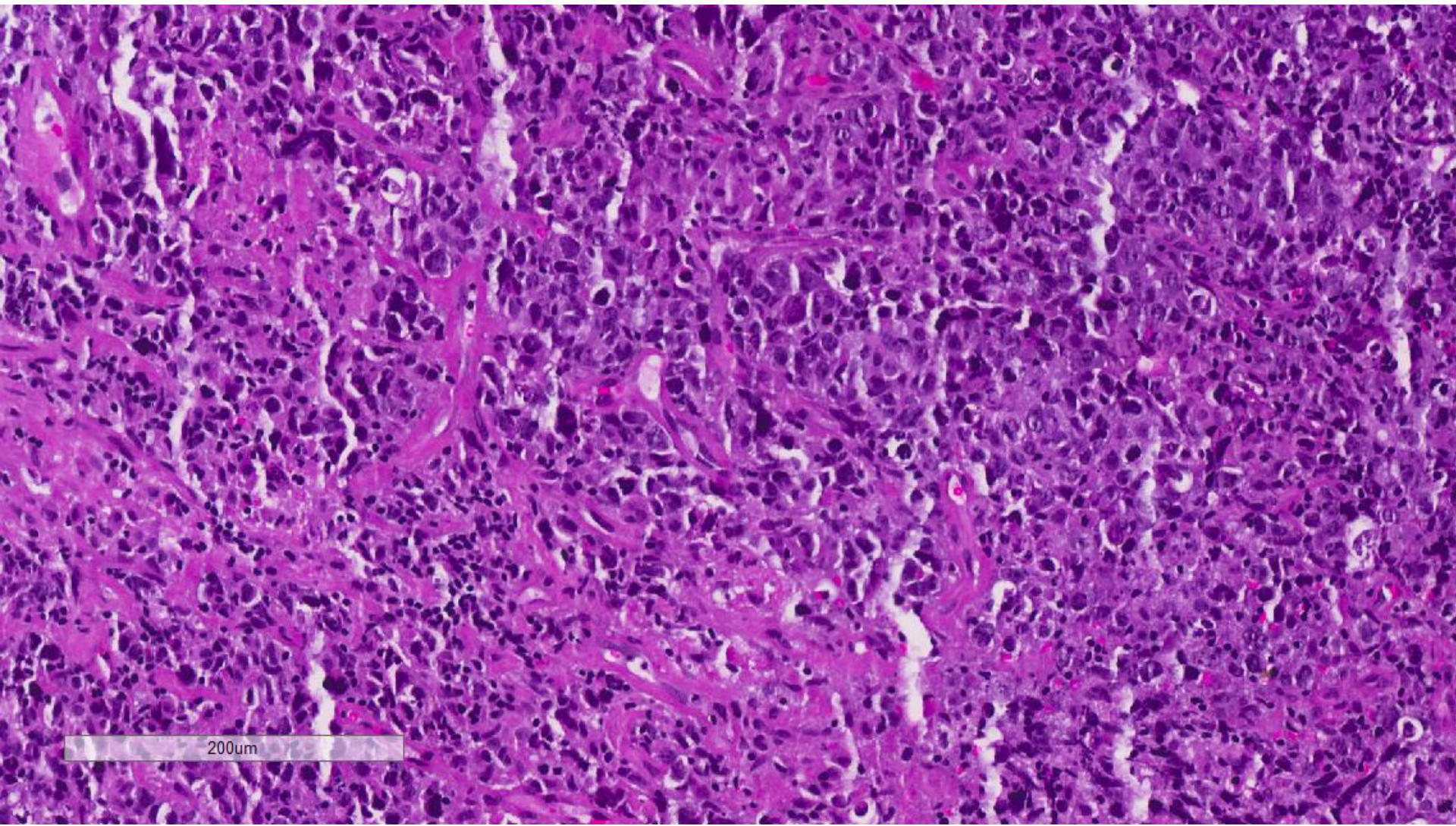
Case 2

54 year old lady underwent core biopsy of an enlarged axillary lymph node. No past medical history of note.

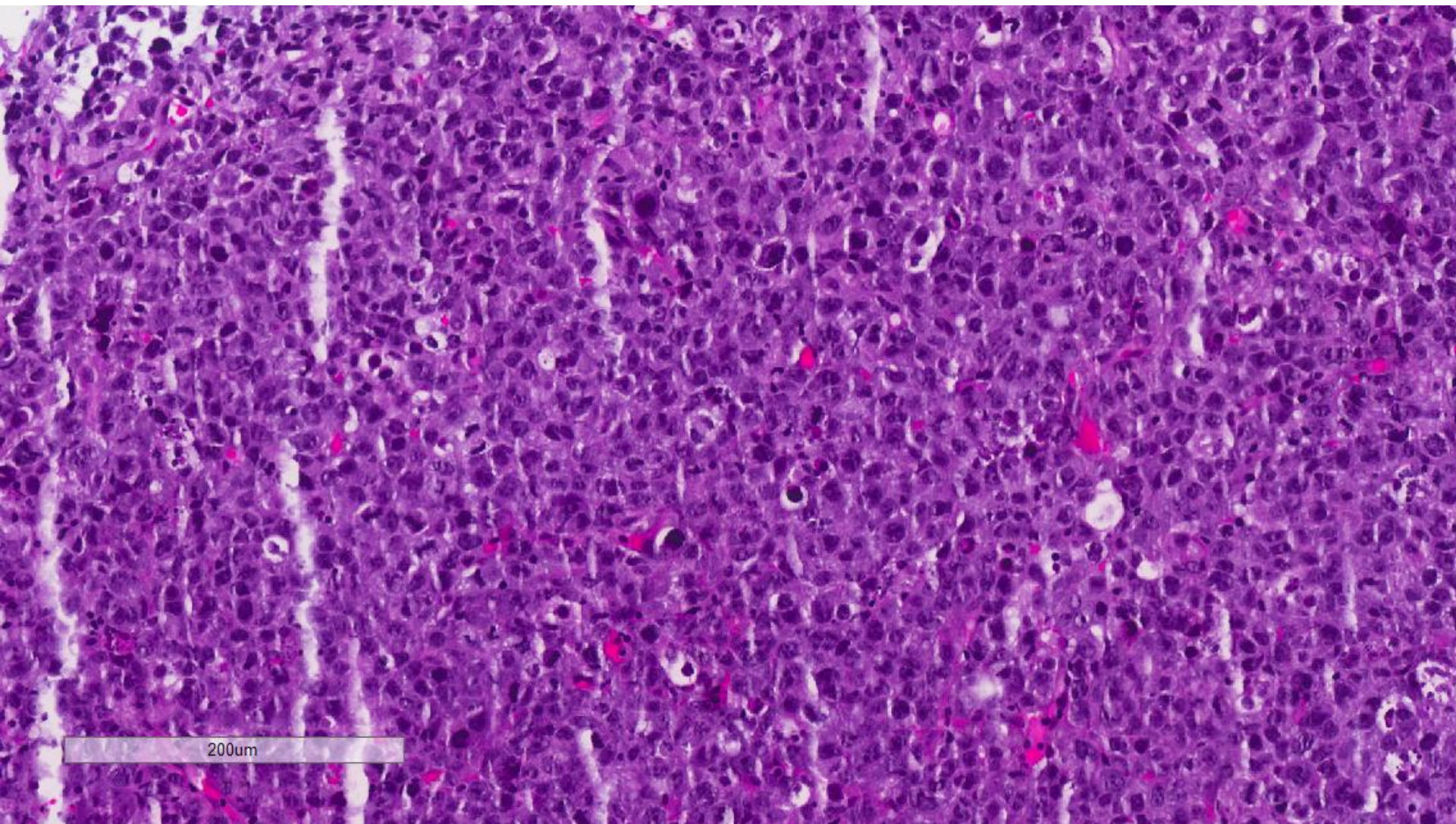




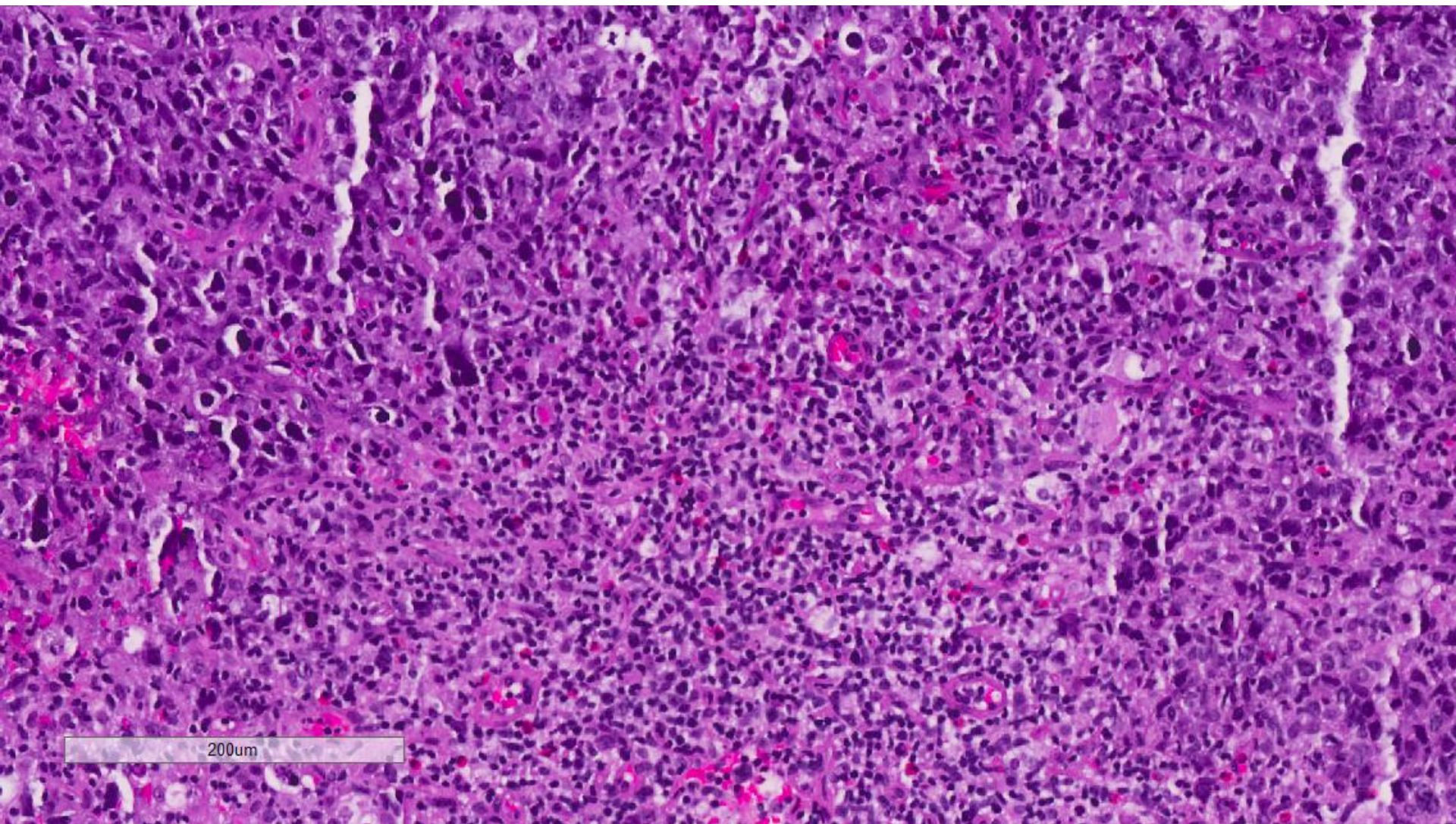
2mm



200um

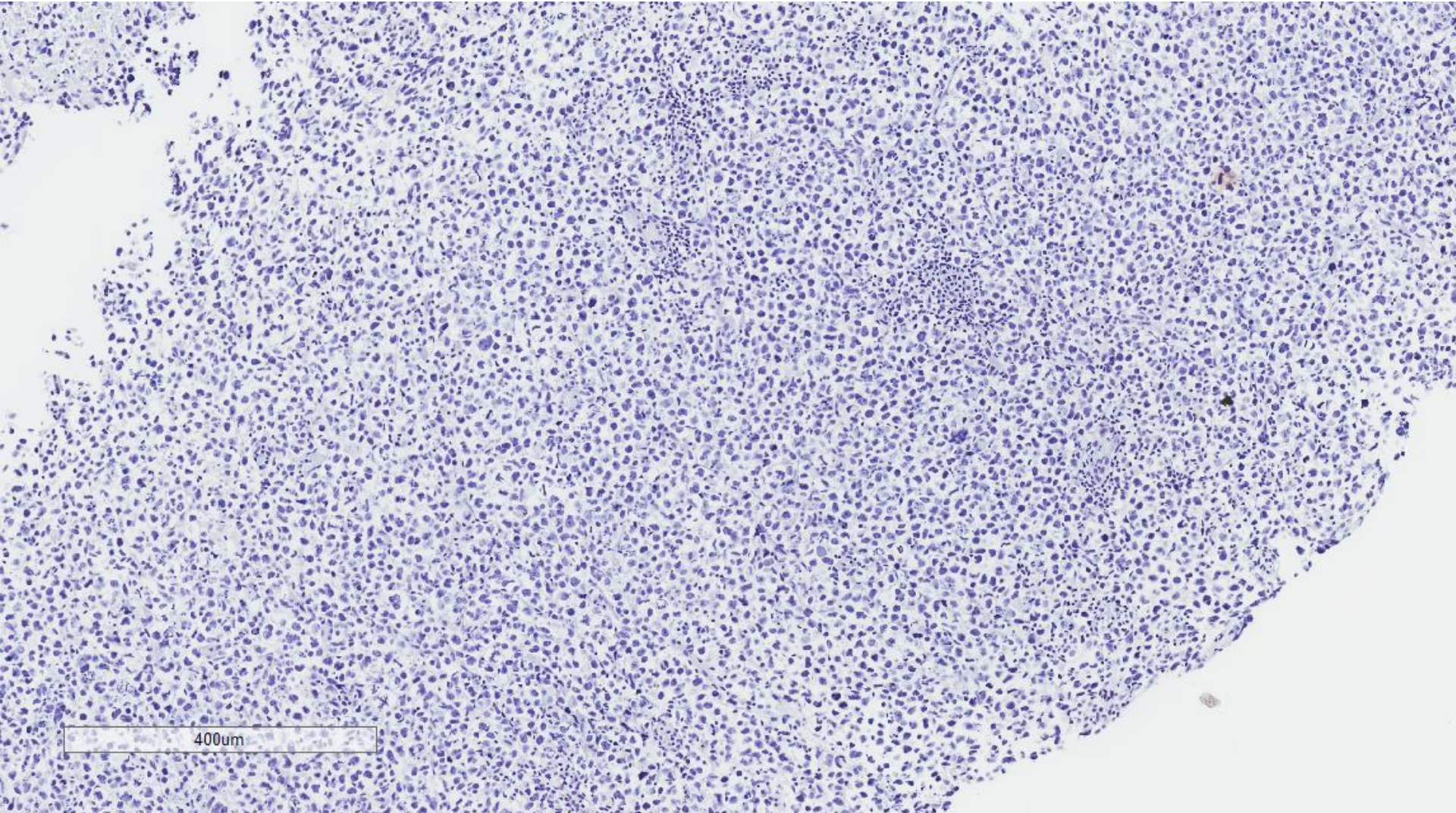


200µm

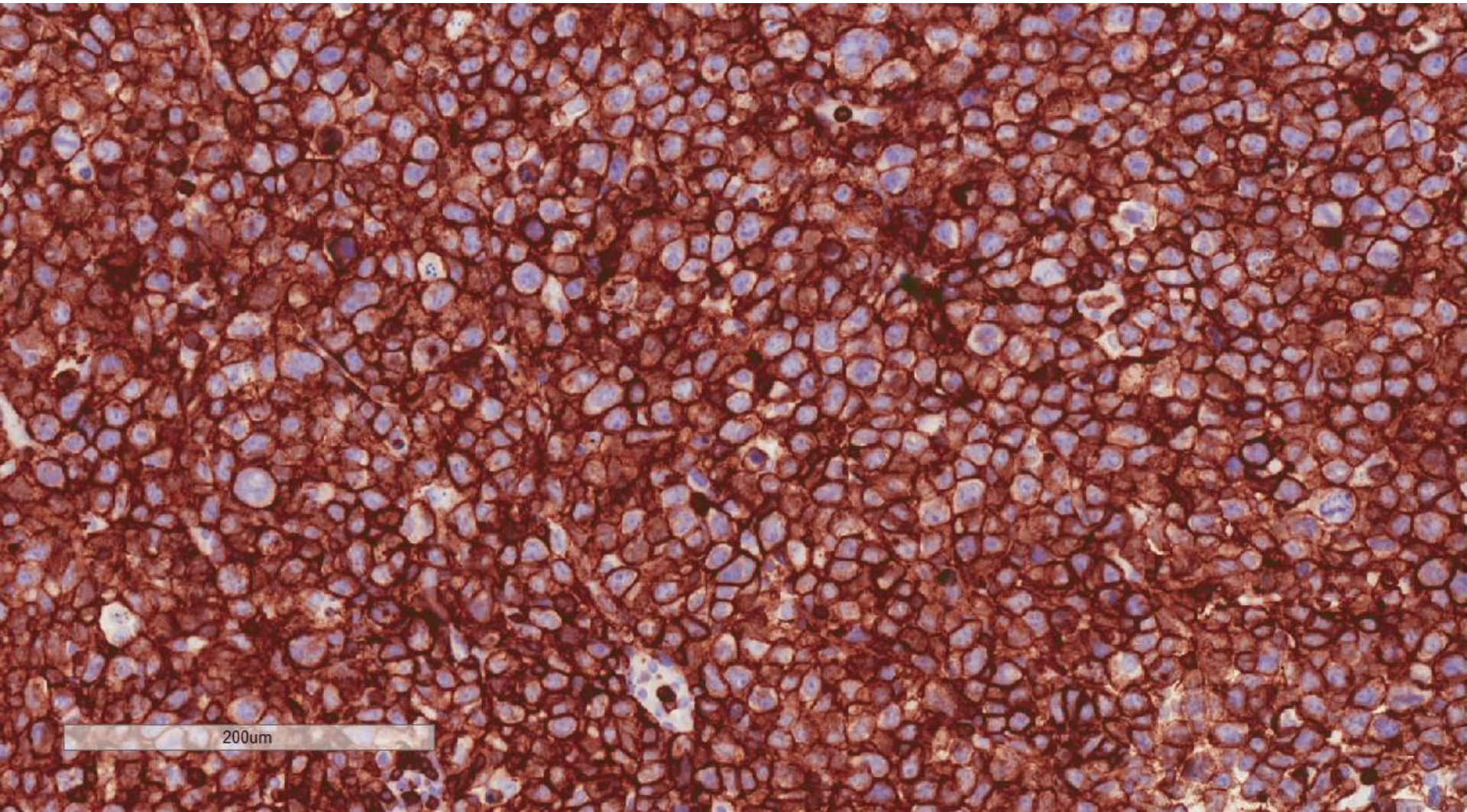


200µm

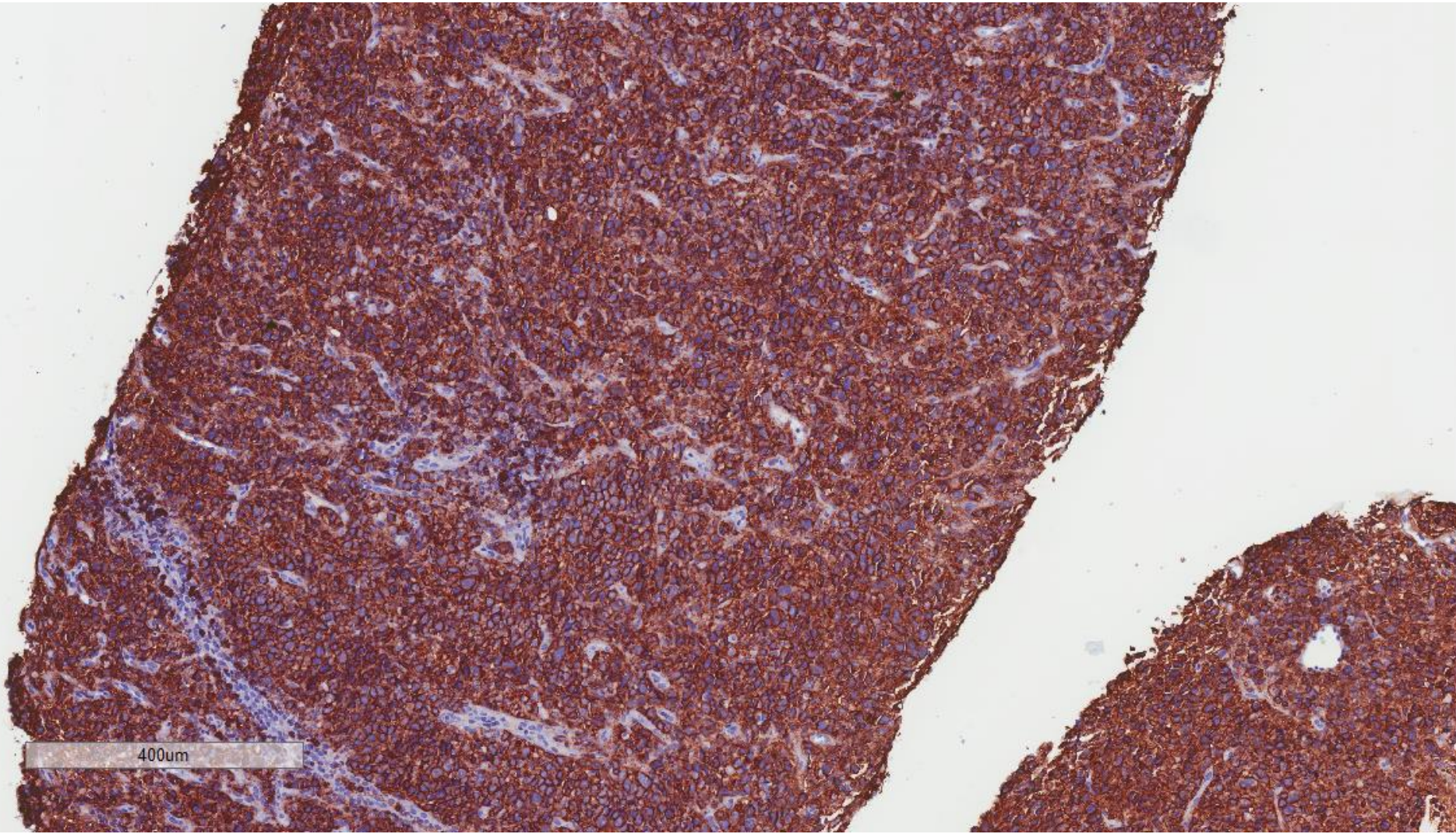
MNF116



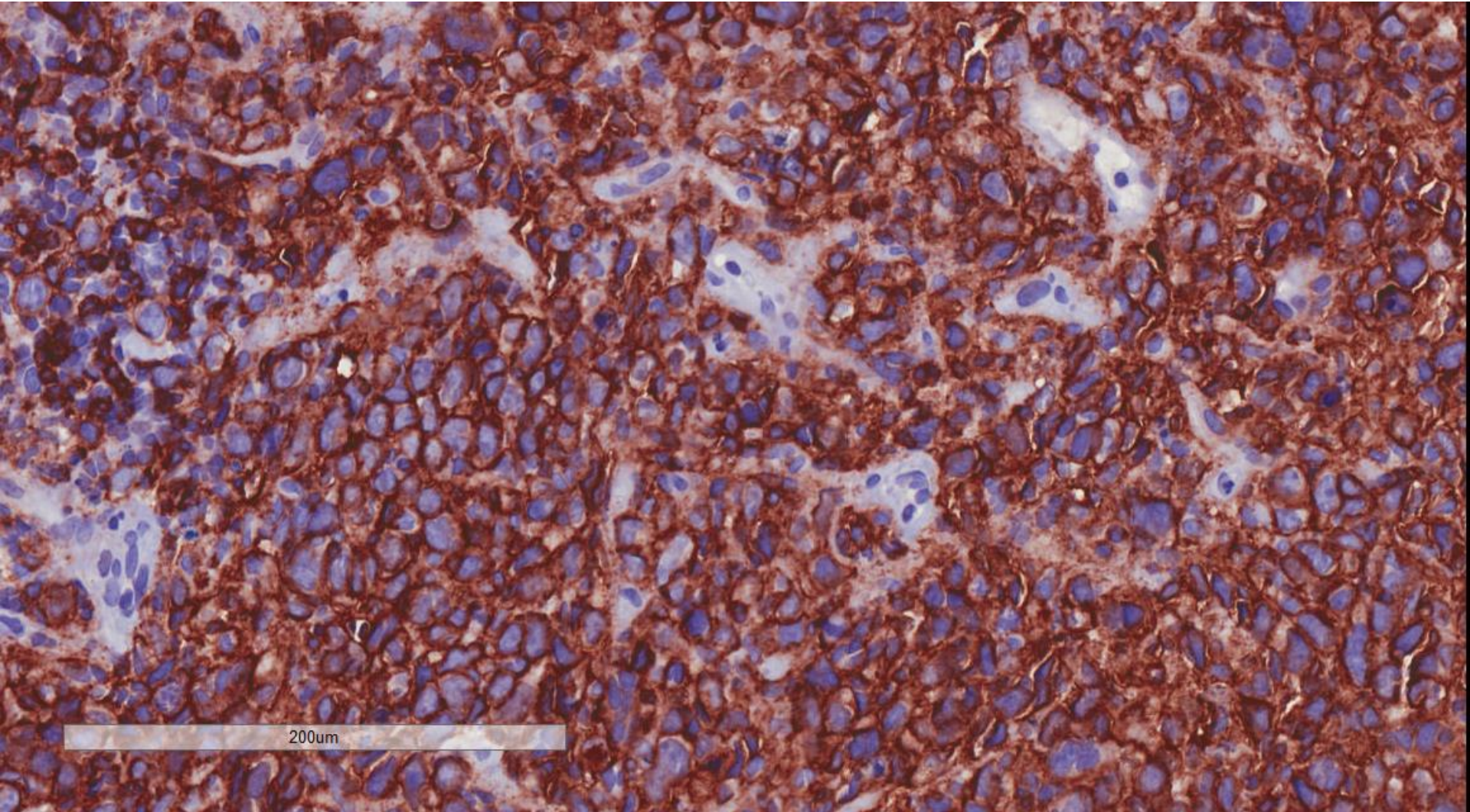
LCA



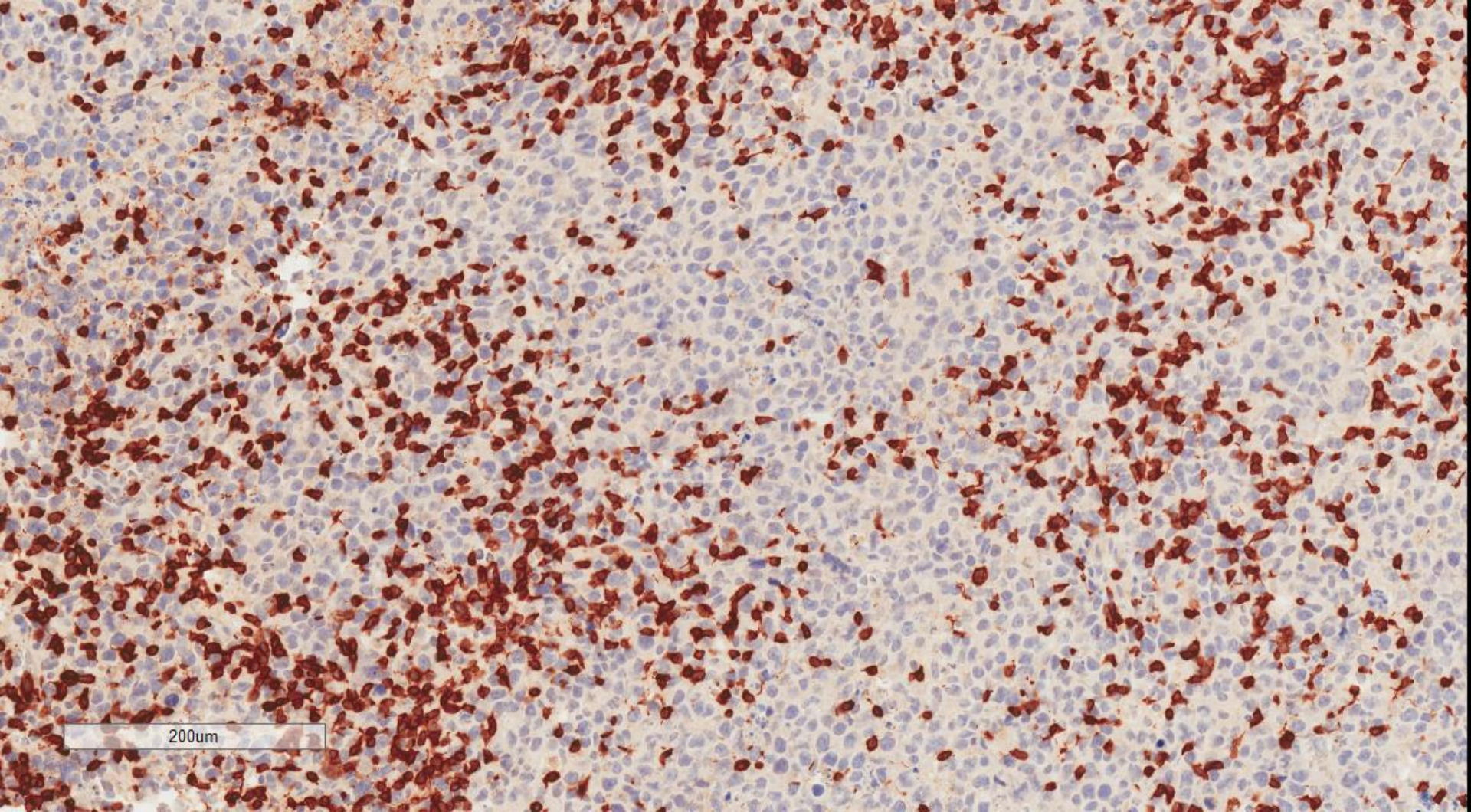
CD20



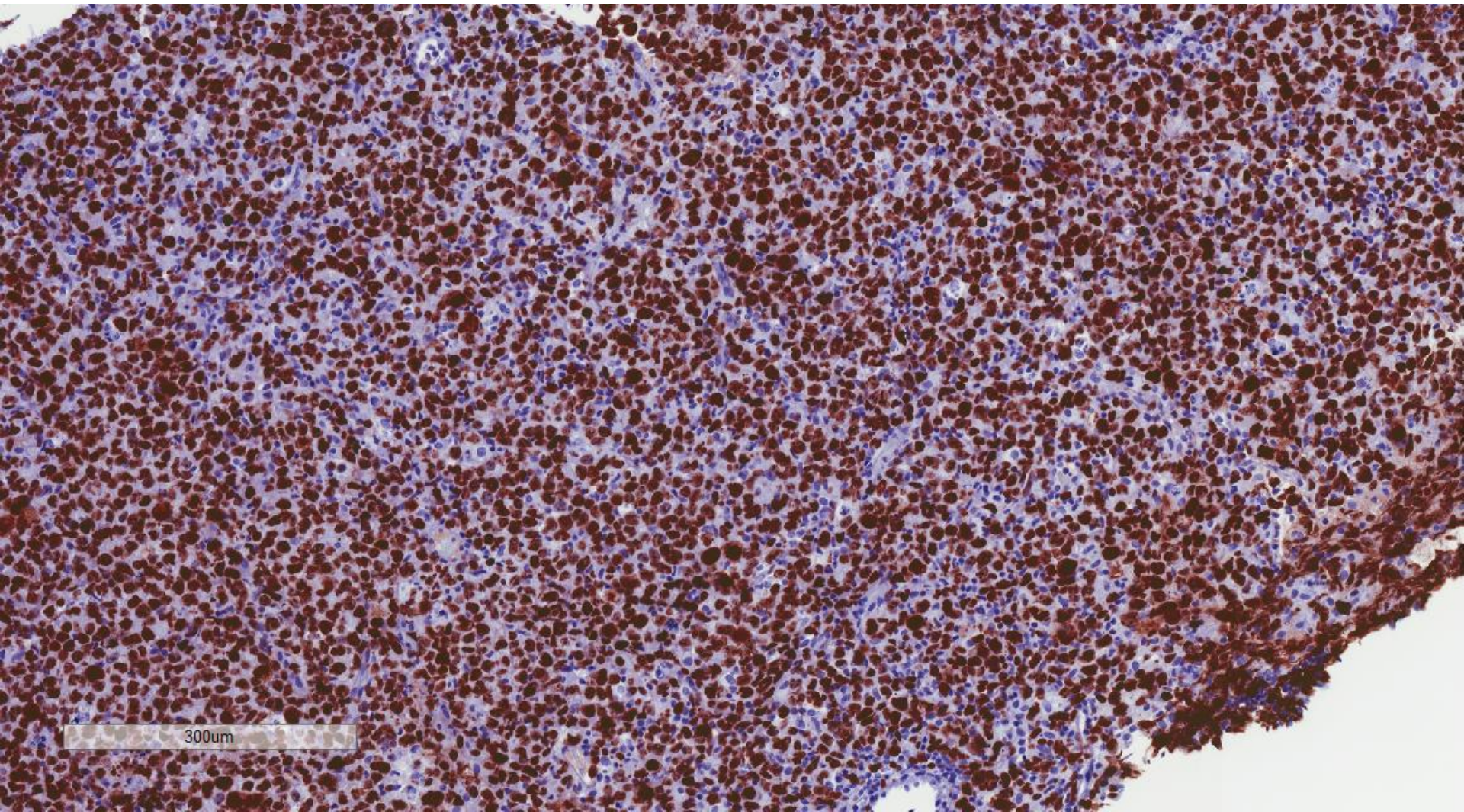
CD20



CD3



Ki67



Core biopsy, left axillary lymph node: Diffuse large B cell lymphoma