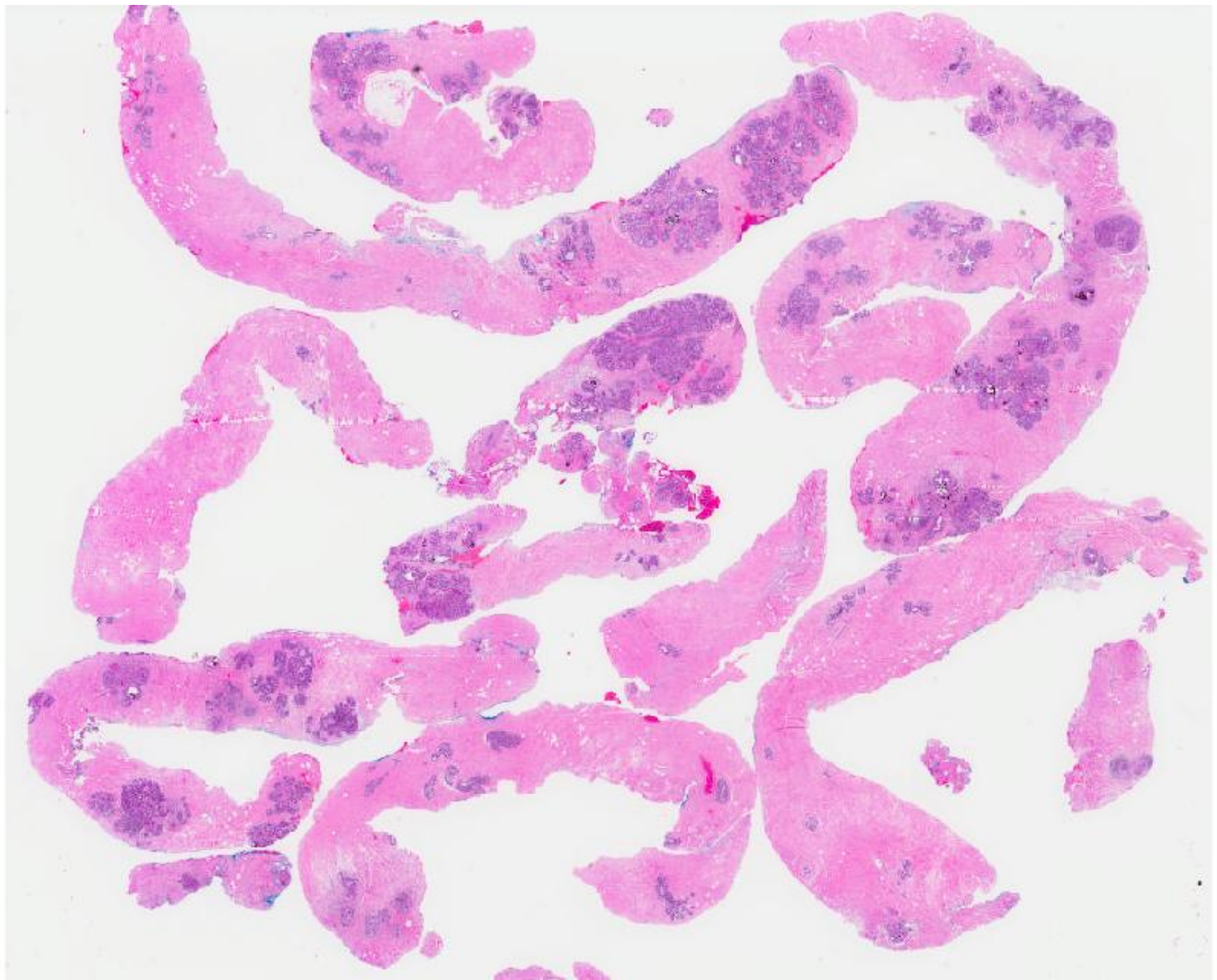
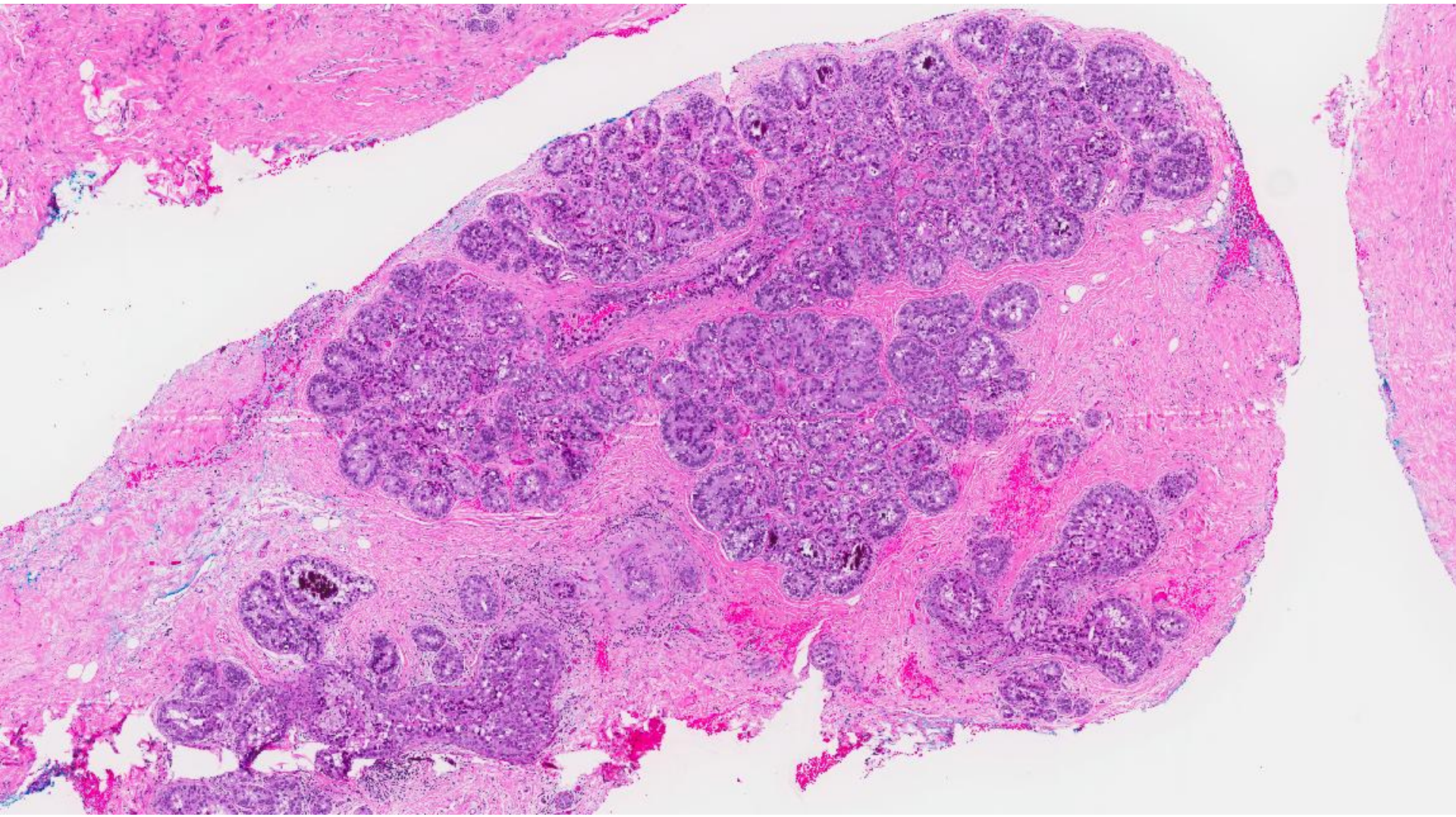


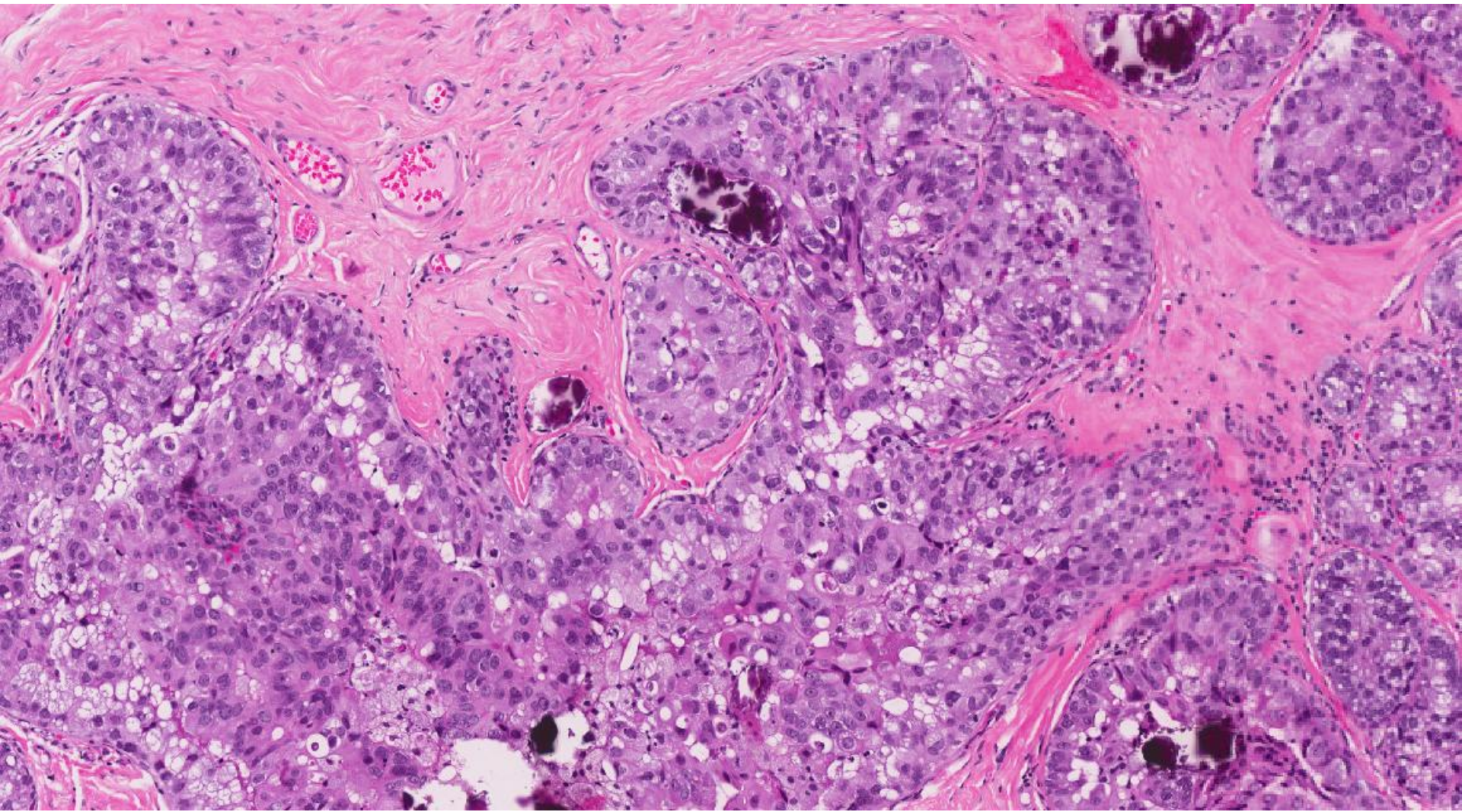
Case 22

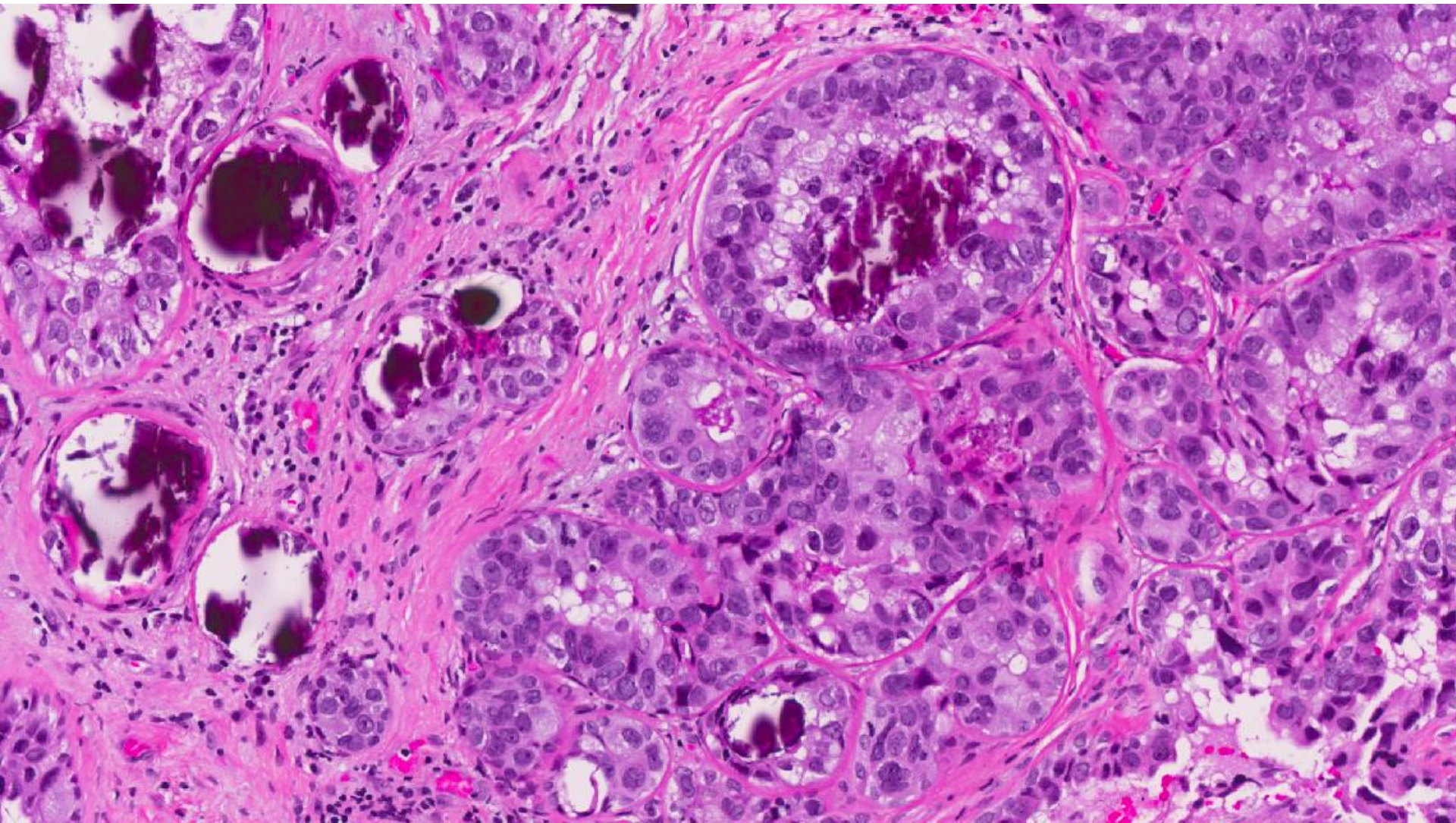
42 year old Indian lady underwent mammographic screening.

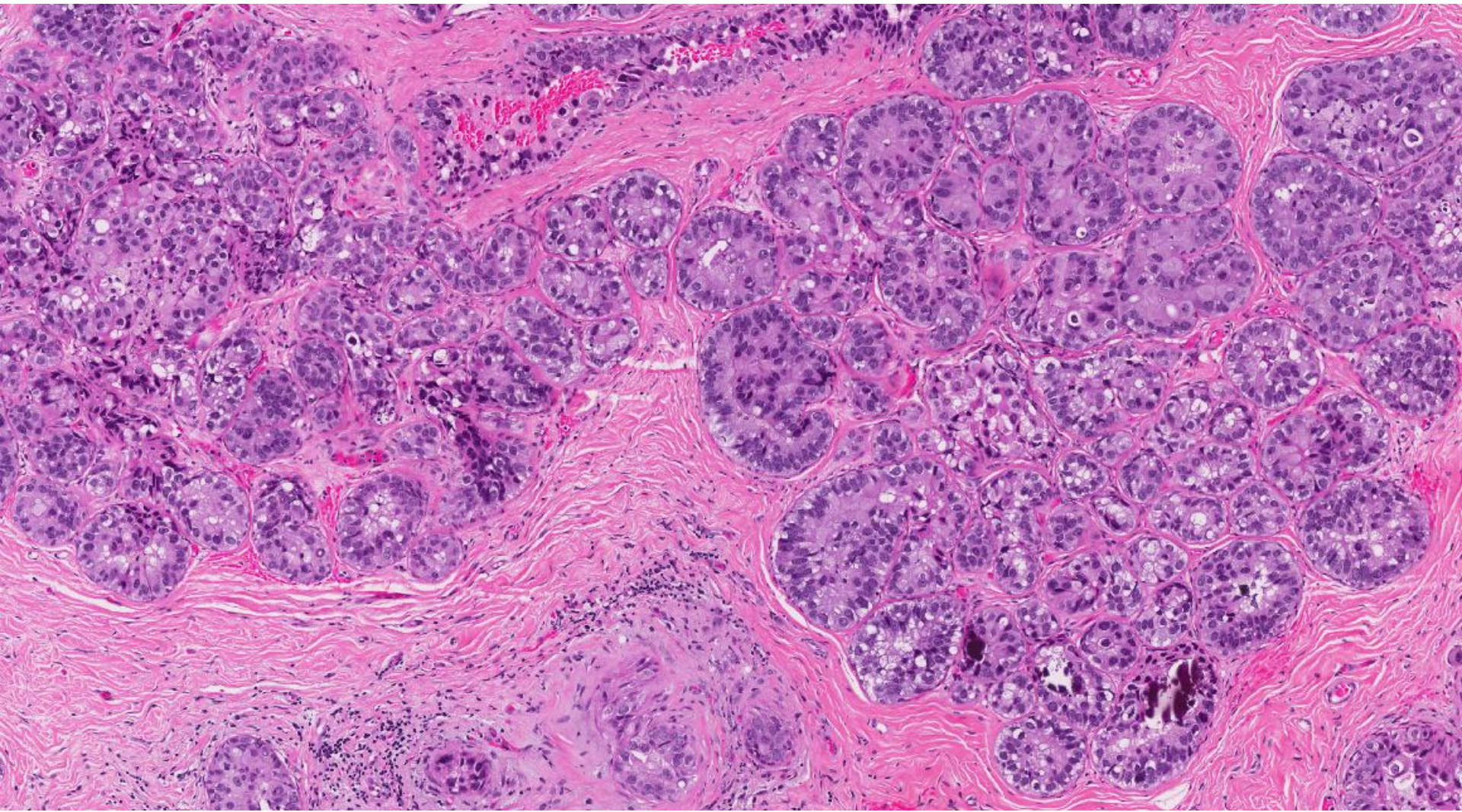
Stereotactic mammotome biopsies of right breast microcalcifications were performed.

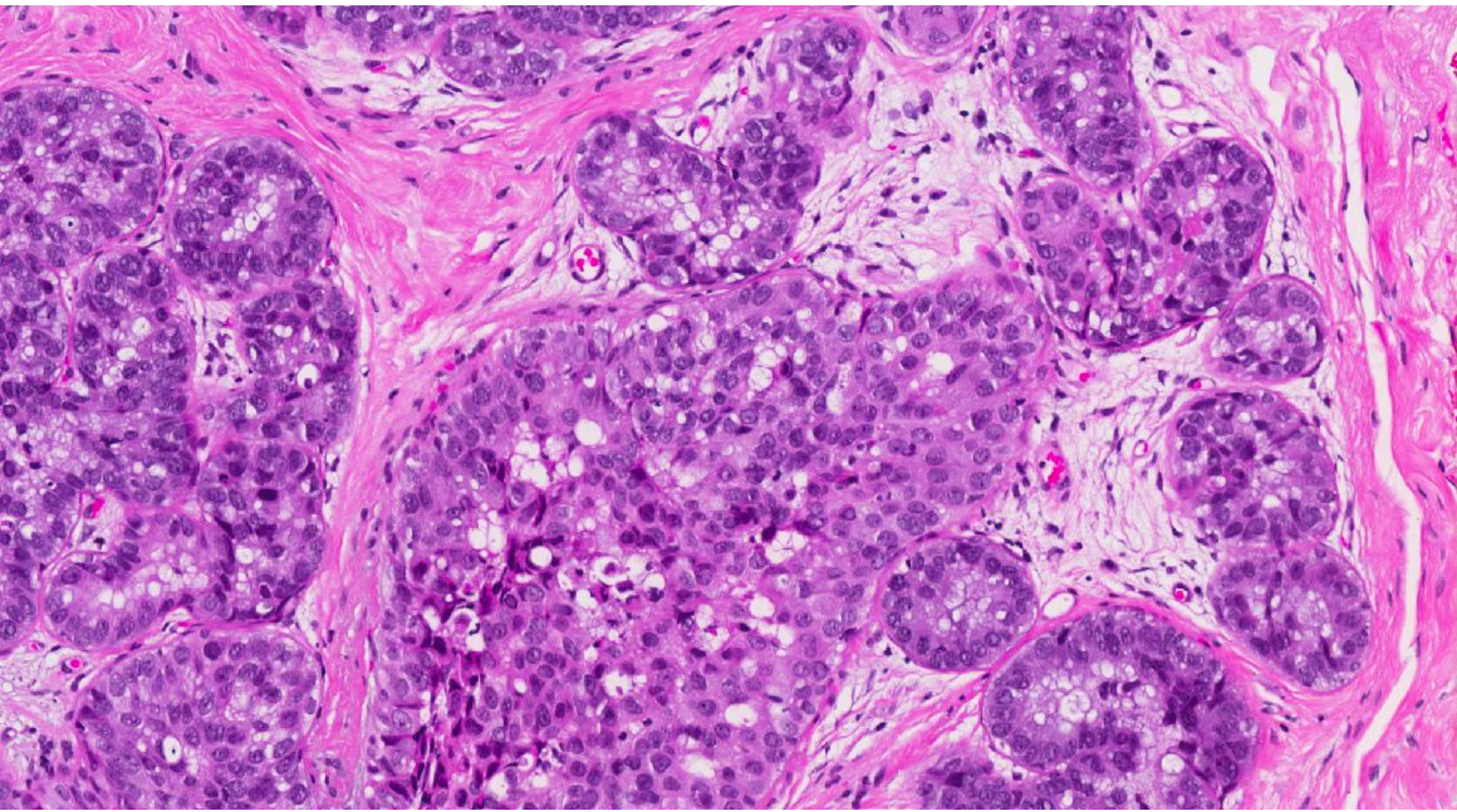












Diagnosis

Ductal carcinoma in situ, high nuclear grade, with necrosis and calcifications