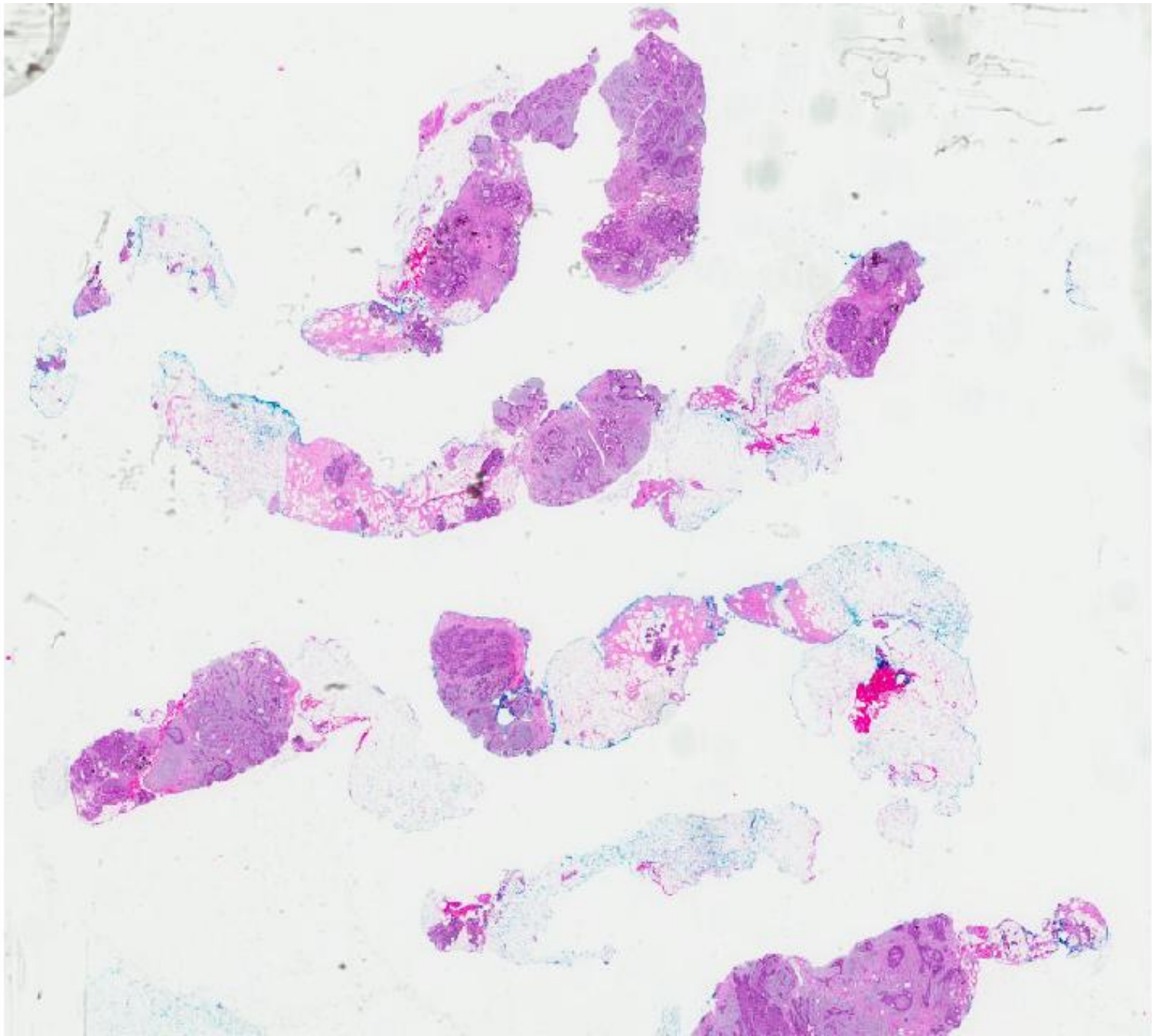
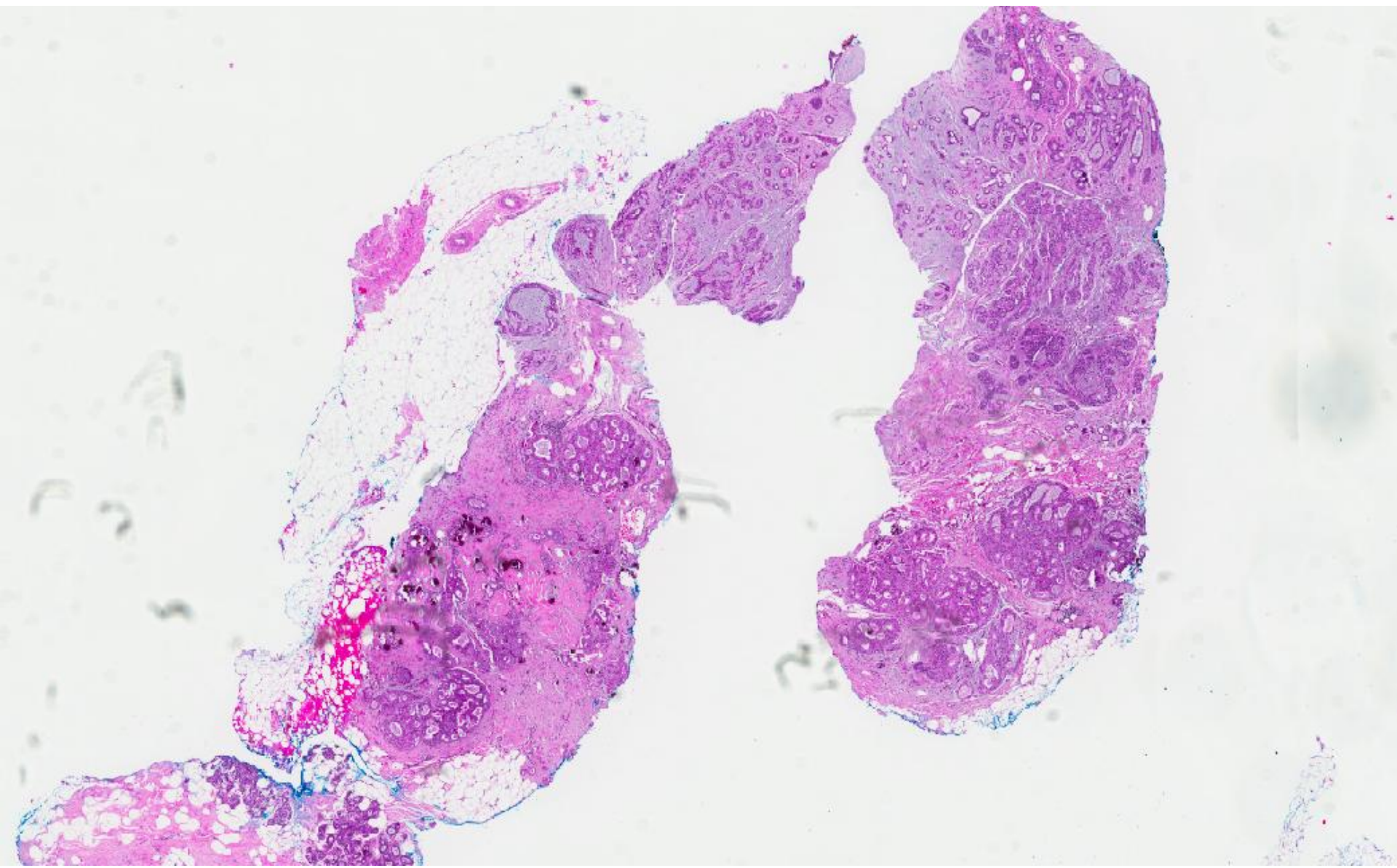
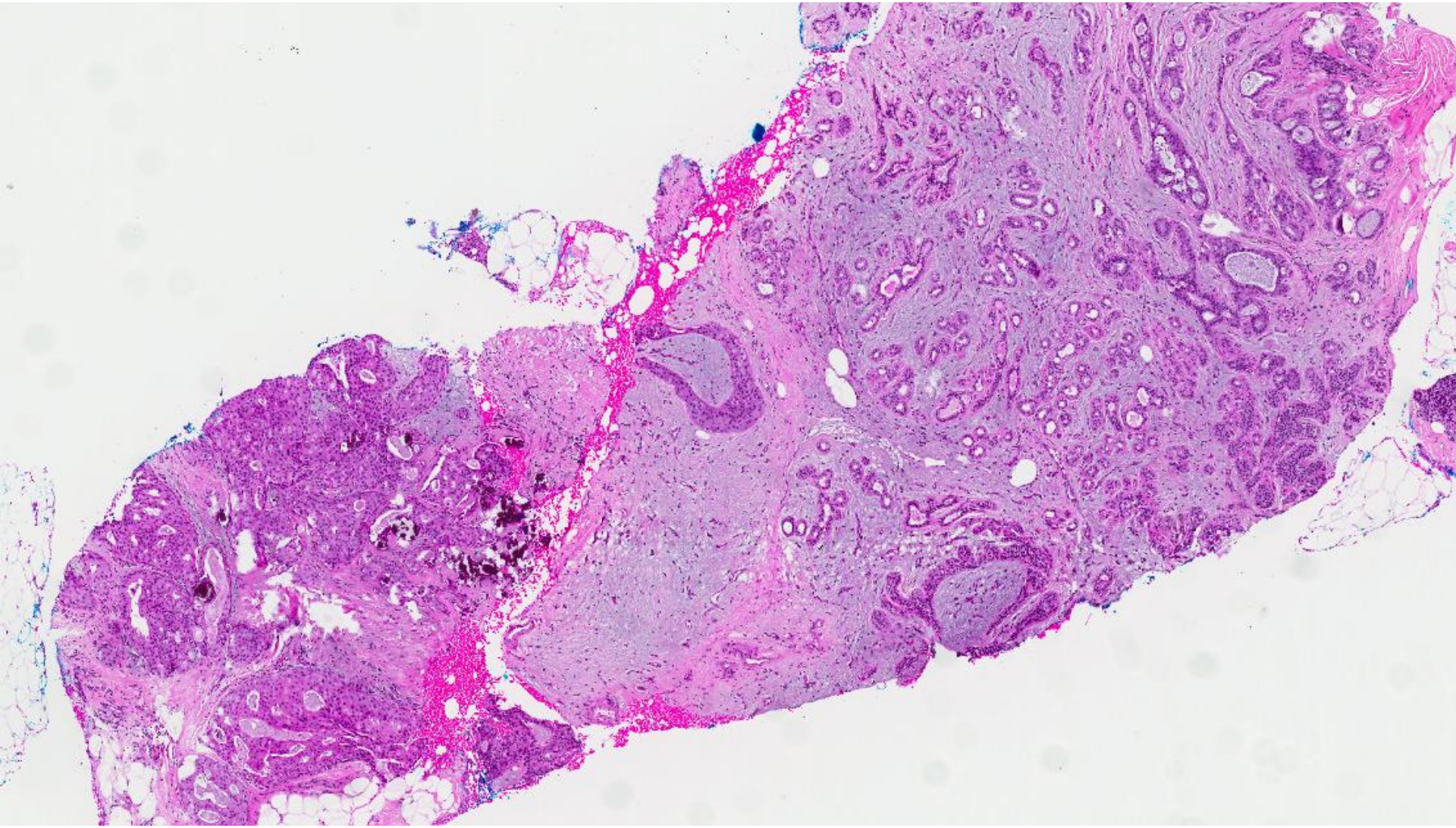


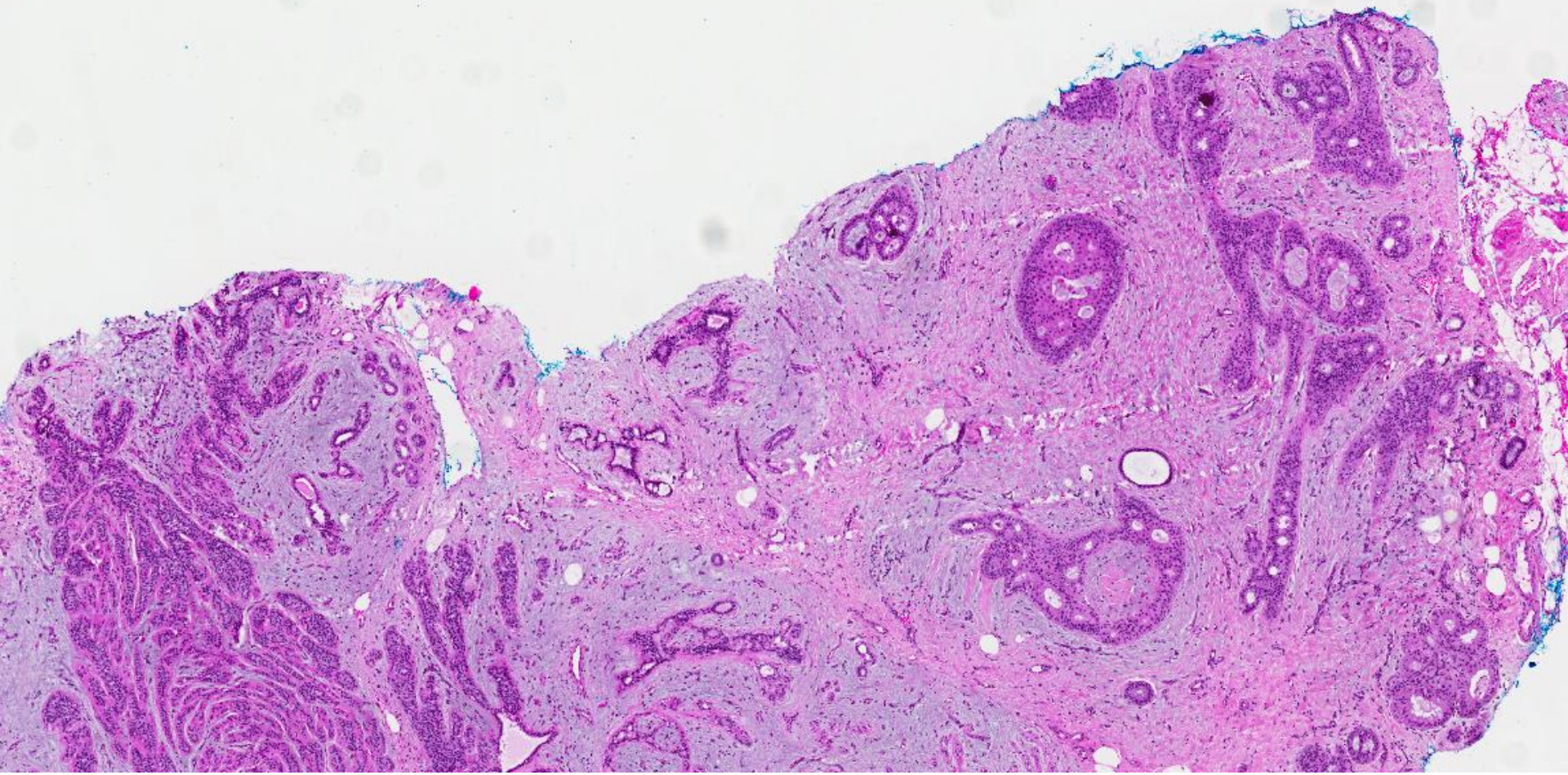
Case 34

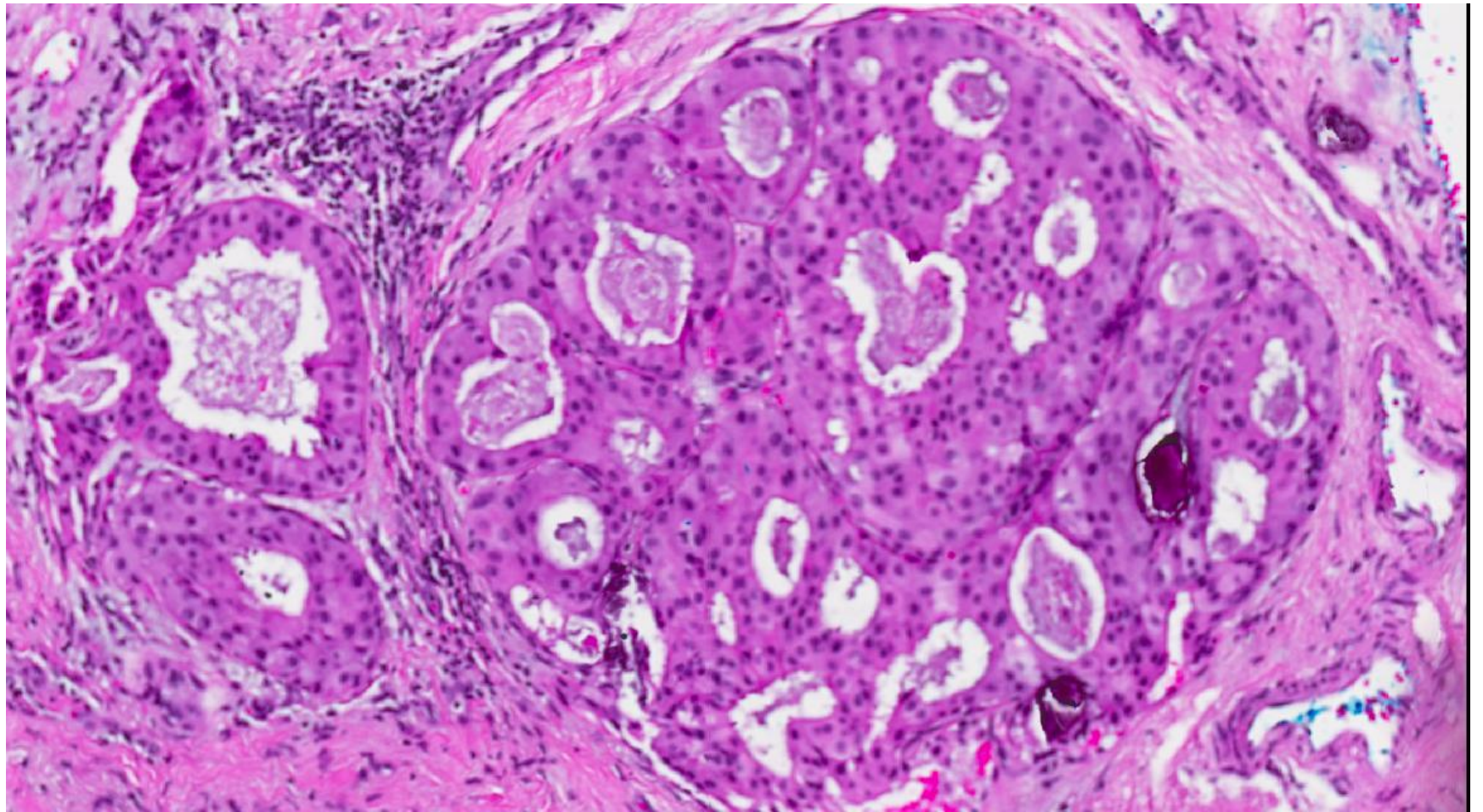
51 year old lady with left breast microcalcifications on mammography. Stereotactic mammotome biopsies performed.

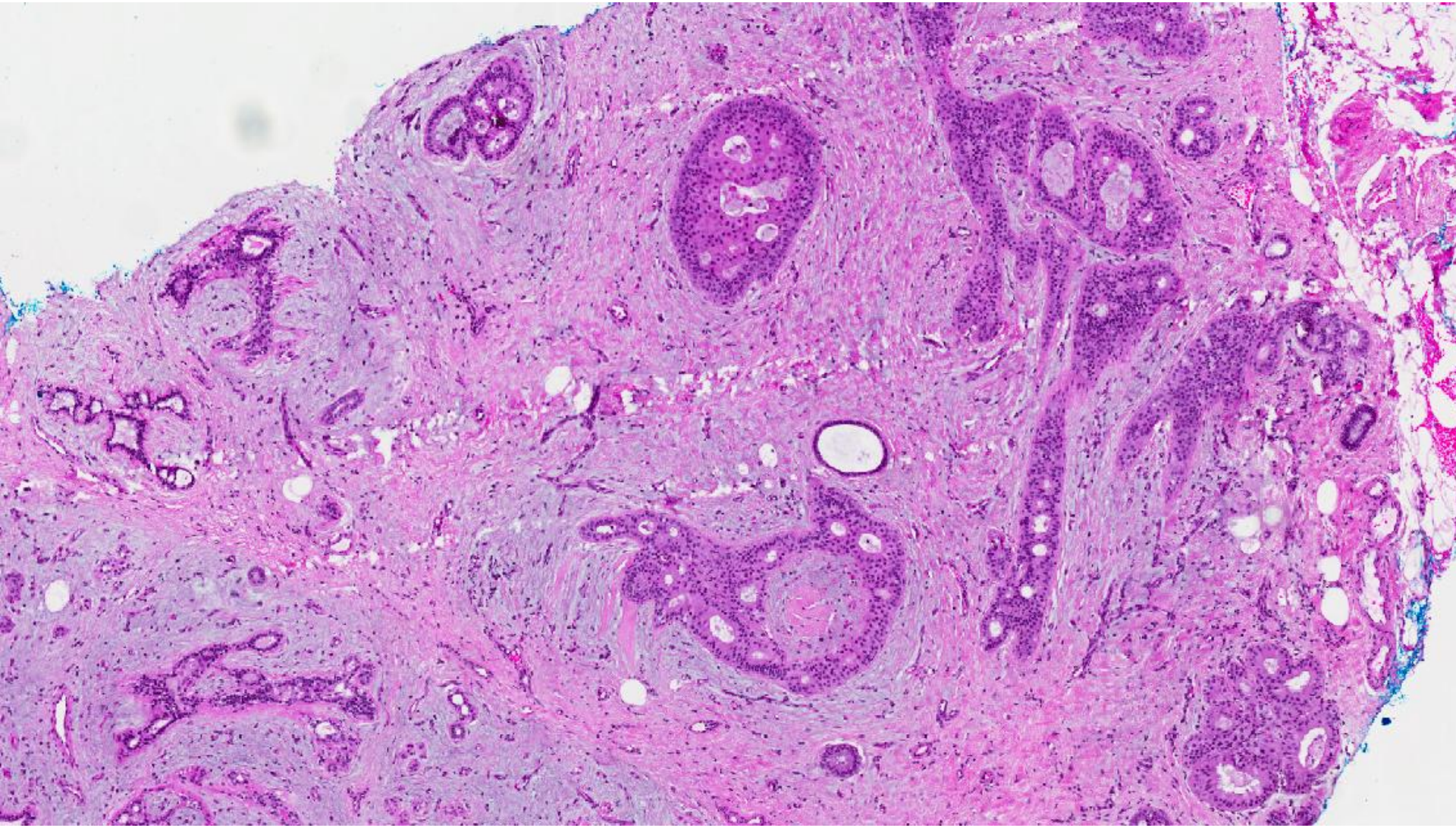












Diagnosis

- Ductal carcinoma in situ with apocrine features, involving a fibroadenoma.