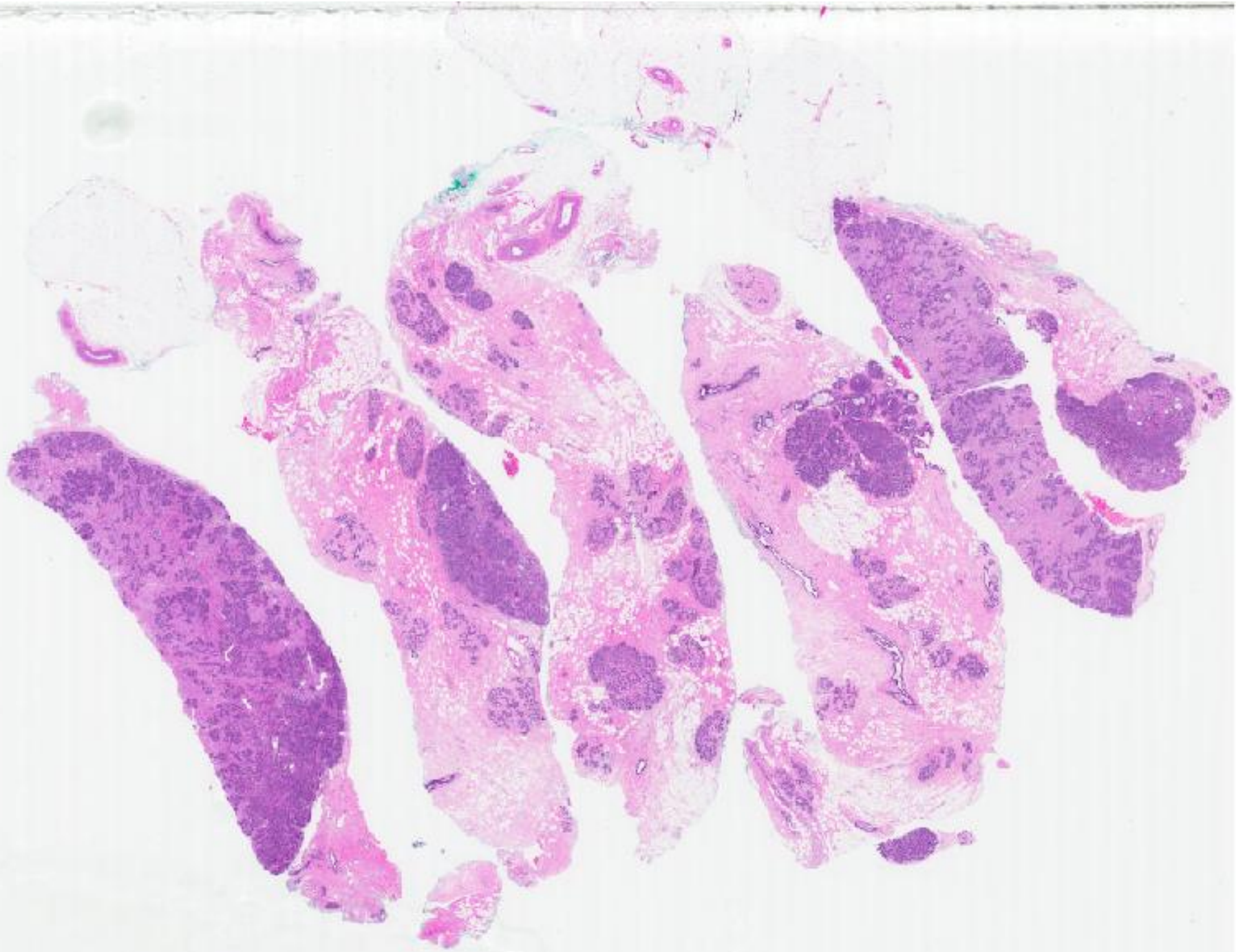
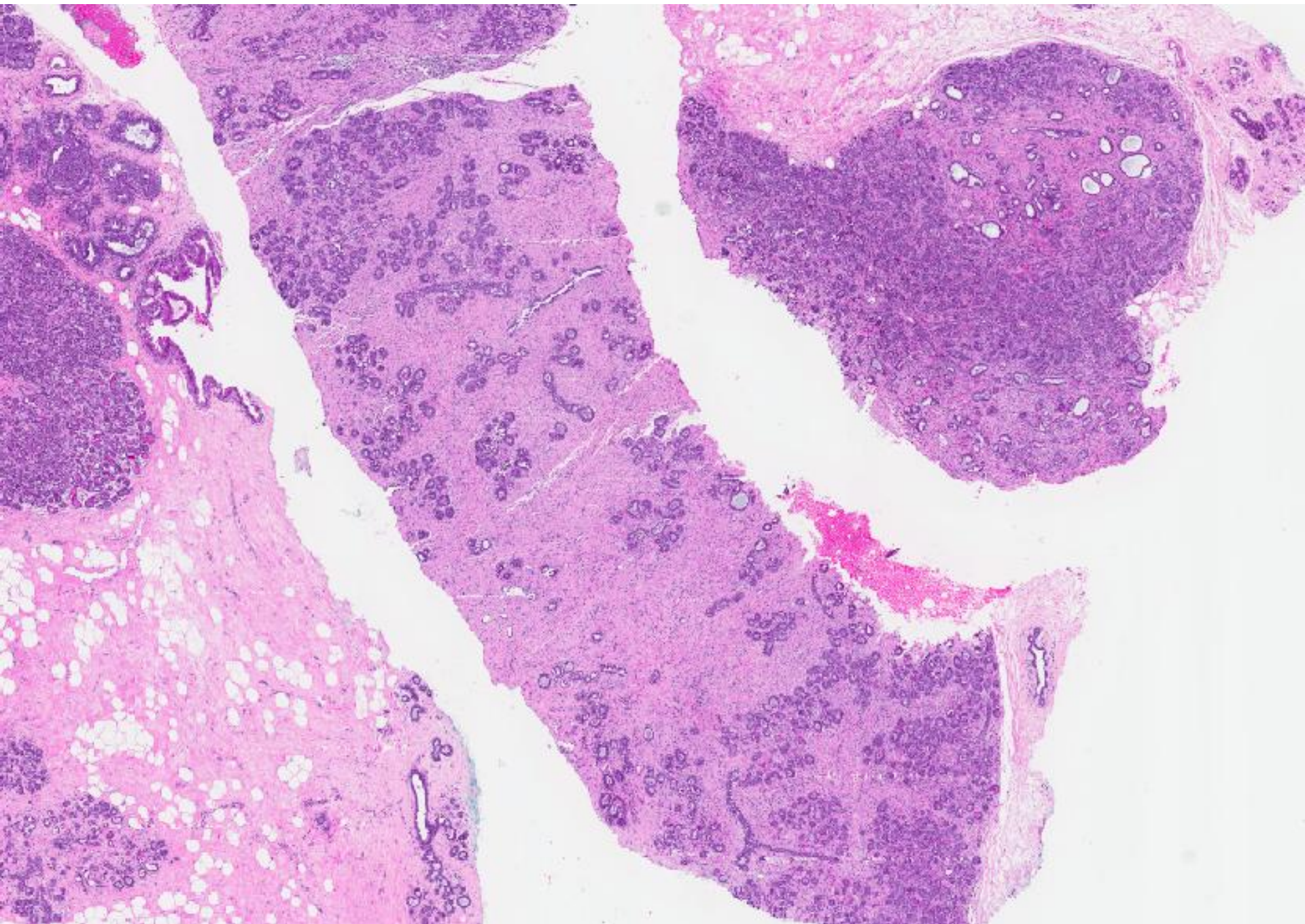
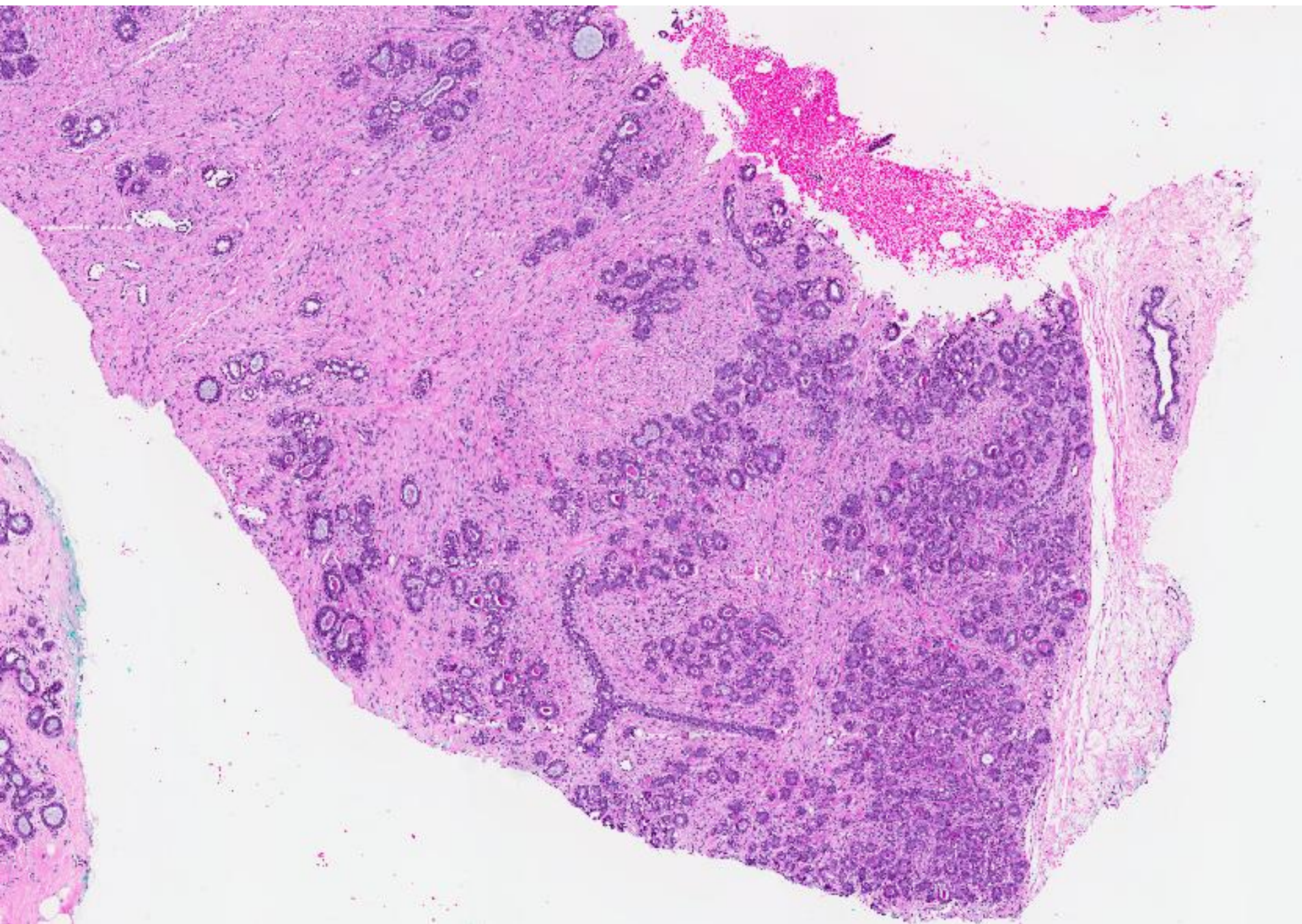


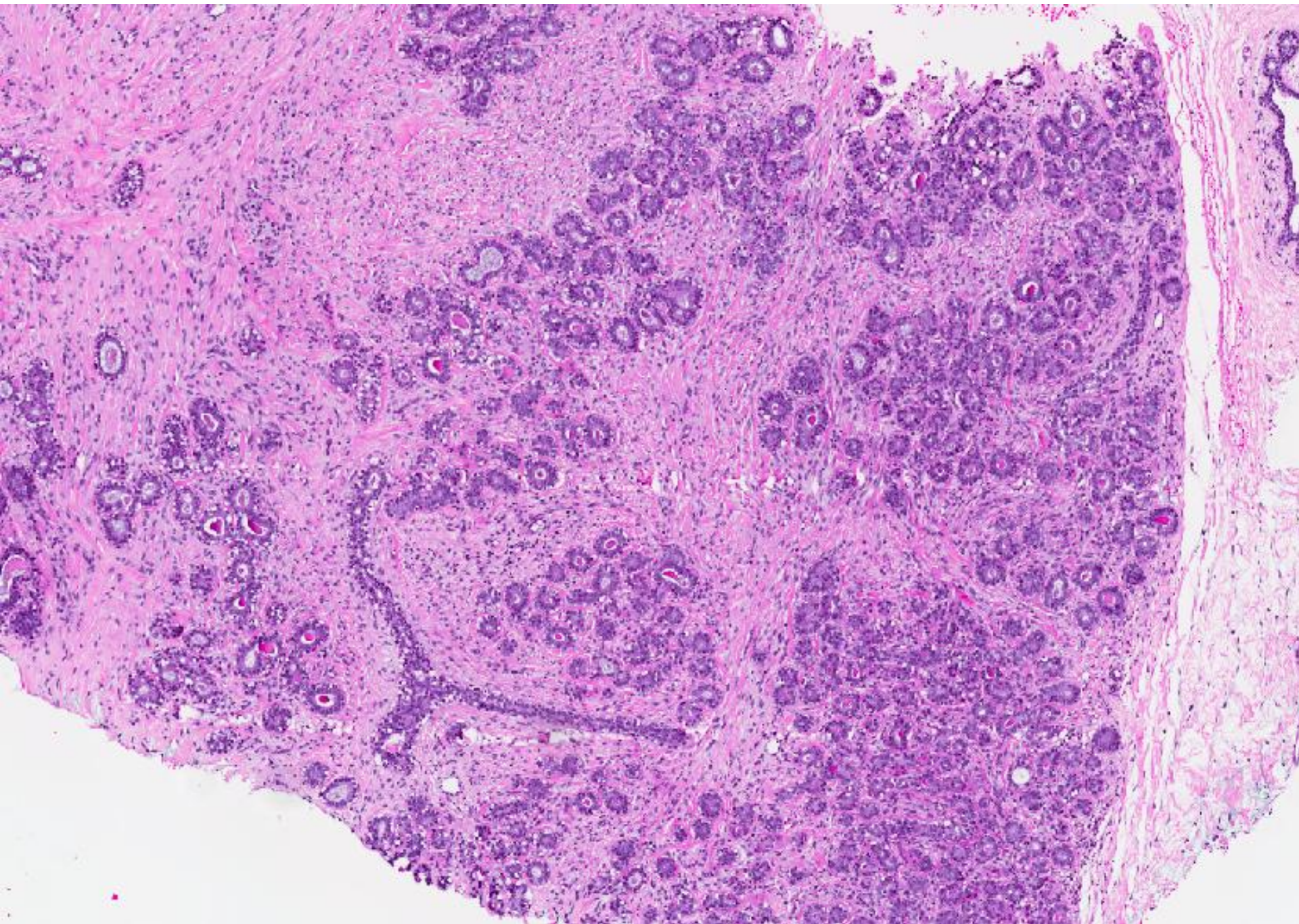
CASE 25

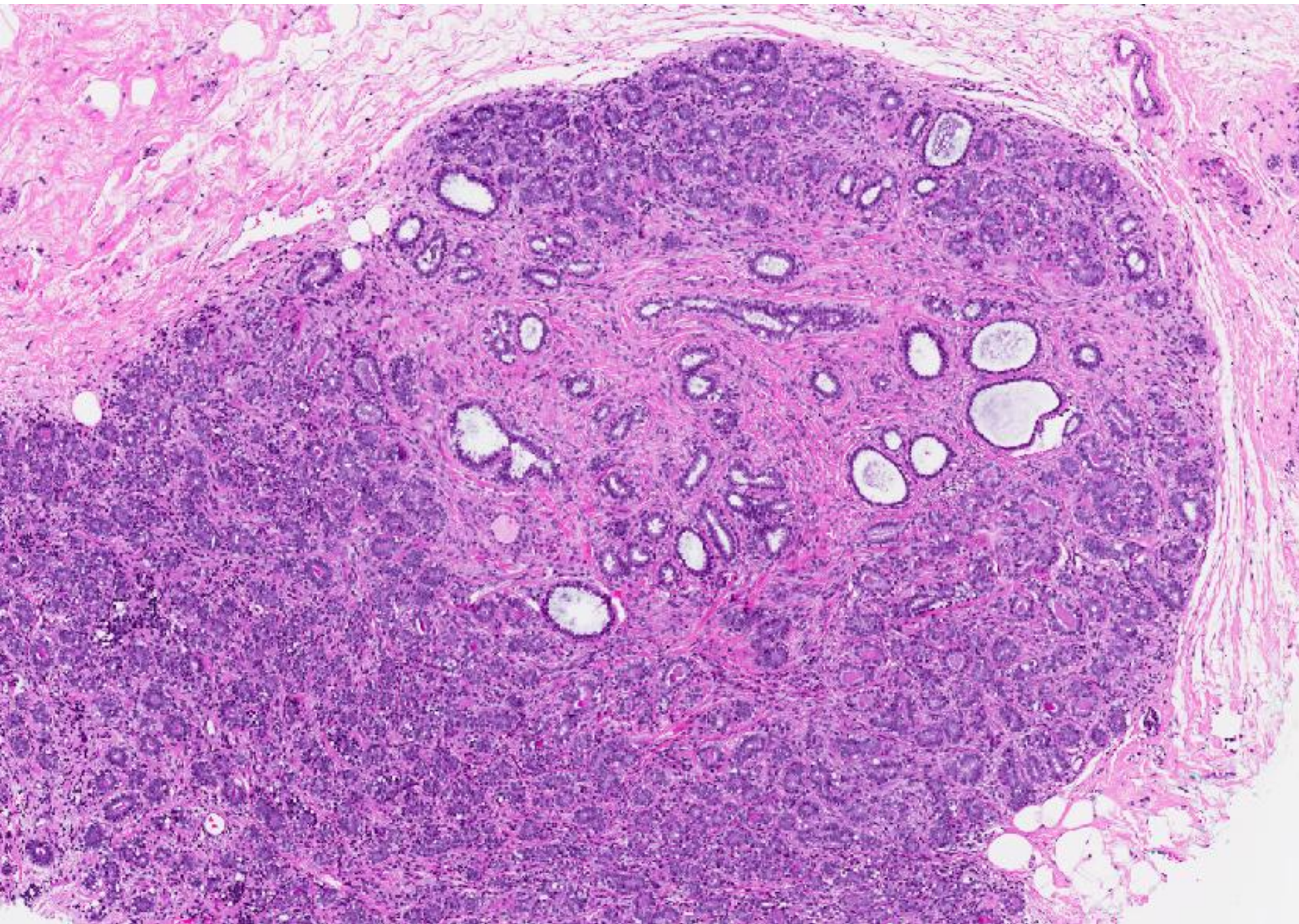
41 year old Chinese female
underwent mammotome biopsy of a
right breast 6 o'clock nodular lesion.

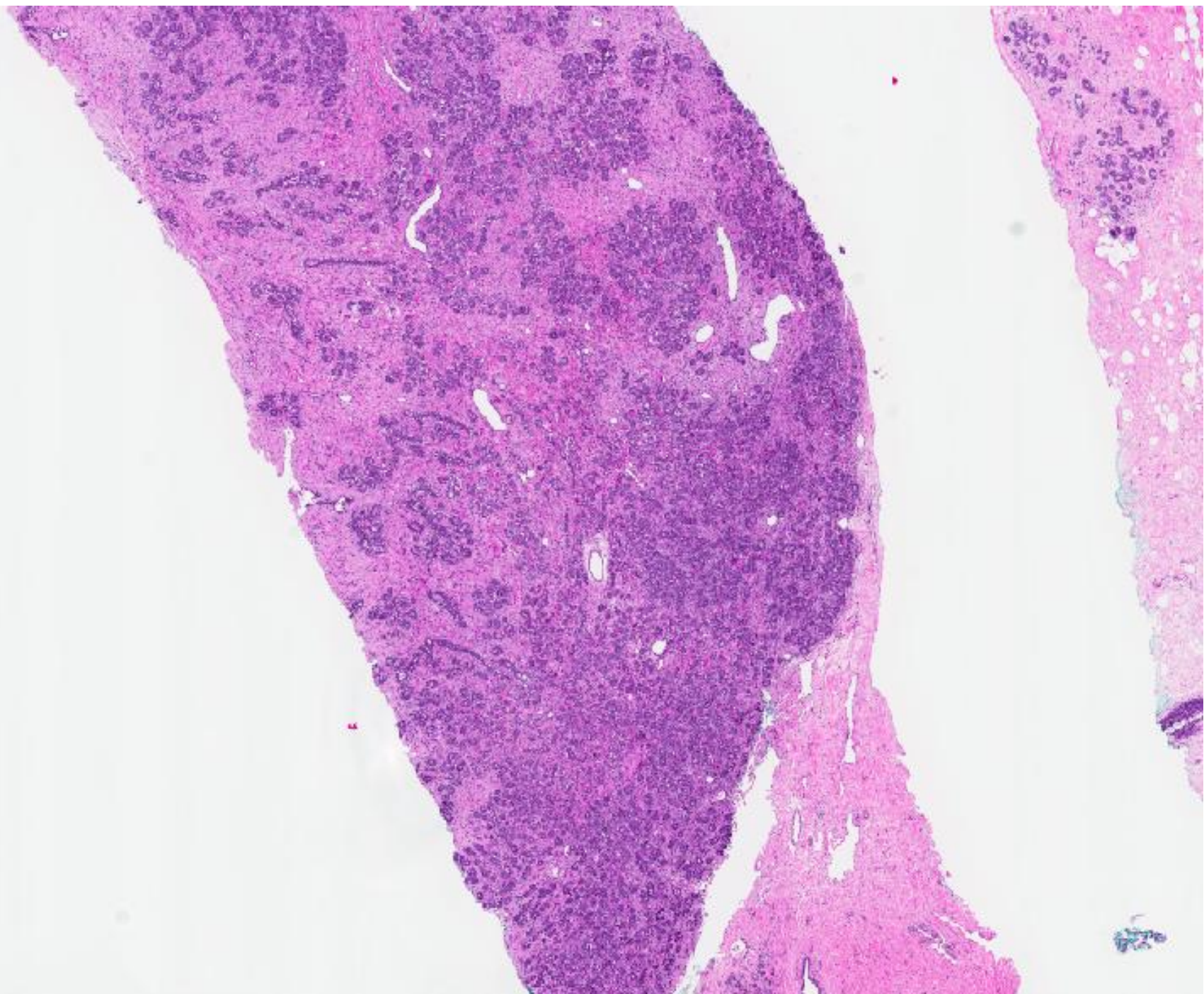


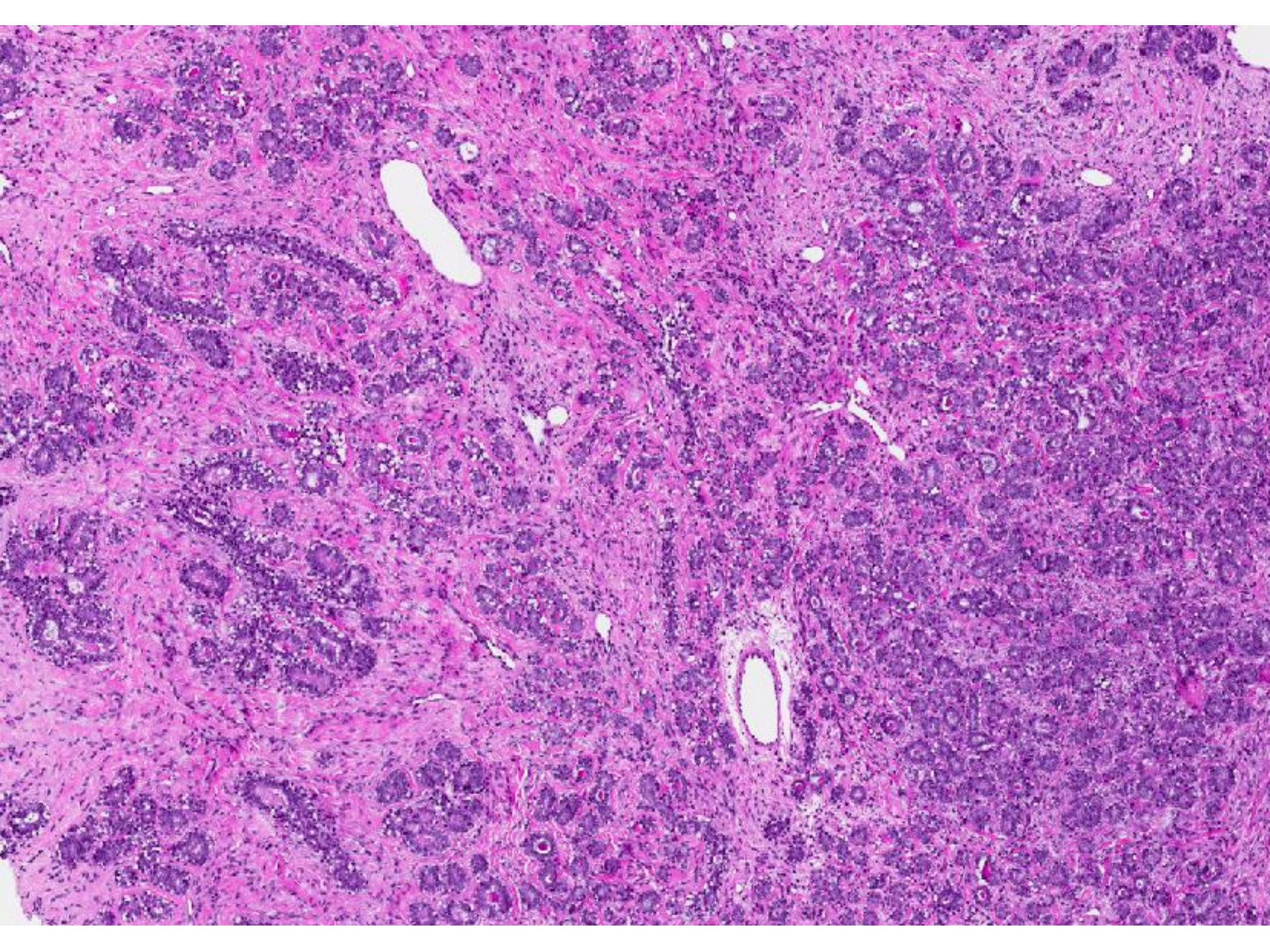


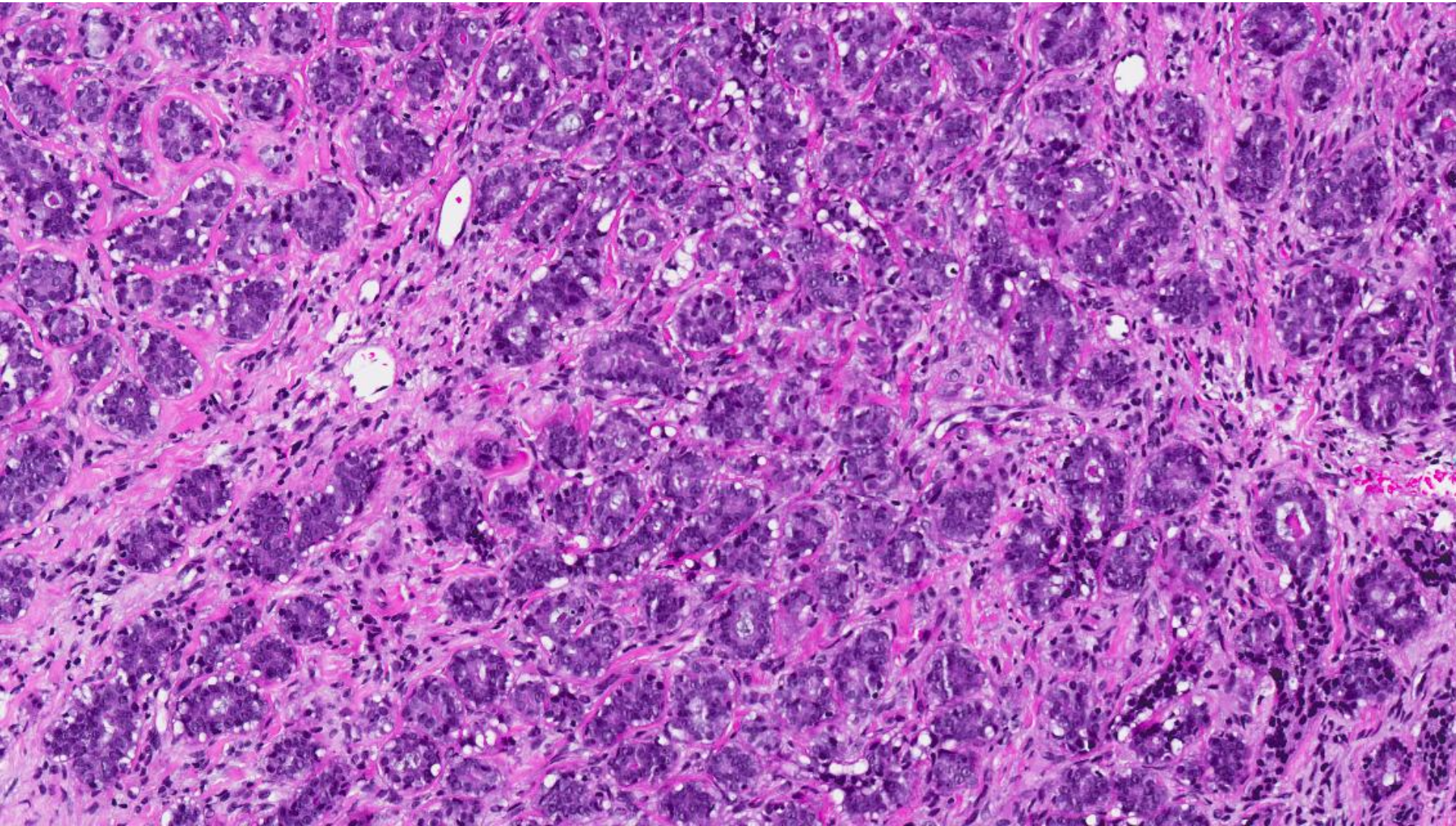












Diagnosis

- Benign breast lesion, consistent with nodular adenosis.
- Tubular adenoma and fibroadenoma-like areas.