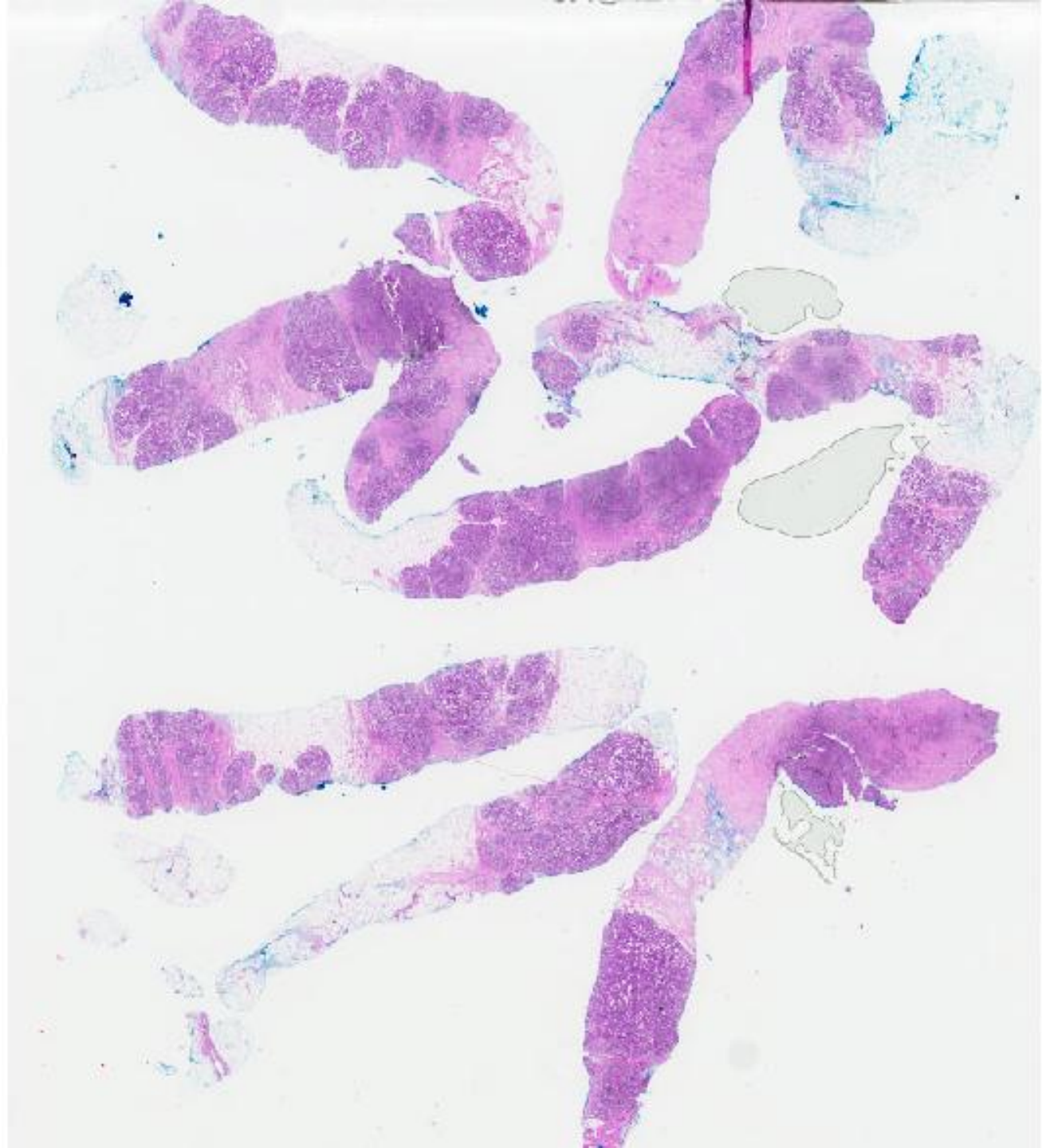
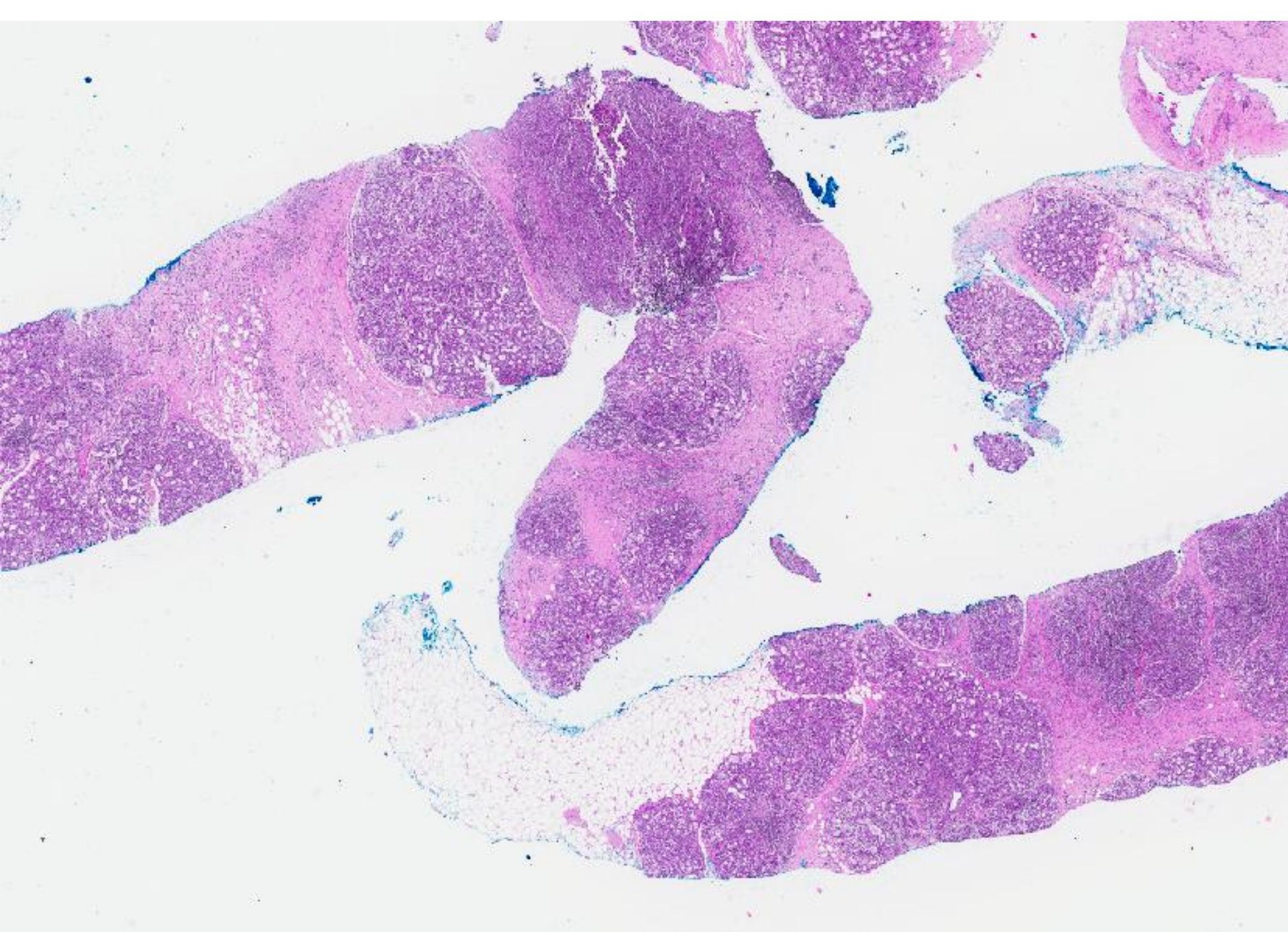


## CASE 21

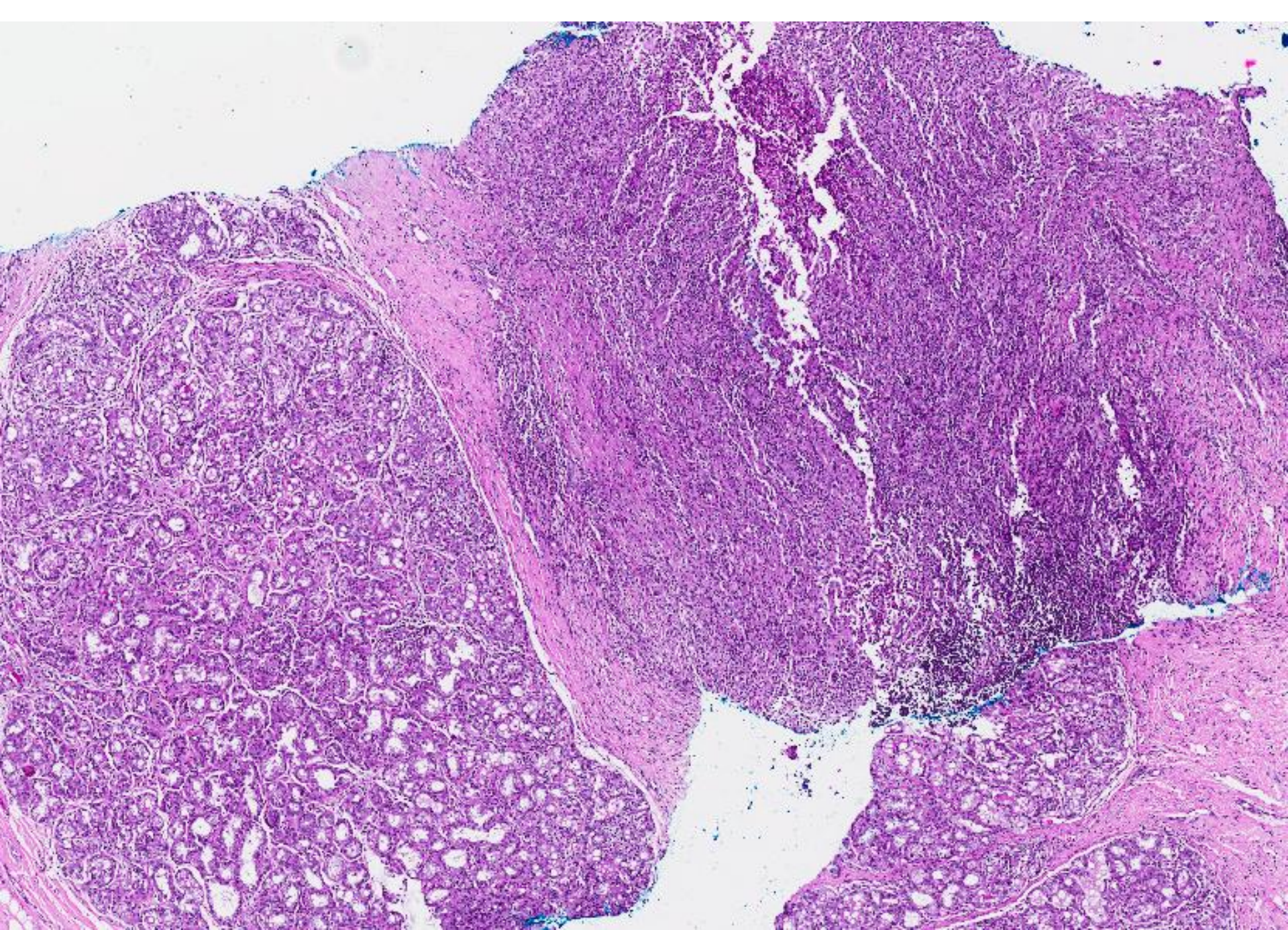
35 year old Indonesian lady was diagnosed with a left breast abscess during pregnancy.

Two weeks after delivery, trucut biopsies of the left breast were performed.

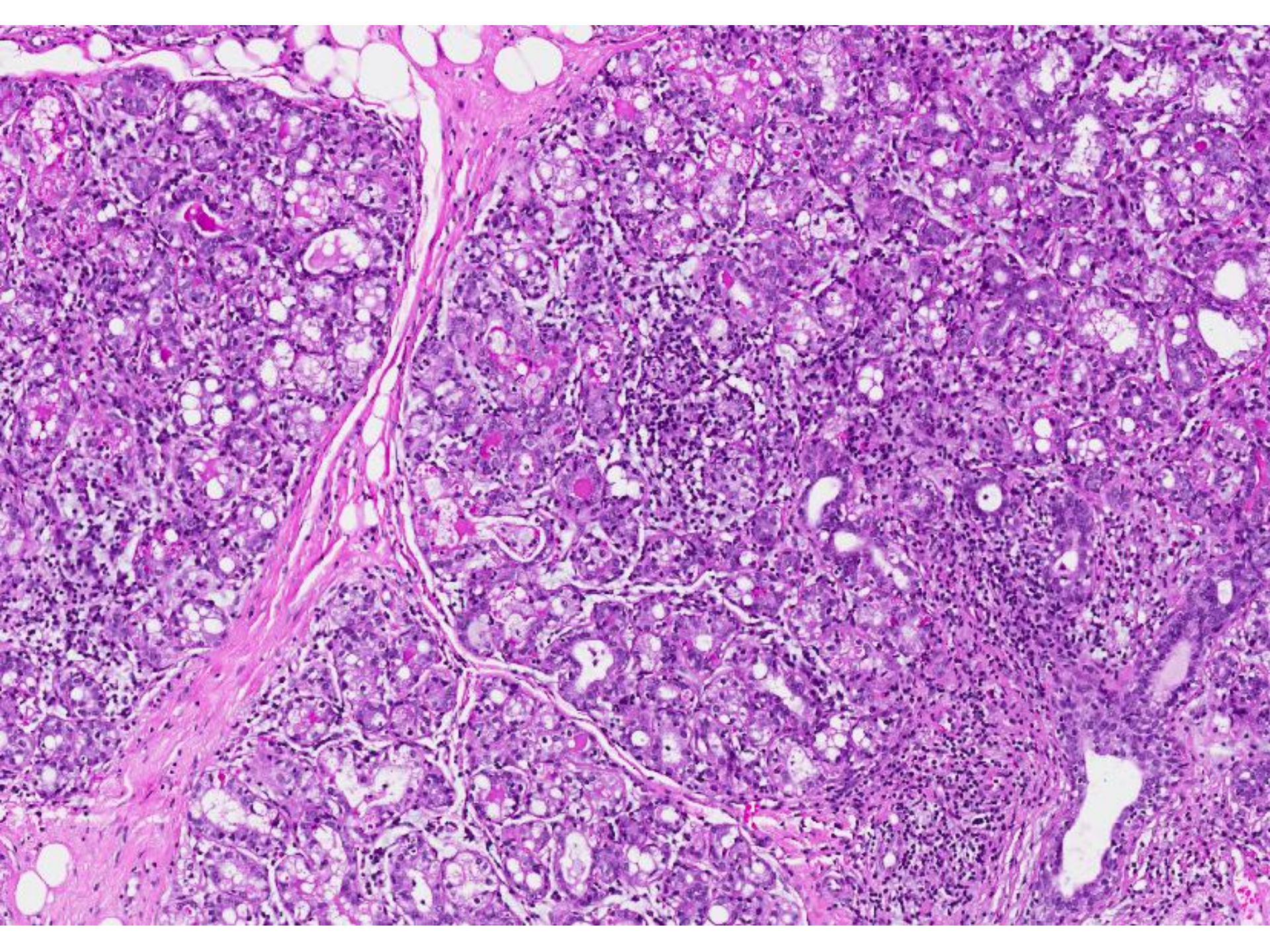




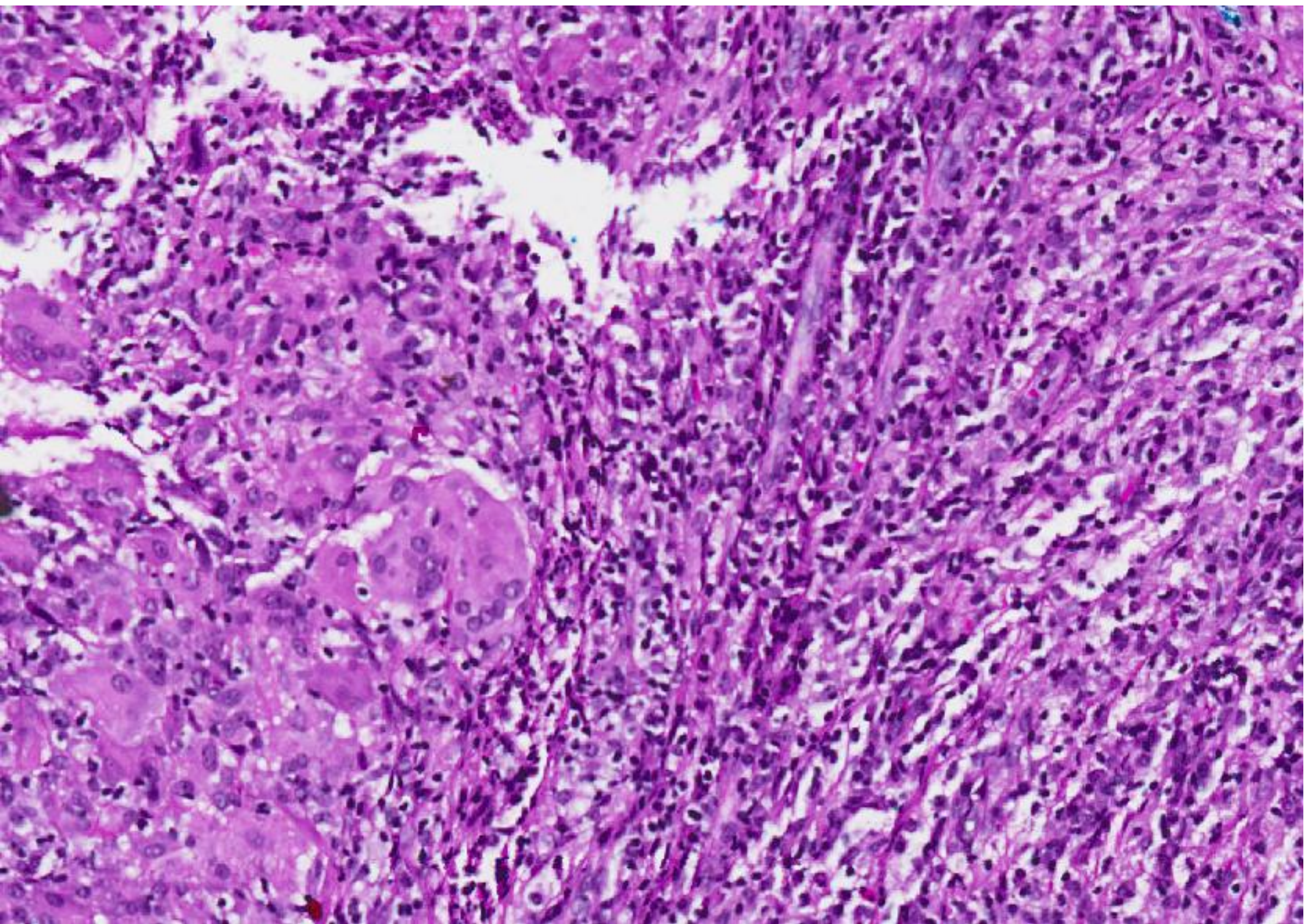




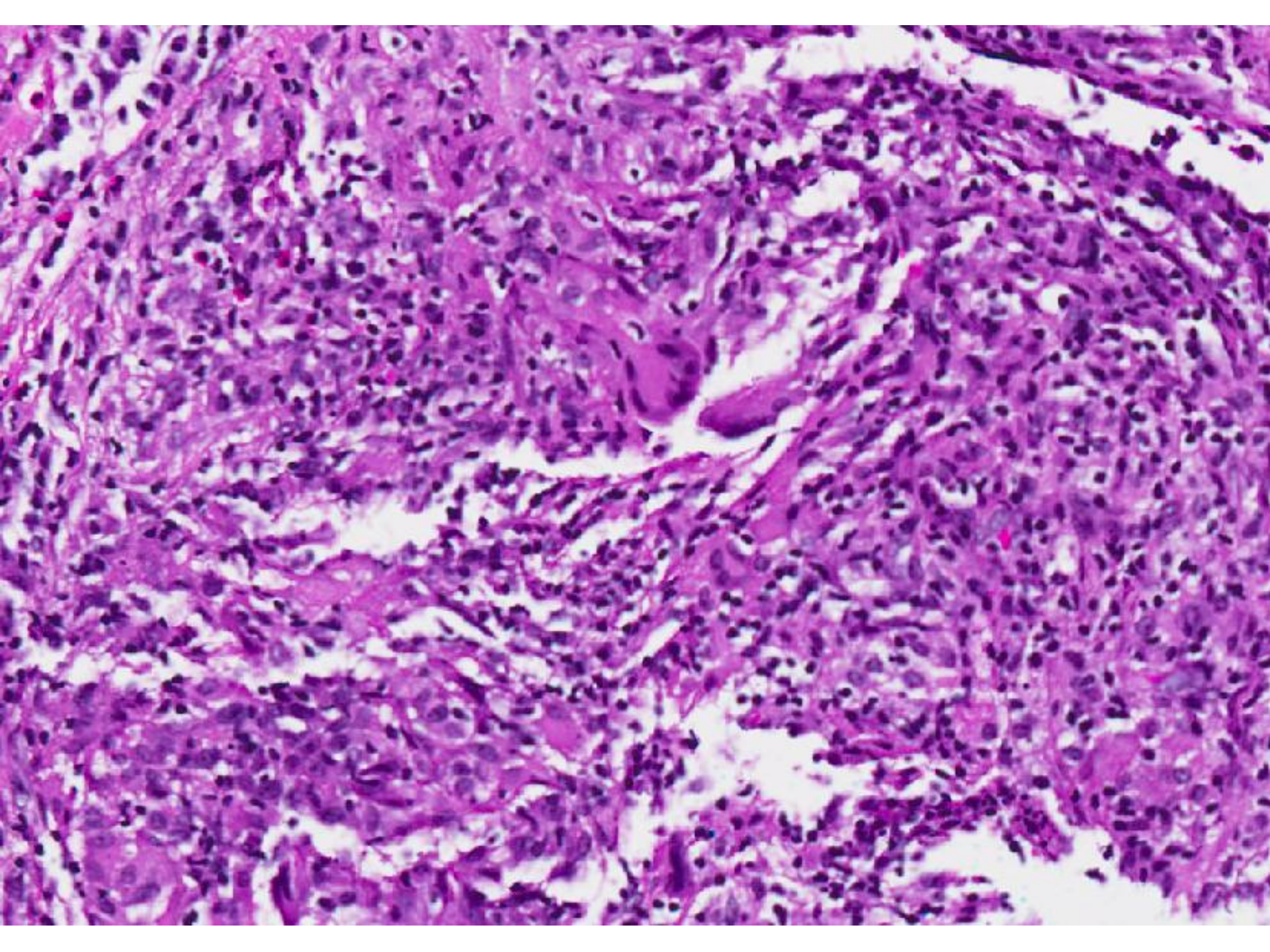




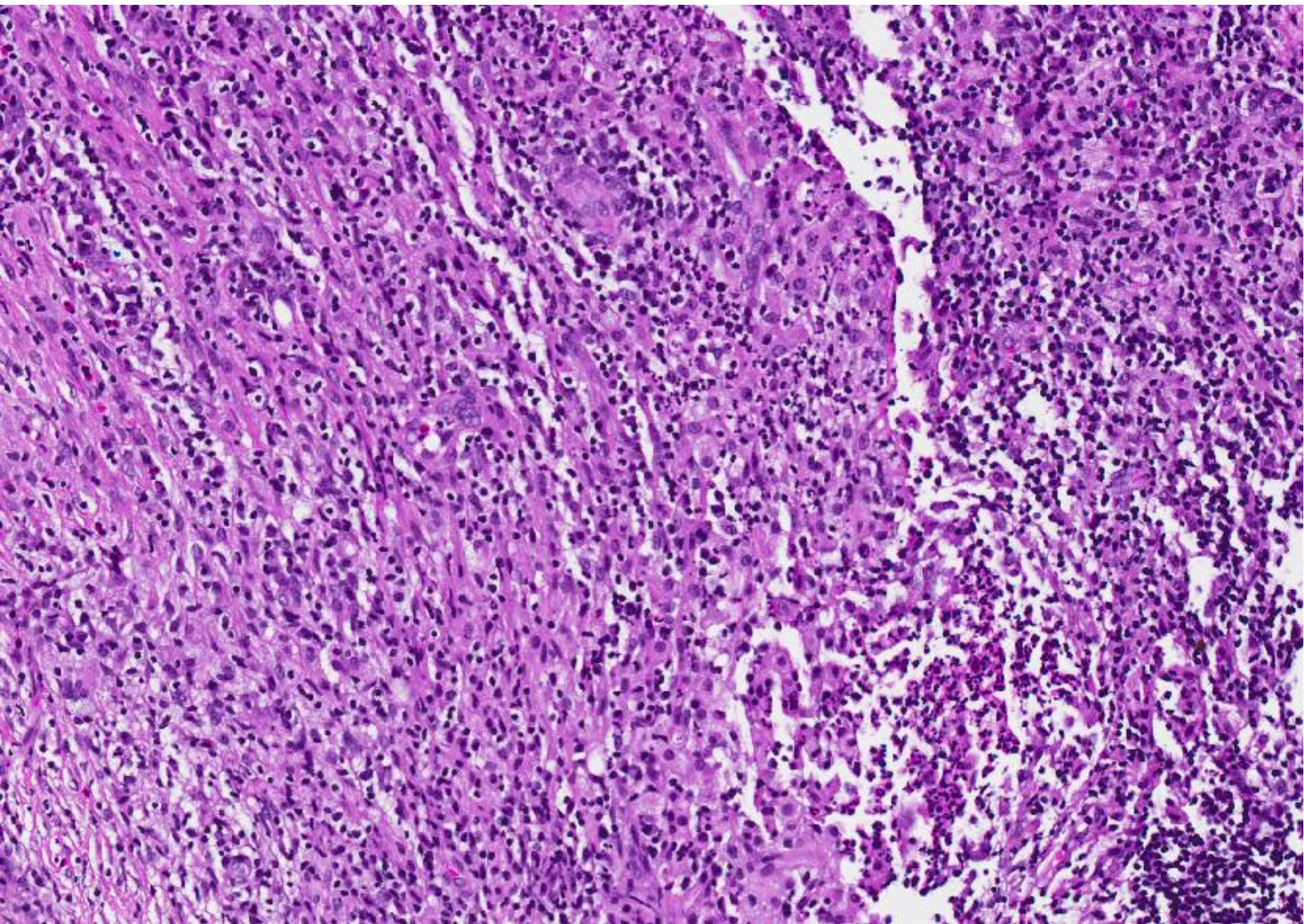














# Diagnosis

- Lactational hyperplasia.
- Acute on chronic inflammation with granulomatous component.



# Granulomatous inflammation in the breast

- Infective.
- Duct ectasia.
- Autoimmune.
- Fat necrosis.
- Cancer.
- Idiopathic.