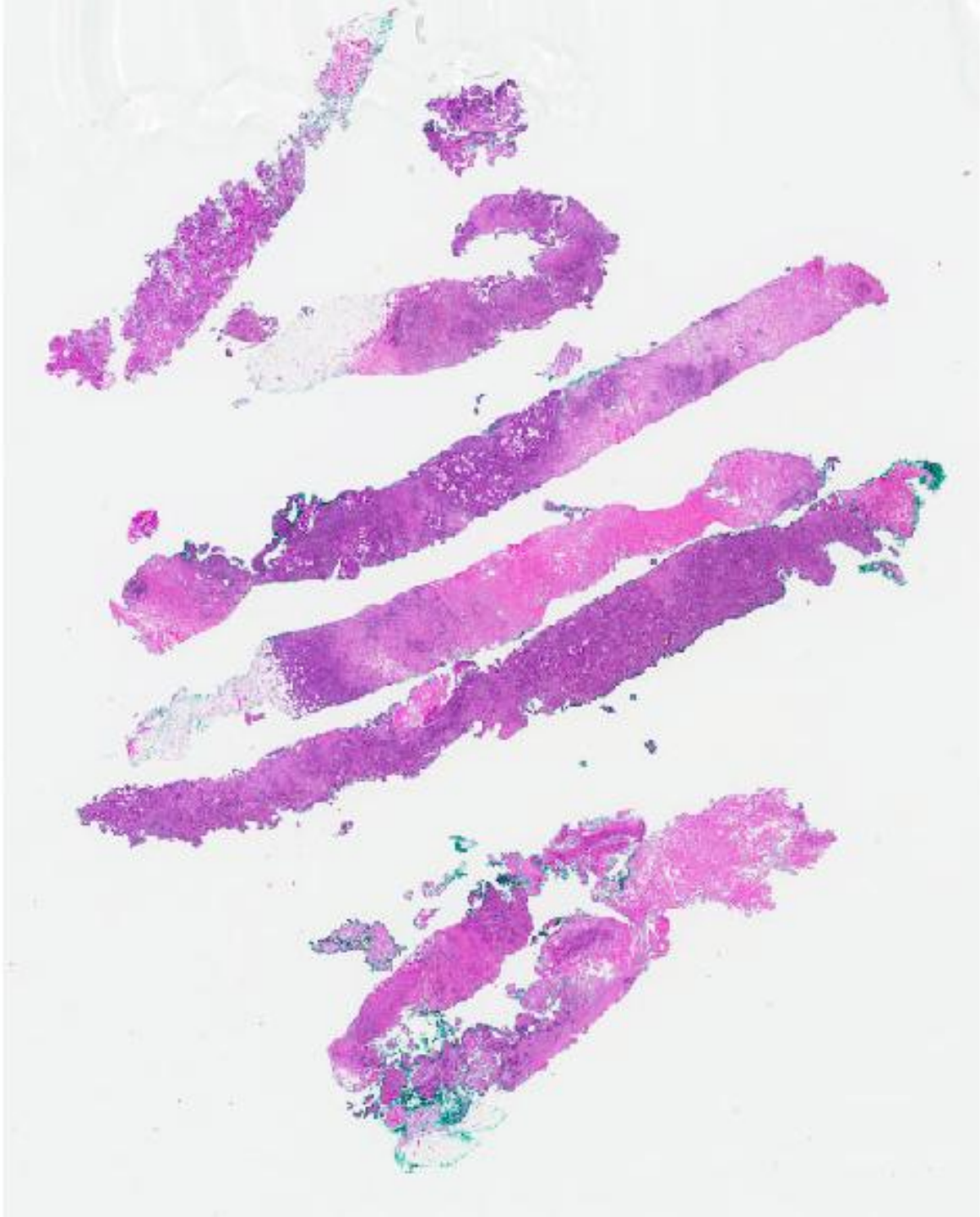
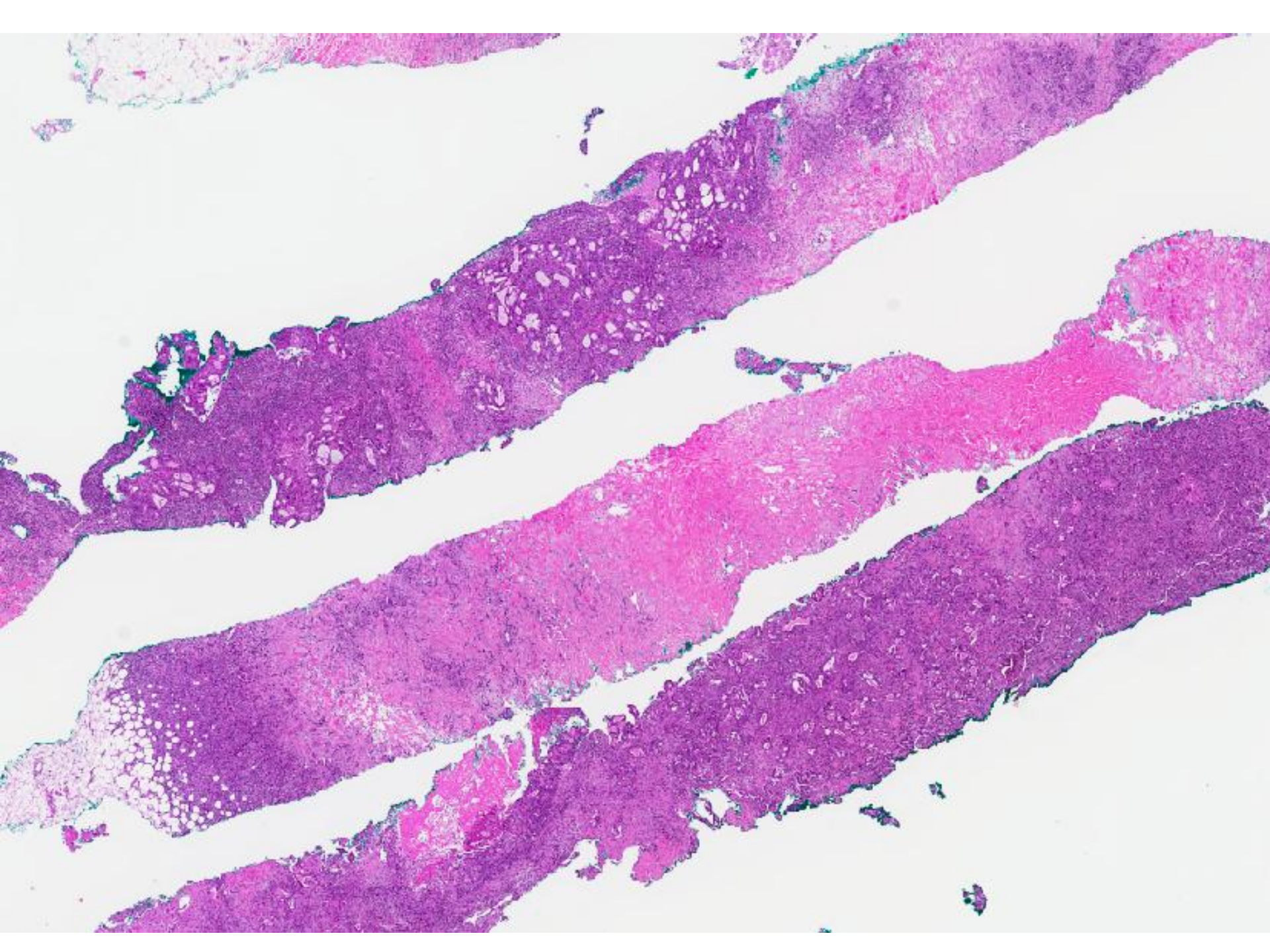
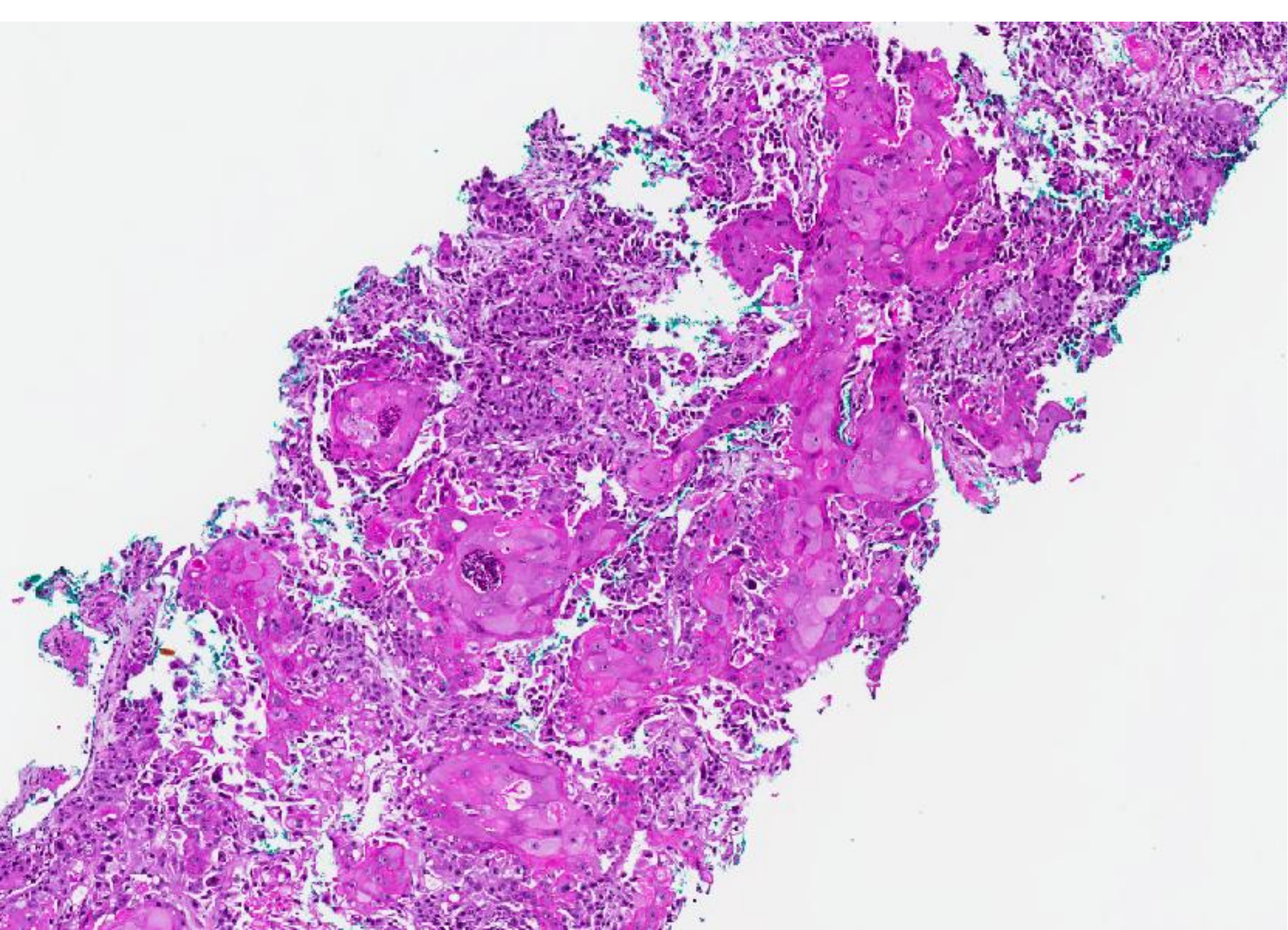


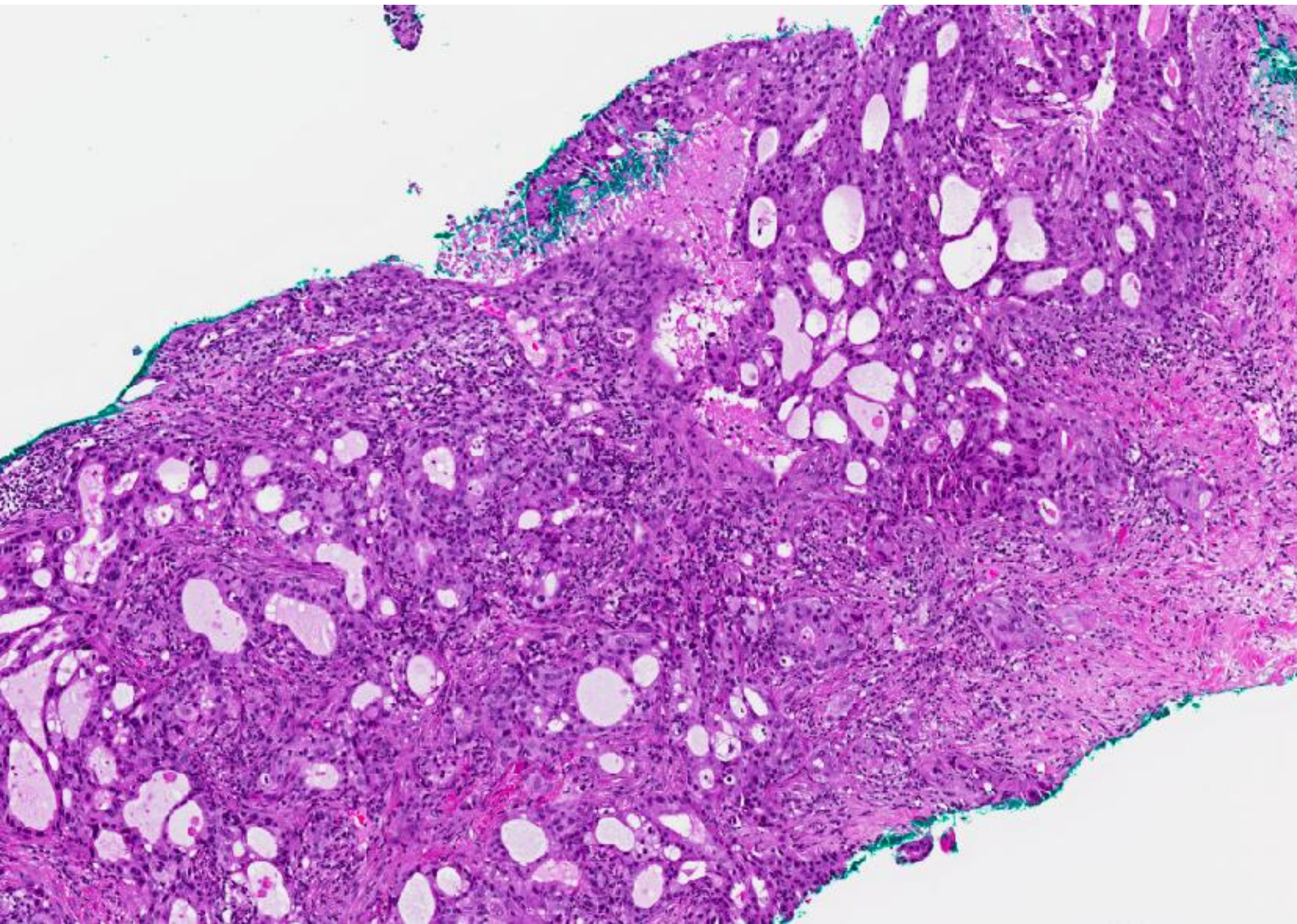
CASE 17

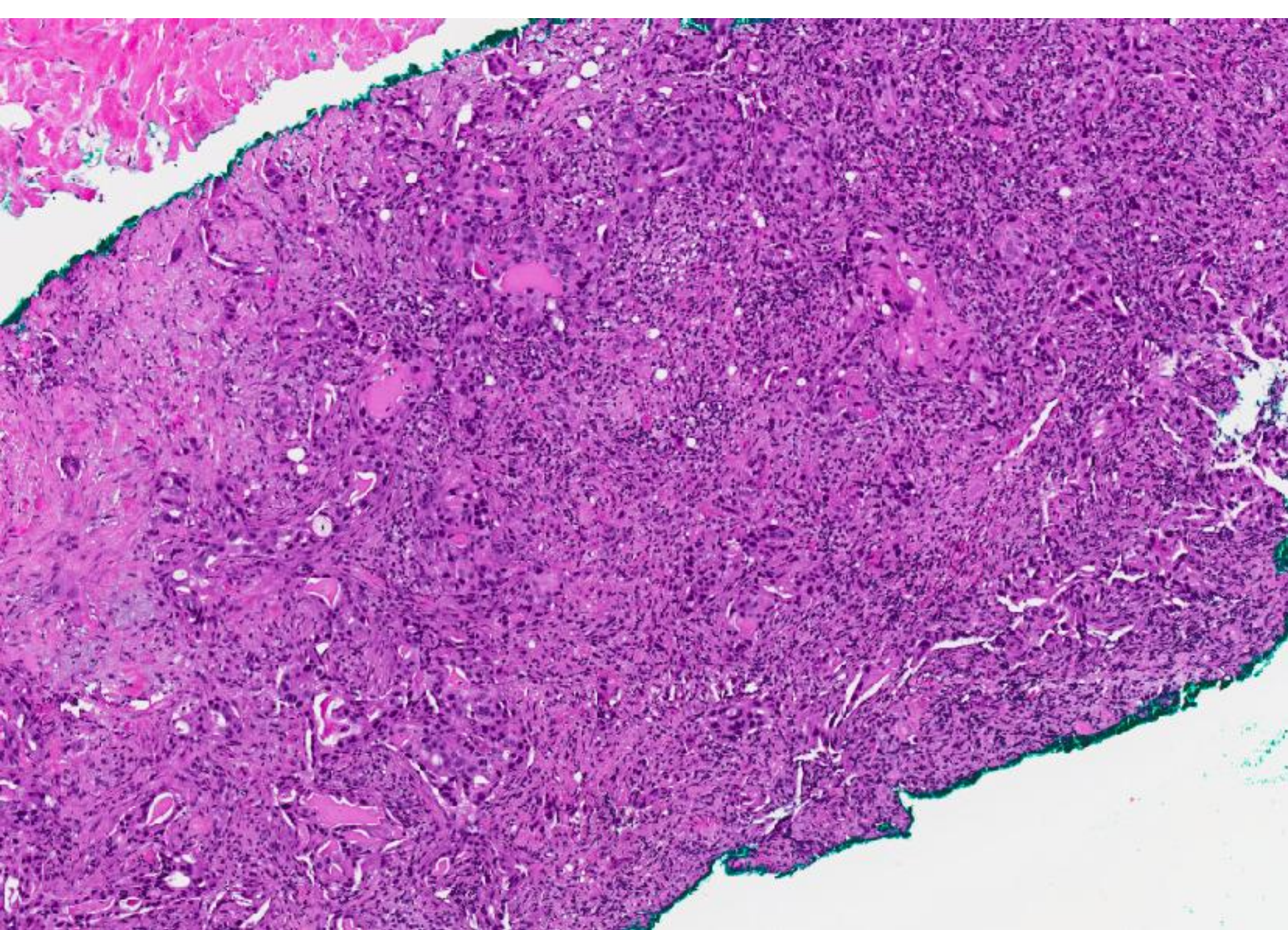
79 year old Chinese lady presented with a left breast mass. A trucut core biopsy was performed.

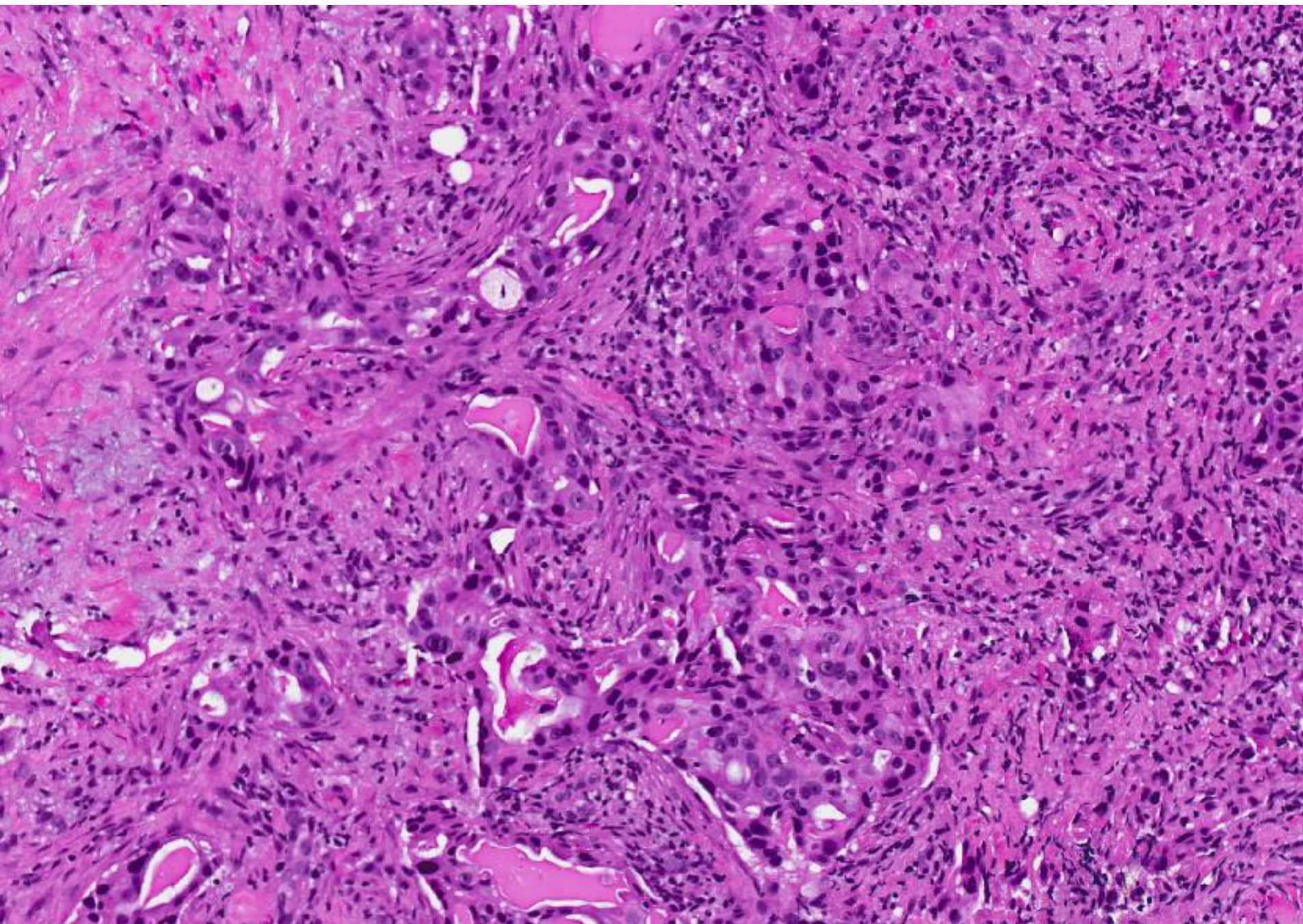


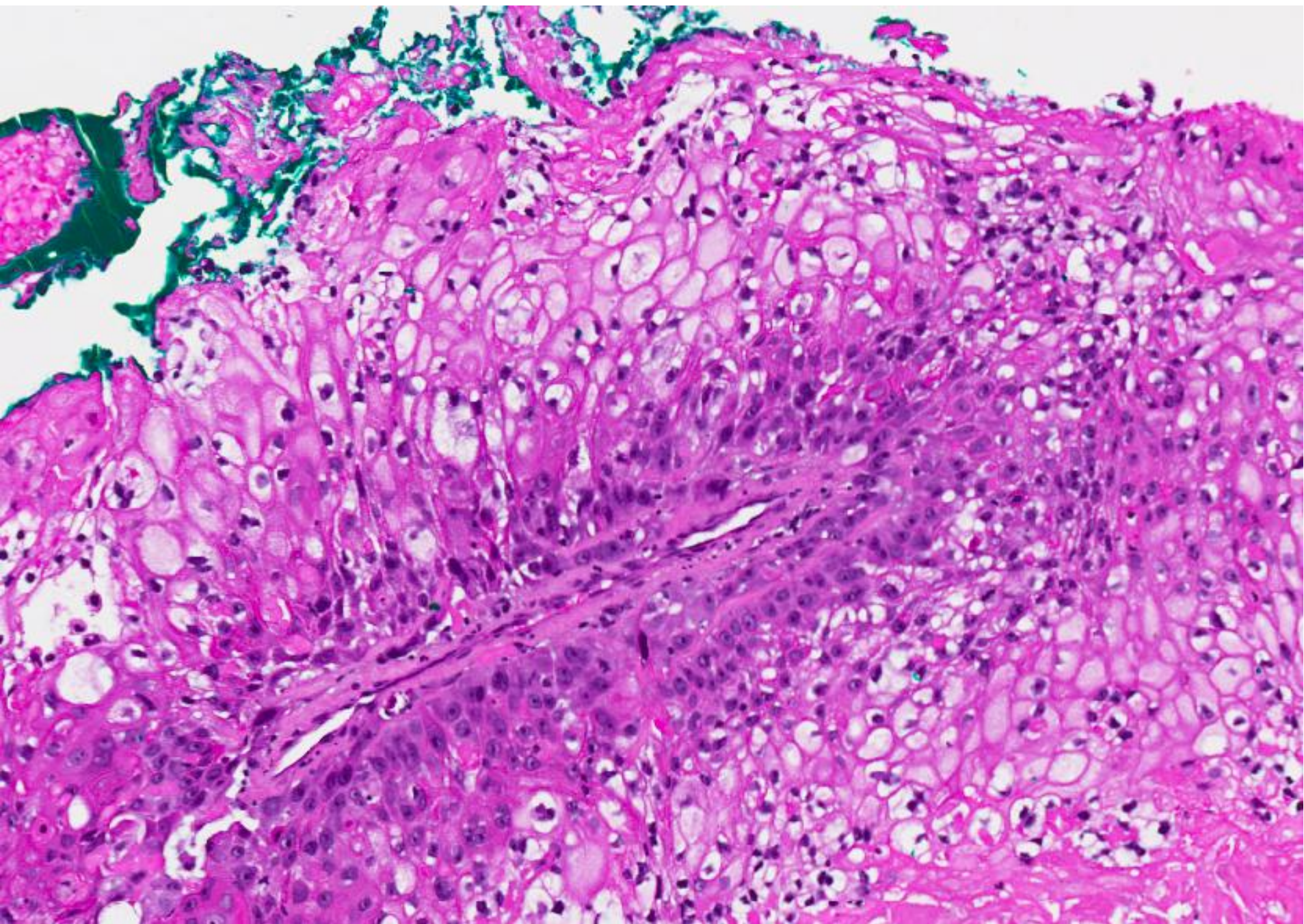


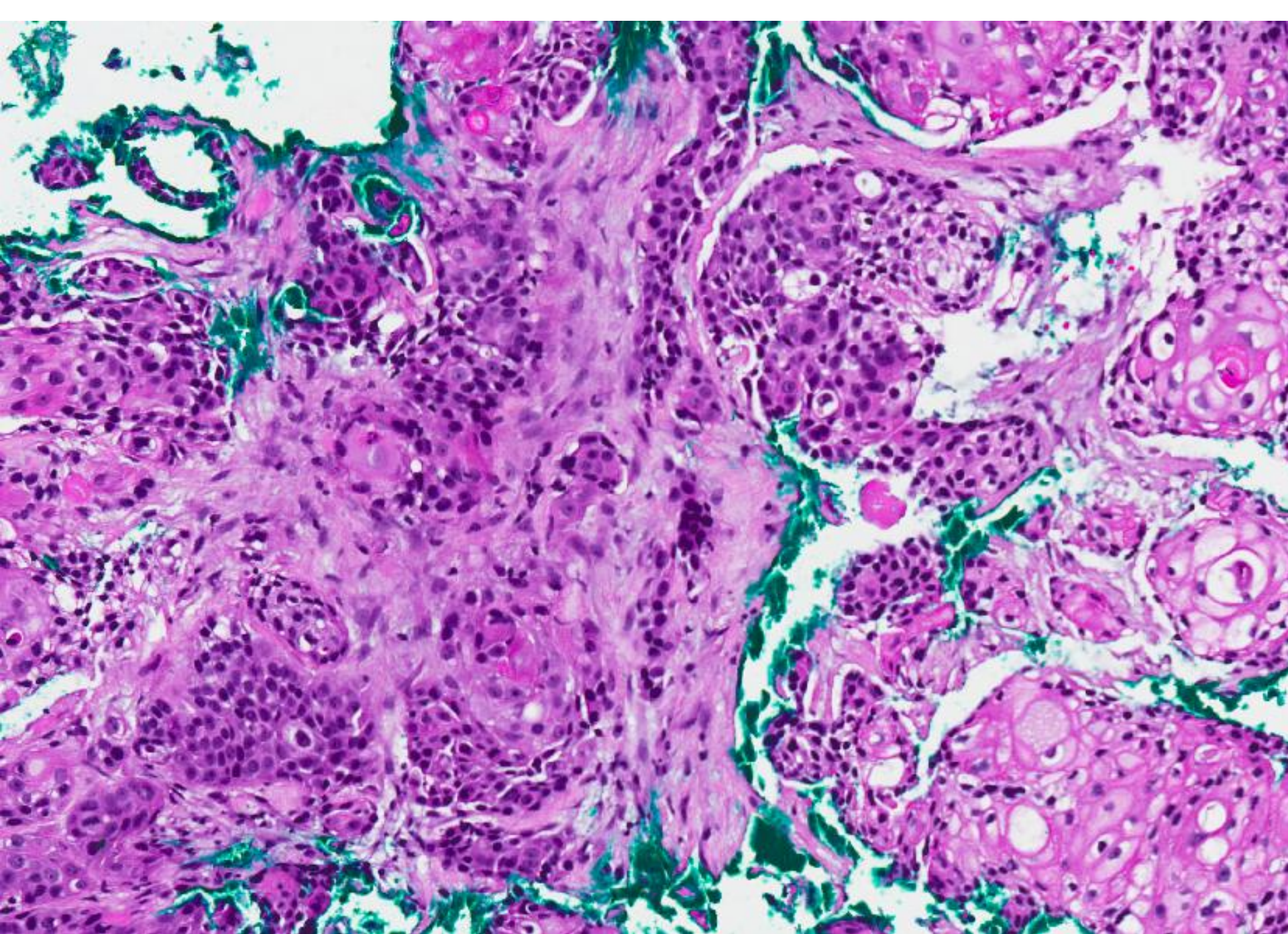












Diagnosis

- Invasive carcinoma with squamous metaplasia (metaplastic carcinoma).