

## CASE 13

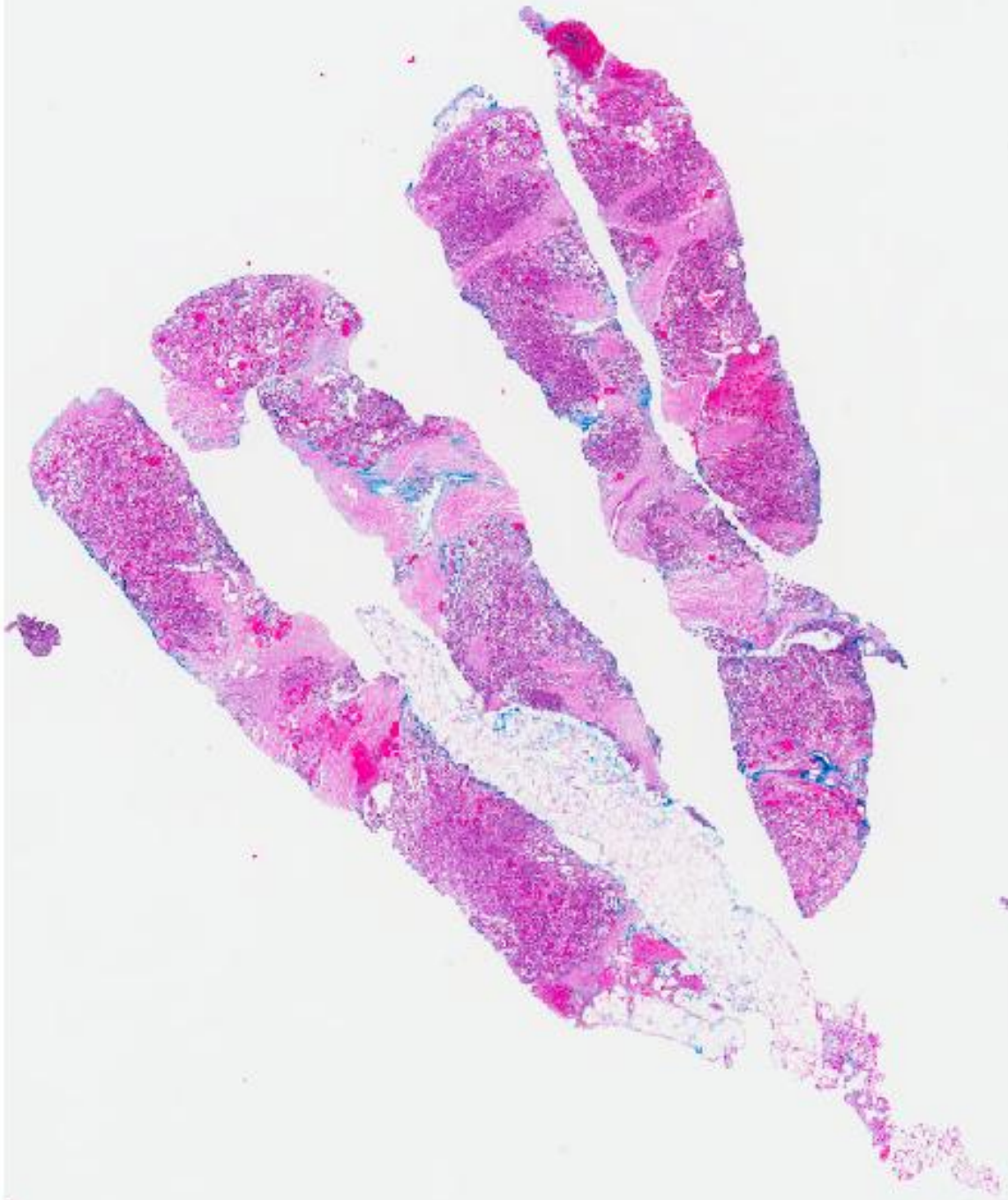
64 year old Chinese lady presented with a right breast lump at the 6 o'clock position.

An ultrasound guided trucut biopsy was performed.

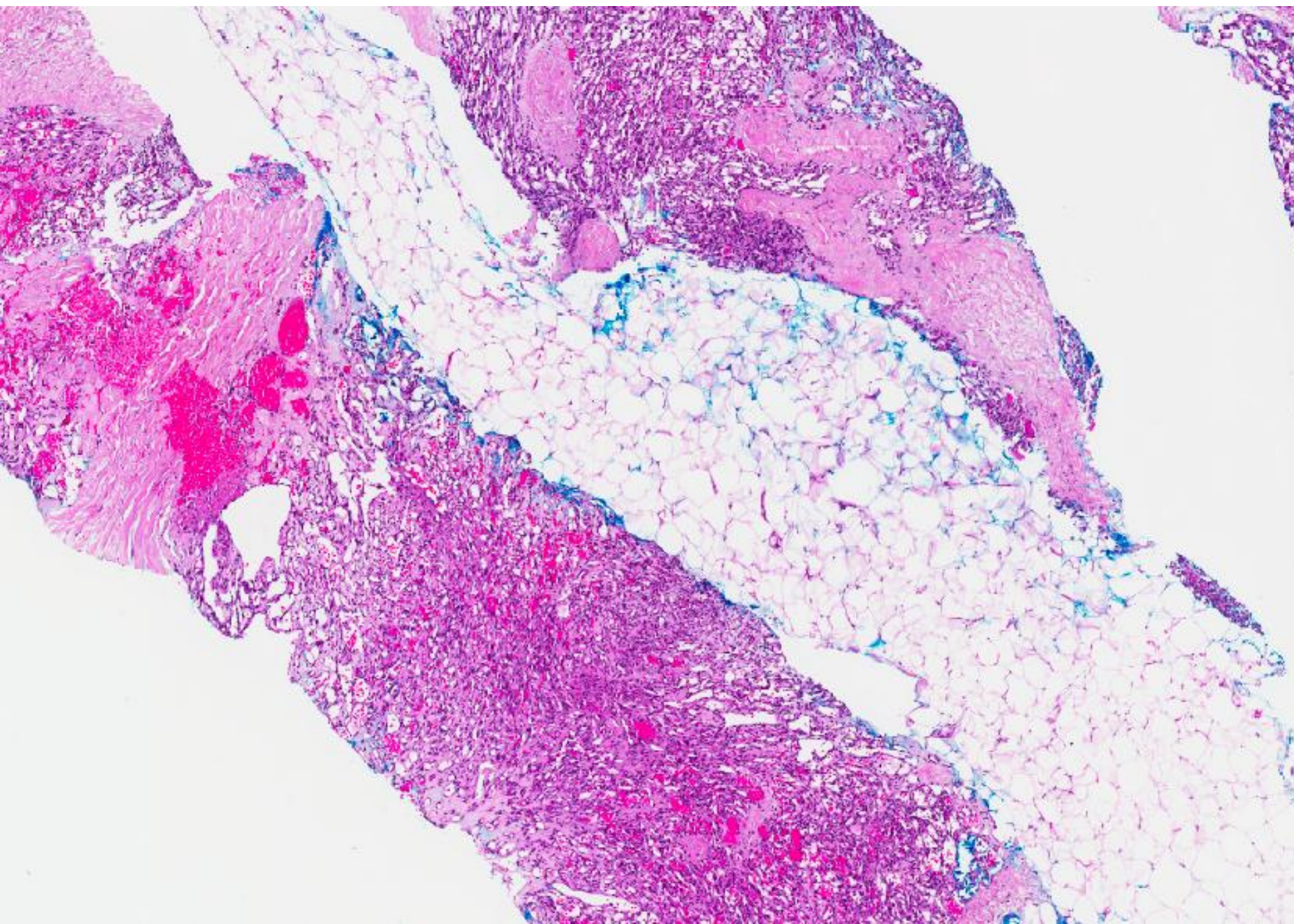
This was followed by surgical excision a week later.

The excised specimen contained a reddish brown nodule 1.4 cm in maximum dimension.

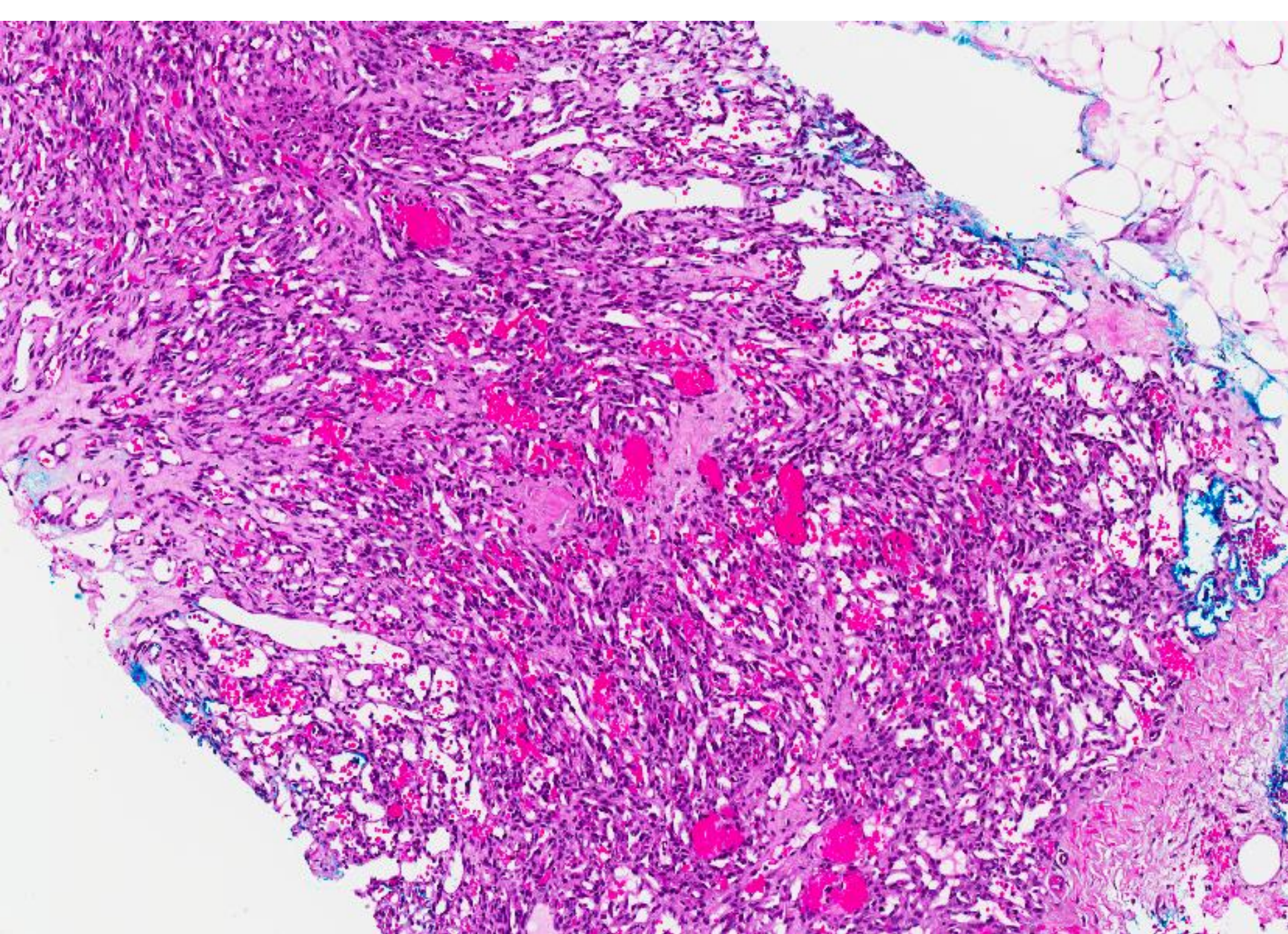
Trucut biopsy



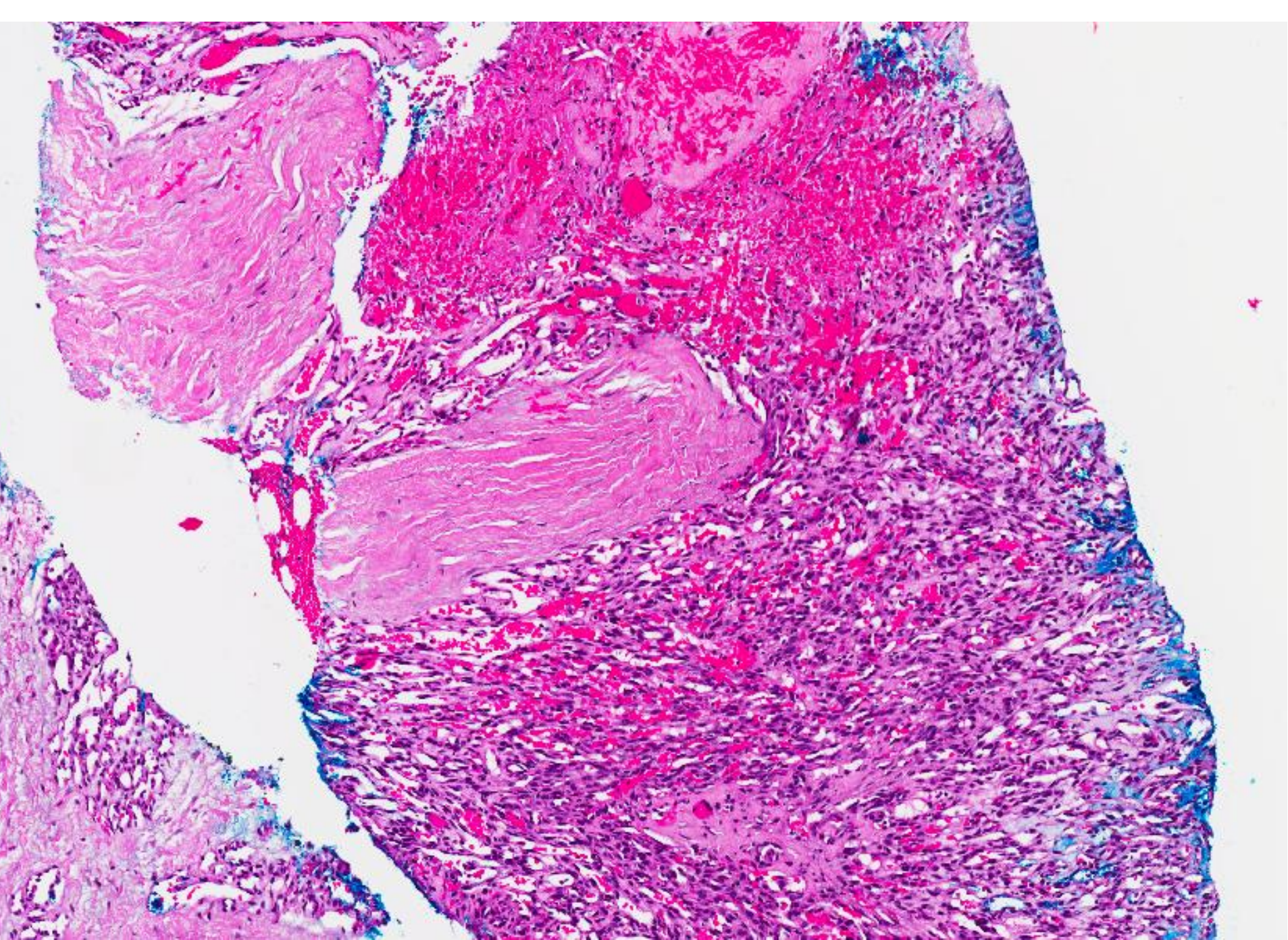




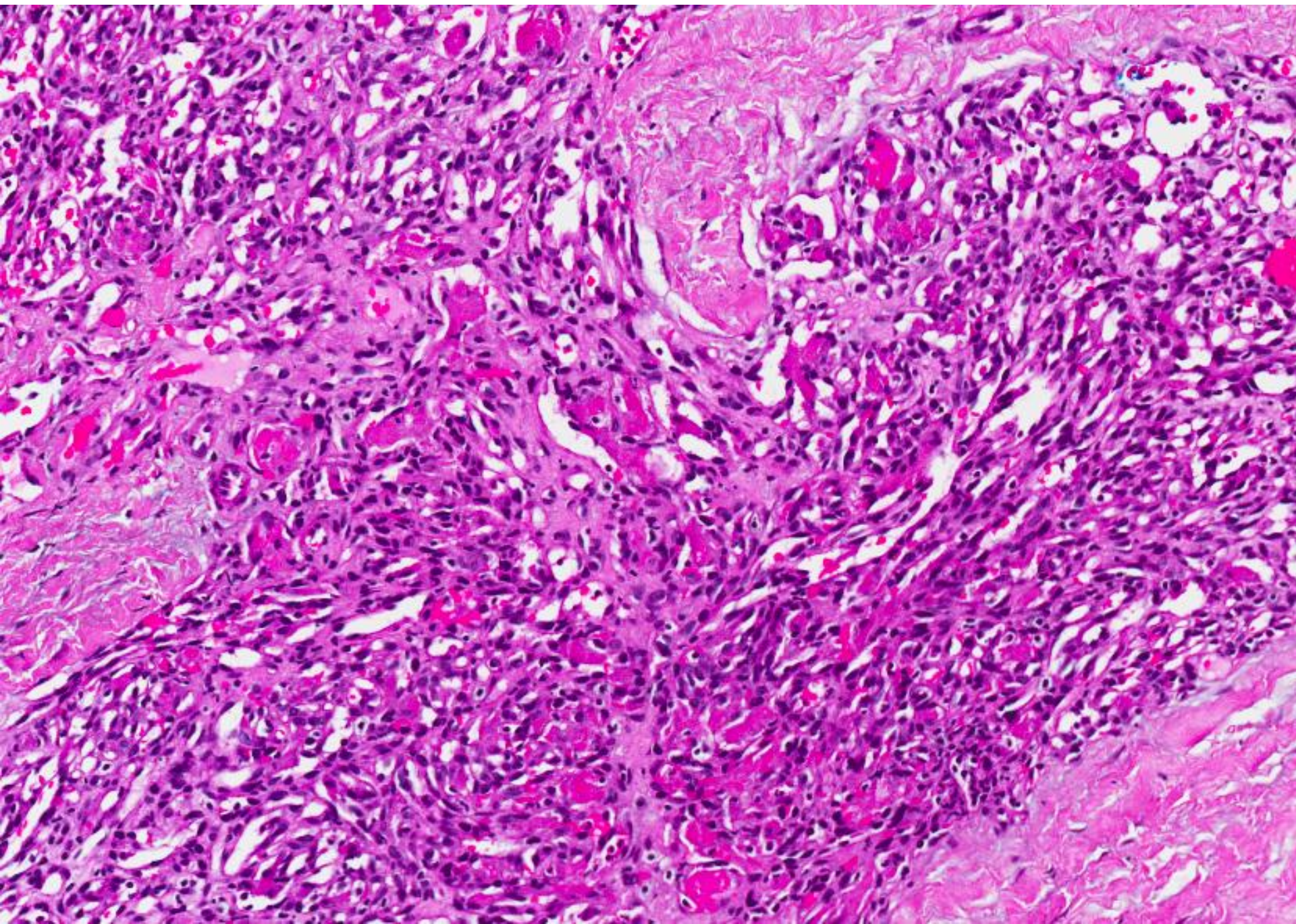




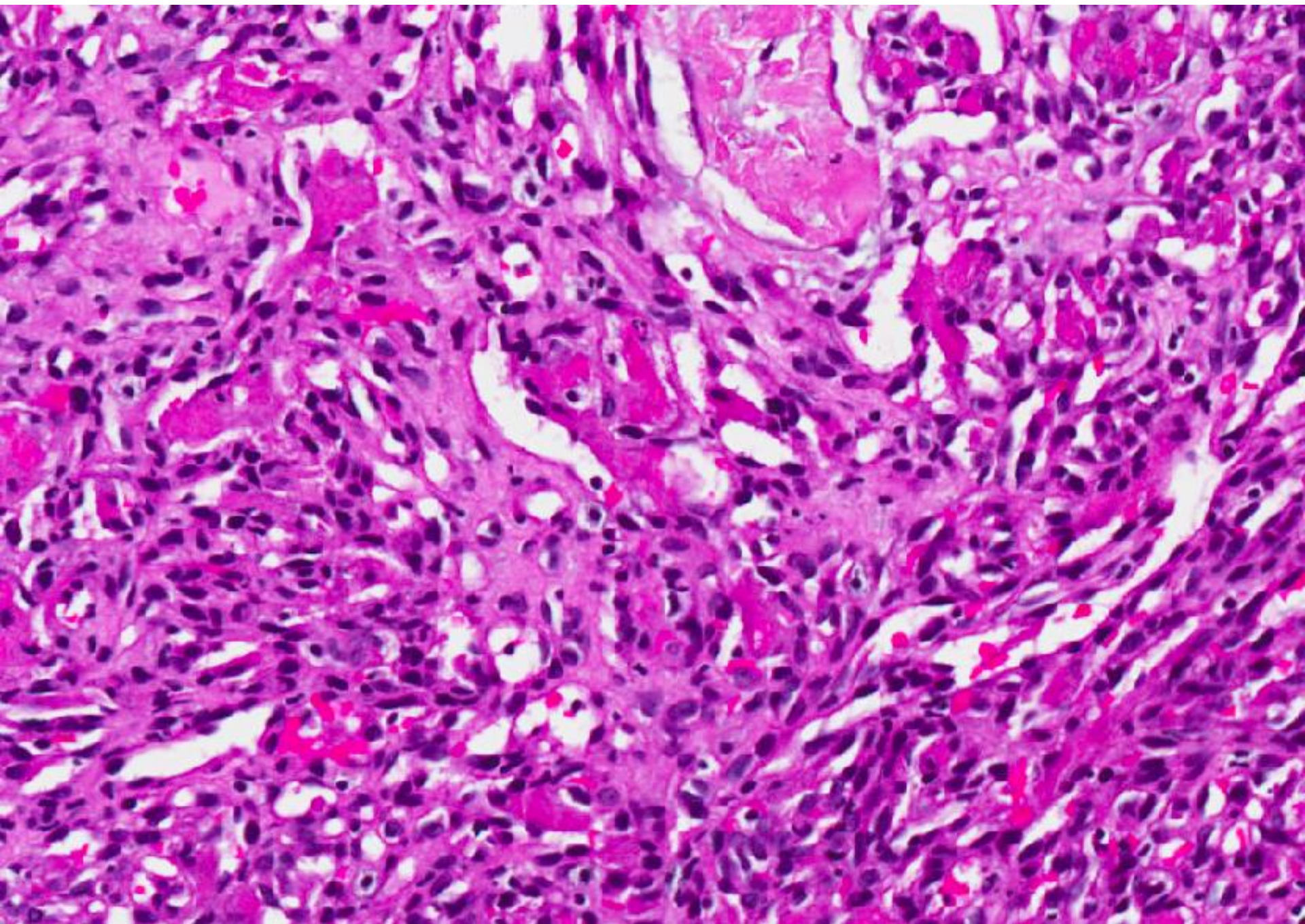














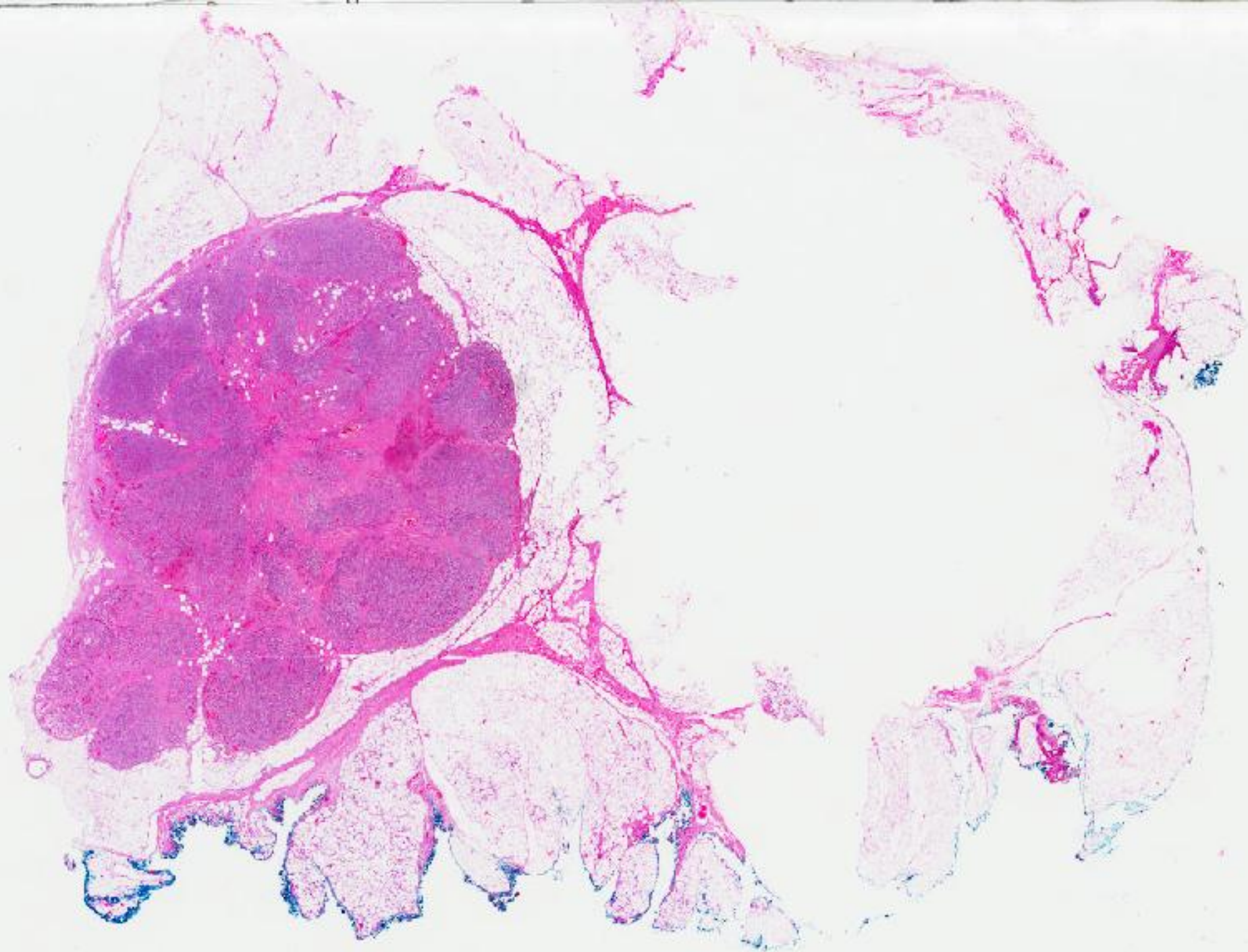
# Diagnosis

- Trucut biopsy: Vasoformative lesion, suggestive of a haemangioma.

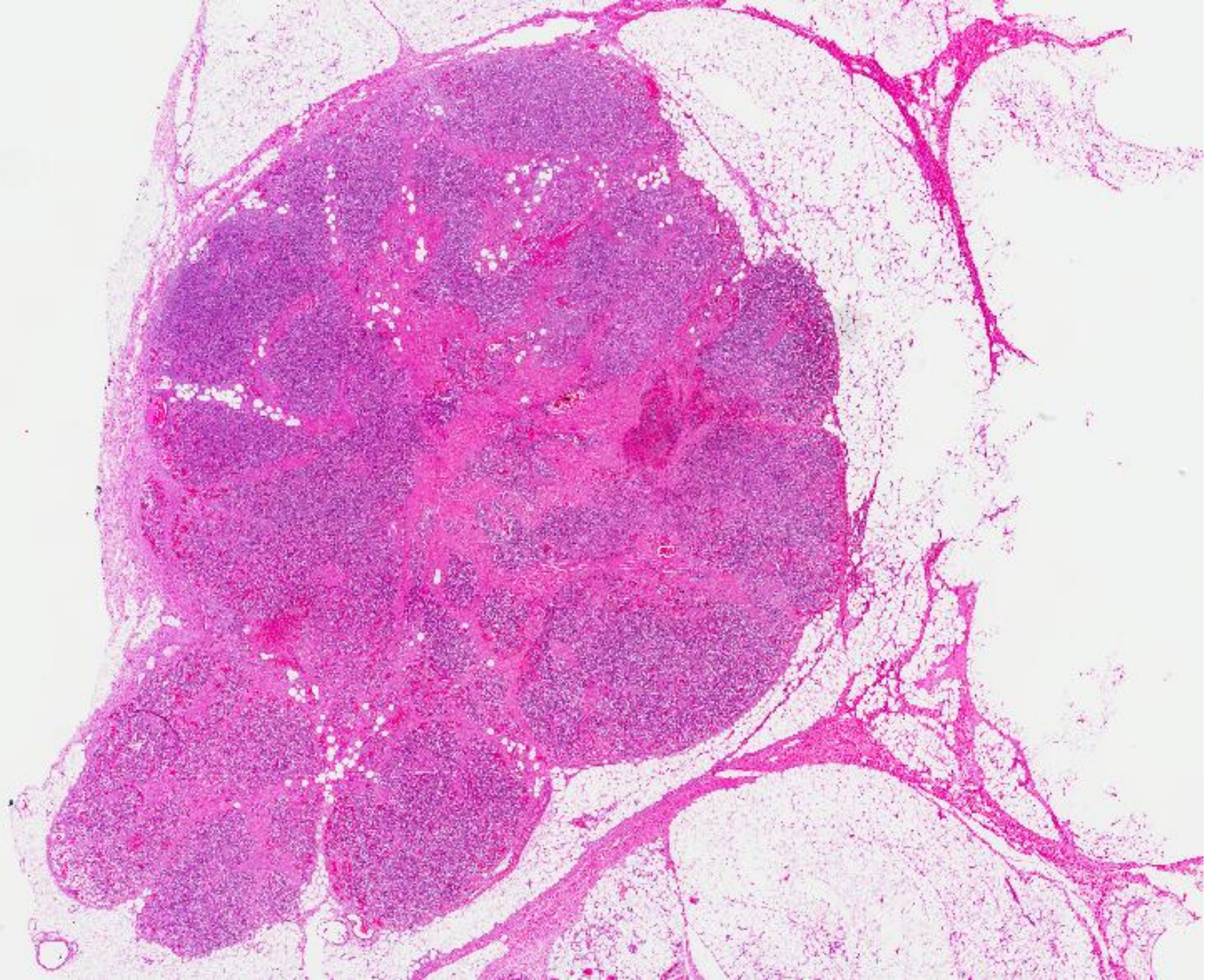


Excision biopsy

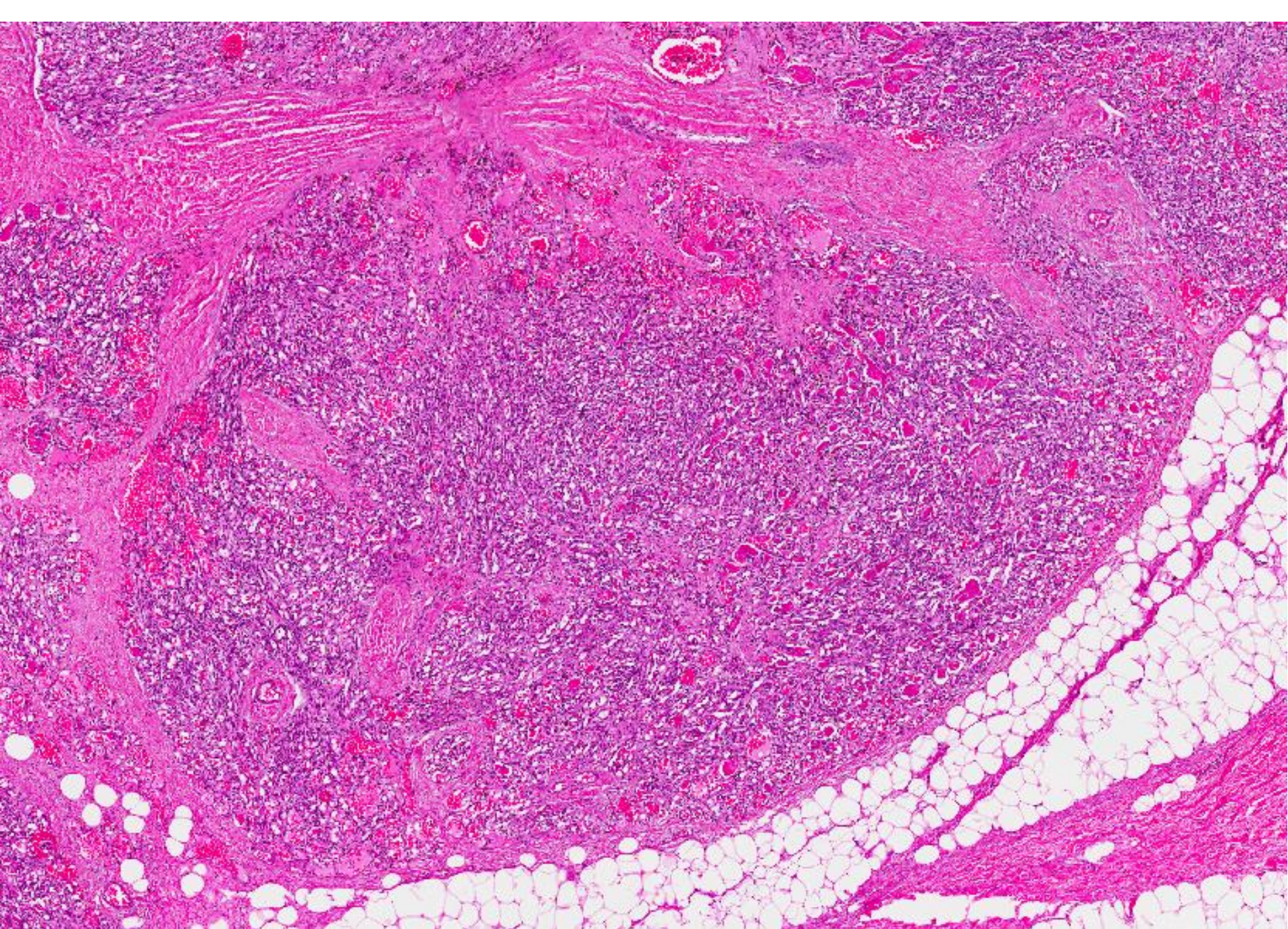




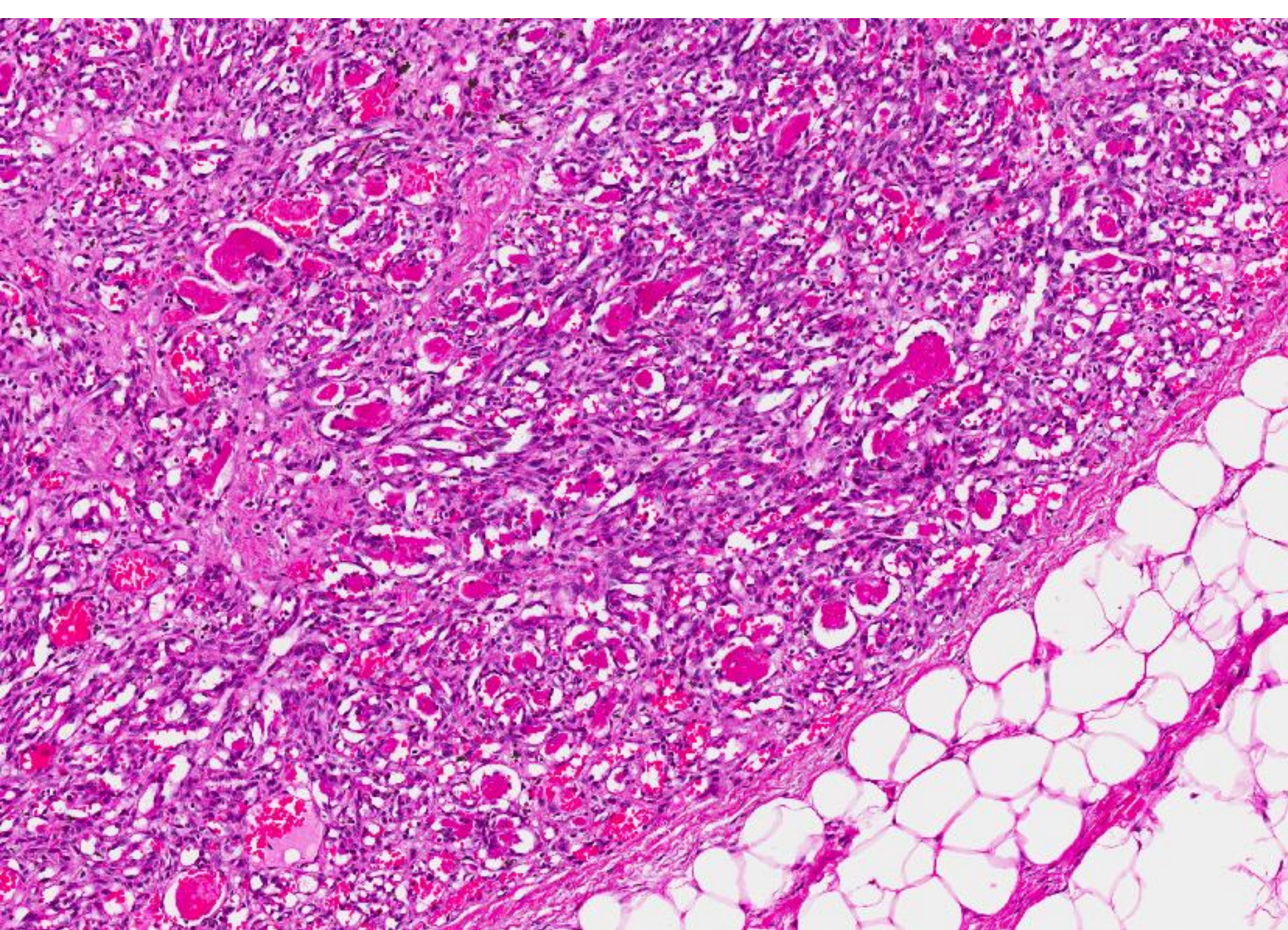




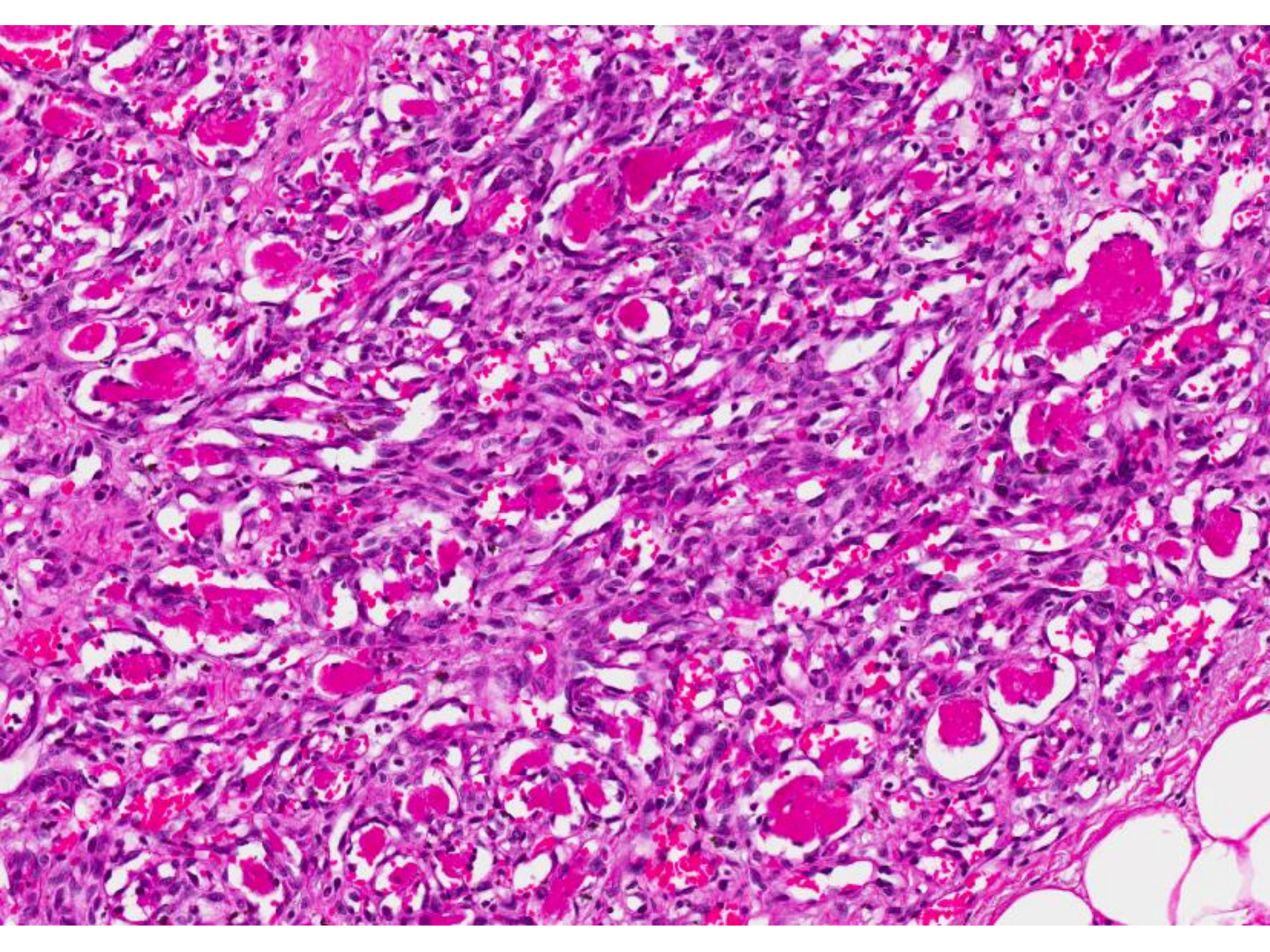




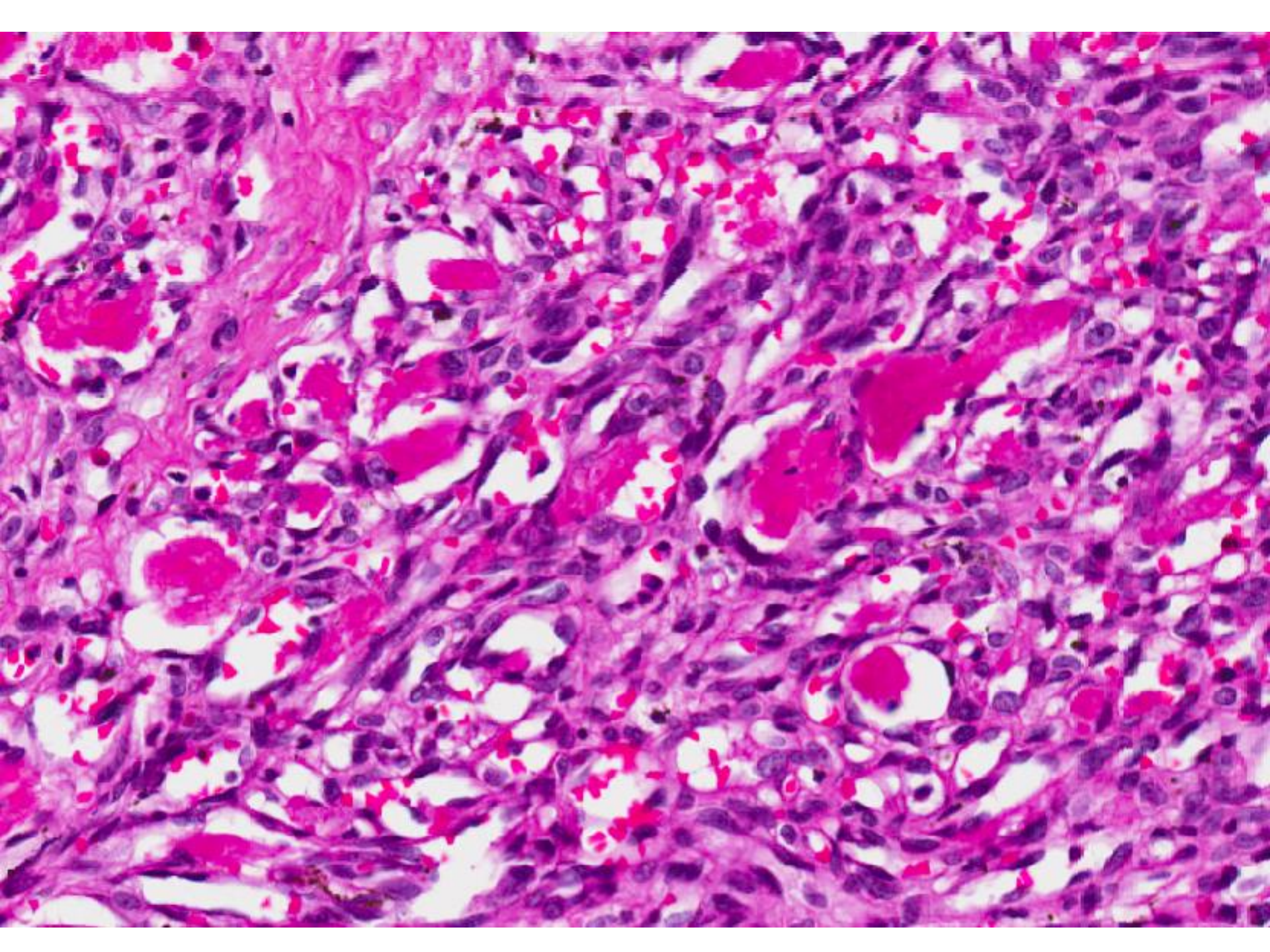














# Diagnosis

- Cellular angiolipoma.



# Cellular angioliipoma

- Can mimic angiosarcoma.
- Clues to benign nature:
  - Good circumscription.
  - Lack of significant endothelial cytologic atypia.
  - Mitotically inert.
  - Absence of anastomosing vascular channels.
  - Absence of necrosis.