

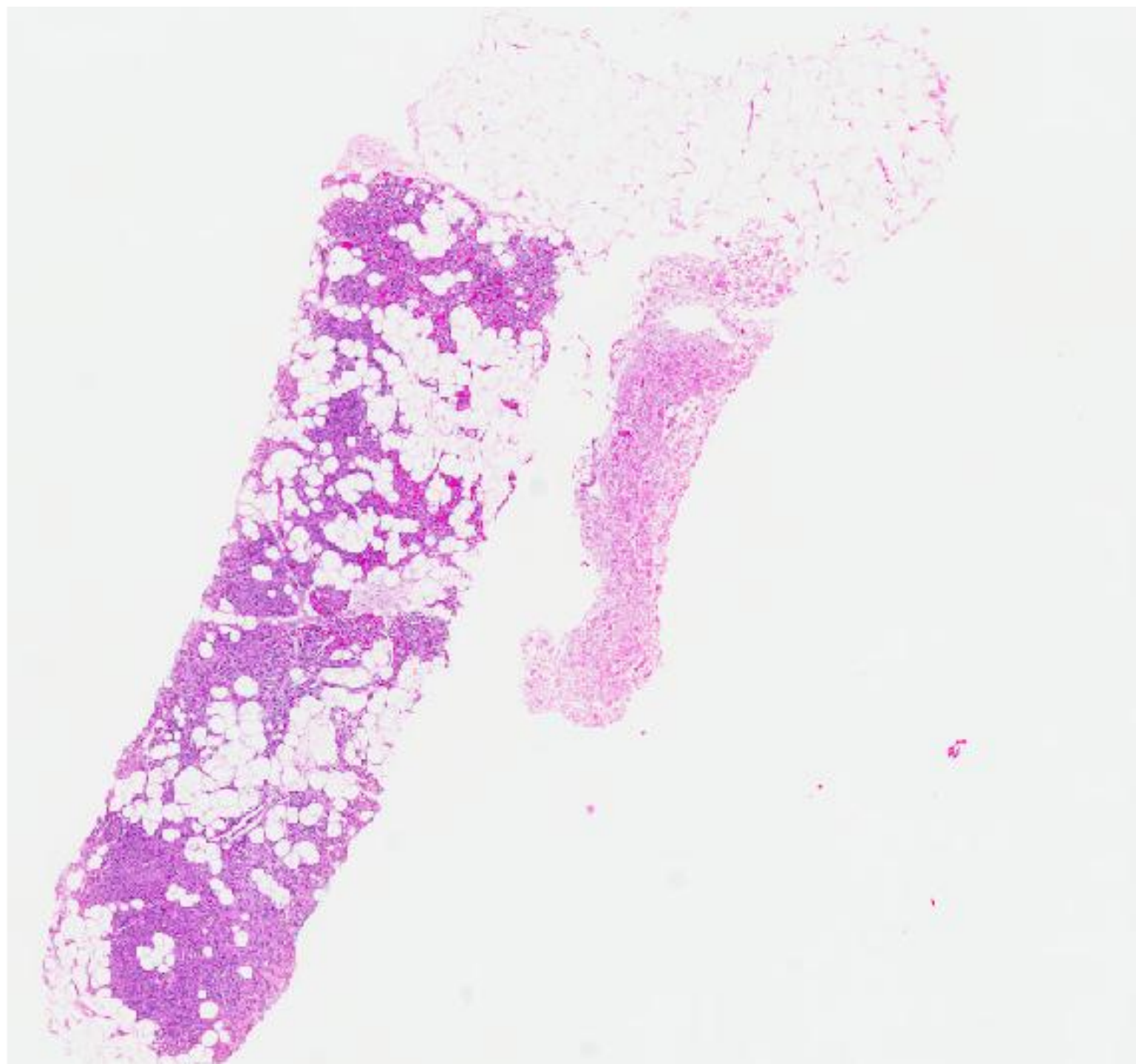
## CASE 12

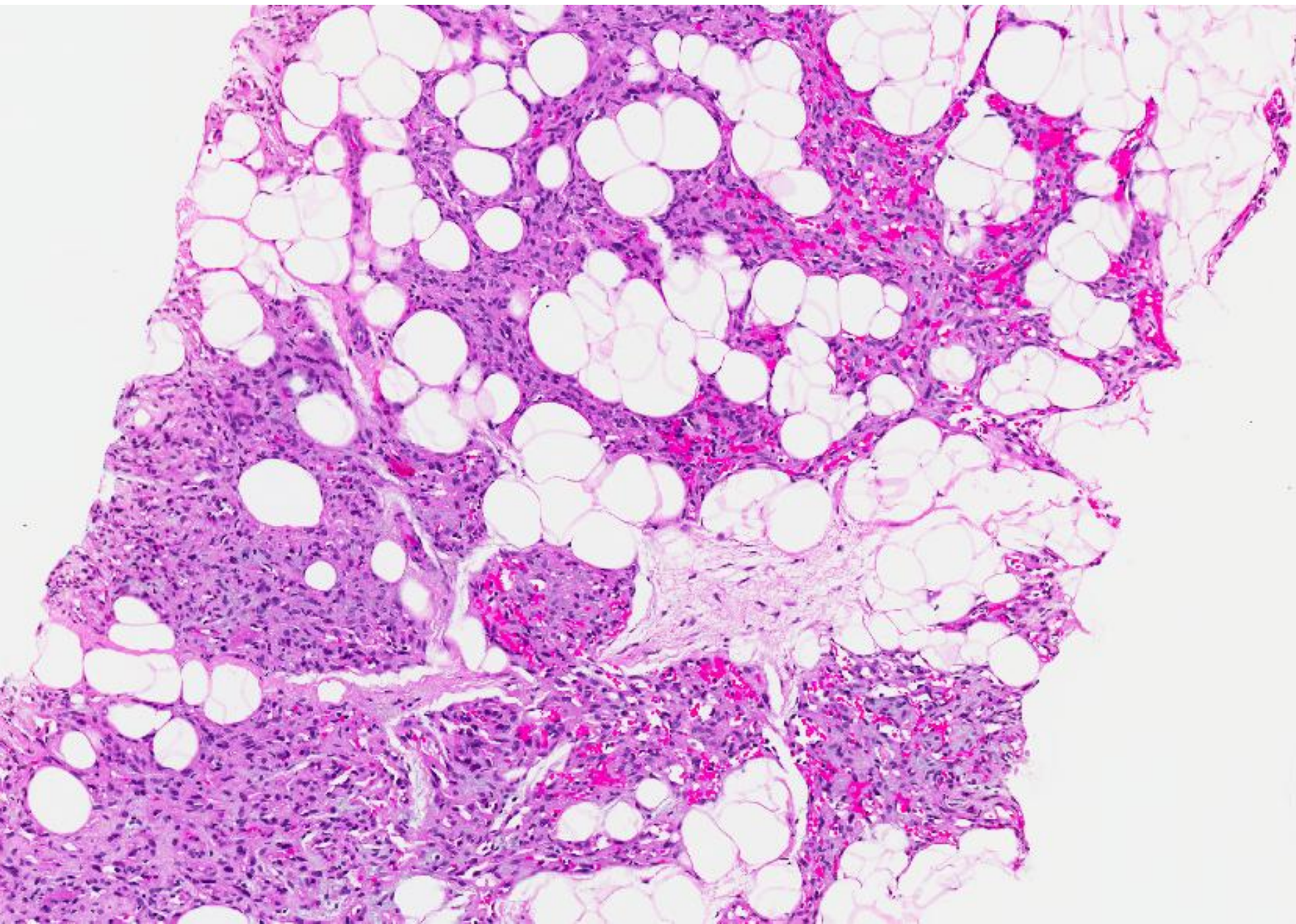
74 year old Chinese lady presented with a nodule in the right breast at the 0330 position.

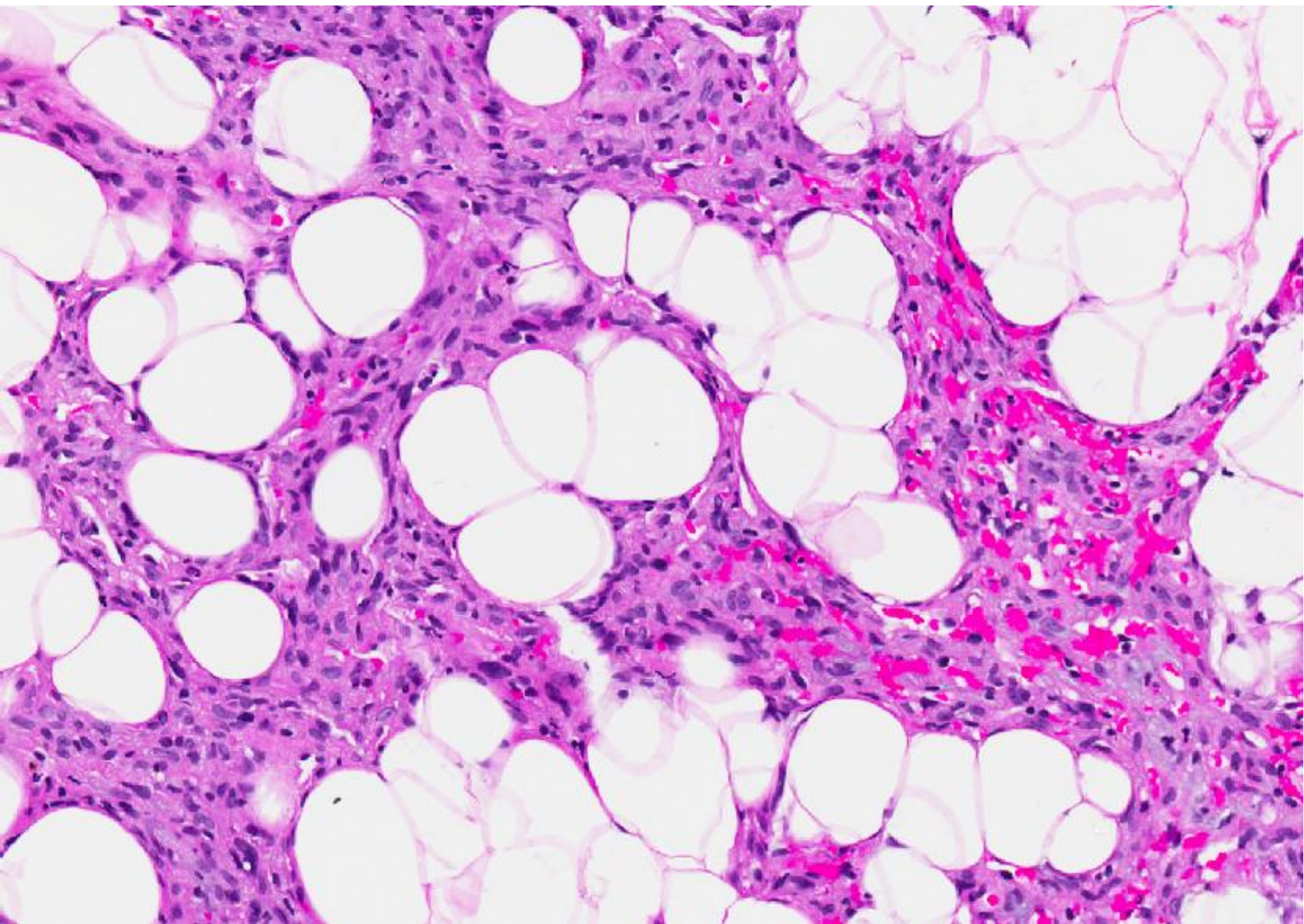
Clinical examination revealed the lump to appear related to the skin and subcutis of the right breast.

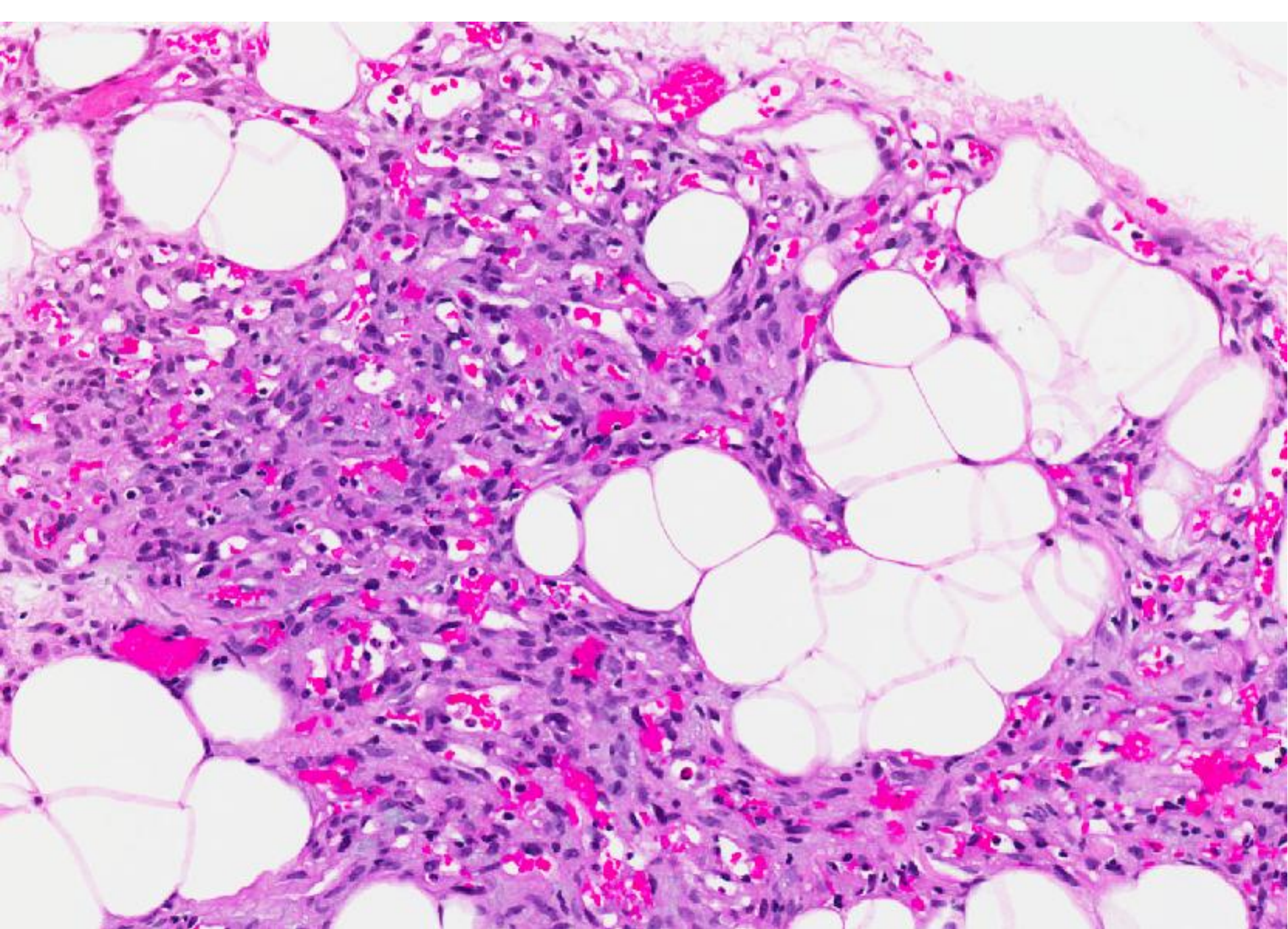
A single core biopsy was performed through the lesion, followed by an excision.

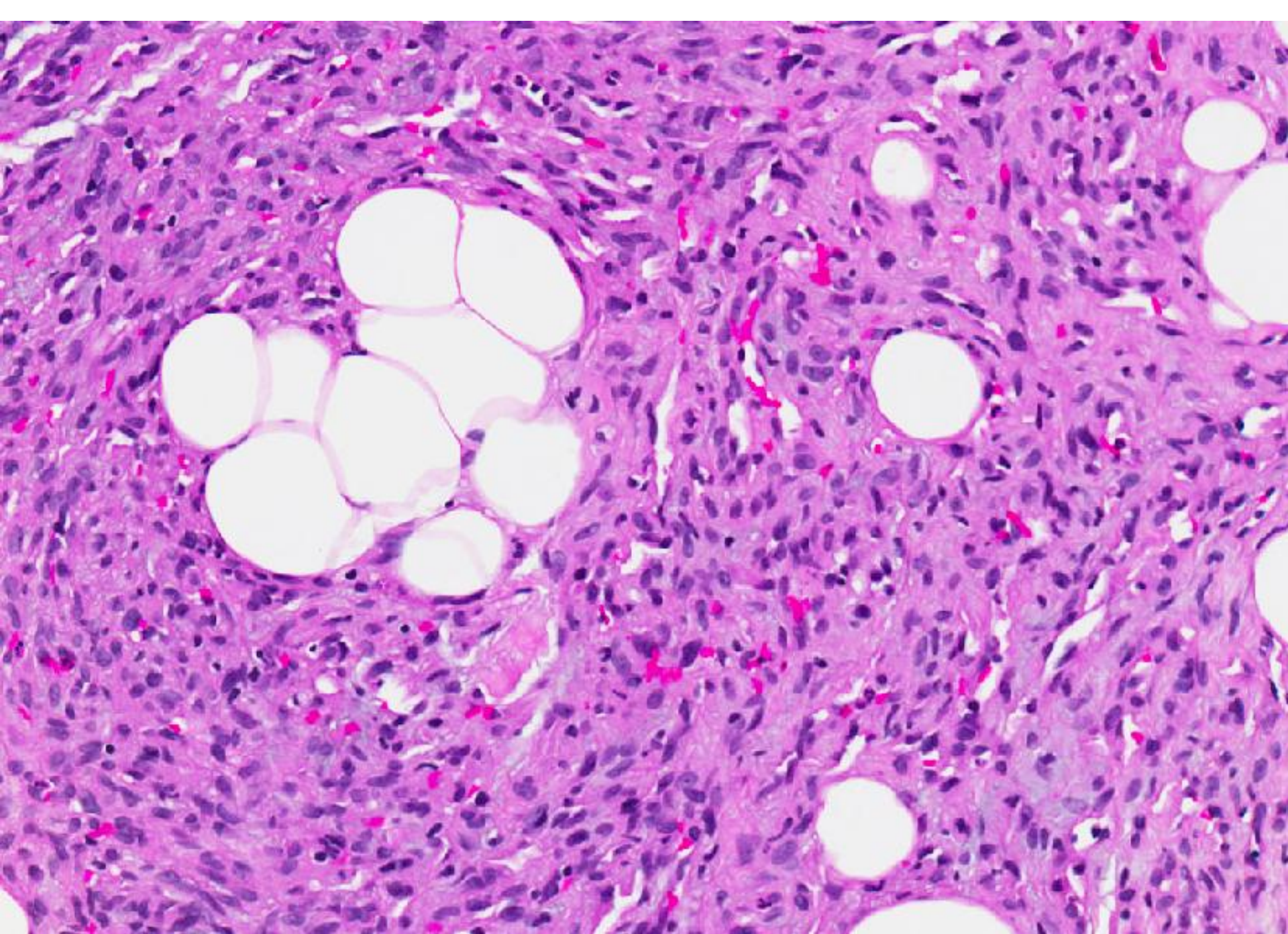
Core biopsy

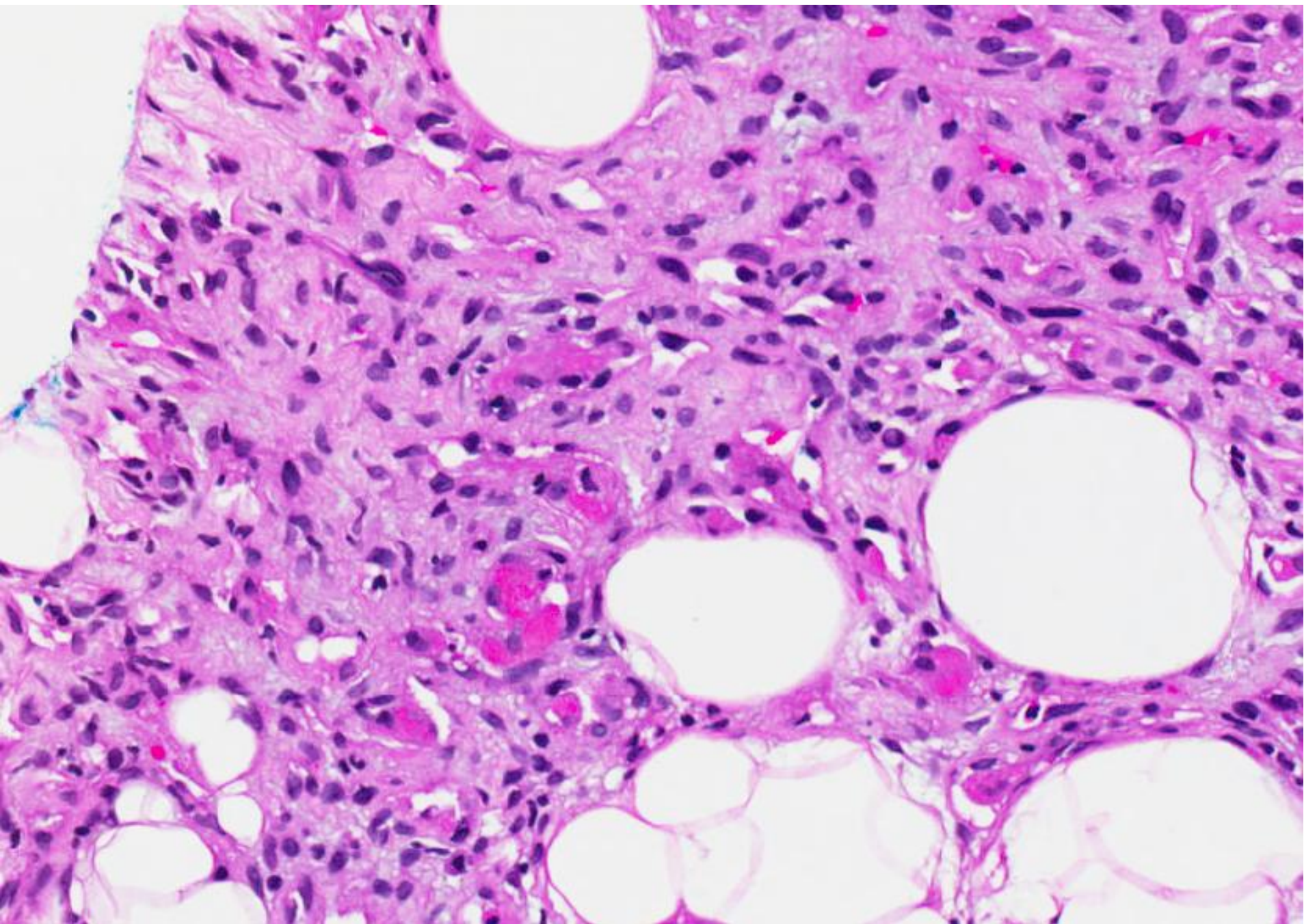










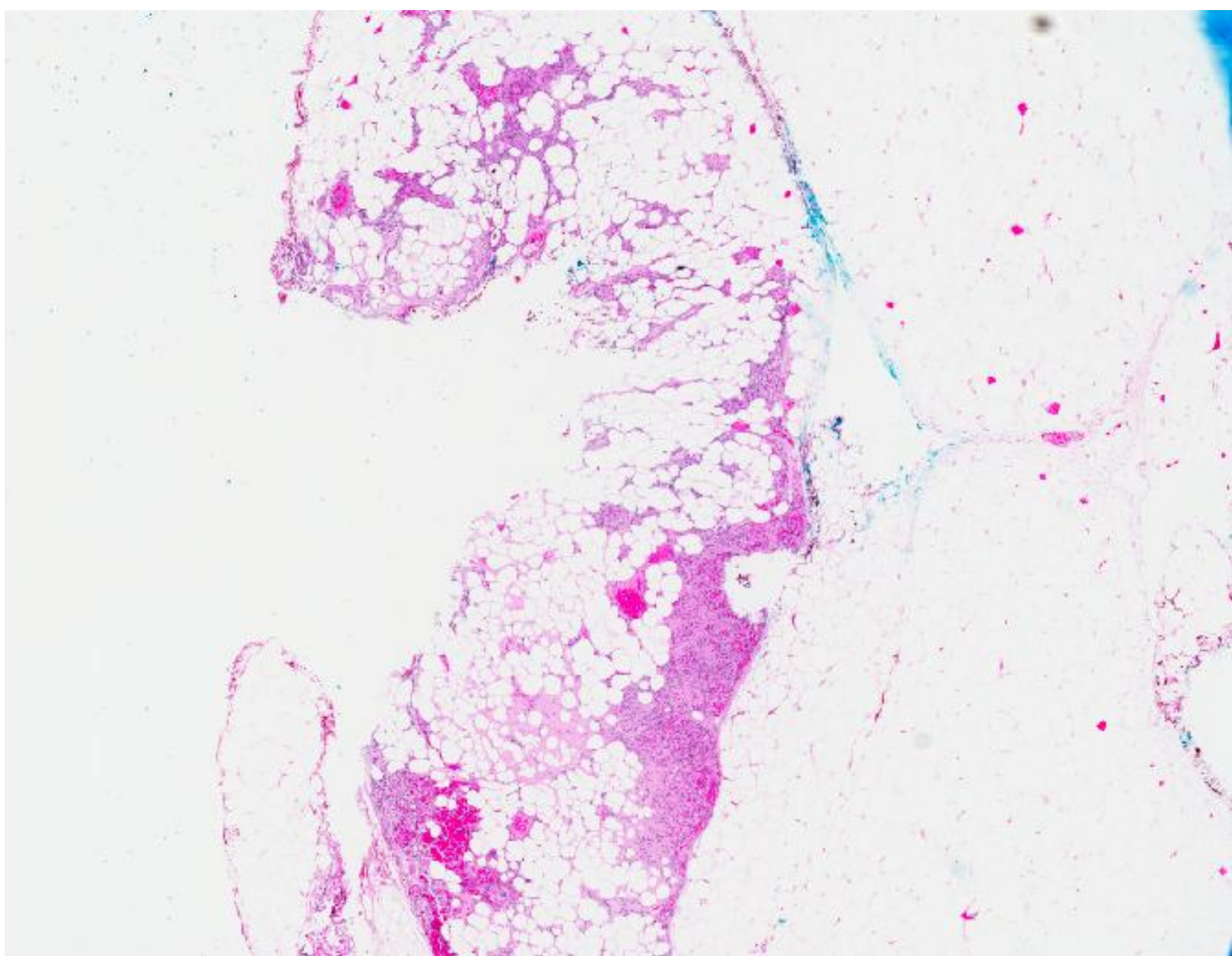


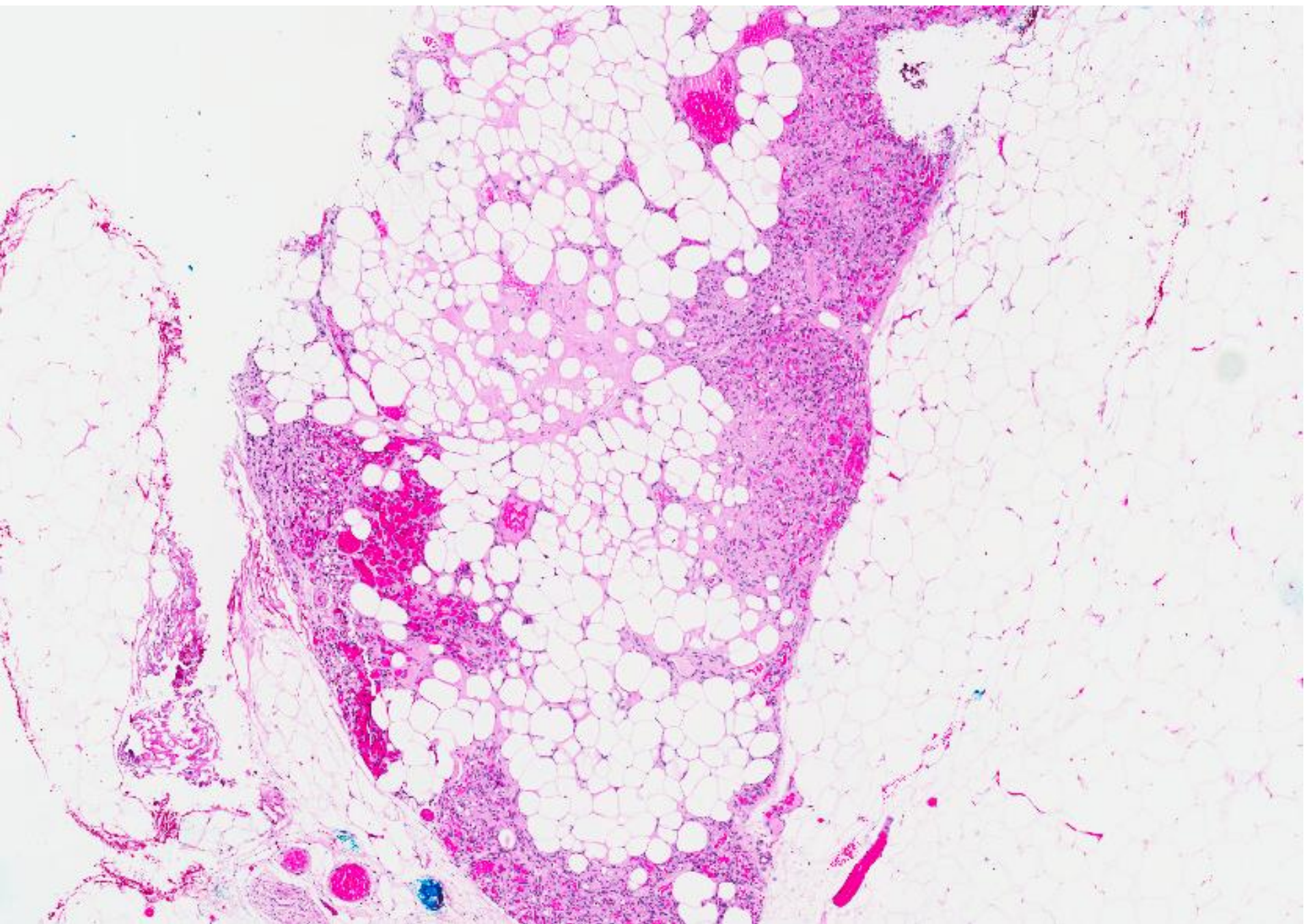


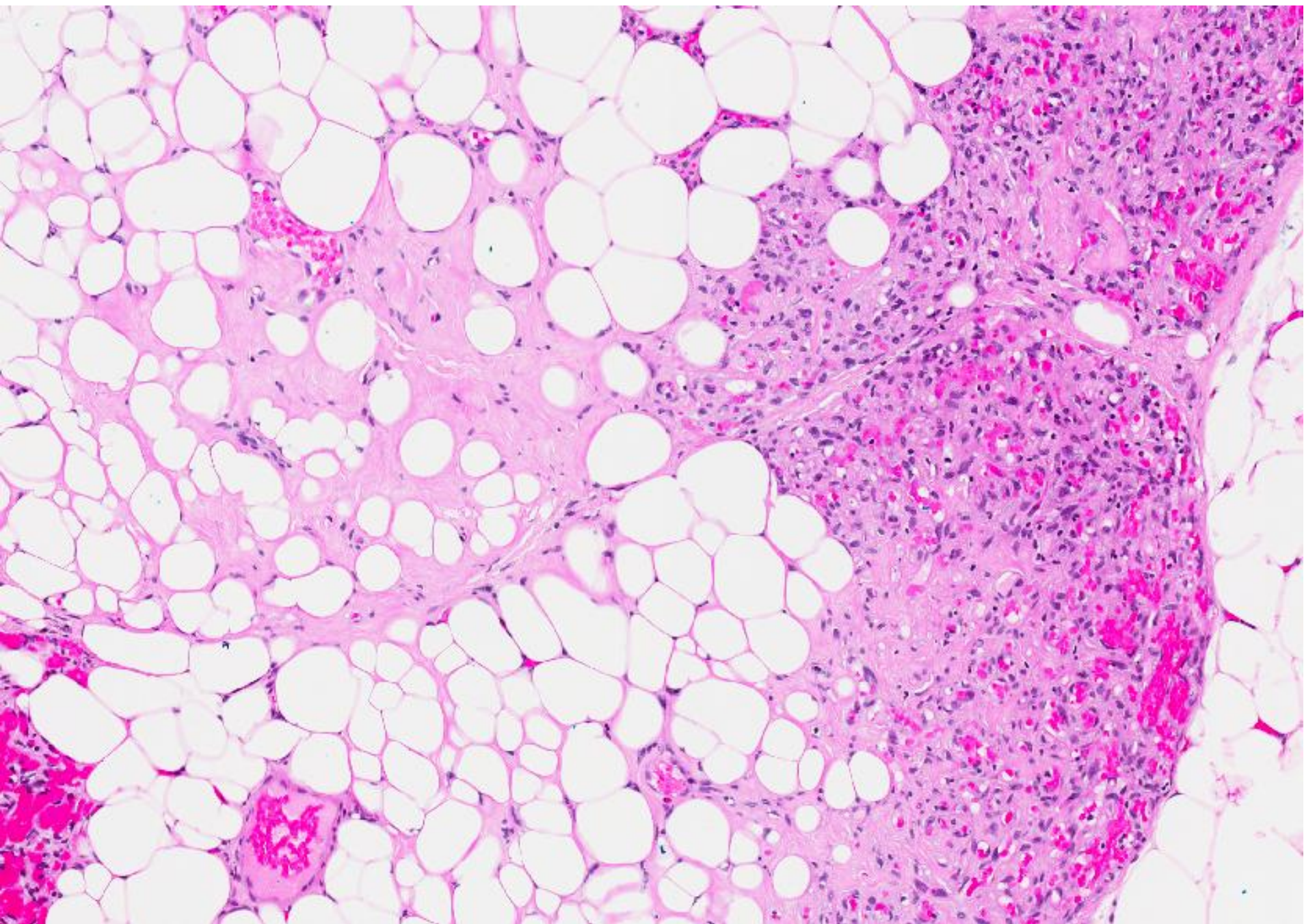
# Diagnosis

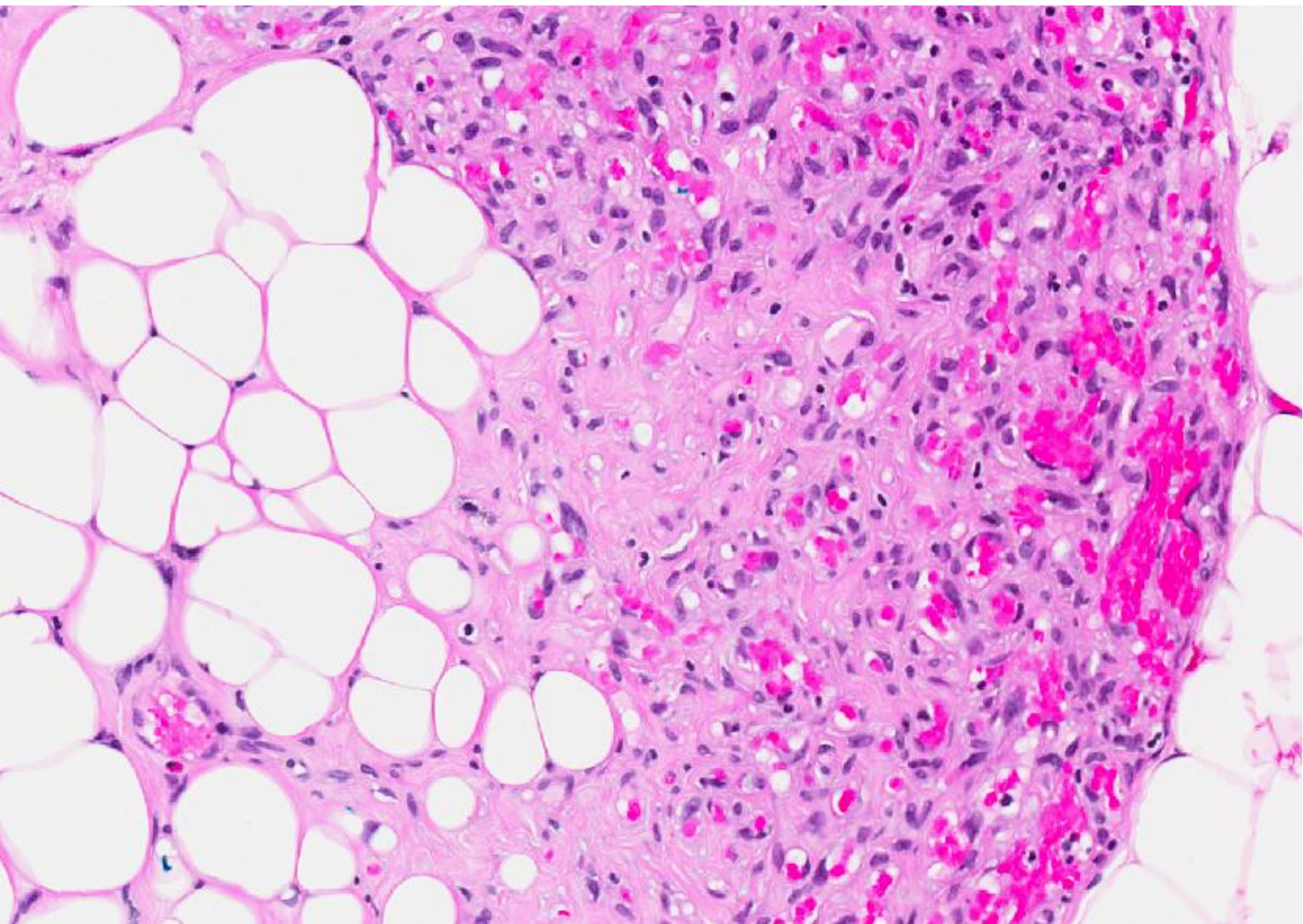
- Core biopsy: Lipovascular lesion, suggest excision.

Excision biopsy









# Diagnosis

- Angiolipoma.

# Angiolipoma

- Variant of lipoma.
- Can occur in the breast, though often in the subcutaneous tissue of skin overlying the breast.
- Benign.
- Painless, in contrast to angiolipomas from other sites.
- On core biopsy, often unable to exclude more sinister vascular lesions.