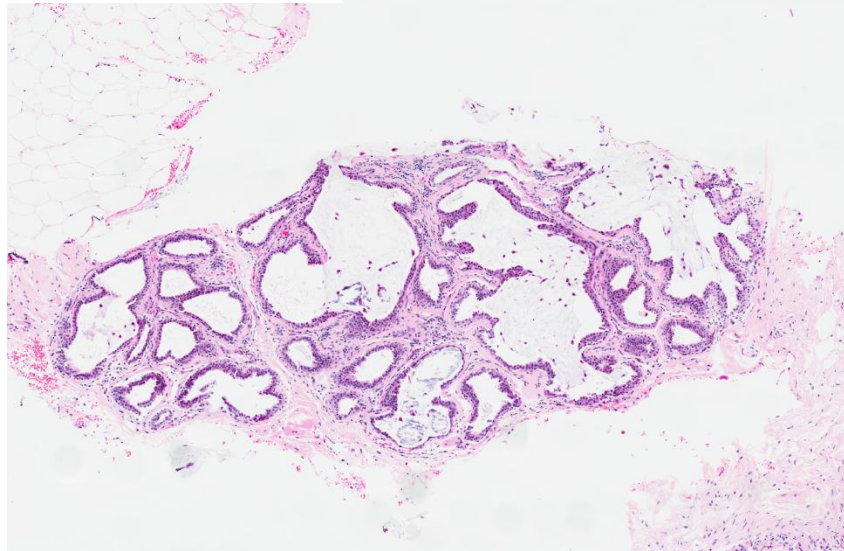
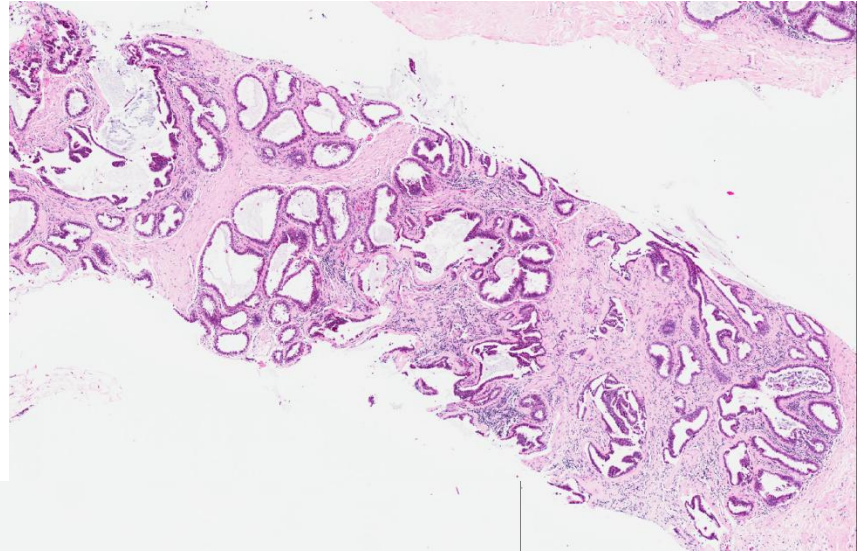
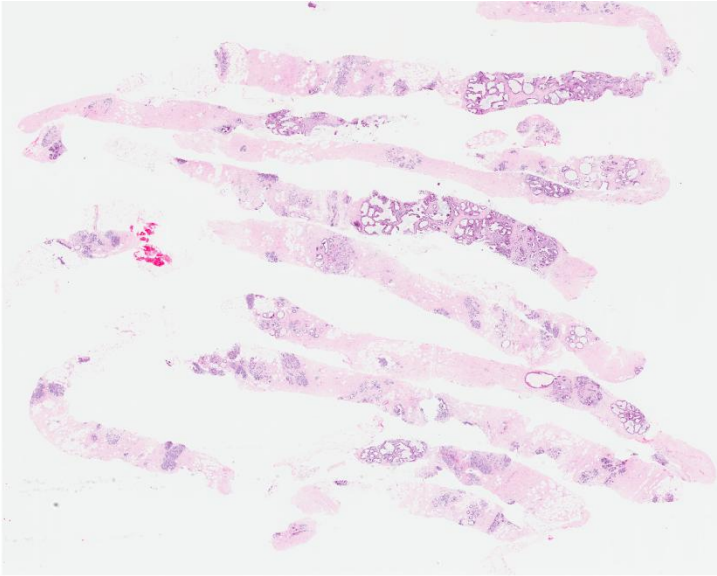


Set C.4

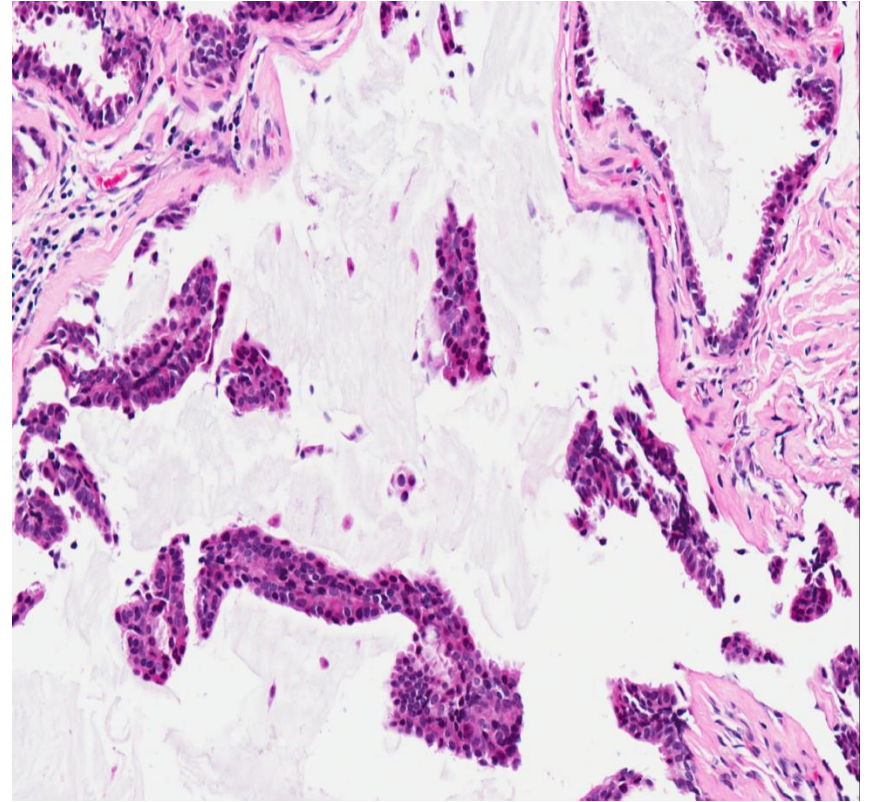
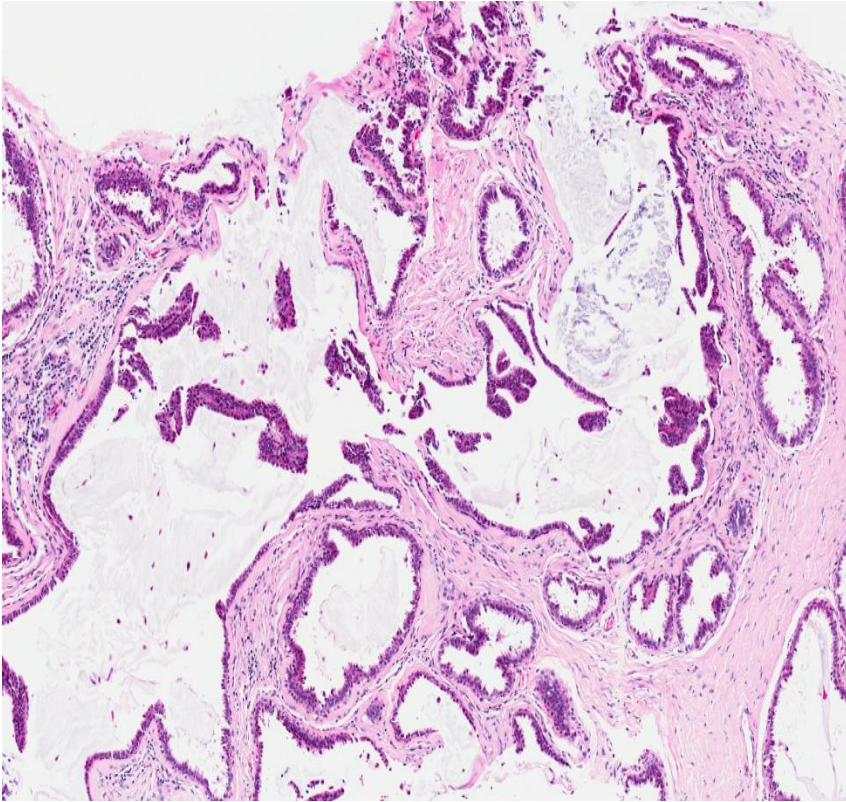
- 51 year old female was discovered to have a 0.8 cm breast mass. Core biopsies were performed.

(contributed by Dr Gary Tse)

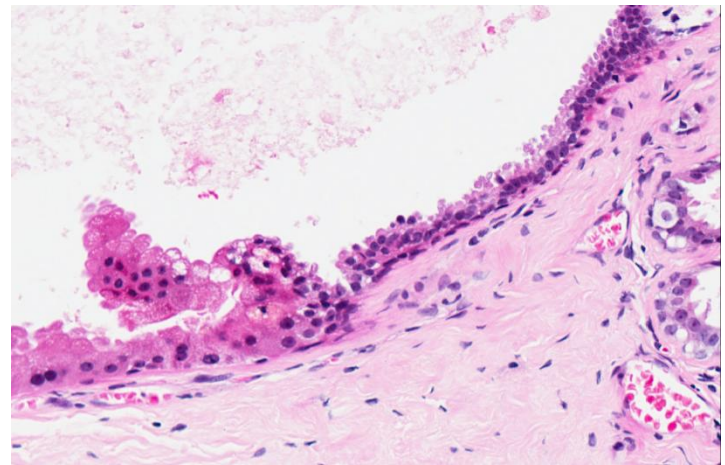
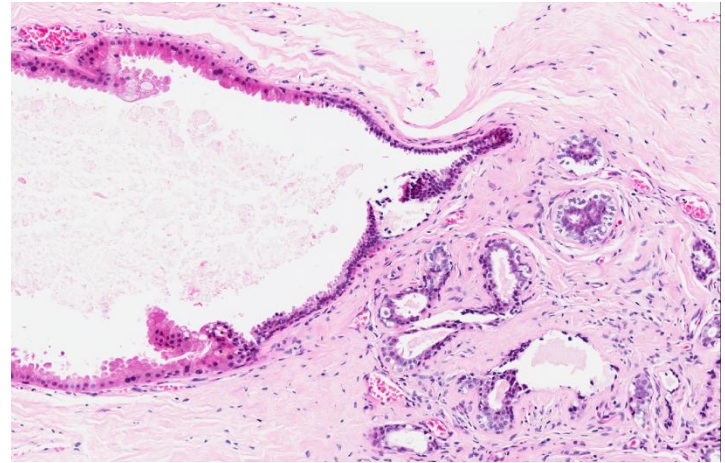
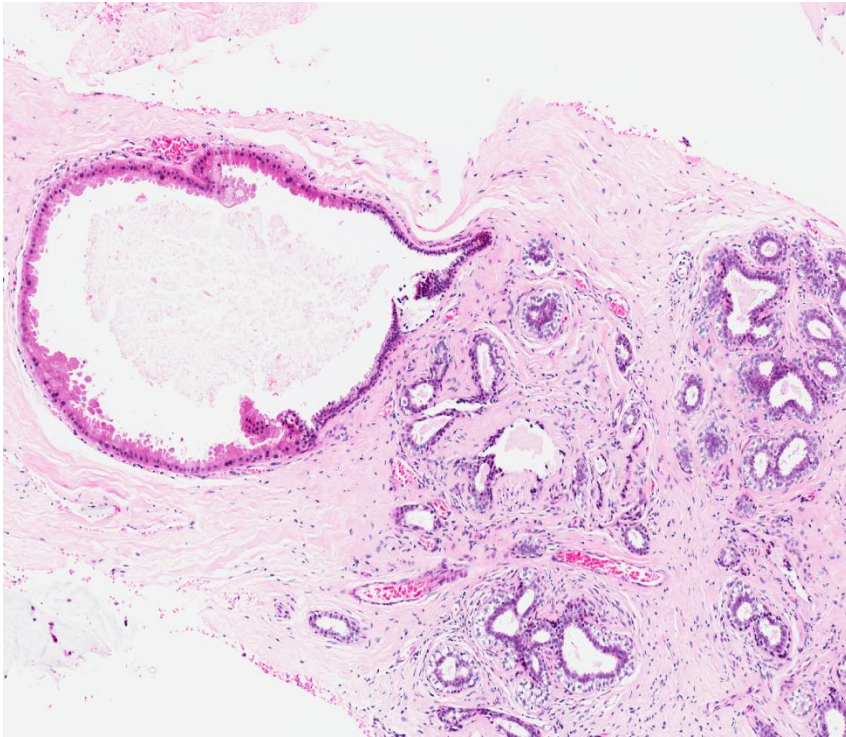
Set C.4



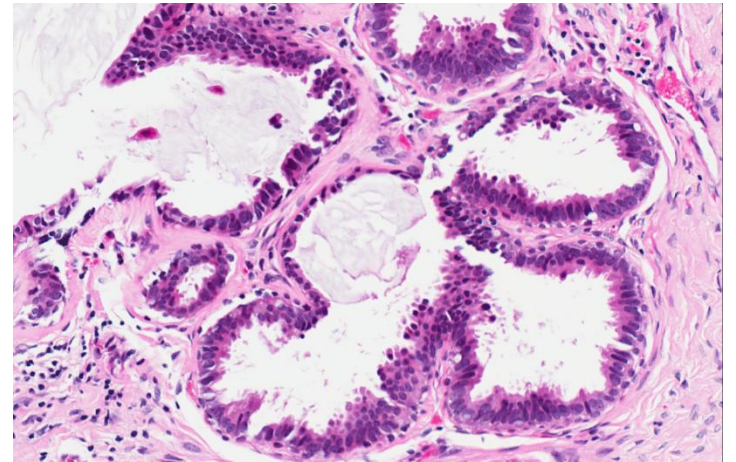
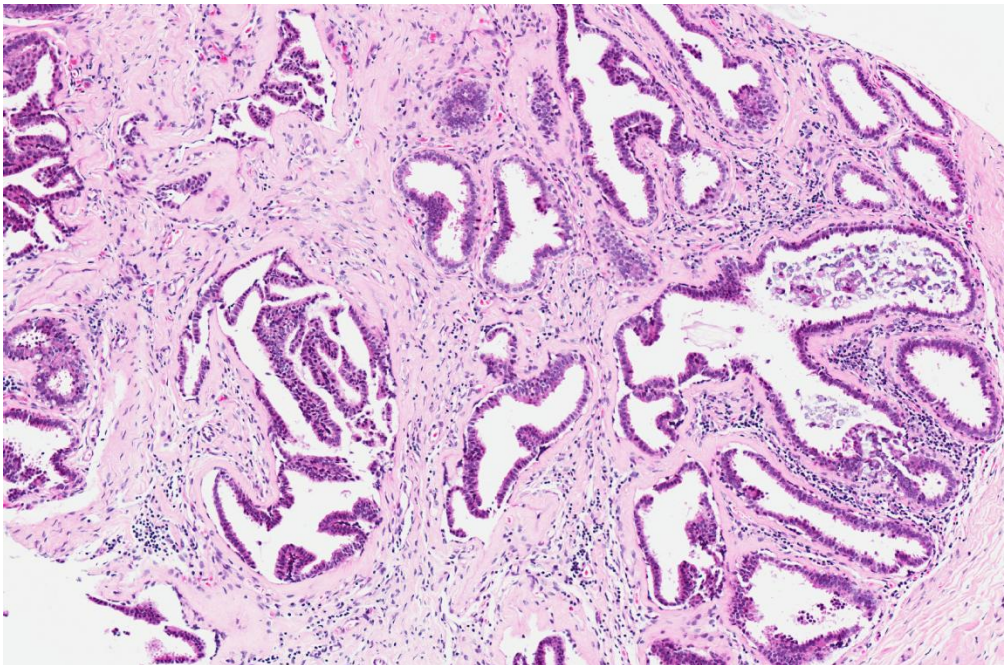
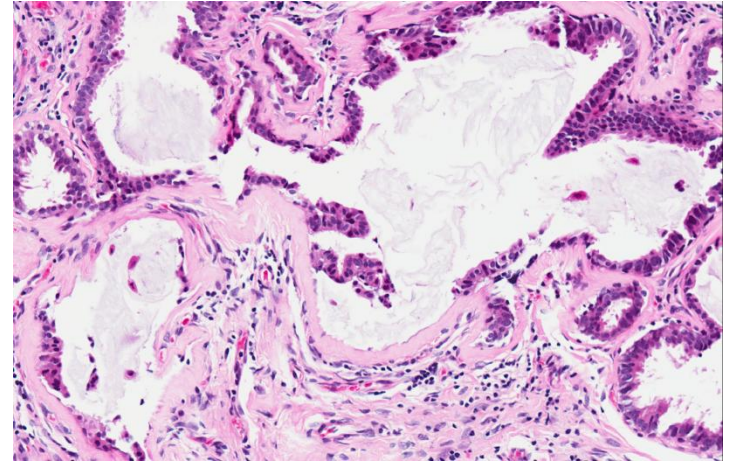
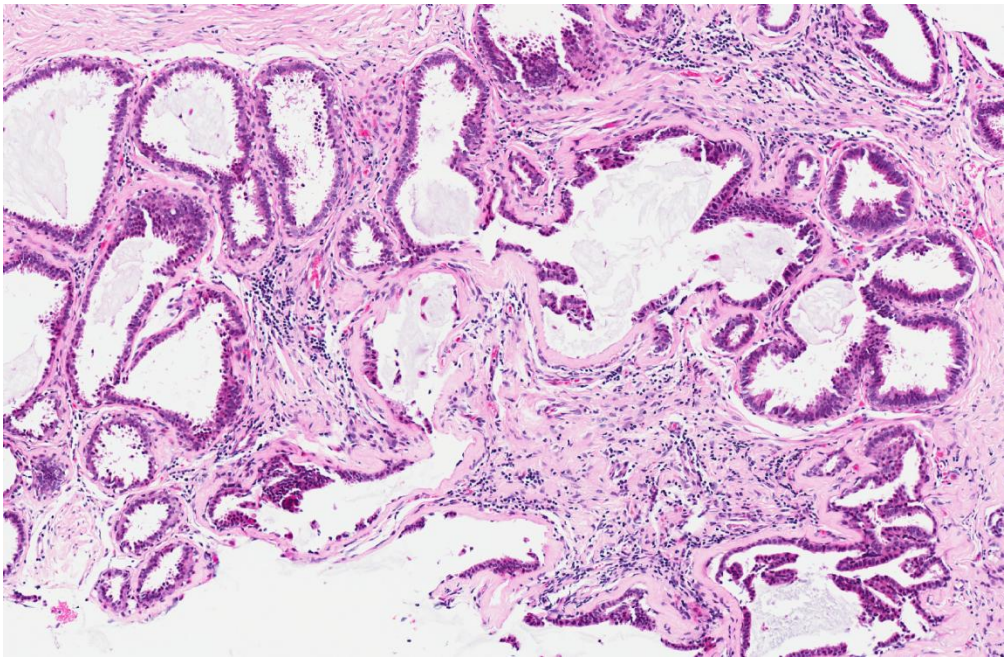
Set C.4



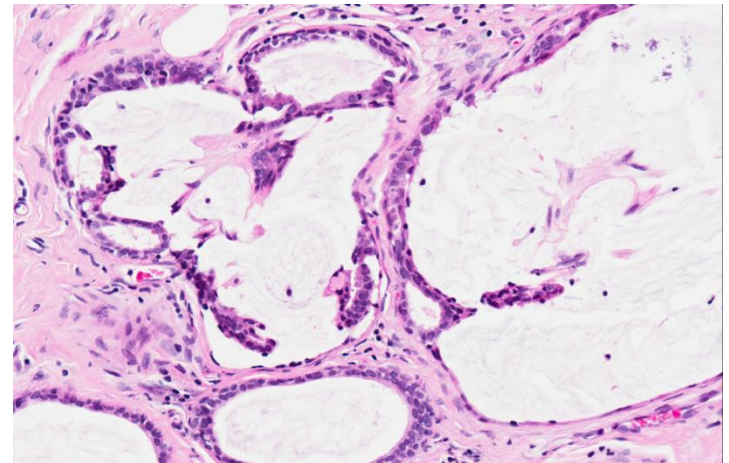
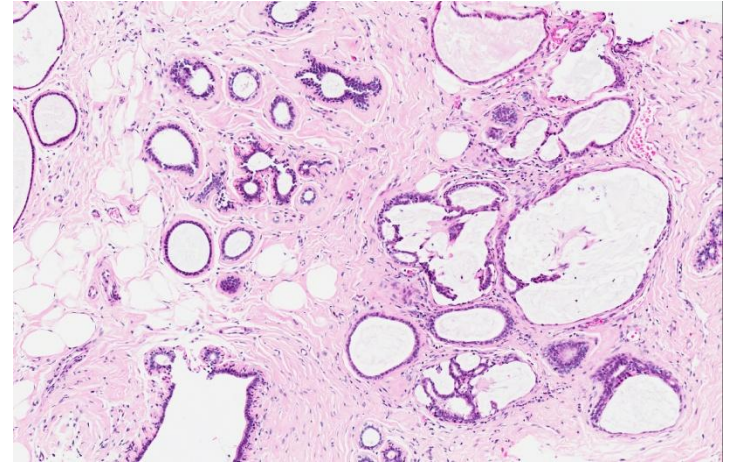
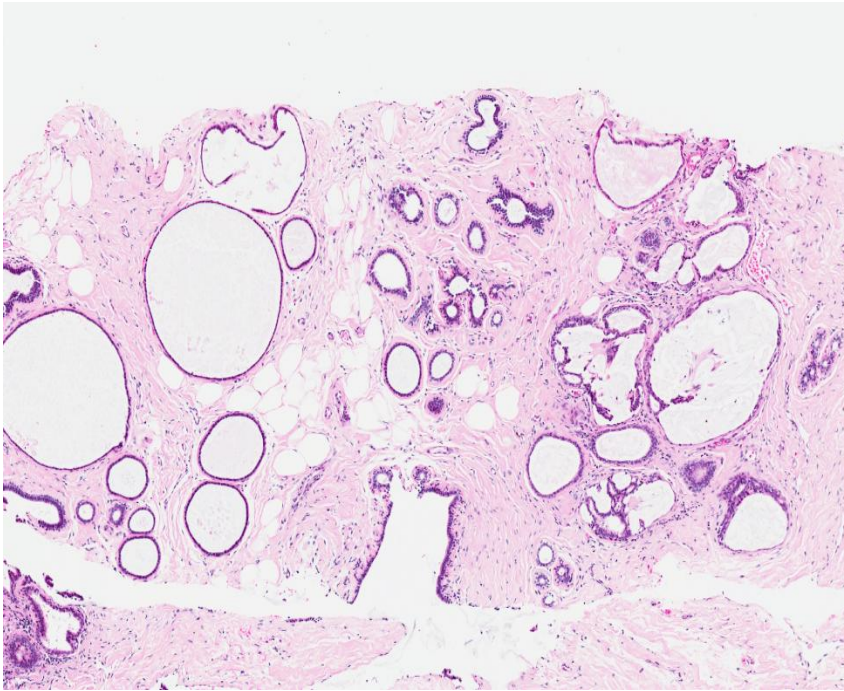
Set C.4



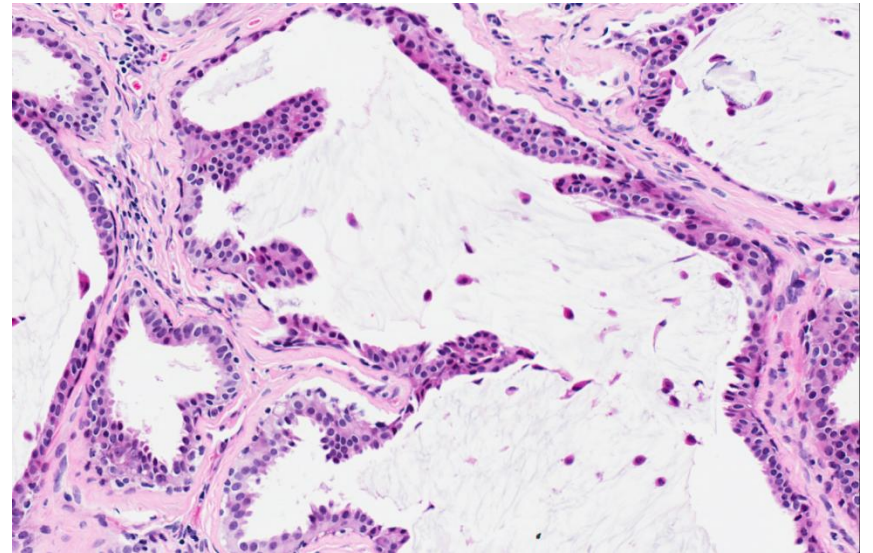
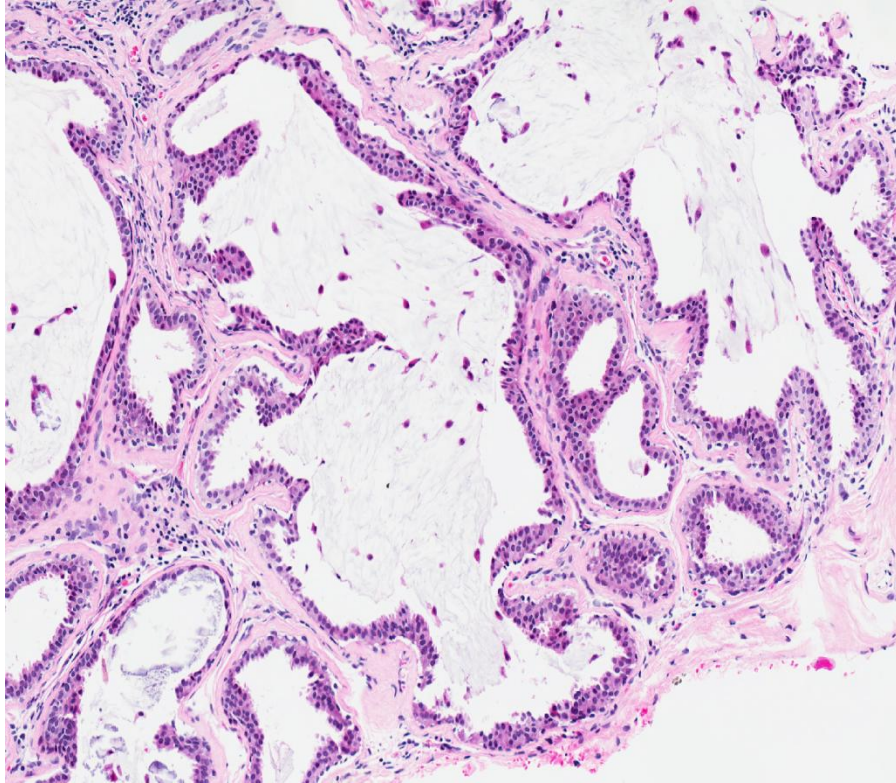
Set C.4



Set C.4



Set C.4



- Fibrocystic changes with columnar cell change and hyperplasia.