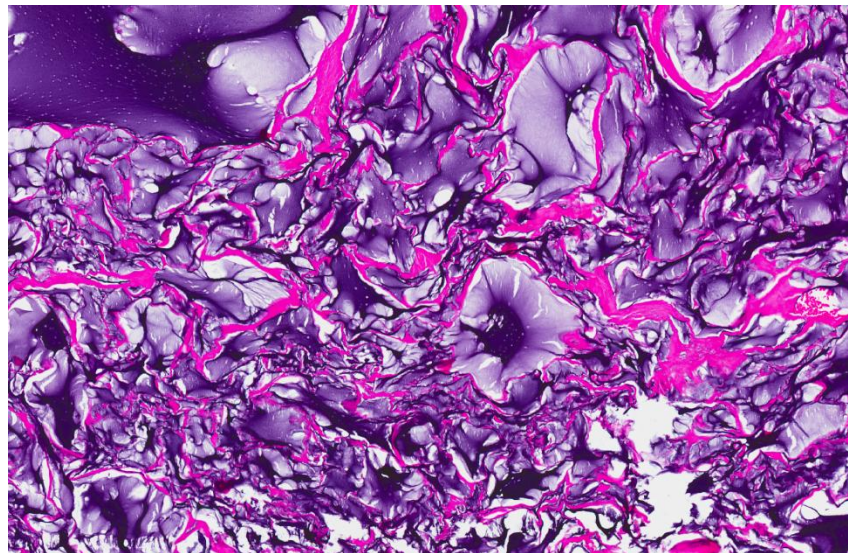
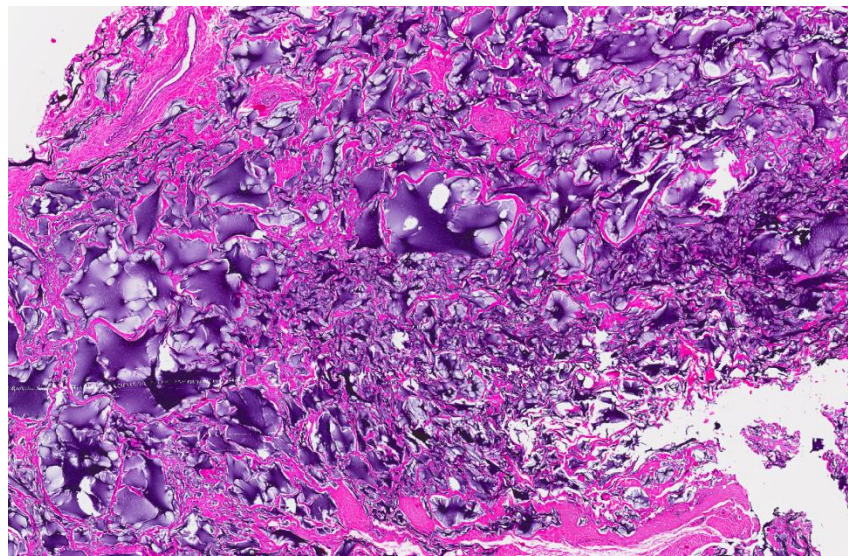
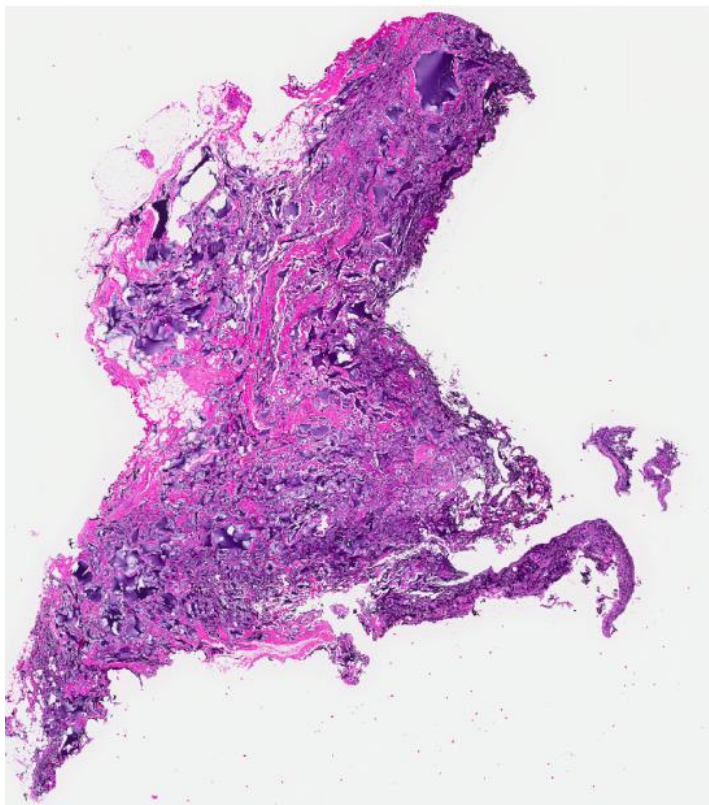


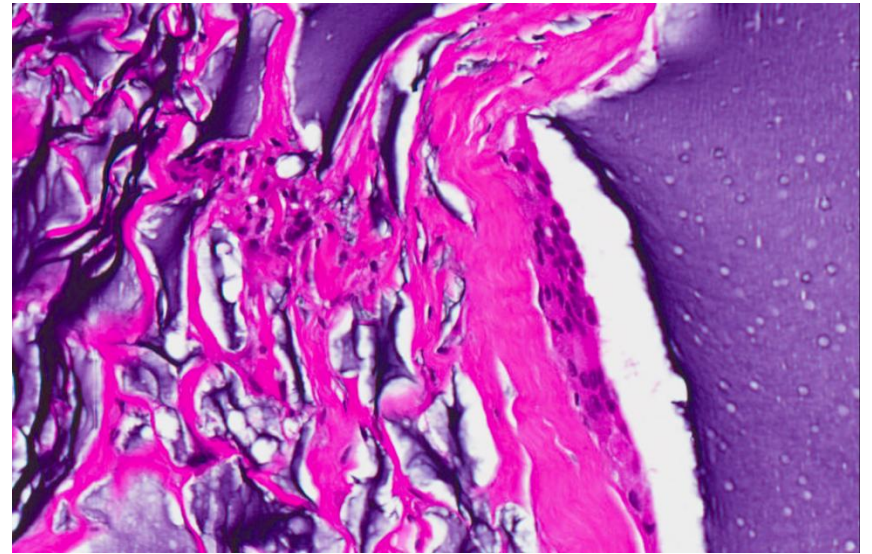
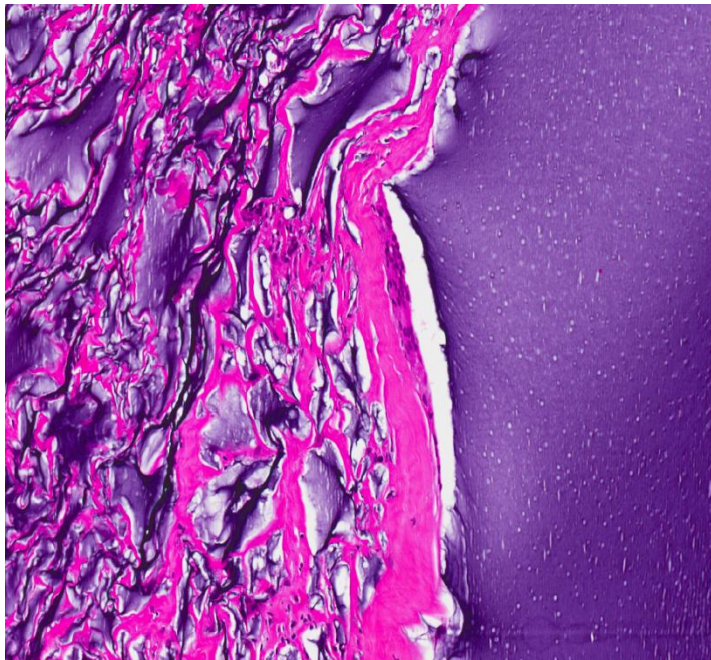
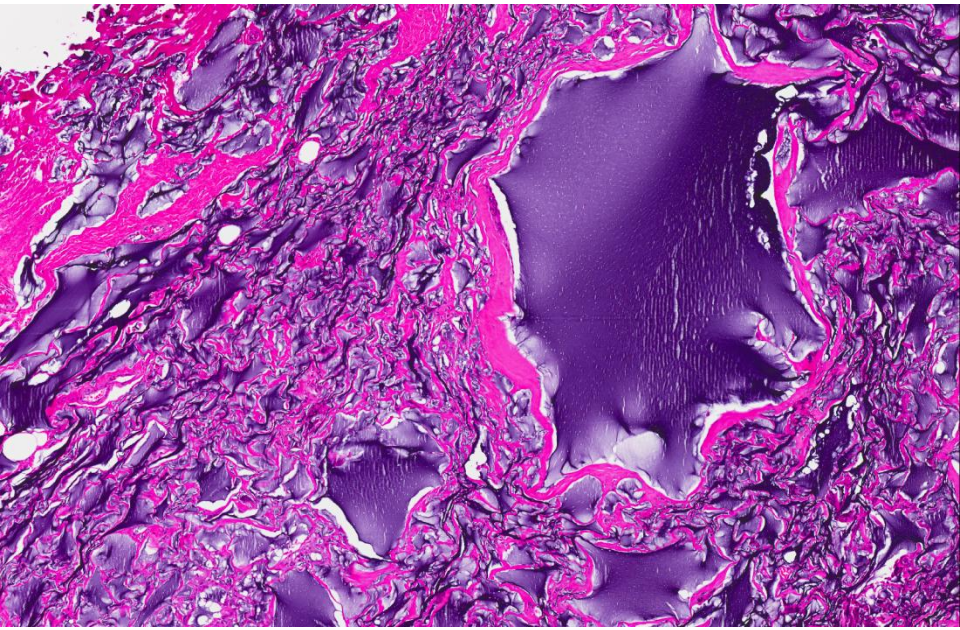
# Set C.10

- 45 year old Chinese female presented with lumpiness in the right breast.
- A previous FNAC was reported as 'mucinous lesion with atypia'.
- Excision biopsy of two lumps in the right breast was performed.
- Current section is from one of the lumps.

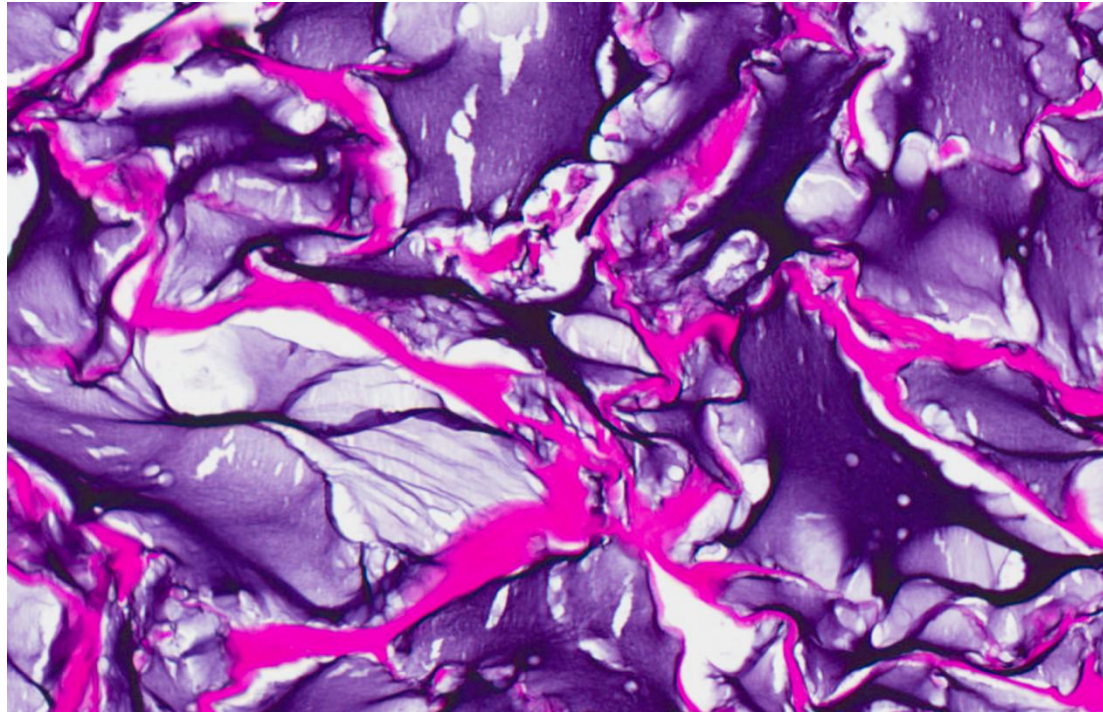
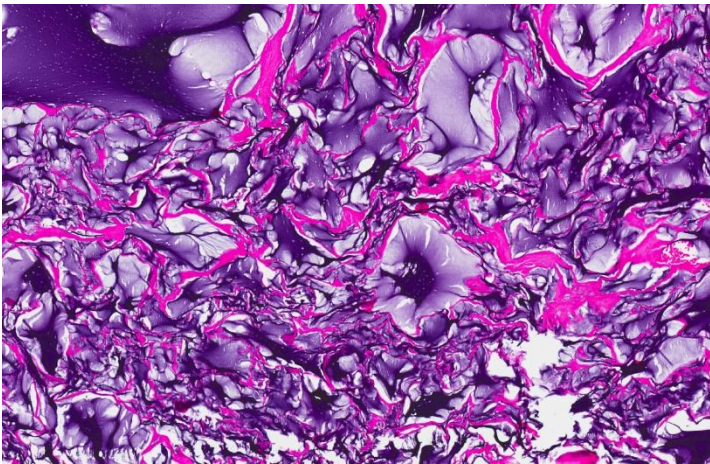
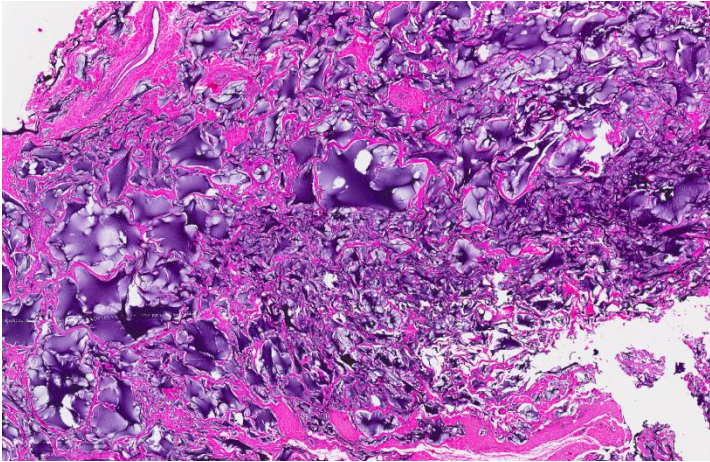
# Set C.10



# Set C.10



# Set C.10



- Injected material for breast augmentation.
- Foreign body giant cell reaction.