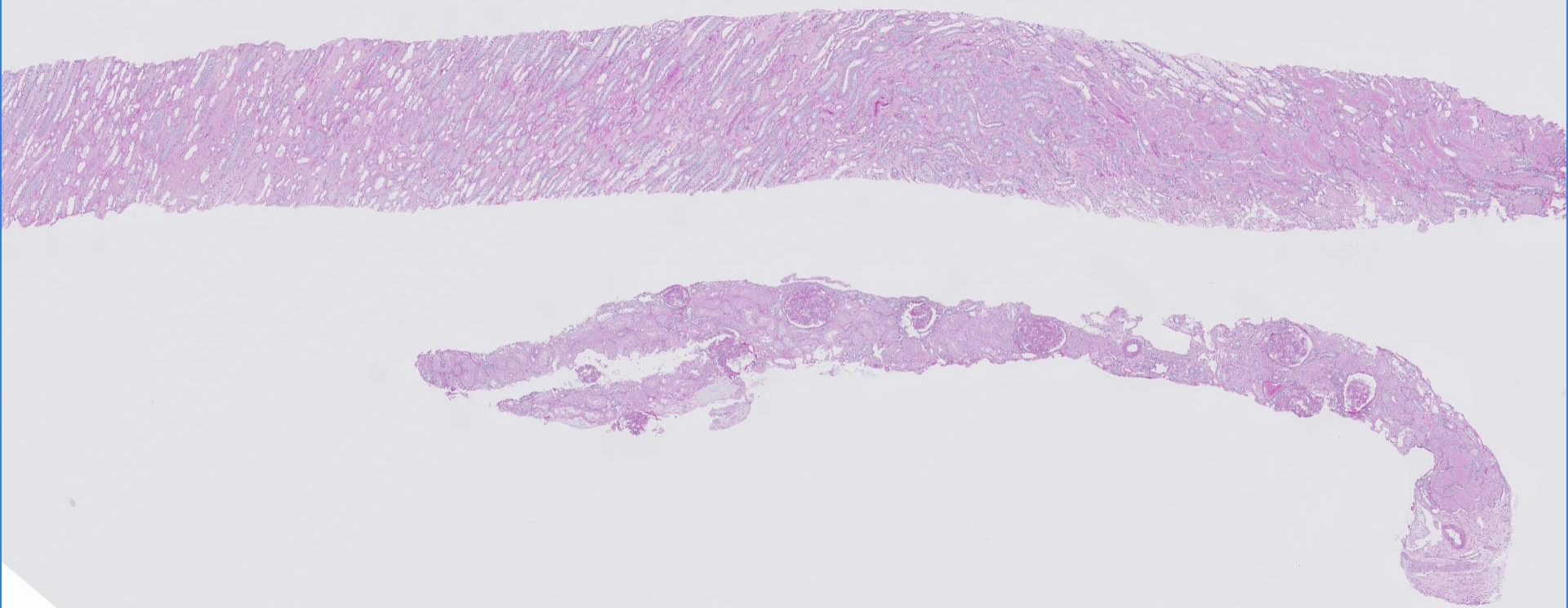
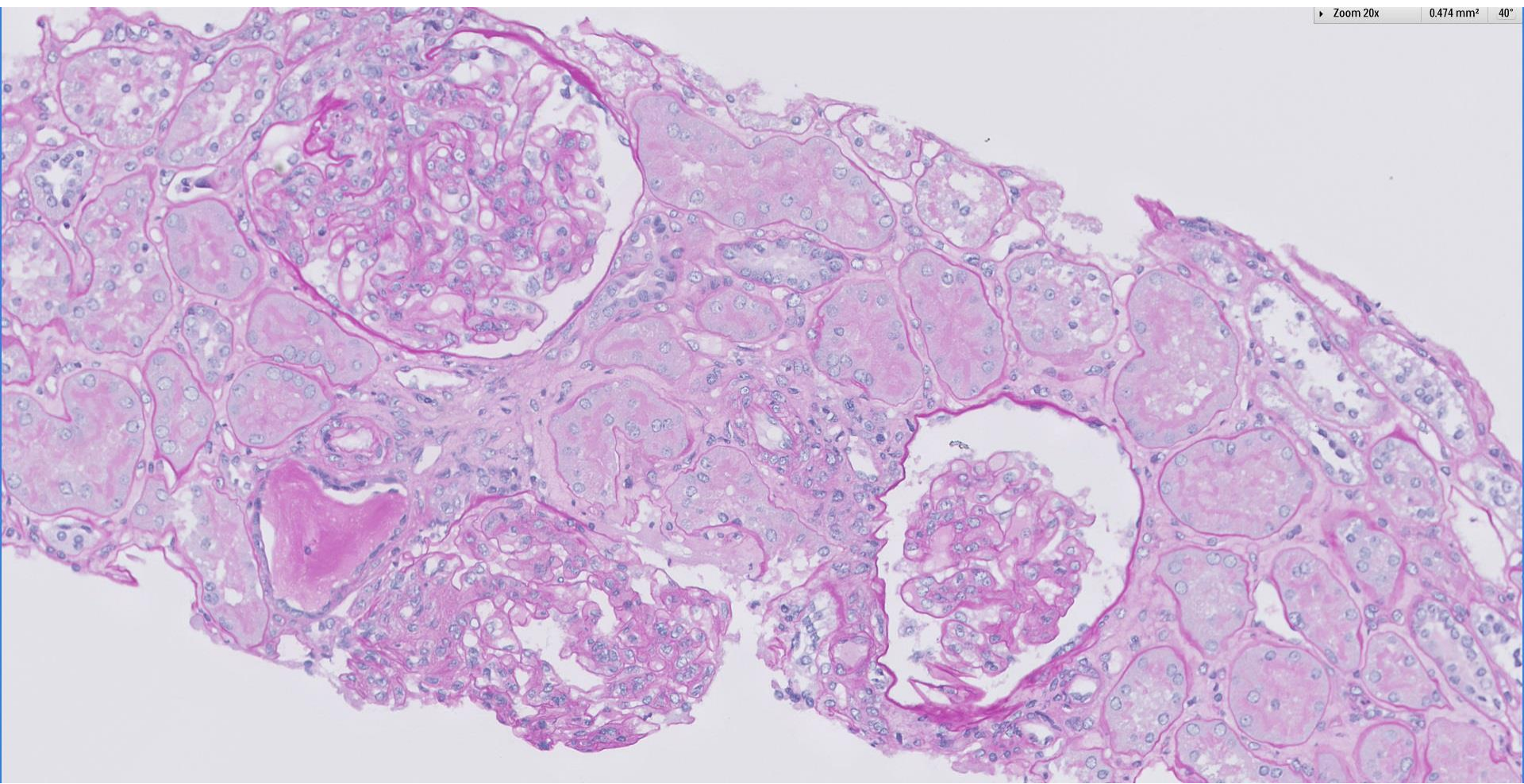
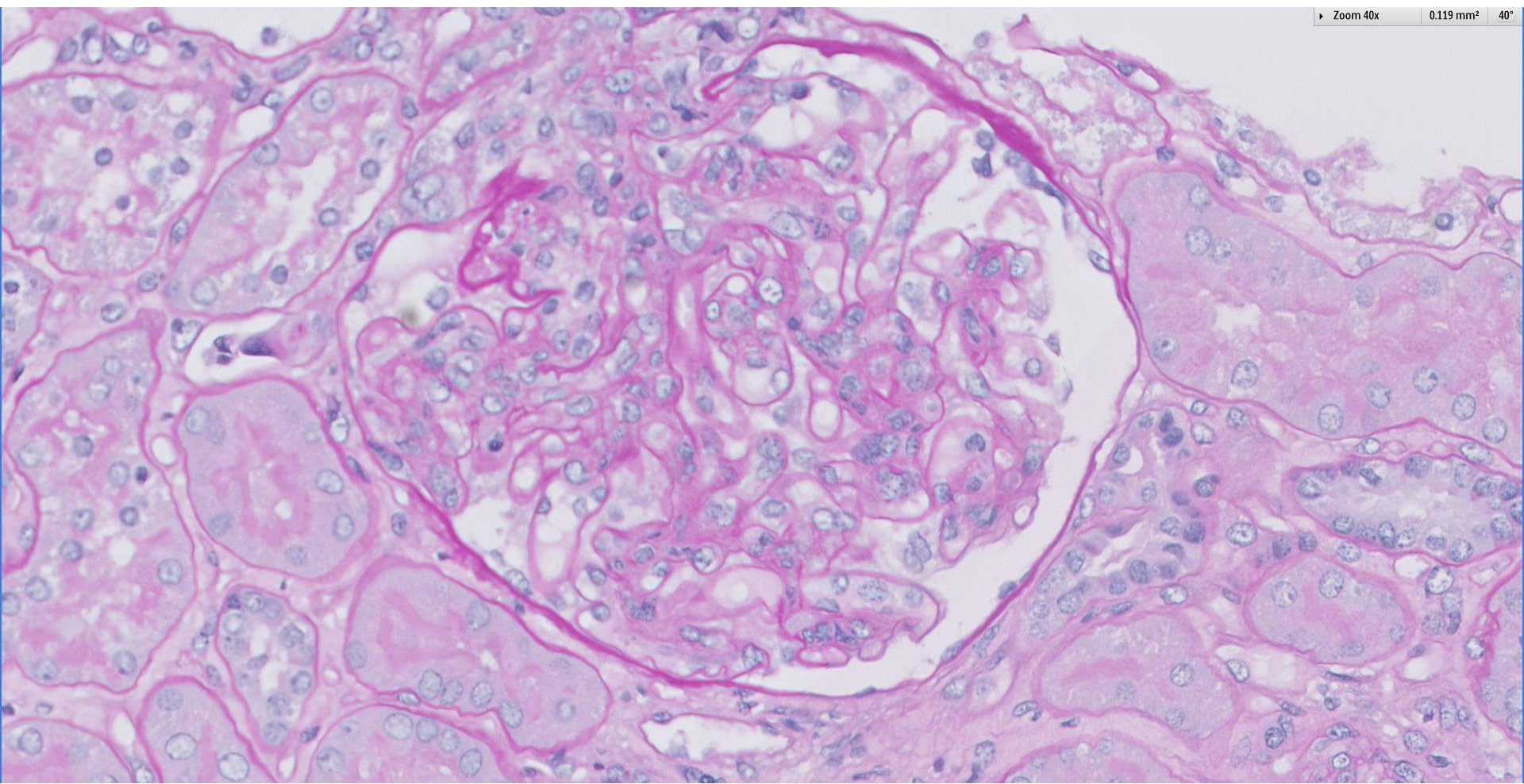


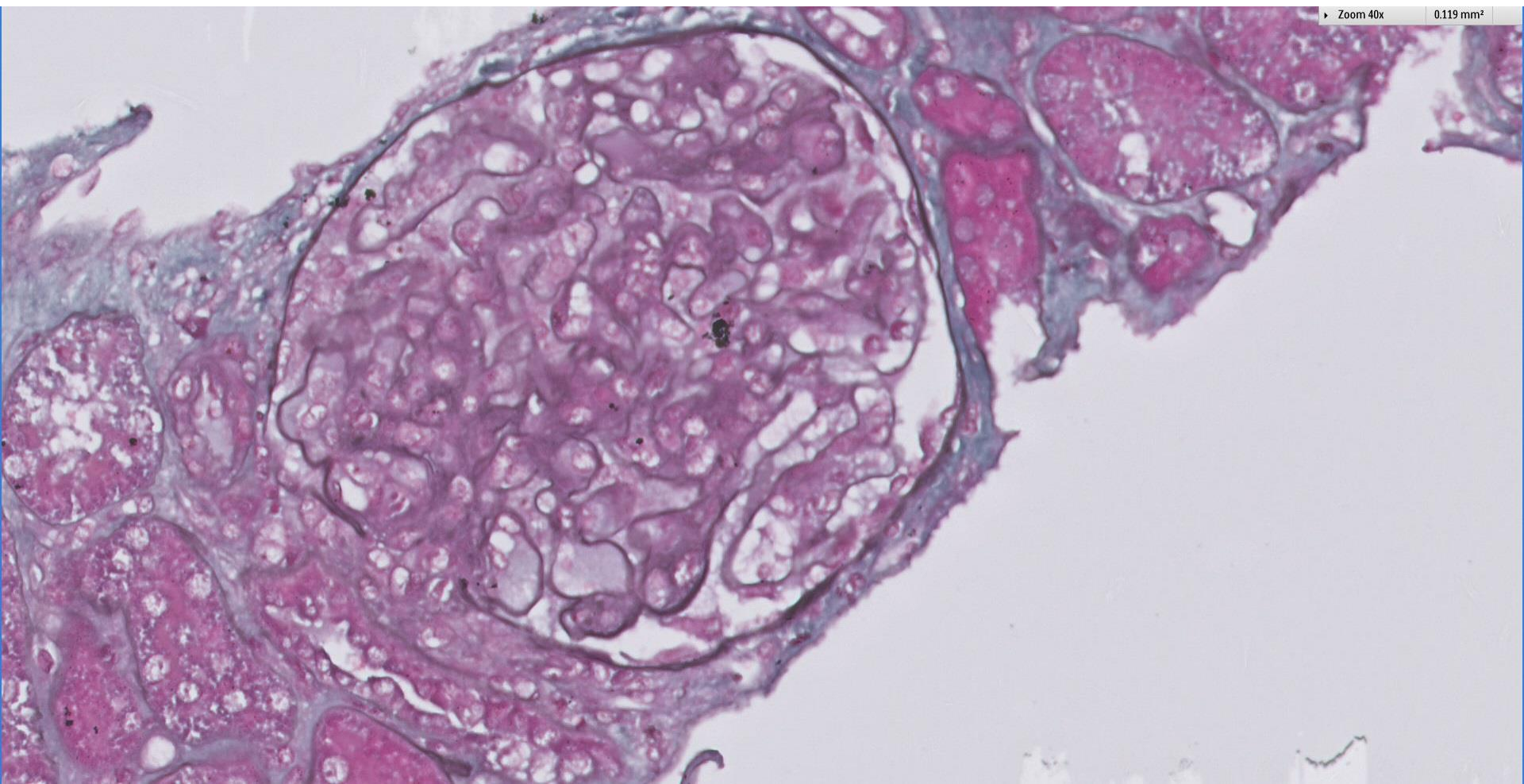
Case 38

32 year old female with fever, rash and pancytopenia found to have haematuria and proteinuria. Urine culture negative.

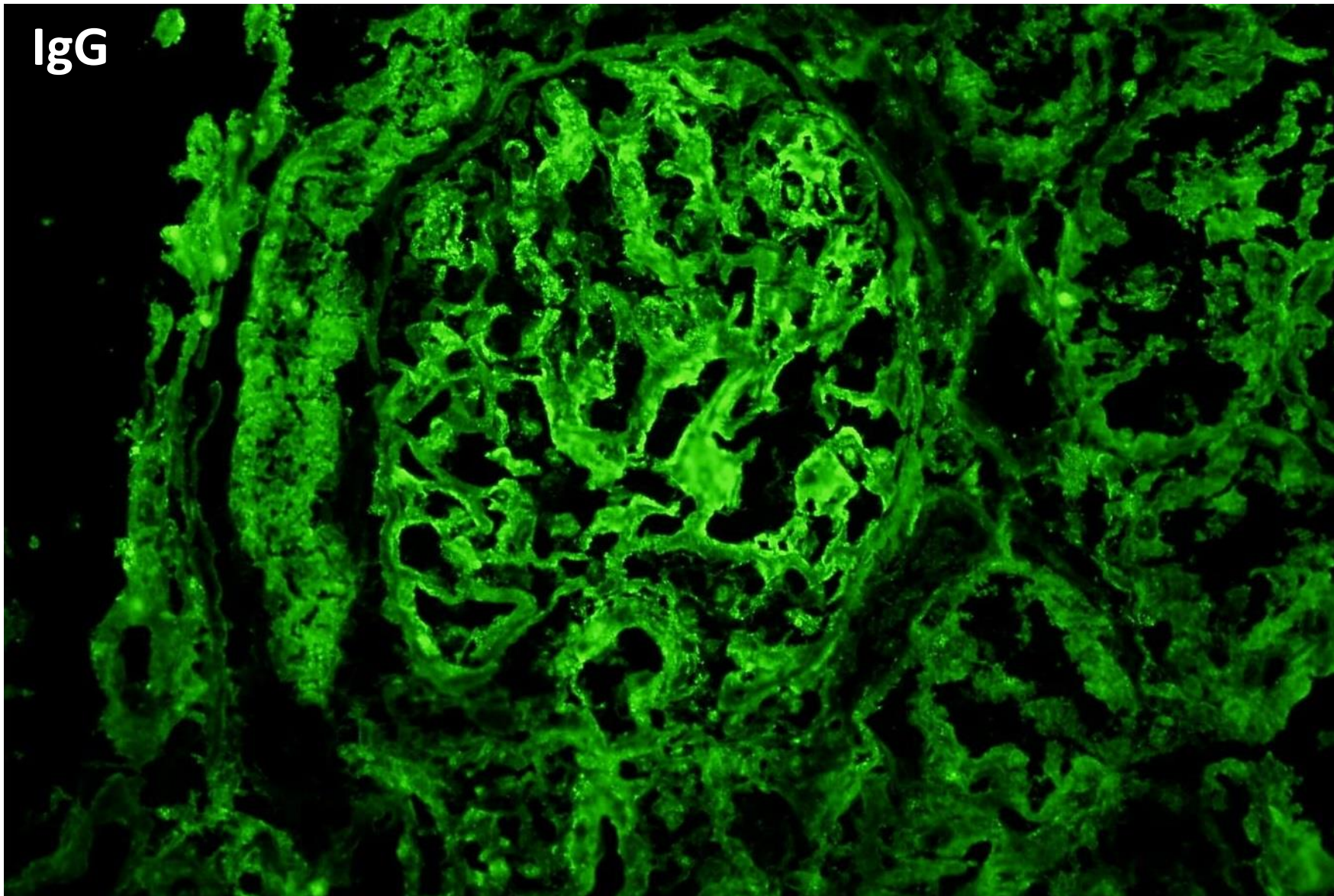




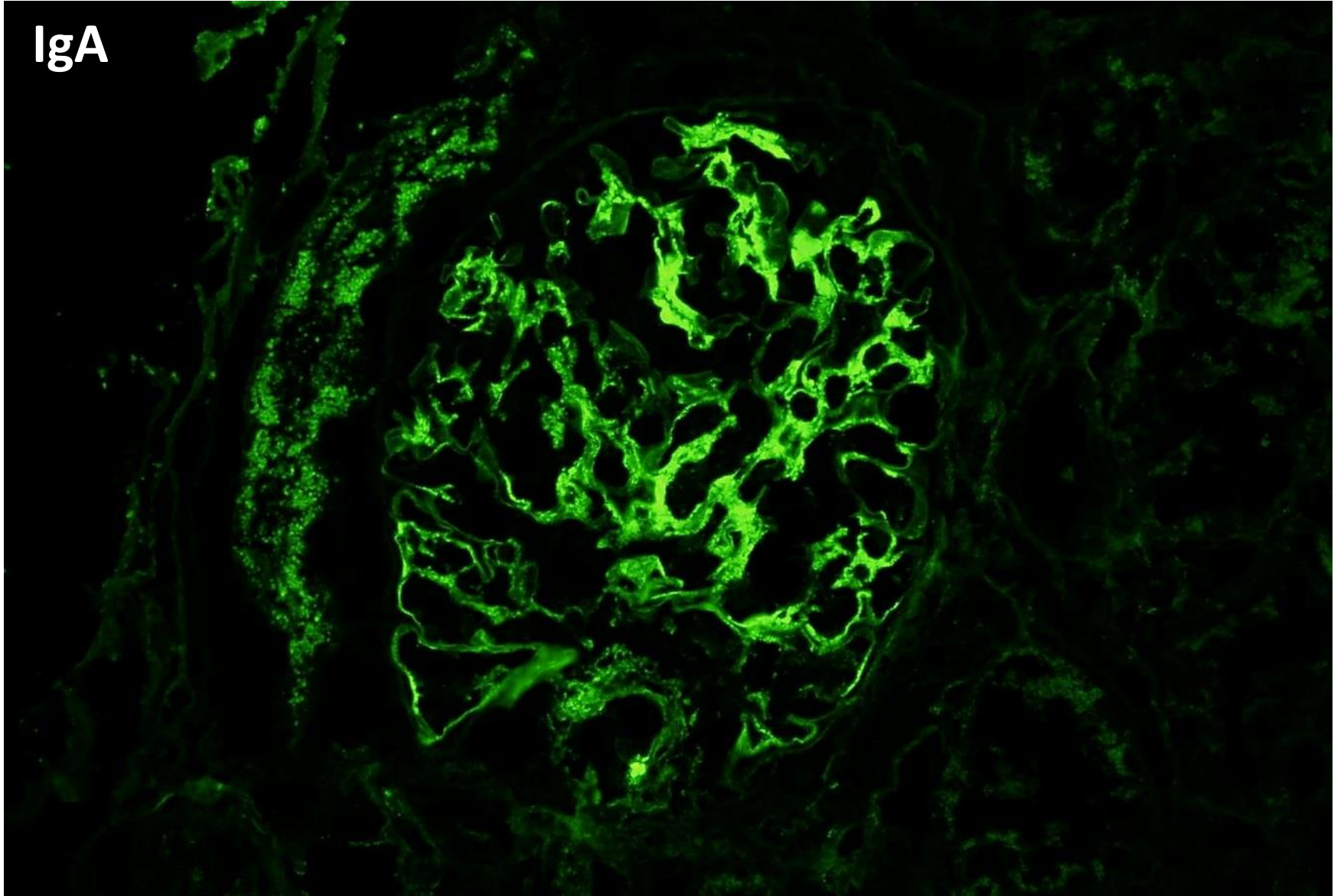




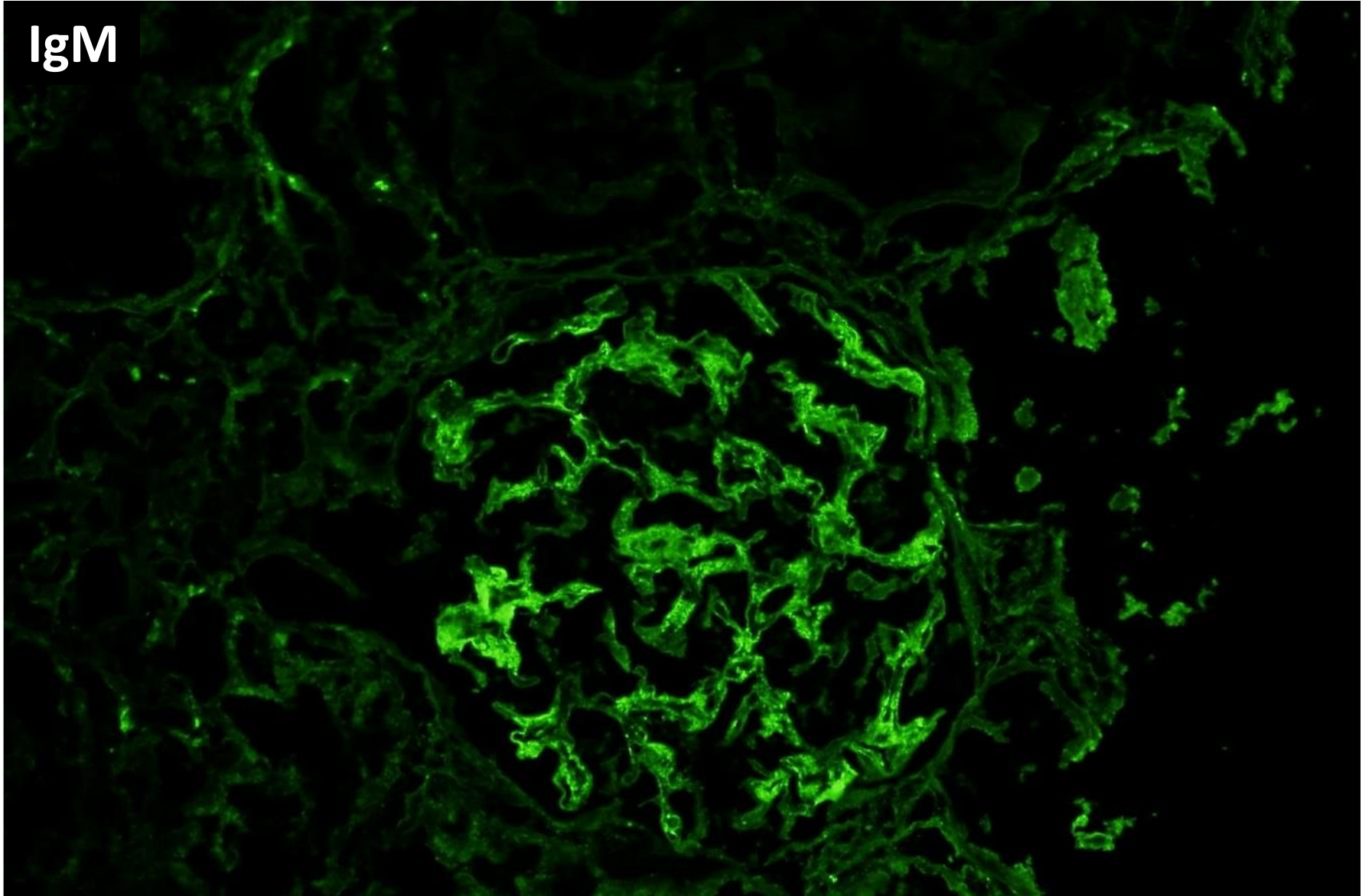
IgG



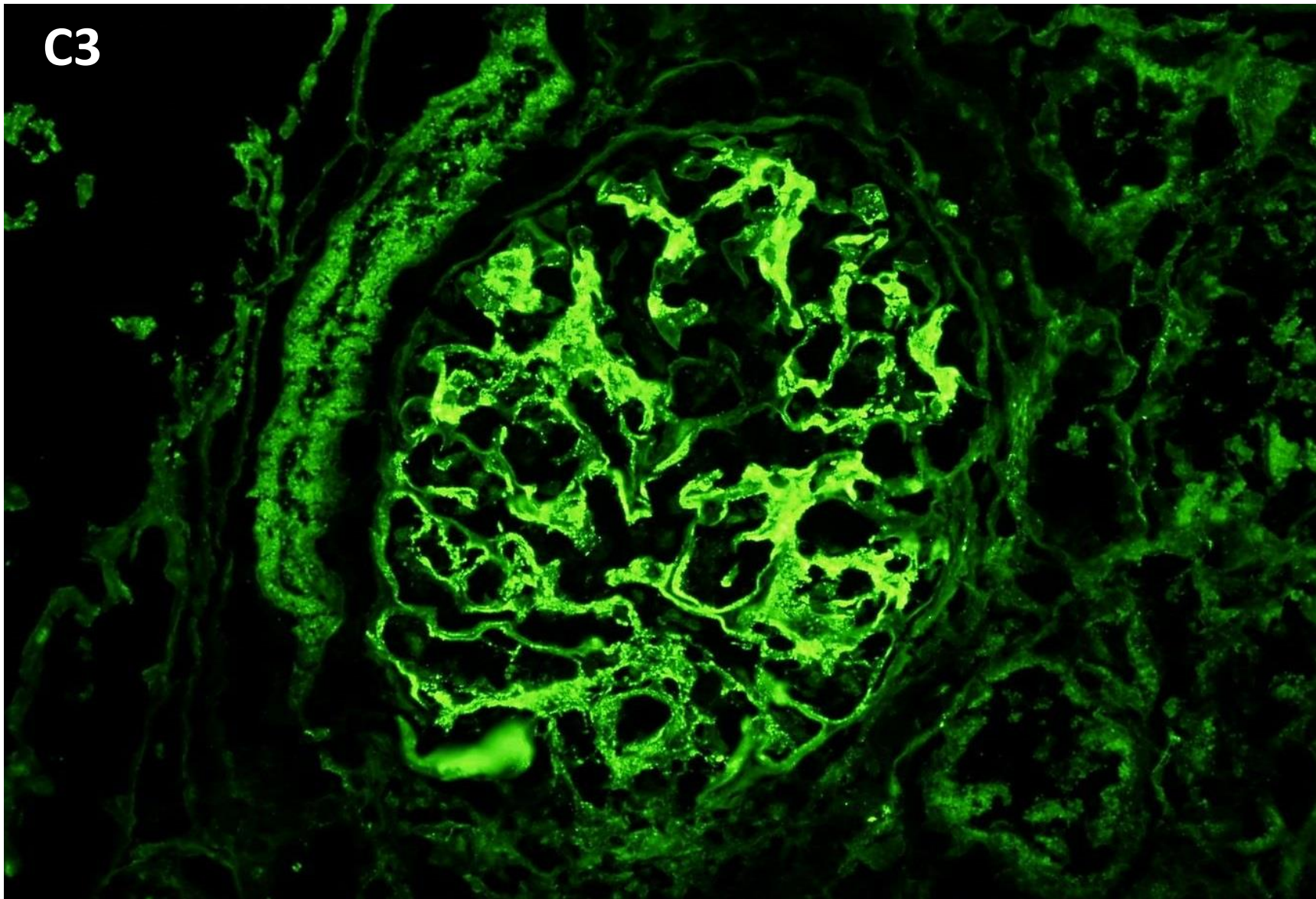
IgA



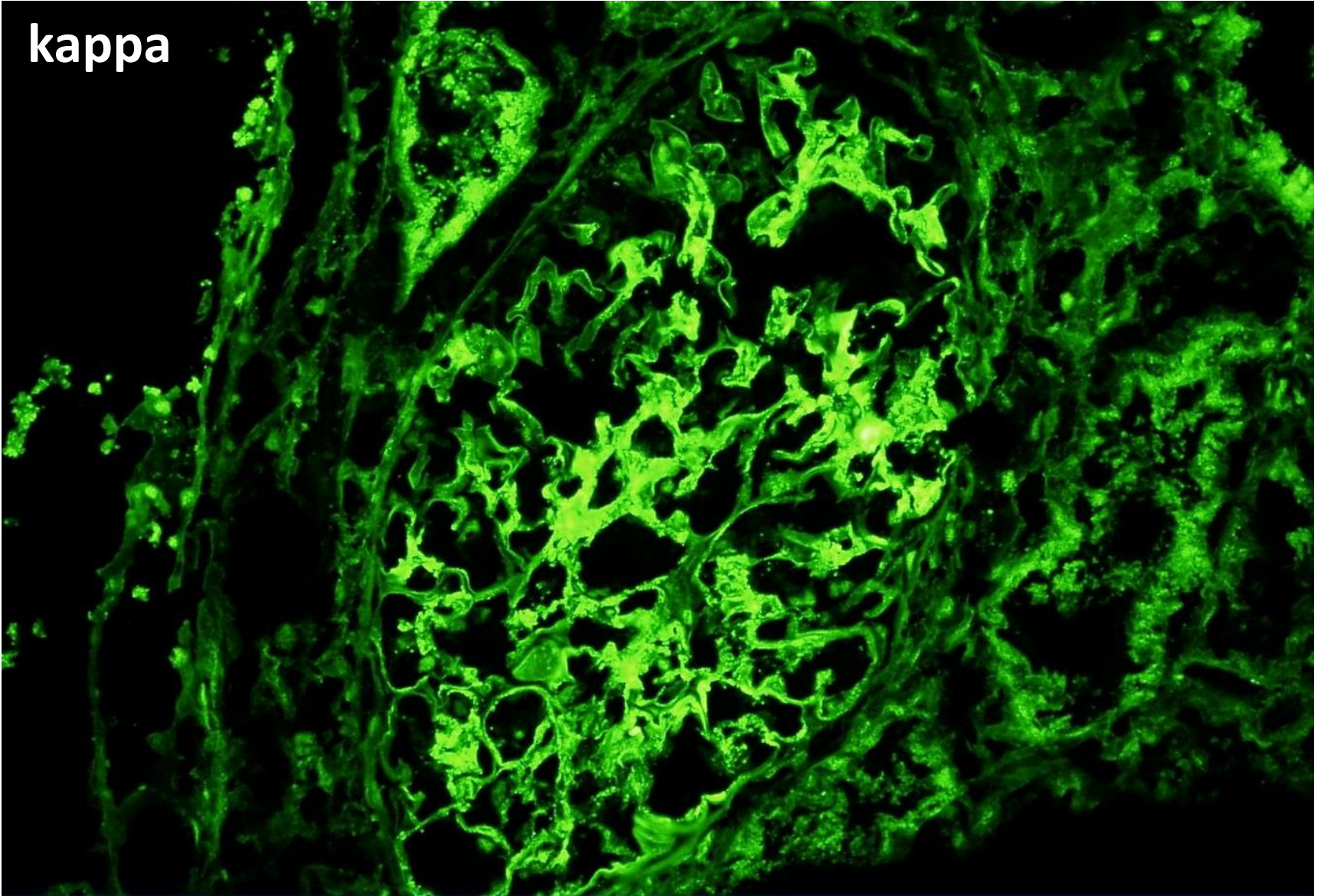
IgM



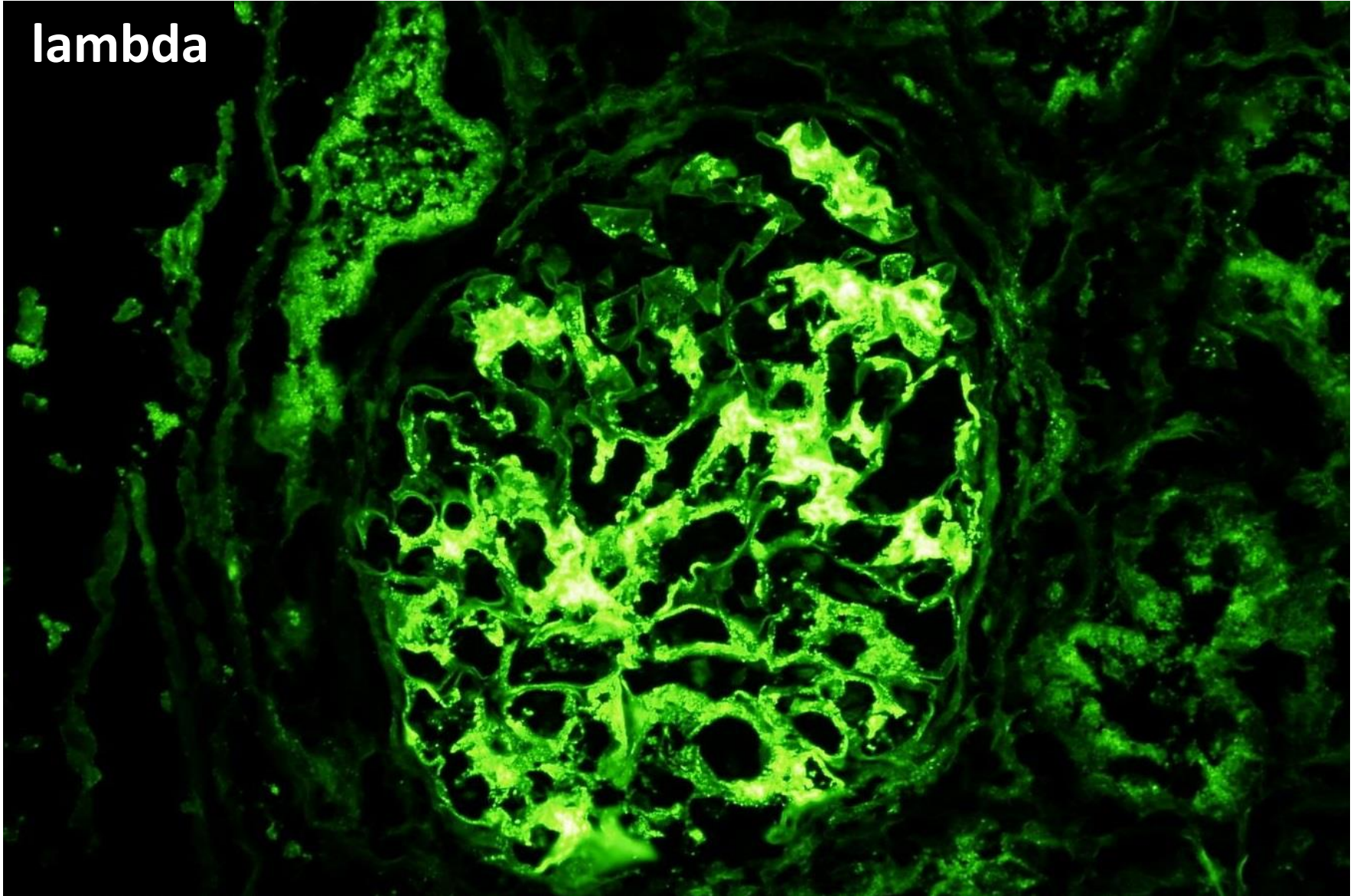
C3

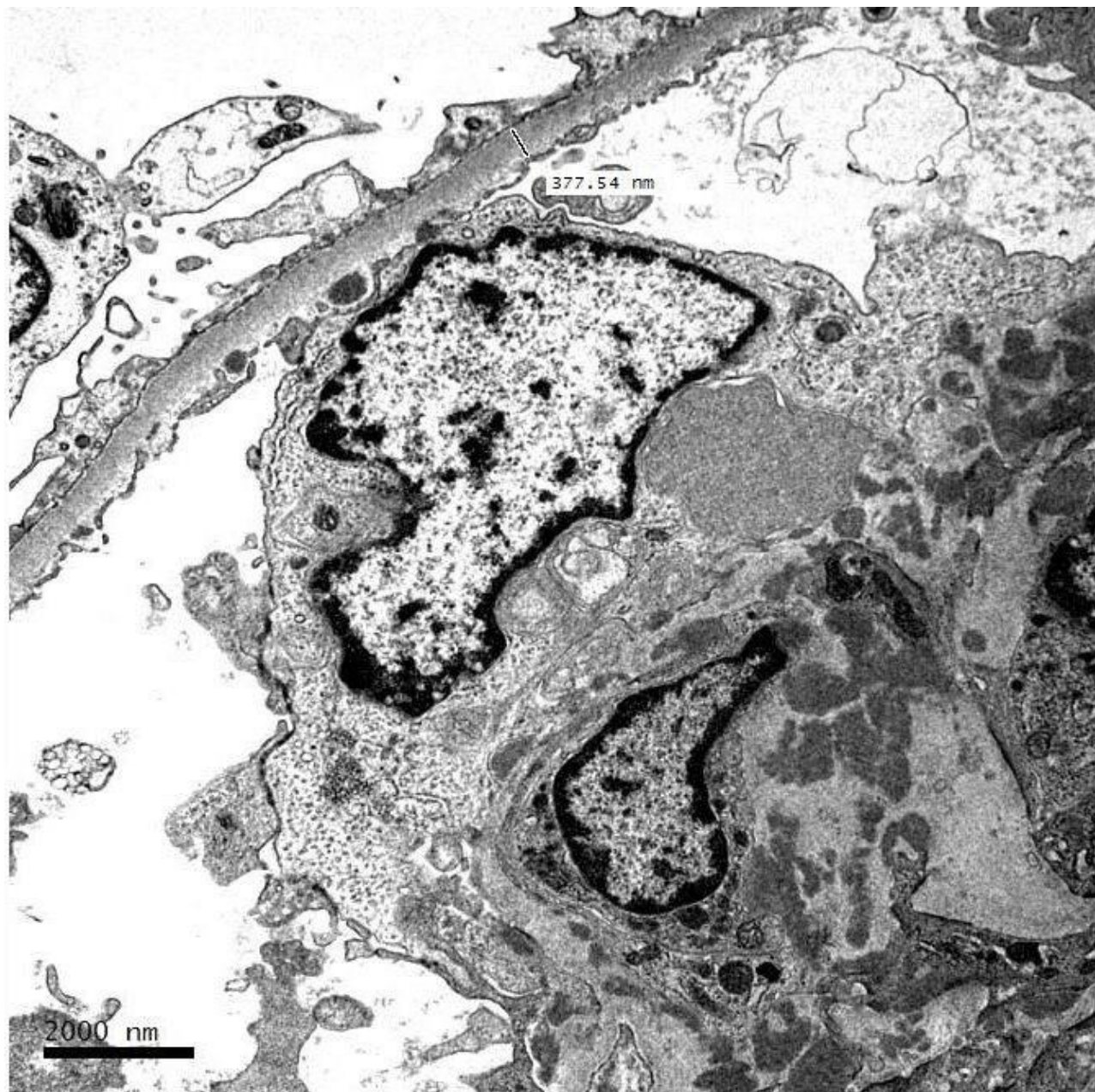


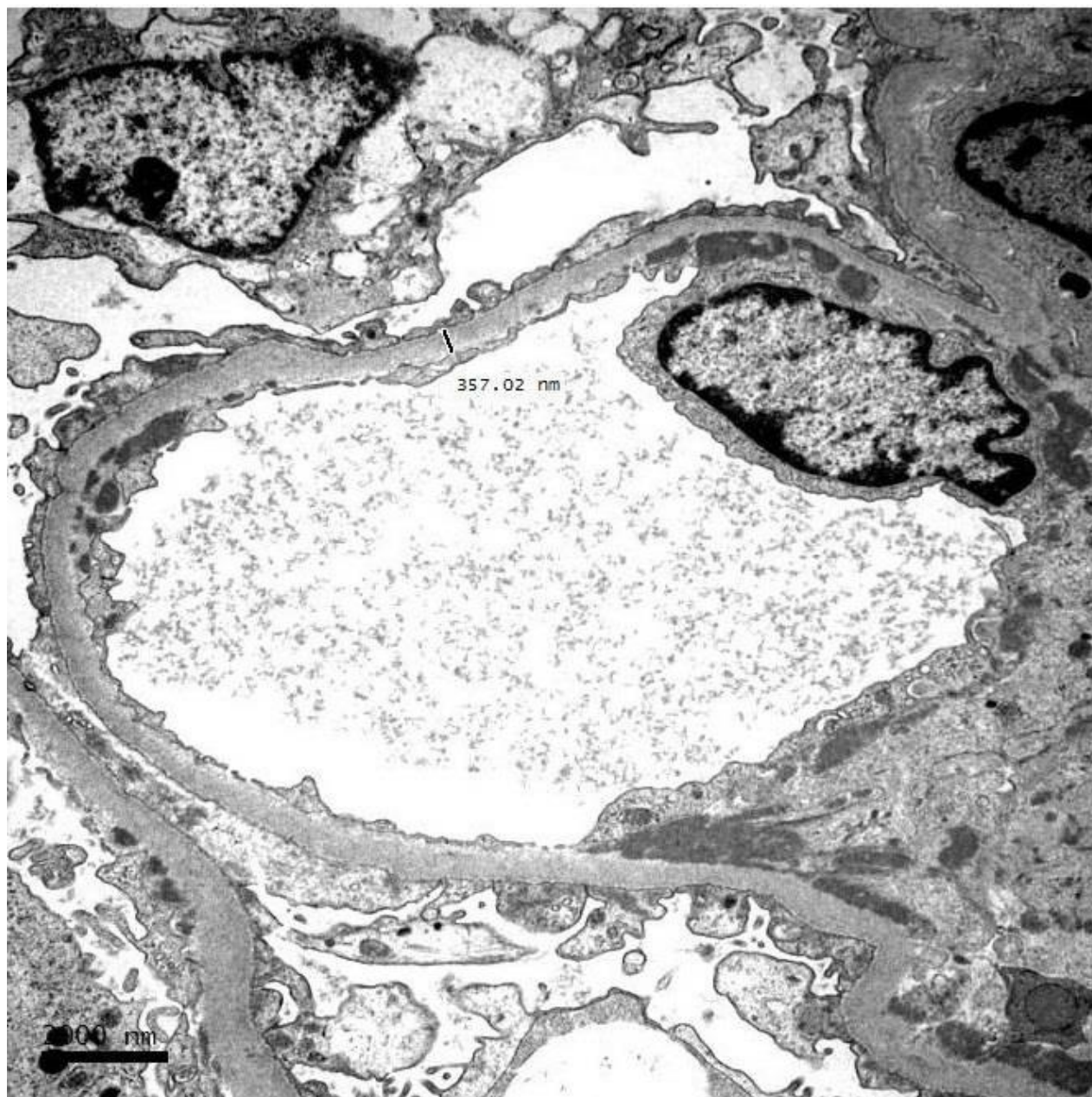
kappa

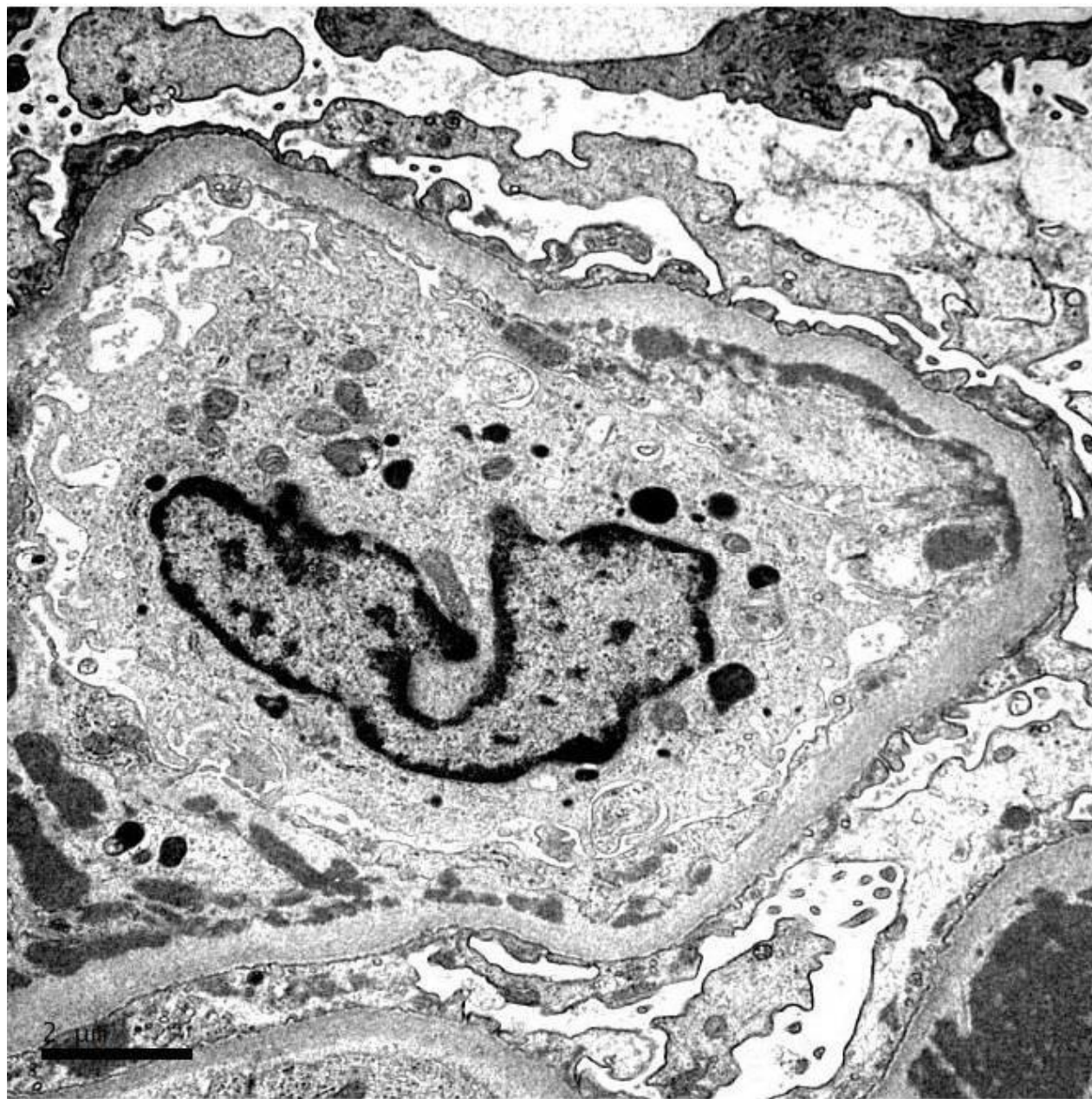

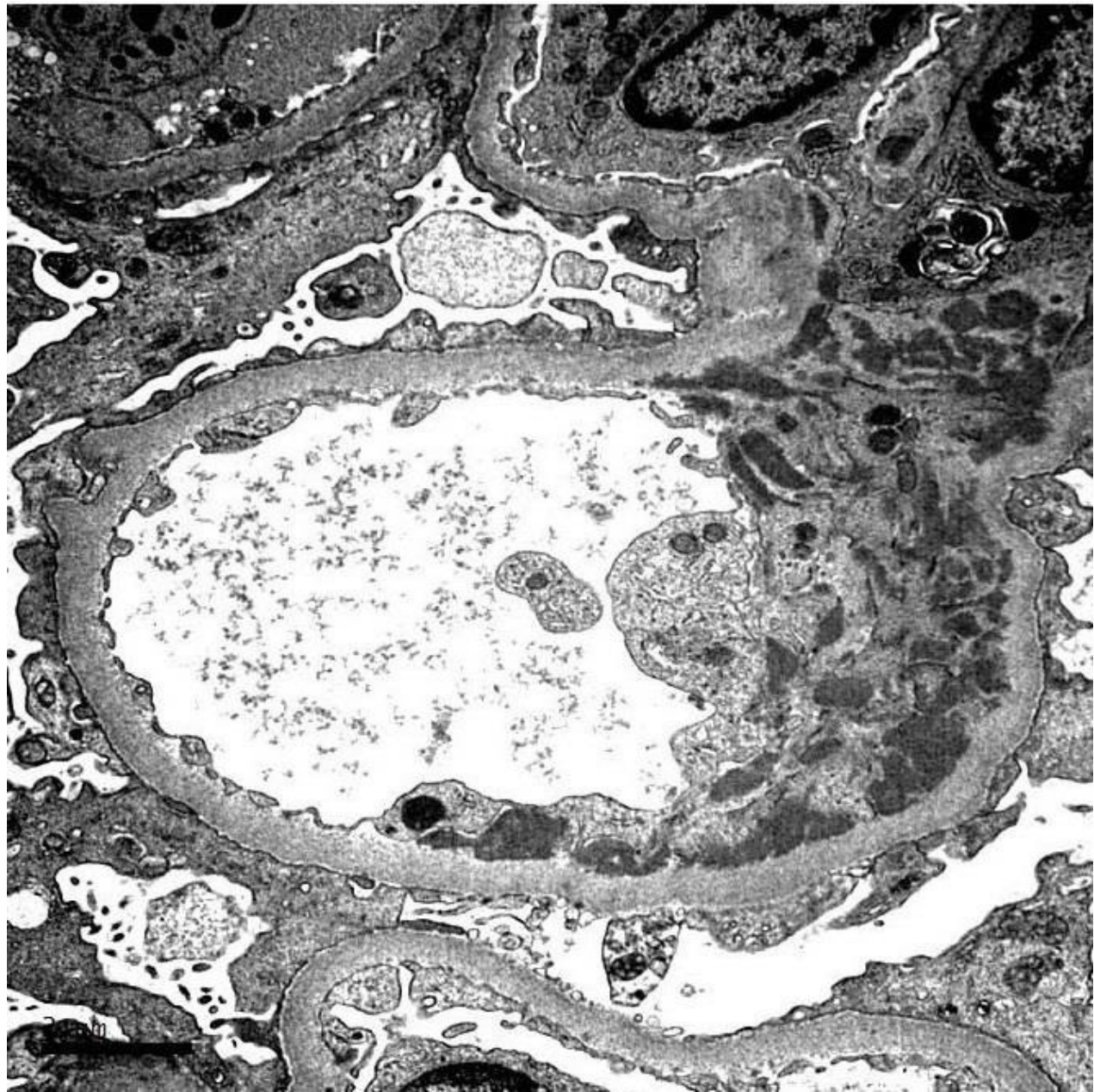
lambda

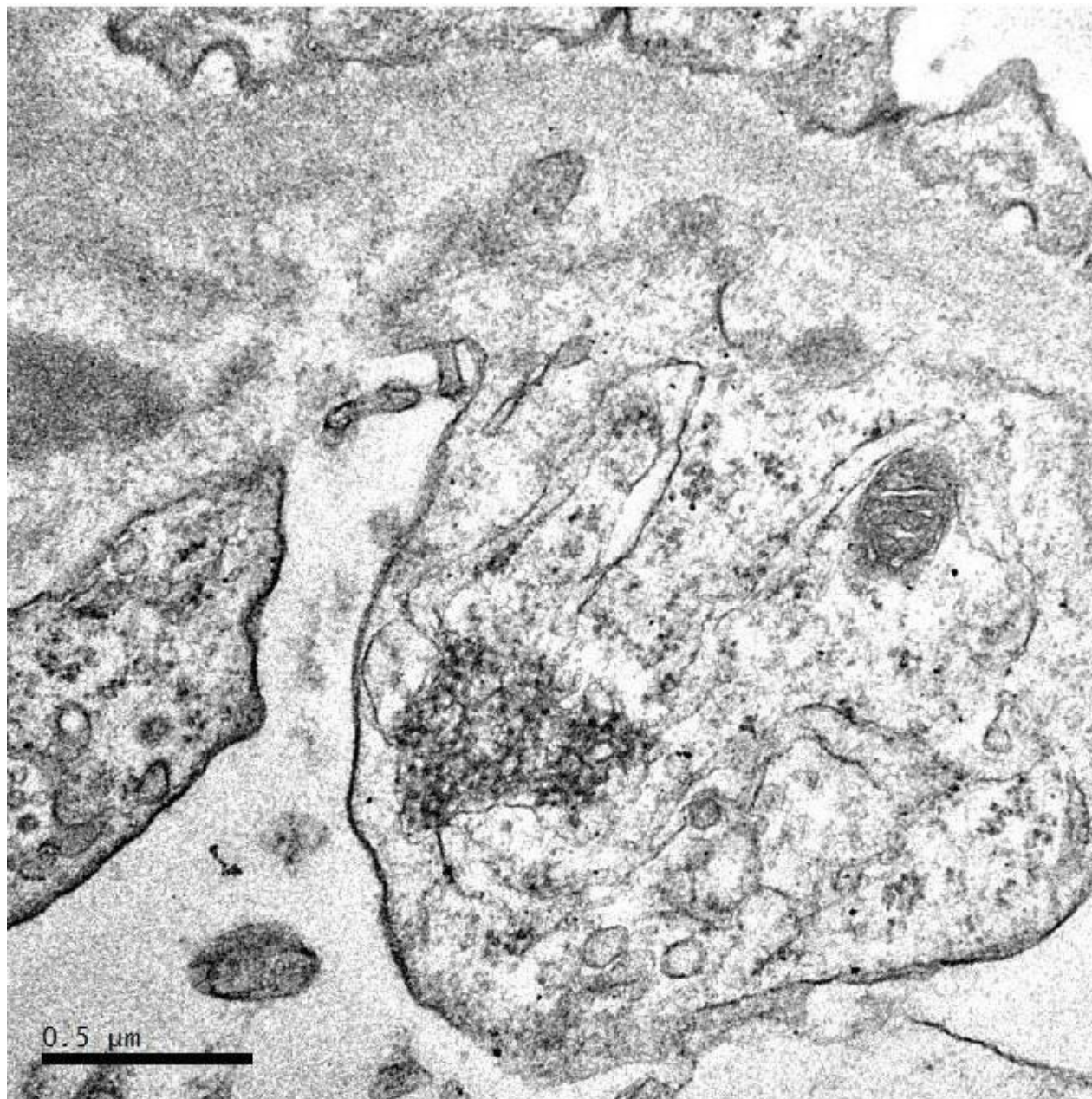














RENAL BIOPSY CLINICOPATHOLOGICAL WORKSHOP 2018

