Breast Pathology Course 2018

Case 26

51 year old female.
Right breast 9 o'clock lump. Excision biopsy performed.

Case contributed by Dr Mihir Gudi, Singapore

Singapore General Hospital
SingHealth
Division of Pathology

SingHealth DukeNUS
ACADEMIC MEDICAL CENTRE
PATHOLOGY

IAP
International Academy of Pathology
Singapore Division



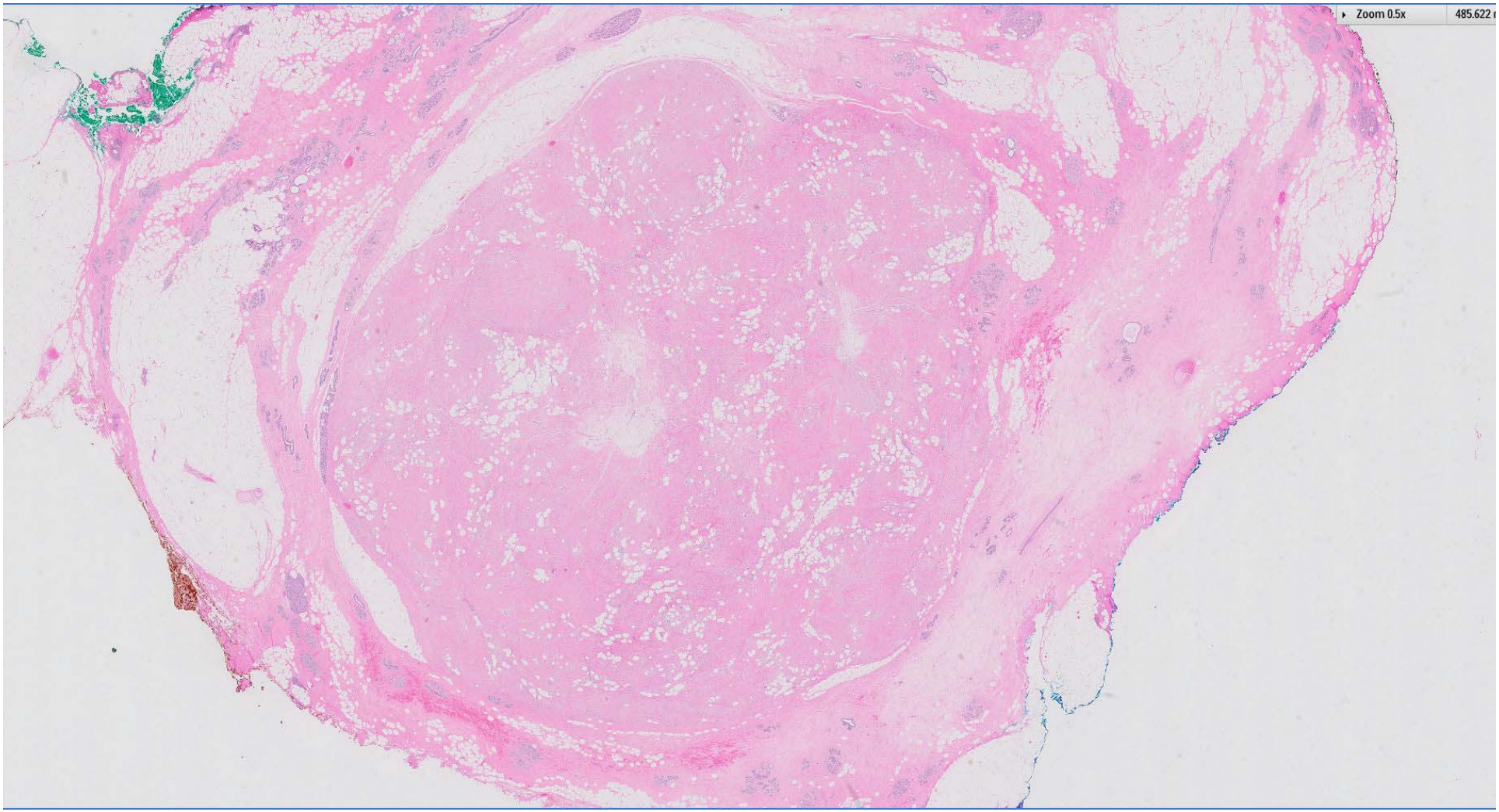
Zoom 0.5x

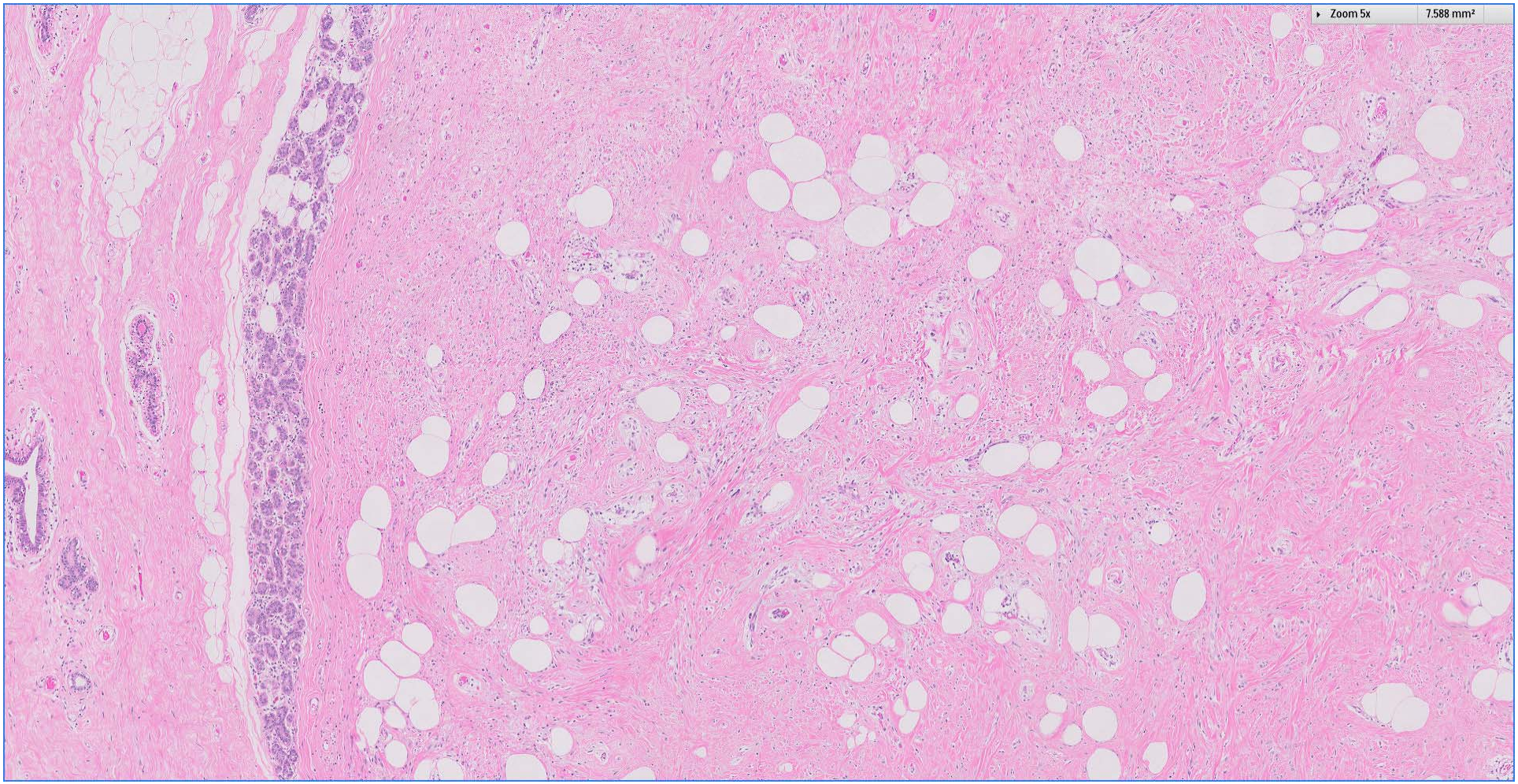
Zoom 5x
7.588 mm²

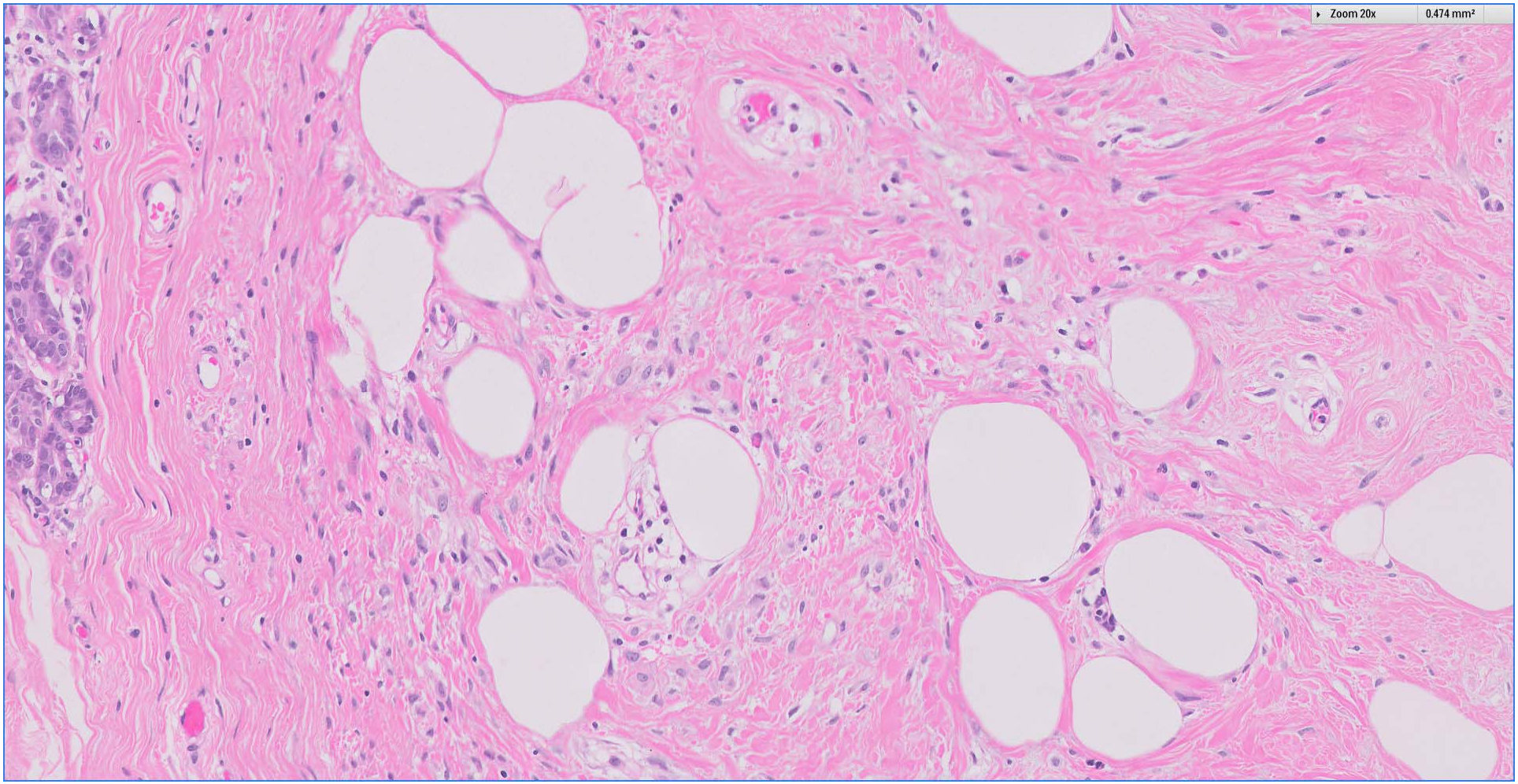
Zoom 20x
0.474 mm²

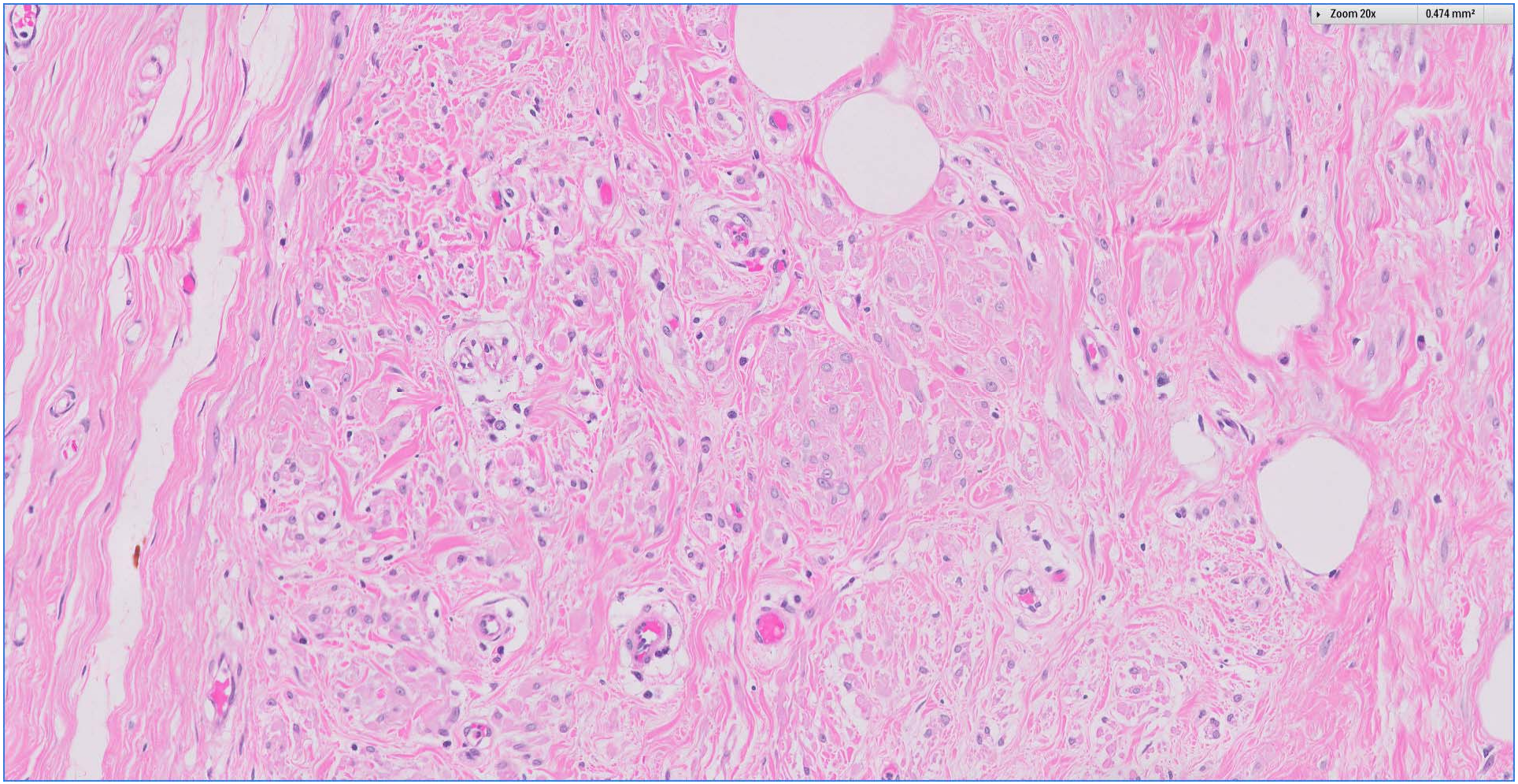
Zoom 20x
0.474 mm²

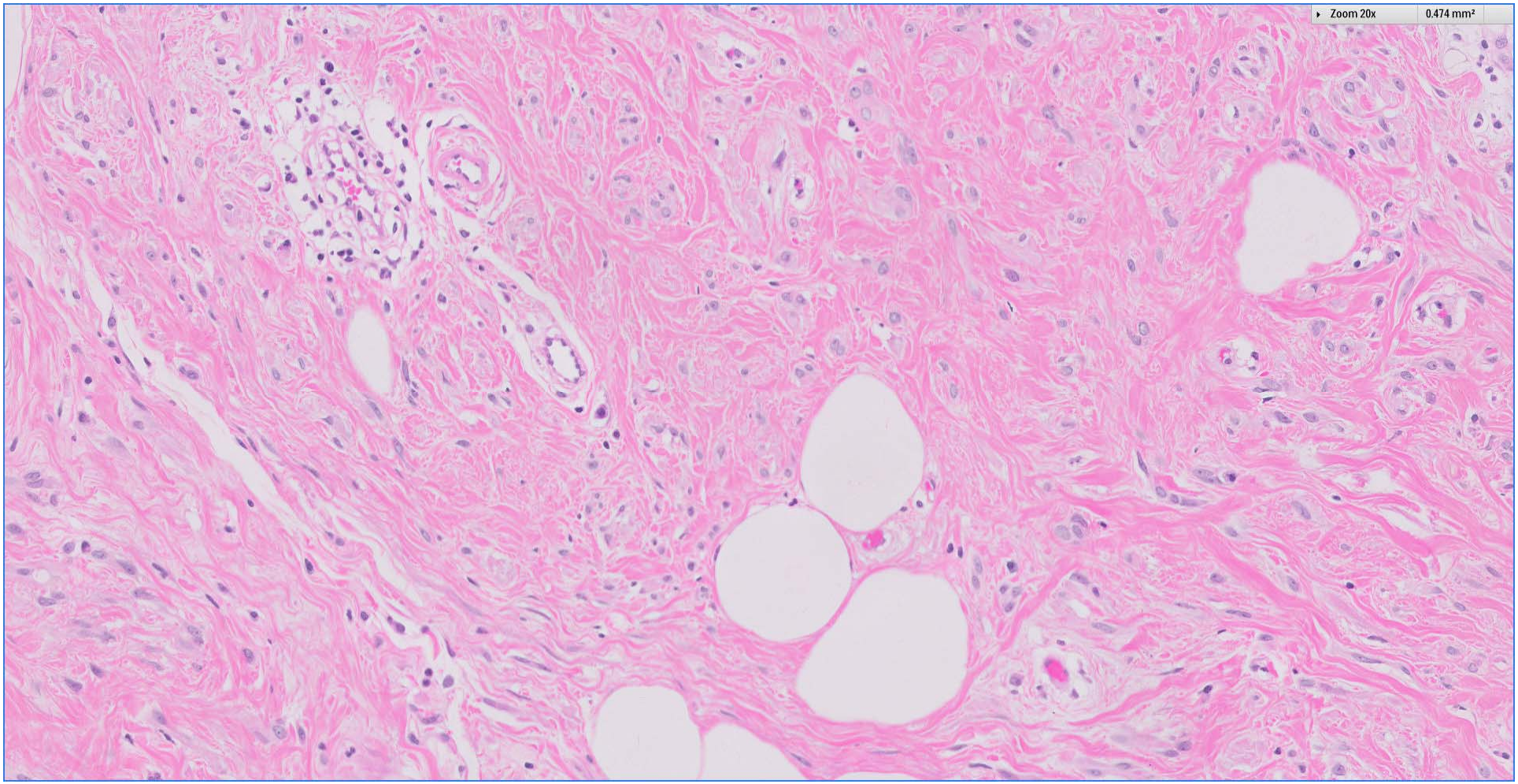
Zoom 20x
0.474 mm²

Breast Pathology Course 2018

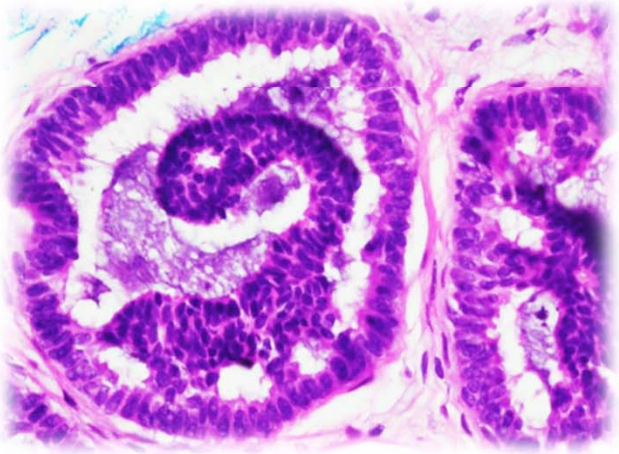

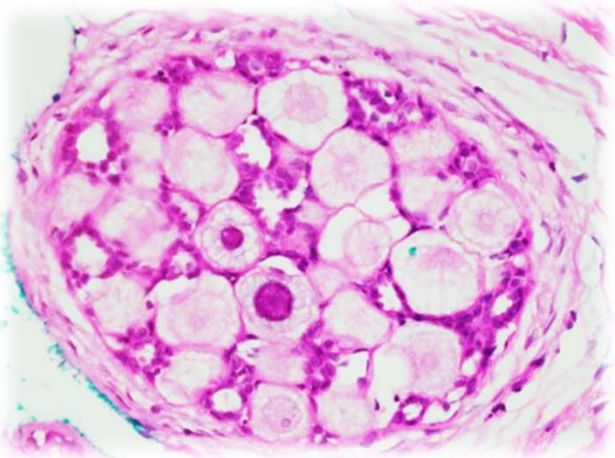

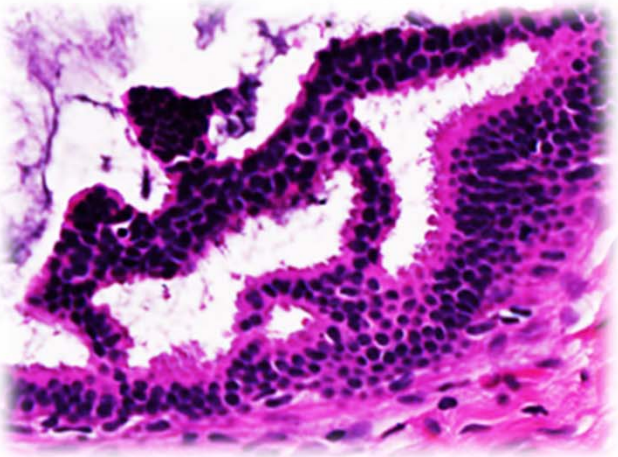

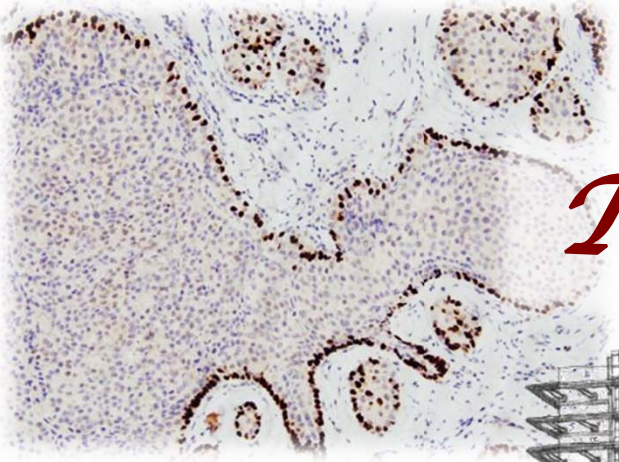

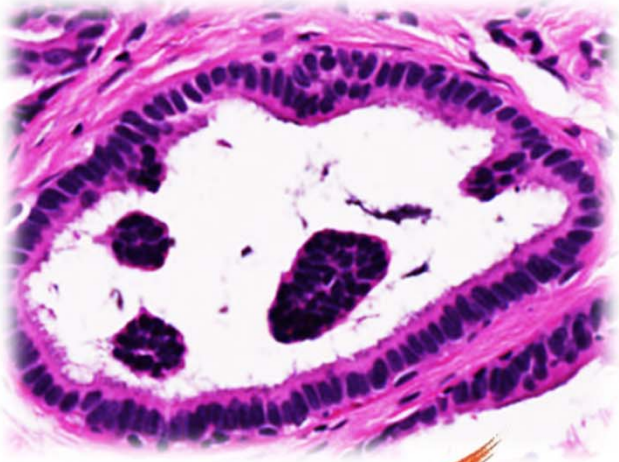

Thank you!



THE ACADEMIA, SINGAPORE GENERAL HOSPITAL 09.05.2014

Singapore General Hospital
SingHealth
Division of Pathology

SingHealth DukeNUS
ACADEMIC MEDICAL CENTRE
PATHOLOGY

IAP
International Academy of Pathology
Singapore Division