Case 1

- 77 year old female presenting with lump left breast.
- Indeterminate on imaging.

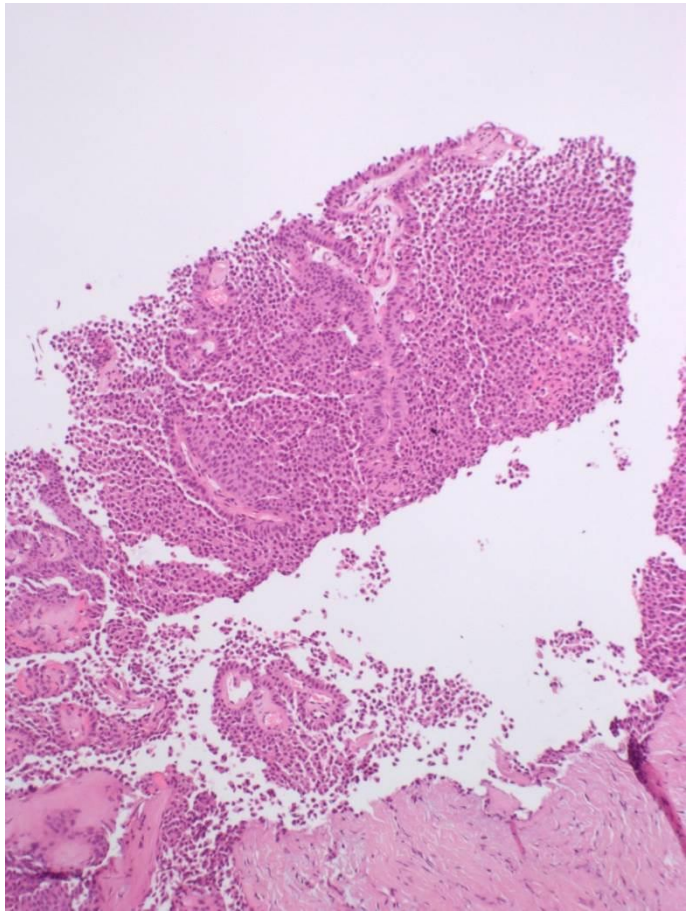

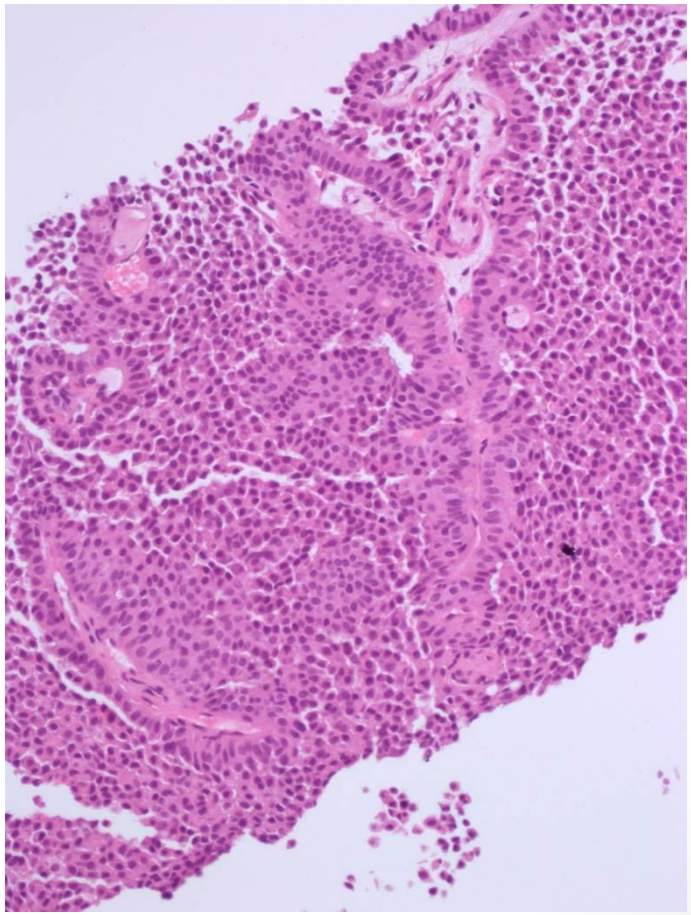

Case 1

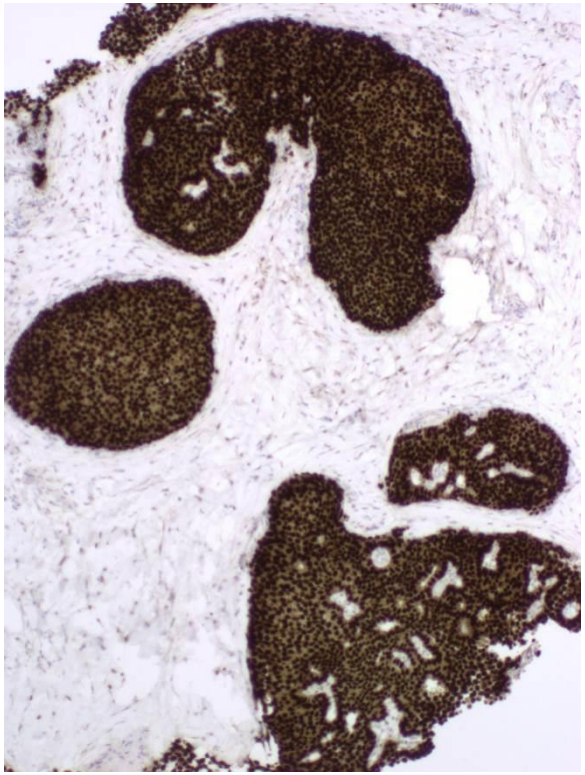

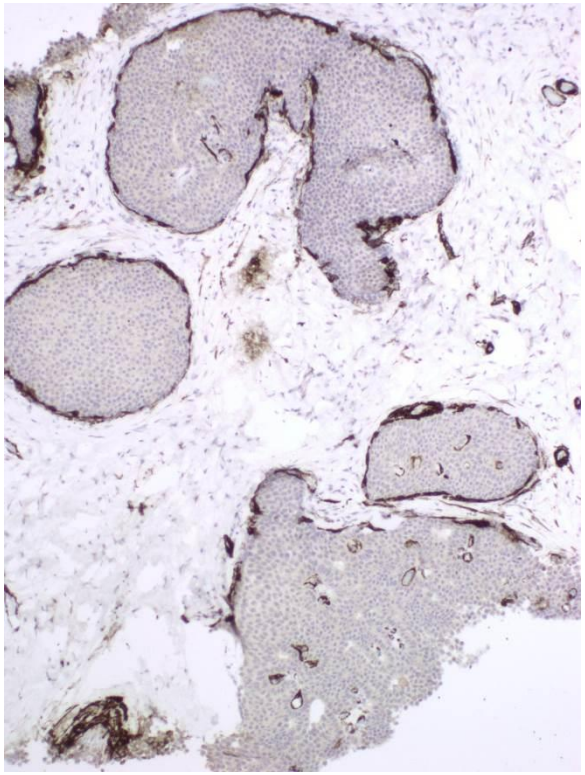

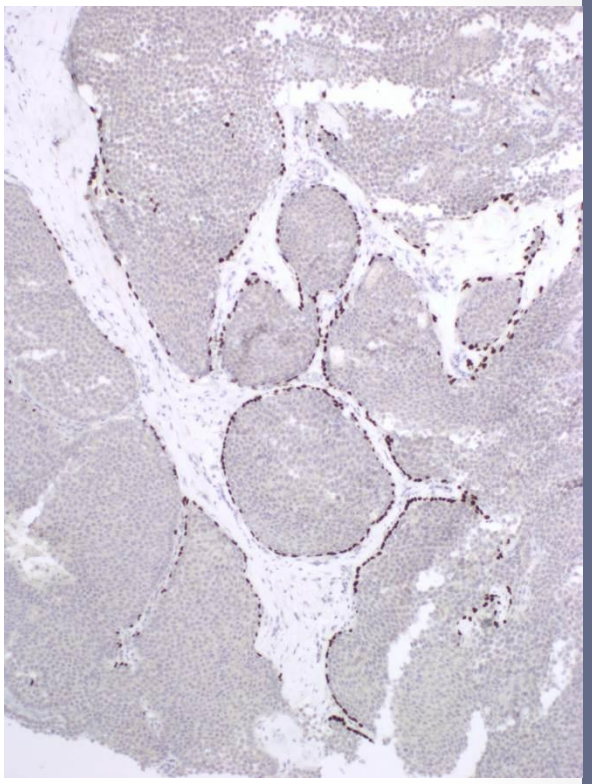

Core biopsy diagnosis: In situ solid papillary carcinoma (B5a)

Case 1

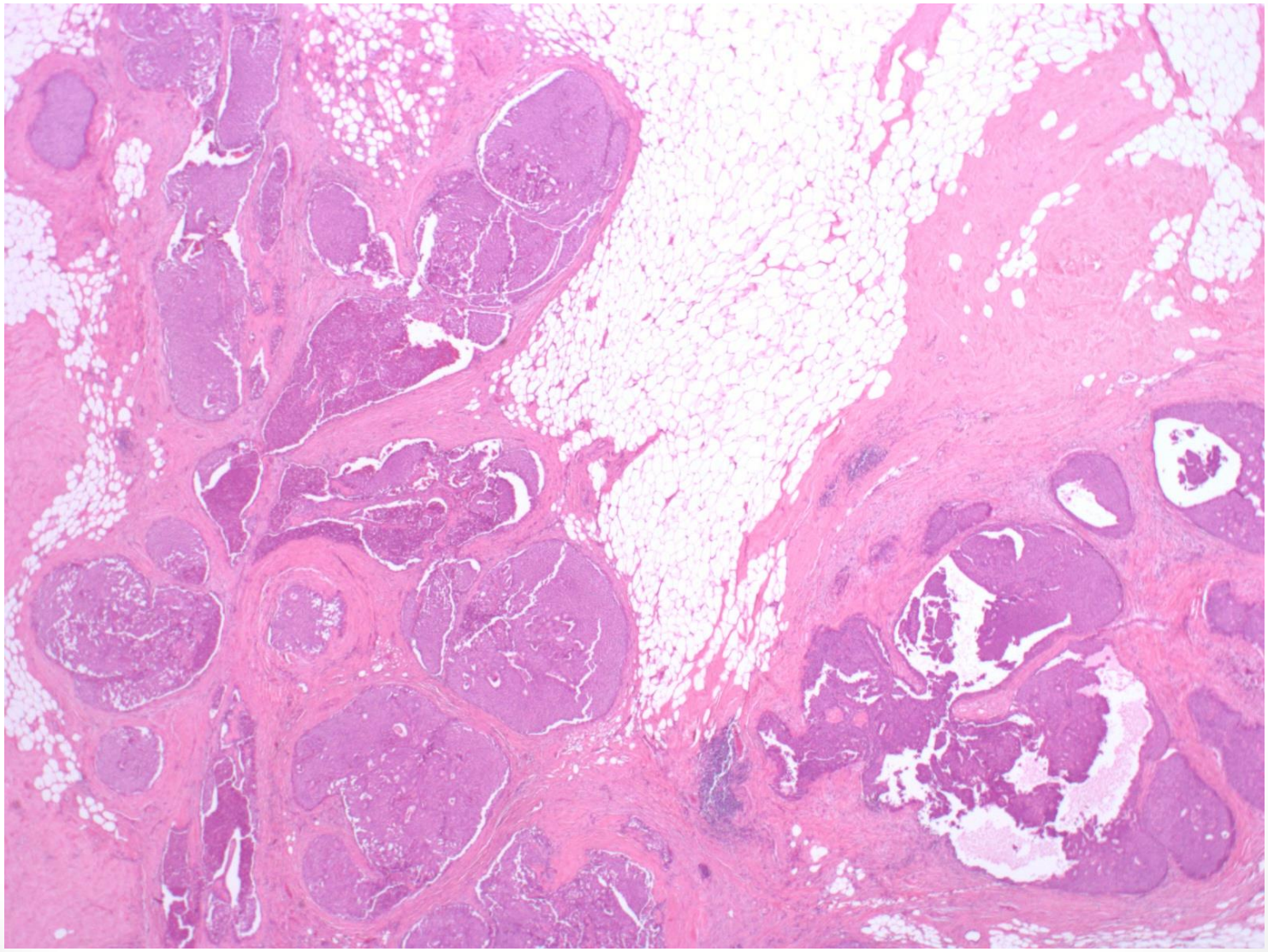

Case 1

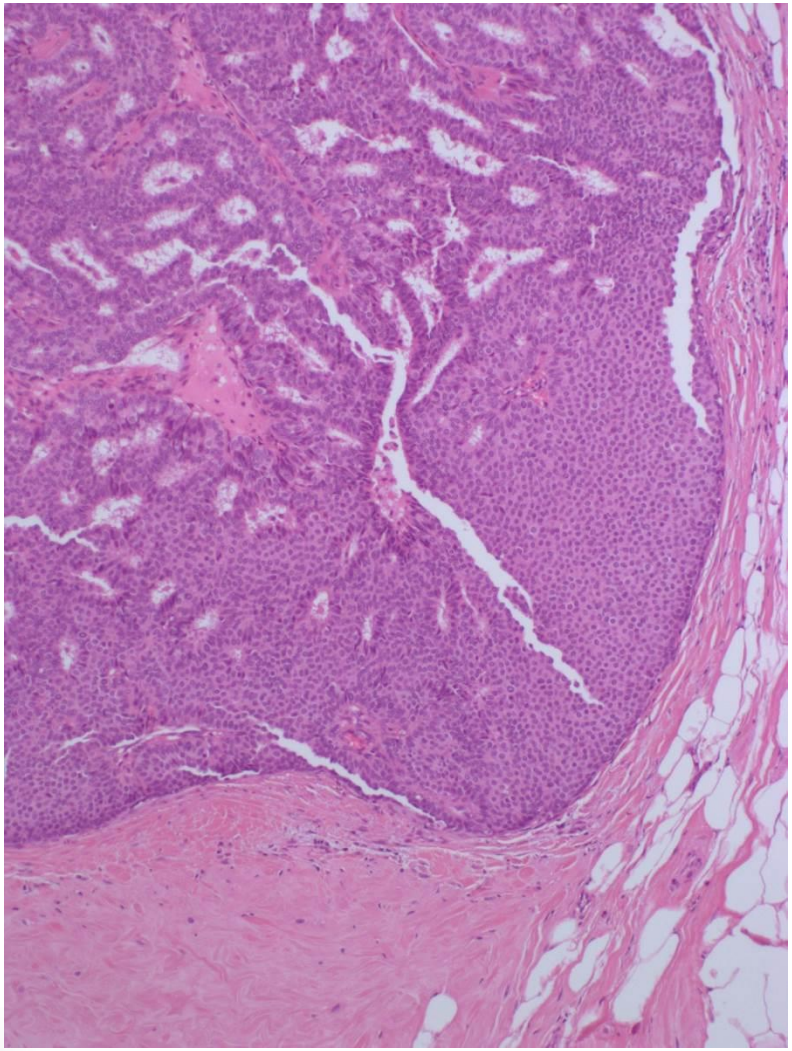

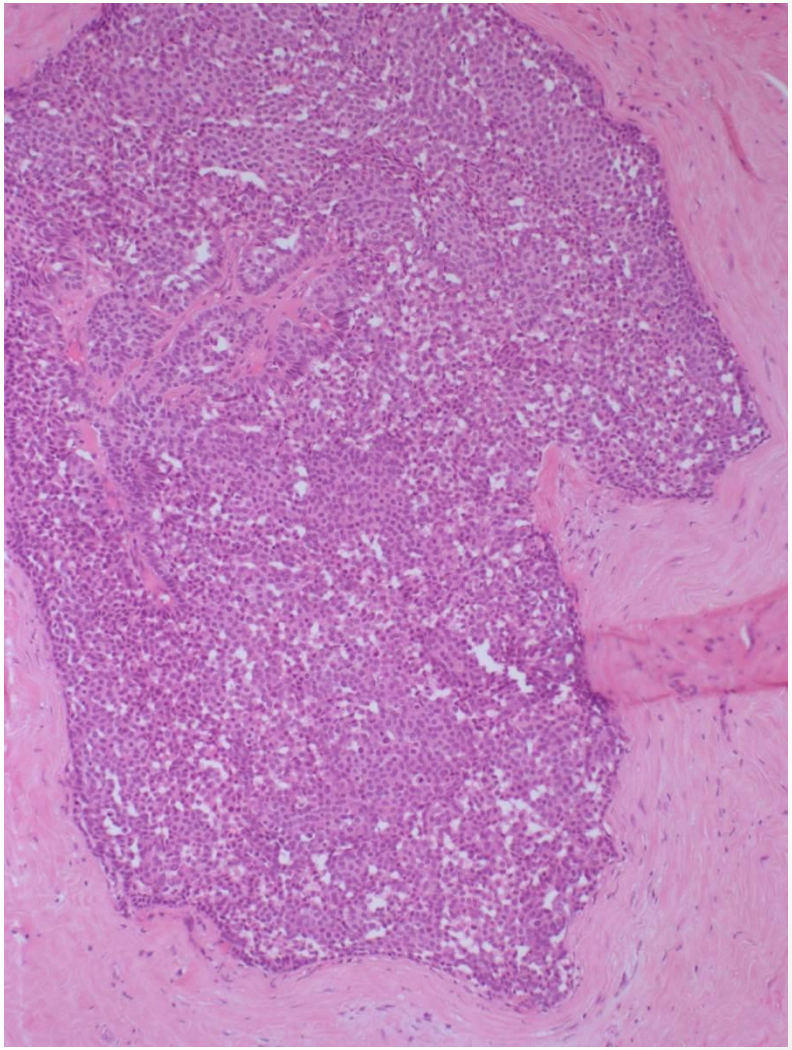

Case 1

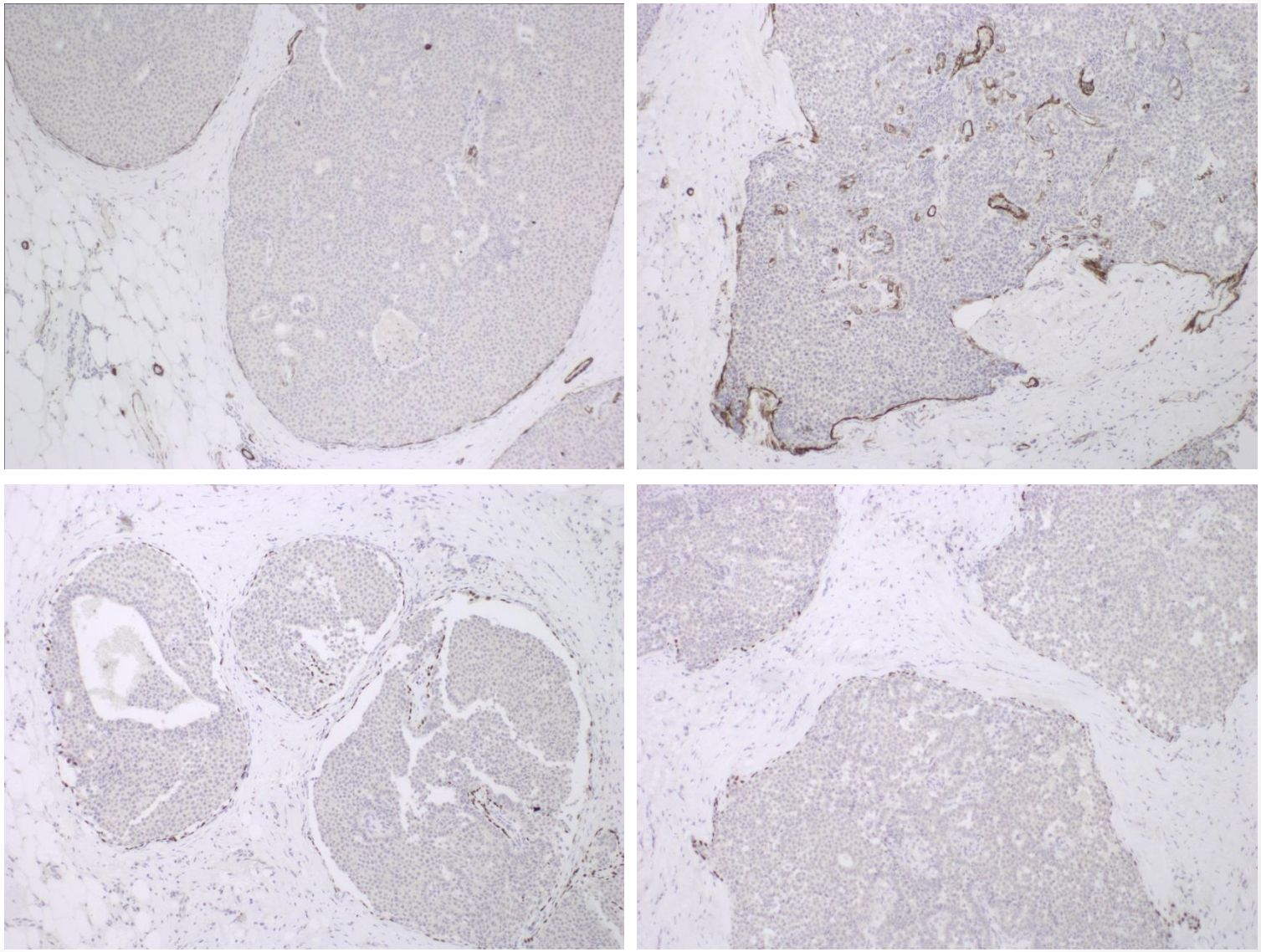

Cambridge Breast Unit

Case 1

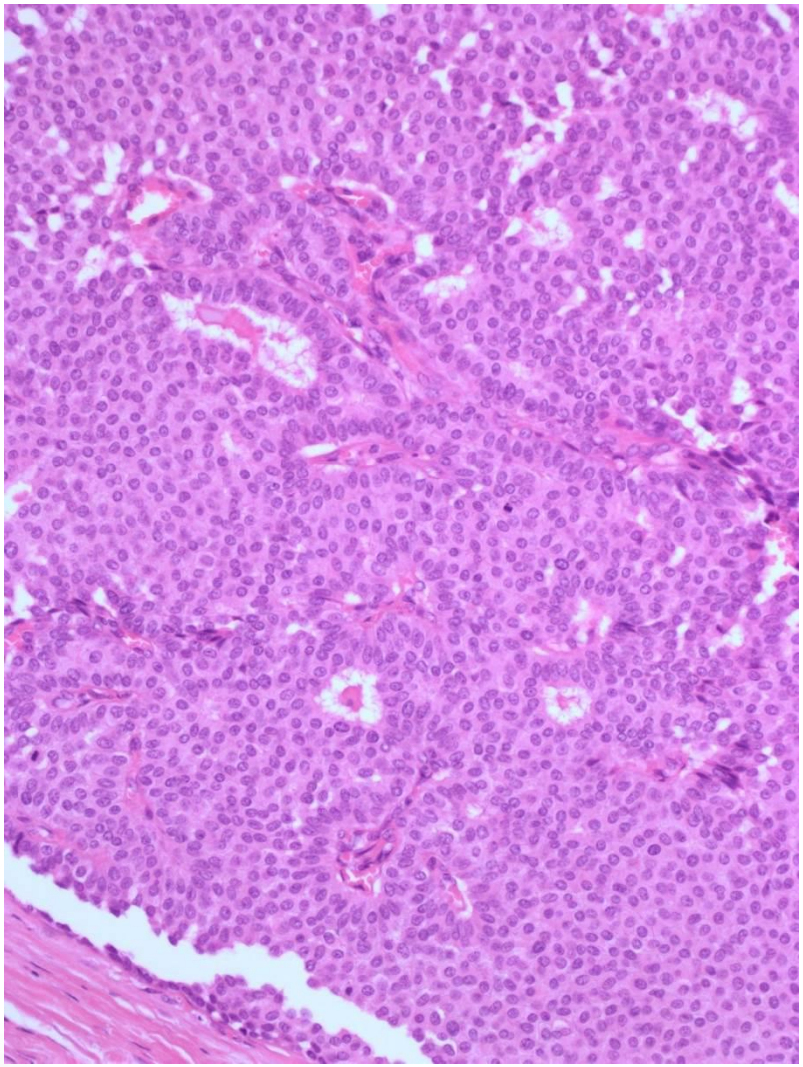

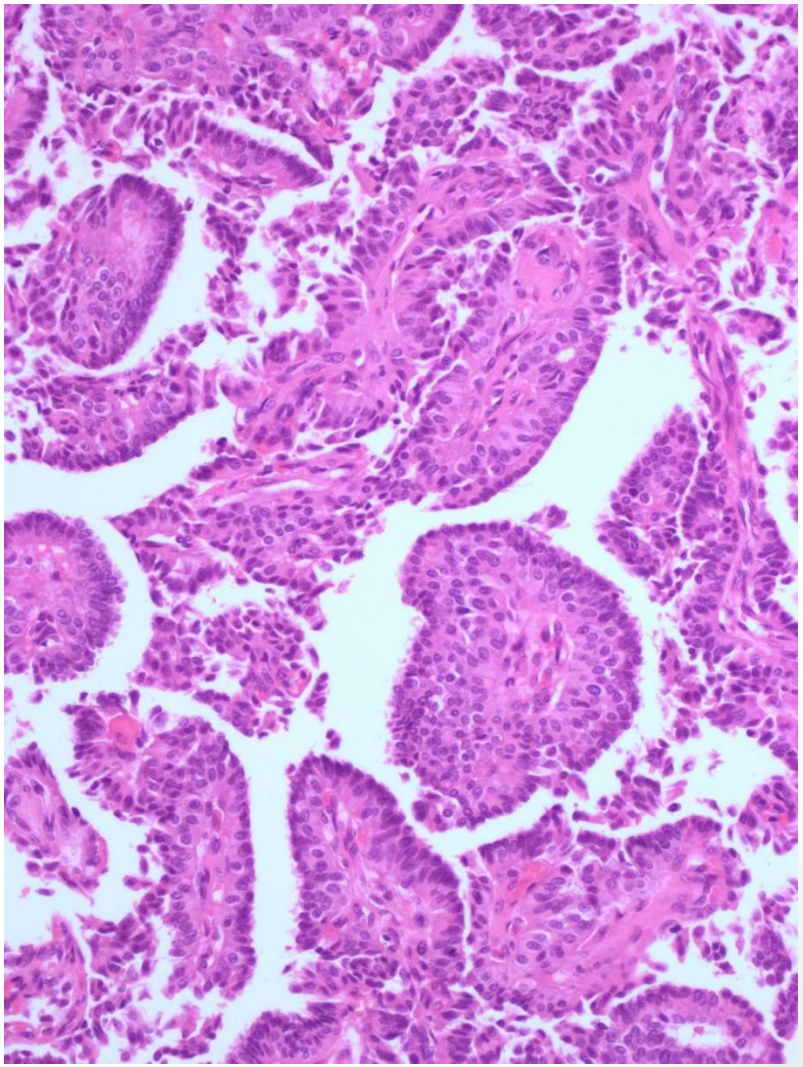

Case 1

Final diagnosis: Solid papillary carcinoma in -situ

Cambridge Breast Unit

Solid Papillary Carcinoma

- Previous edition subtype of EPC – now separate entity
- Expansive cellular nodules with delicate fibrovascular cores that are inconspicuous at low power
- Neuroendocrine differentiation, spindle cell morphology and mucin production are common
- Myoepithelial cells may be present or absent surrounding the nodule

Solid Papillary Carcinoma

- Presence of outer myoepithelial cell layer, or rounded nodular masses without an infiltrative pattern are regarded as DCIS
- Rare variants with irregularly shaped islands arranged in a jigsaw pattern in a desmoplastic stroma, without a MEC layer on IHC = invasive solid papillary carcinoma
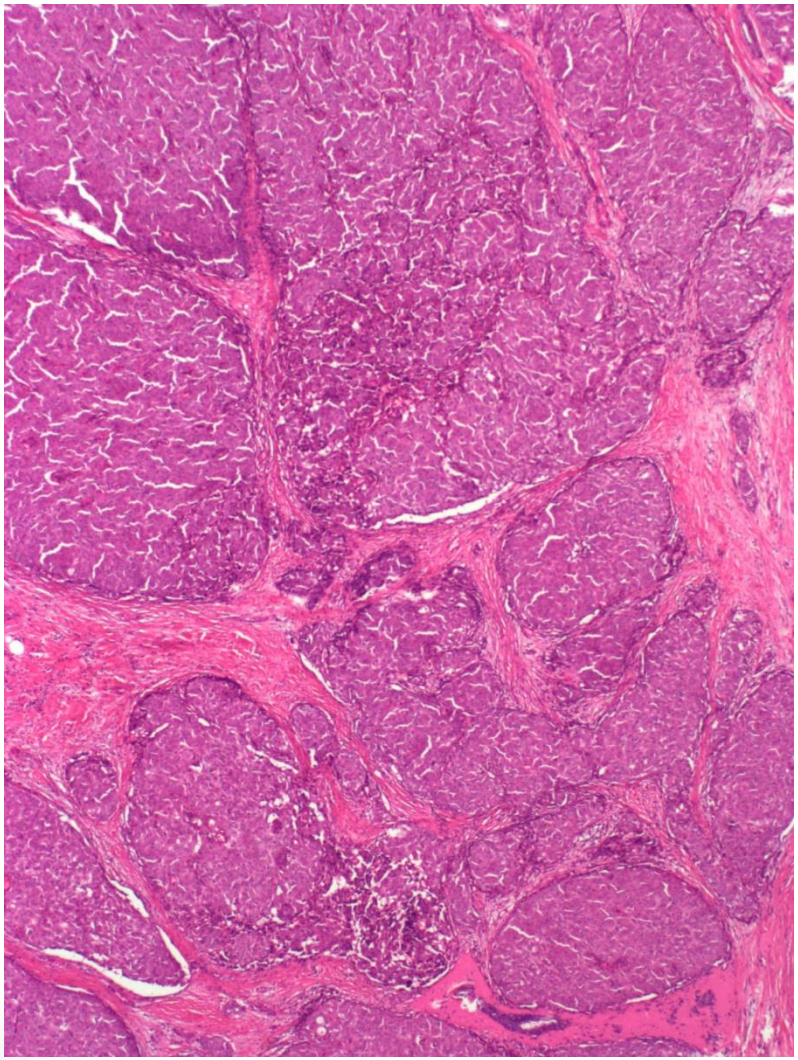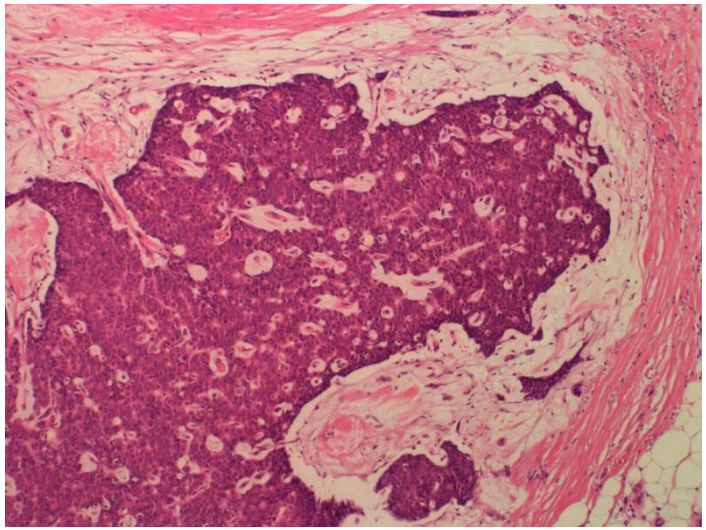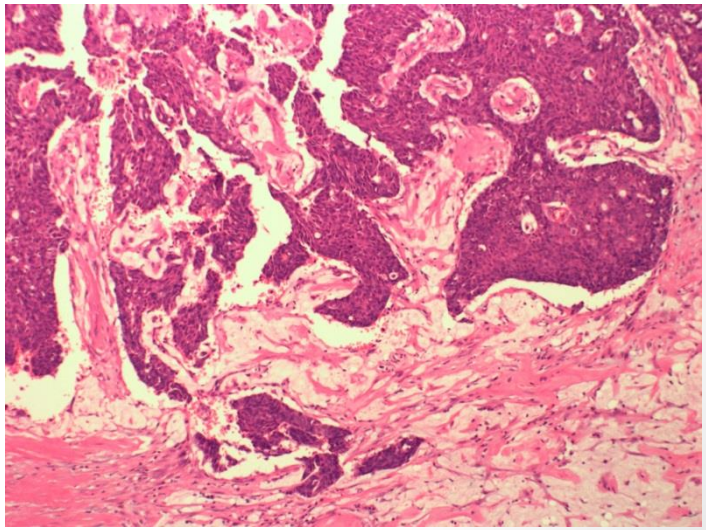
Solid Papillary Carcinoma