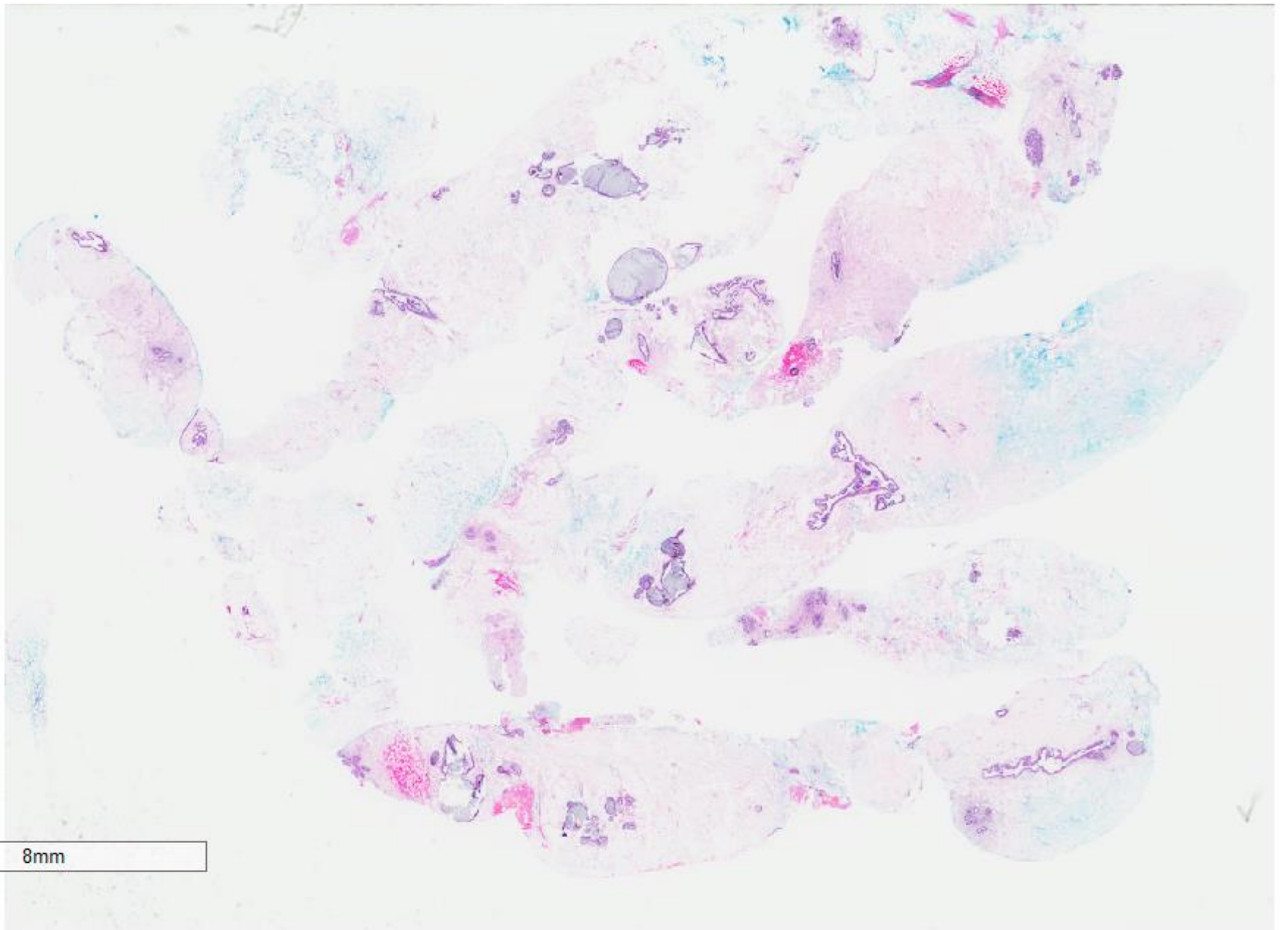
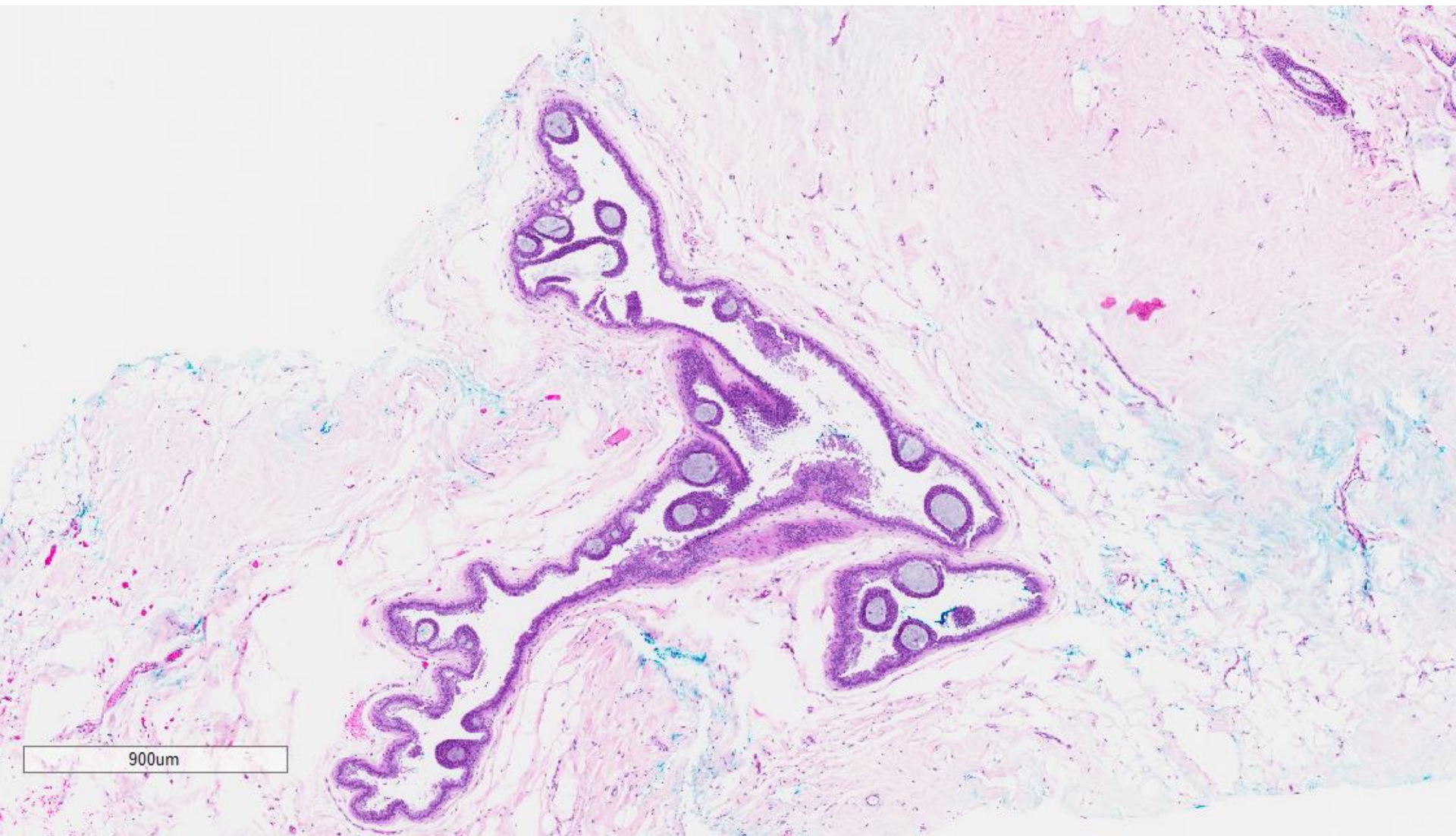


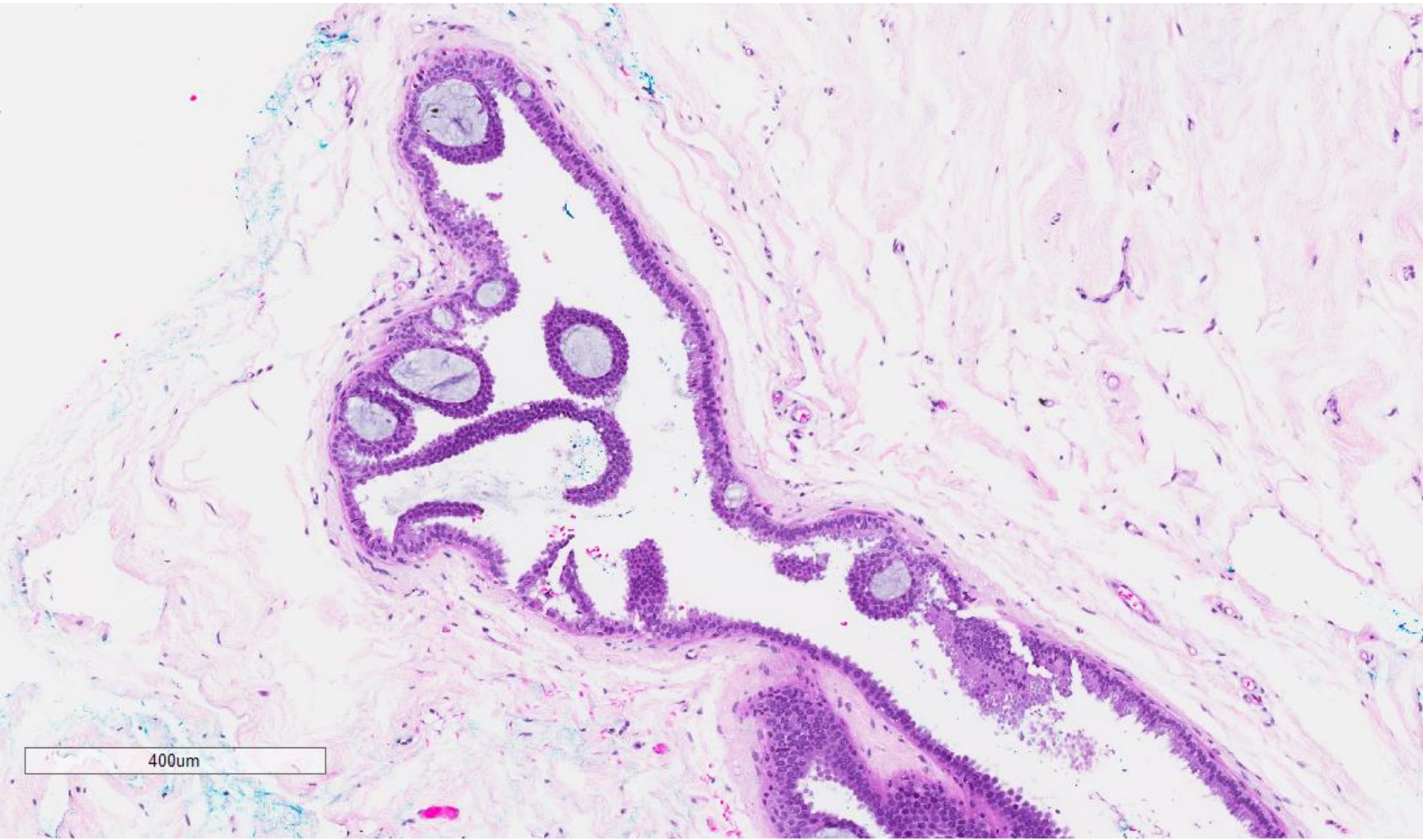
Case 24

43 year old lady underwent core biopsy
of screen detected mammographic
calcifications of the left breast.

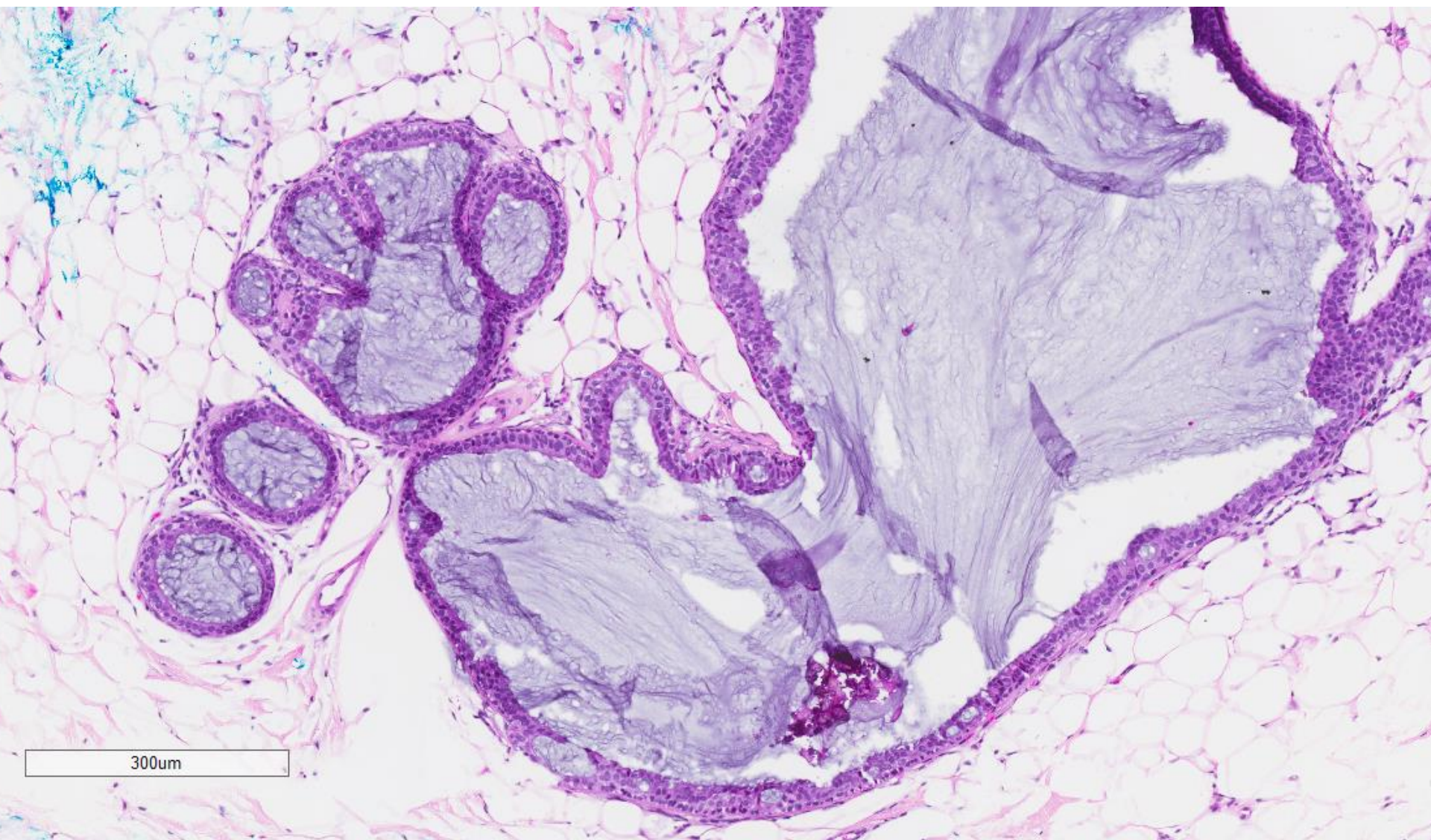


8mm

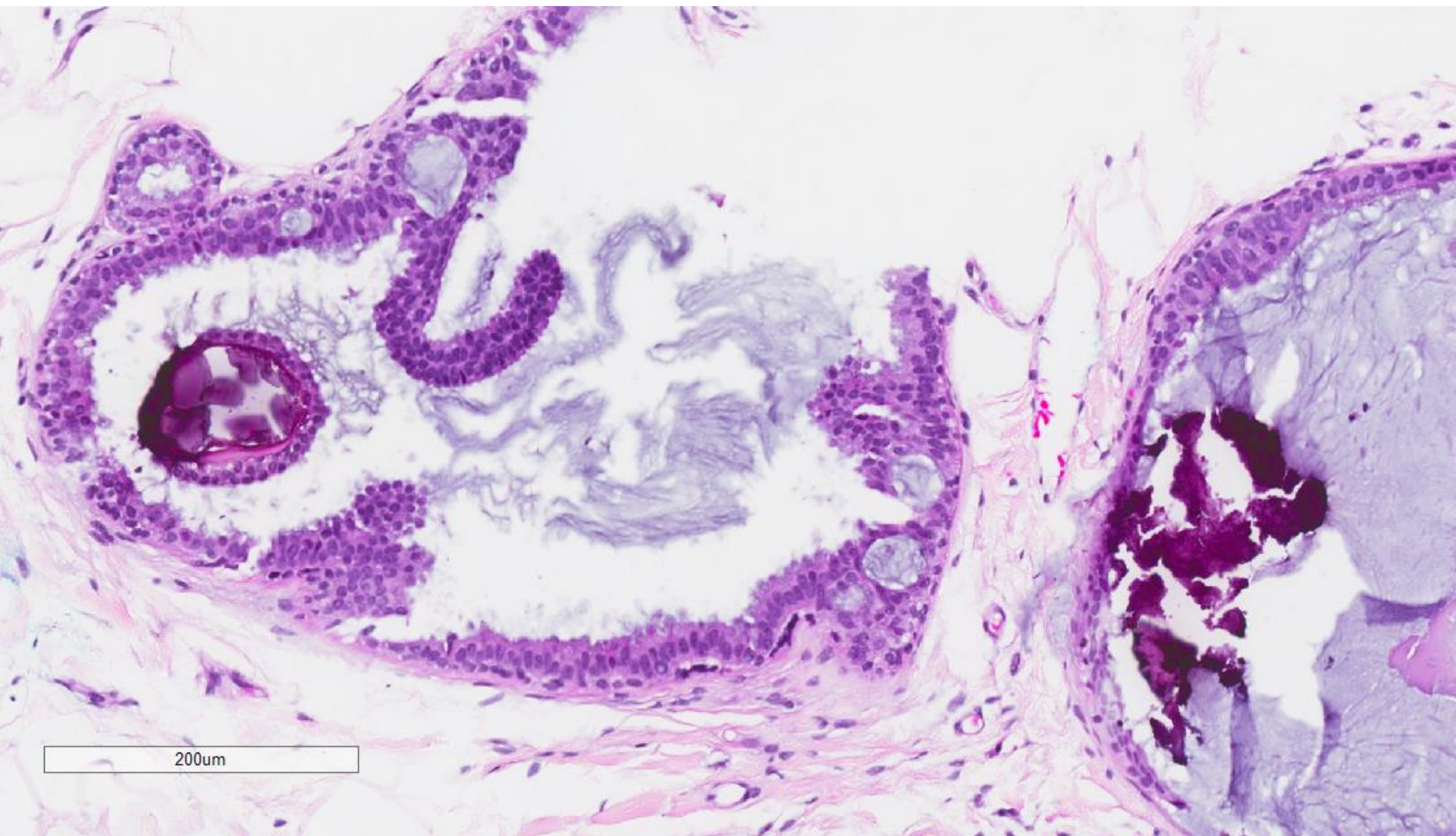




400um



300um



200um

Mucocele-like lesion with atypical ductal hyperplasia, calcifications present