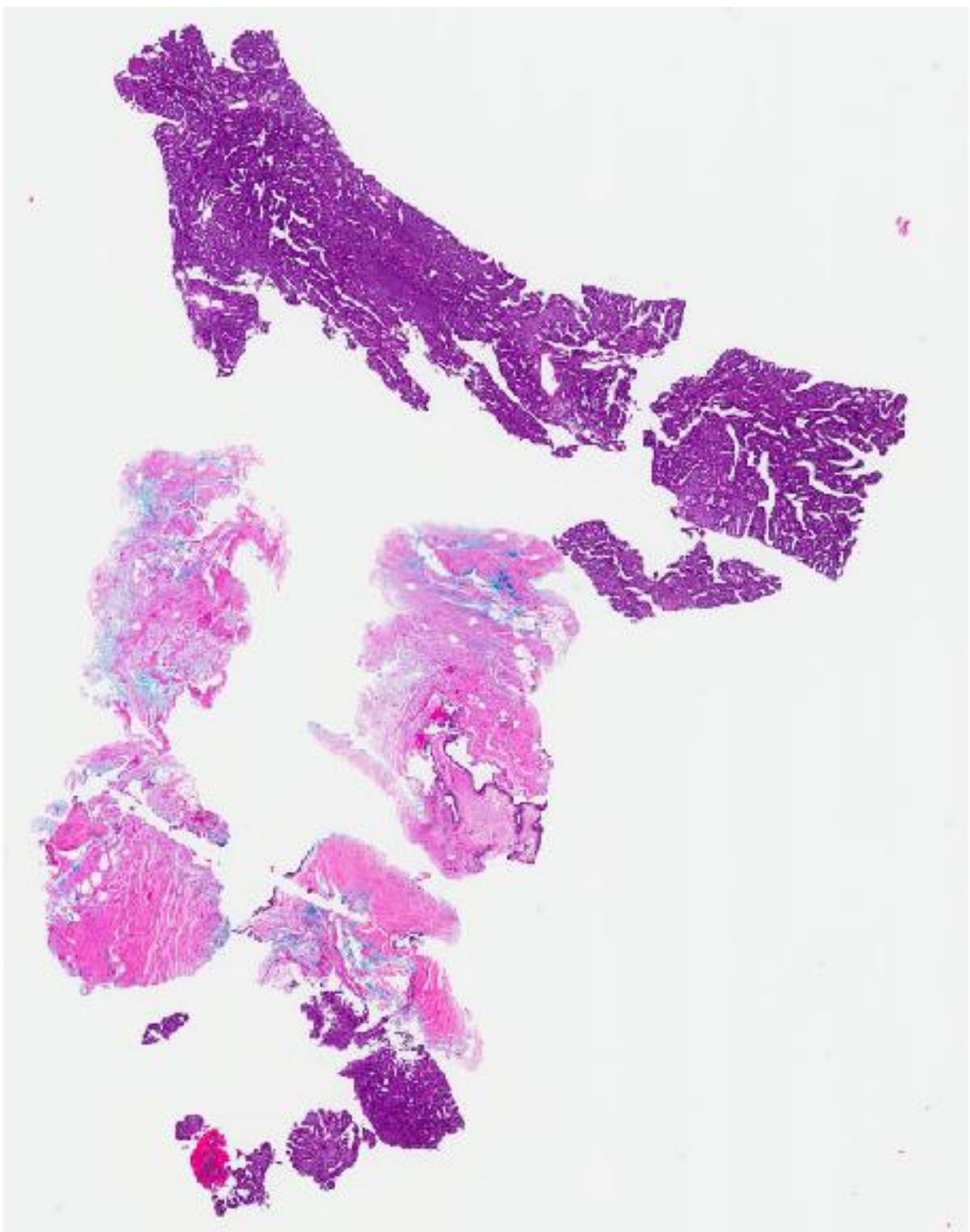
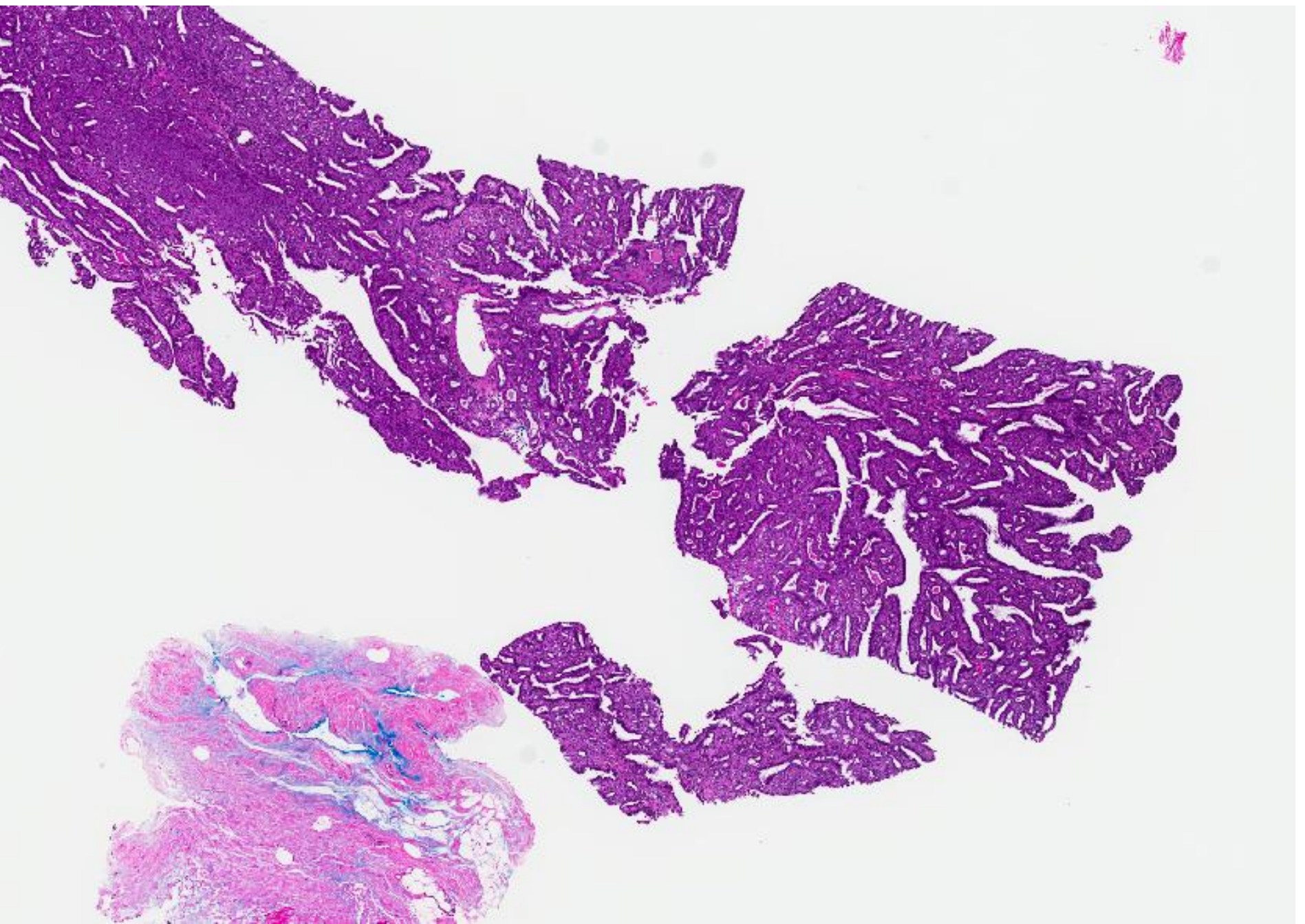


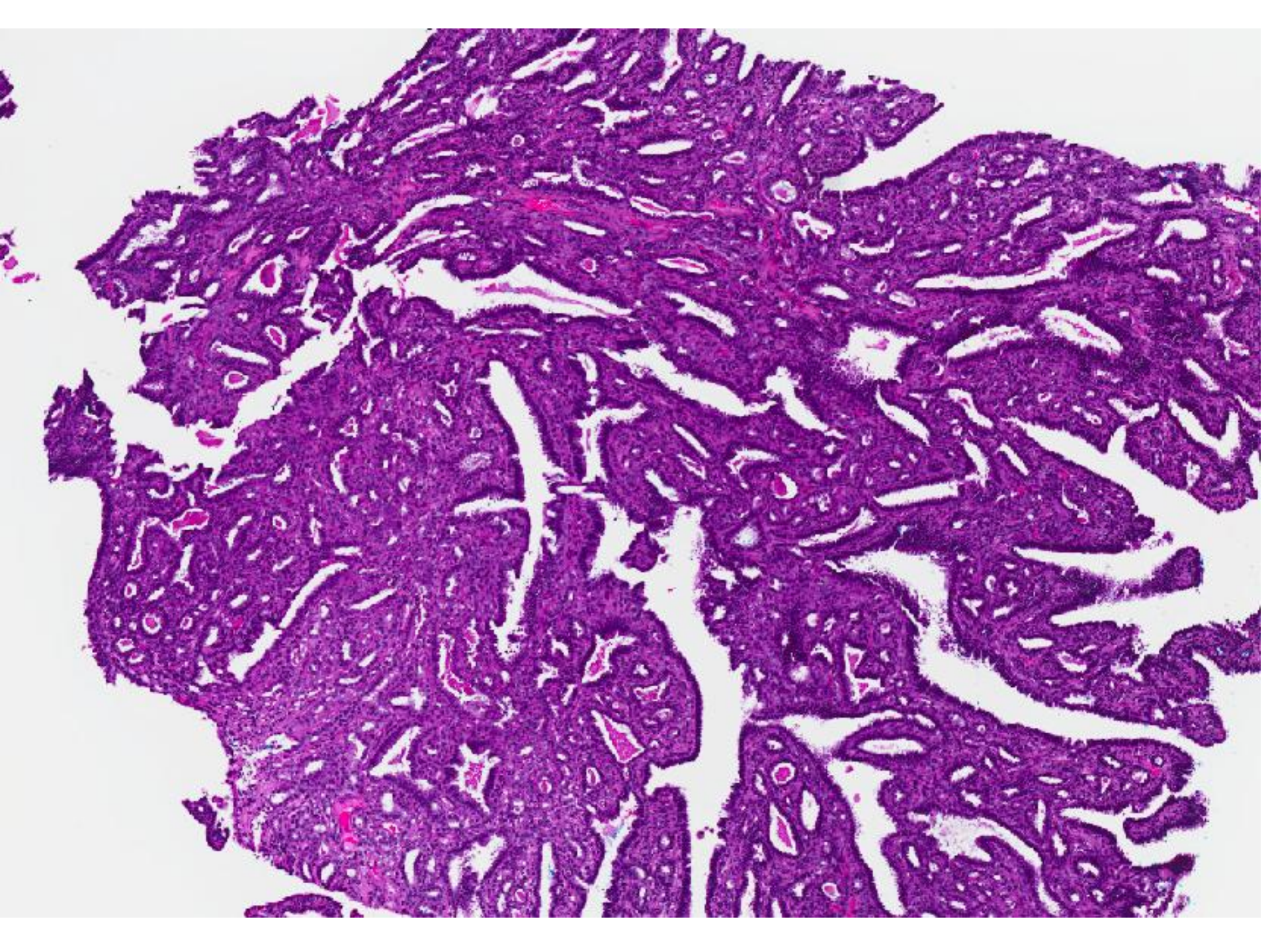
CASE 14

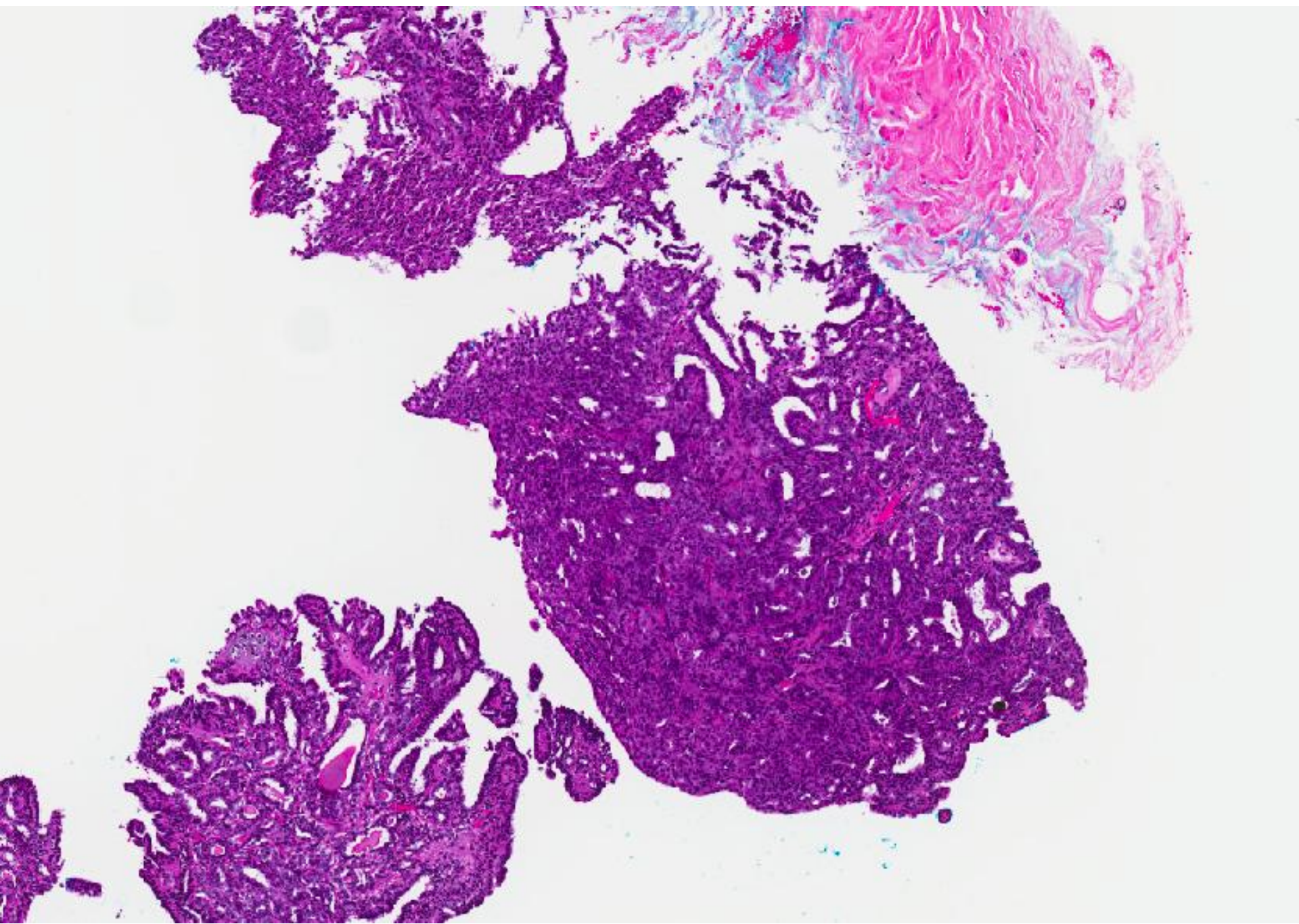
45 year old Chinese lady was radiologically detected with a 15 mm nodule in the right breast, located at the 8 to 9 o'clock position.

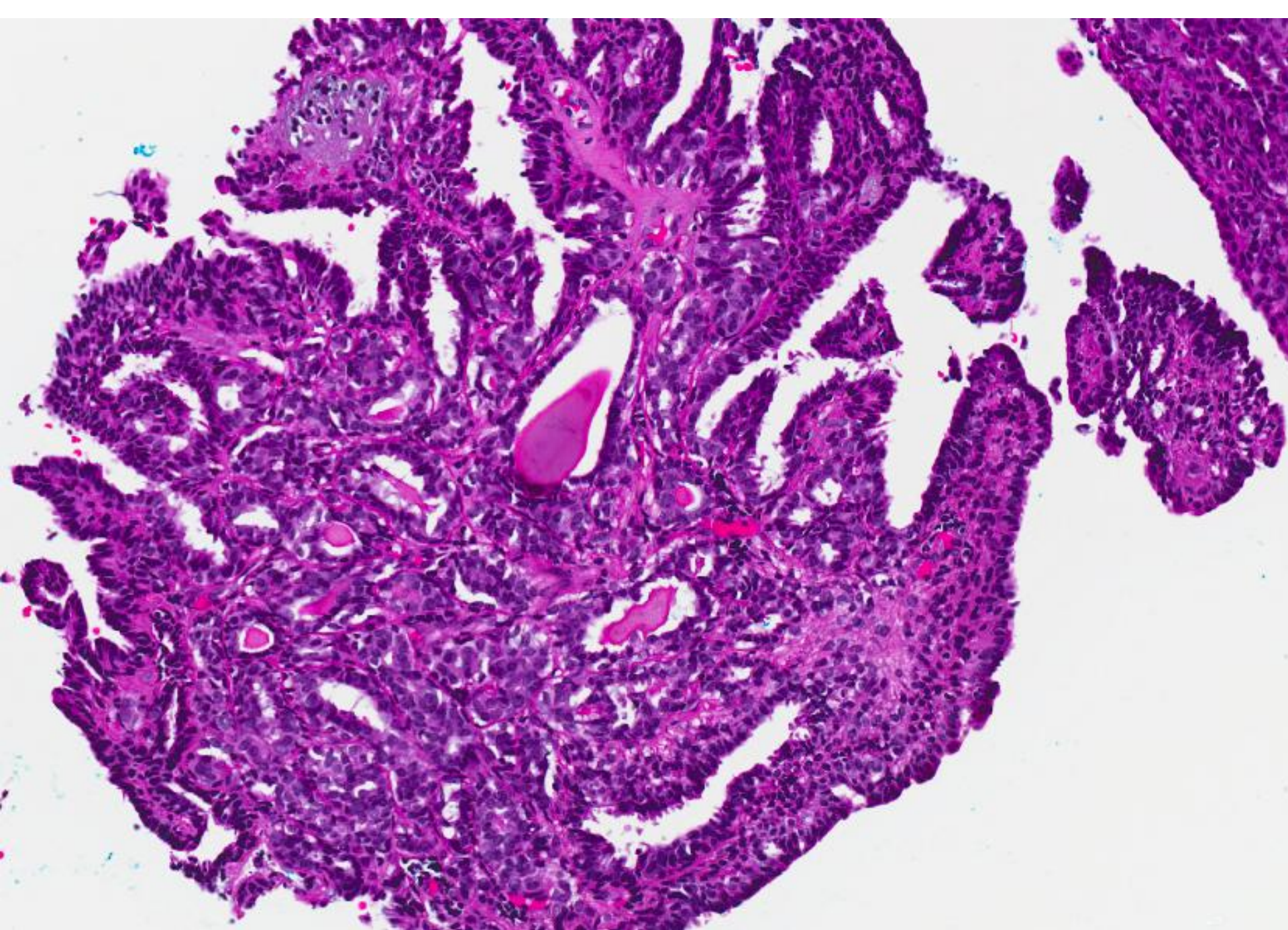
An ultrasound guided core biopsy was performed.

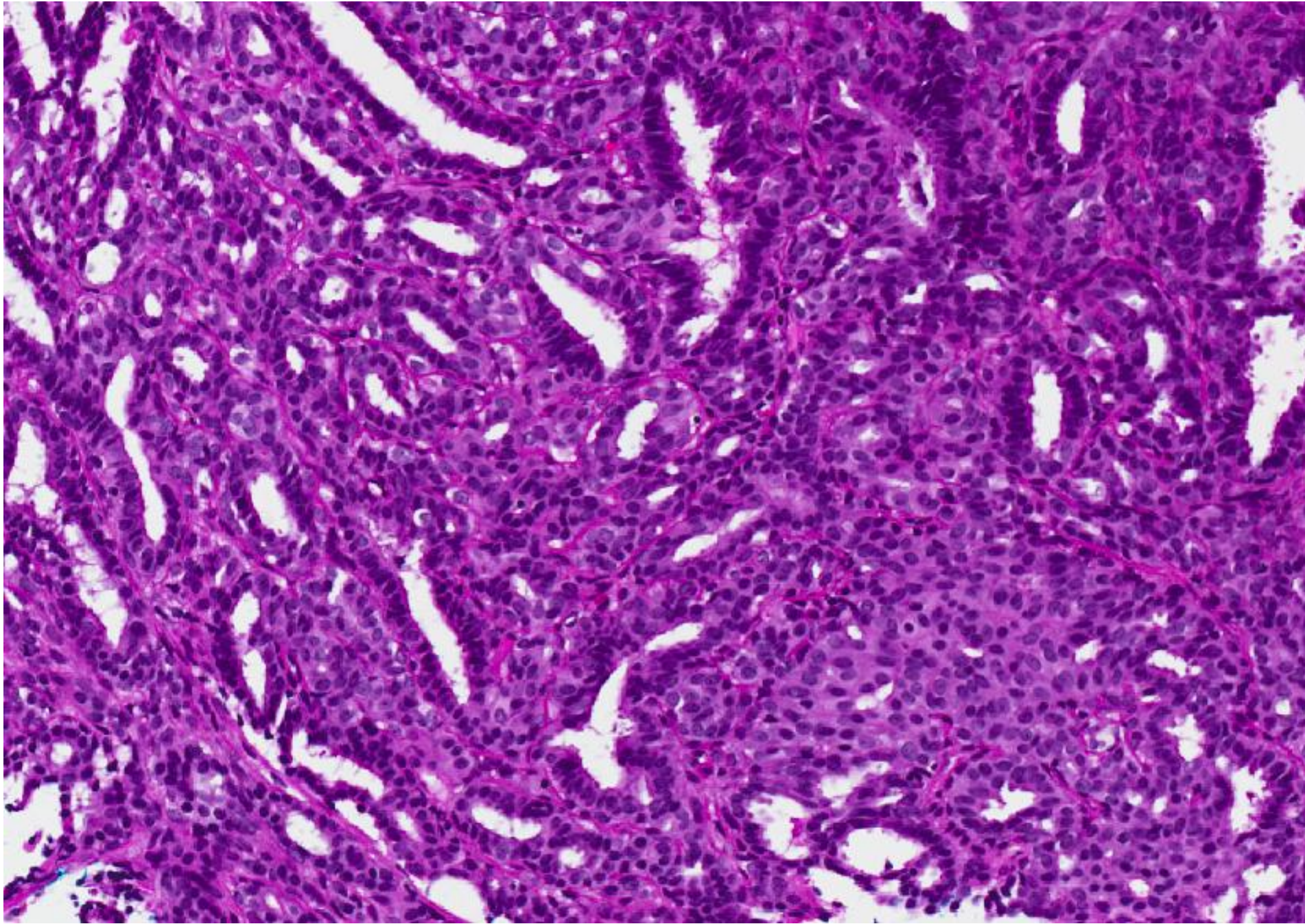












Diagnosis

- Intraductal papilloma.