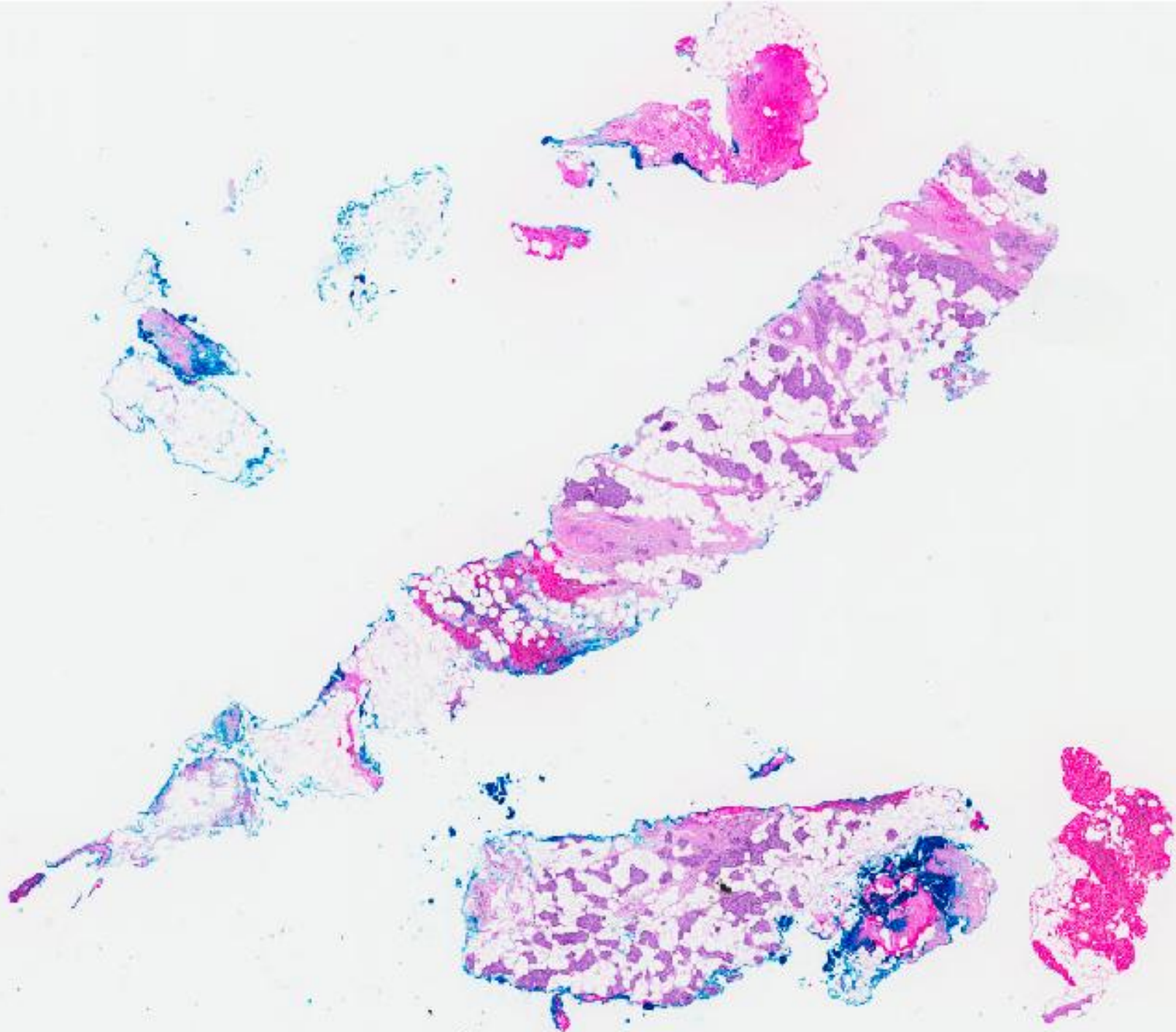


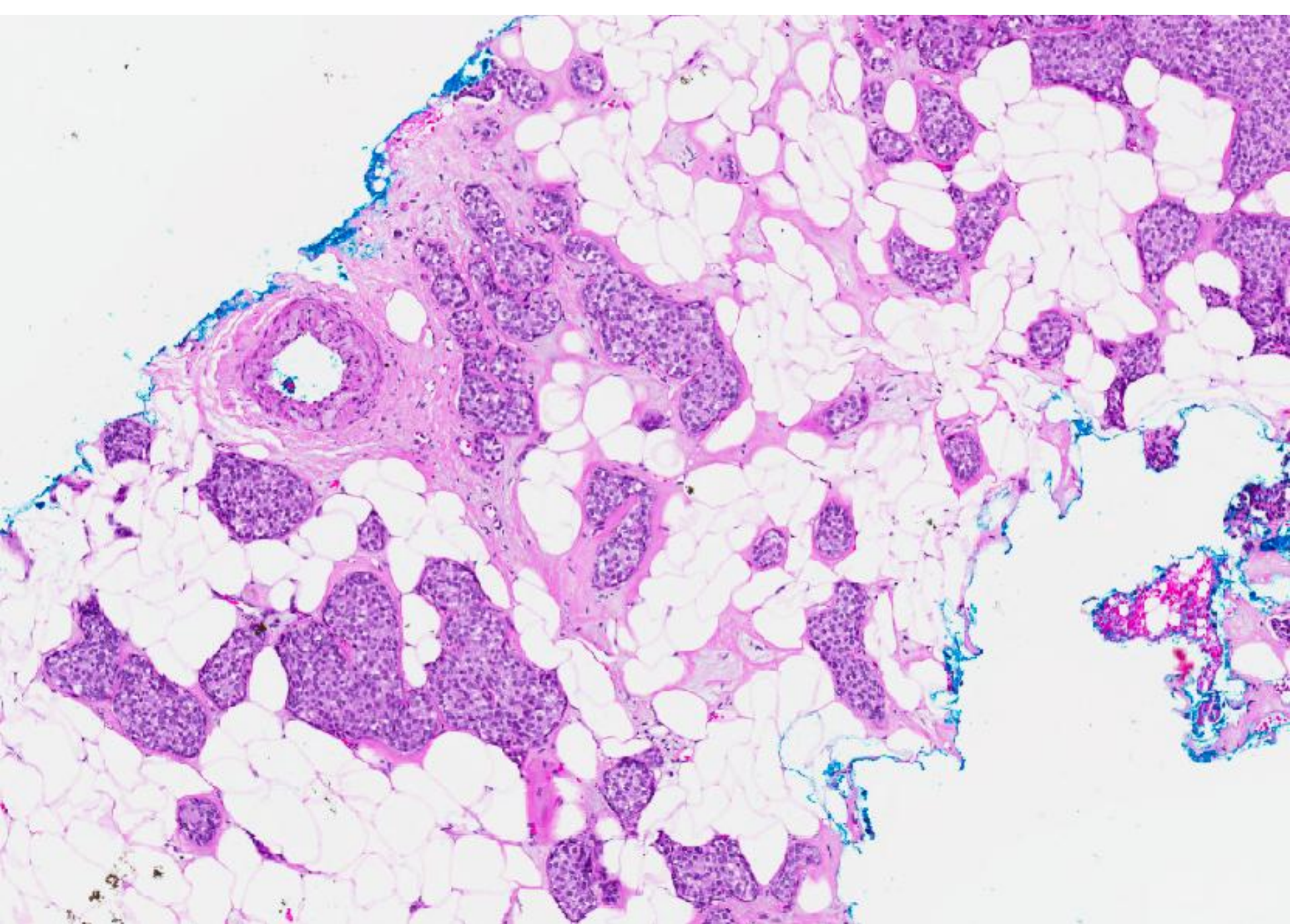
## CASE 5

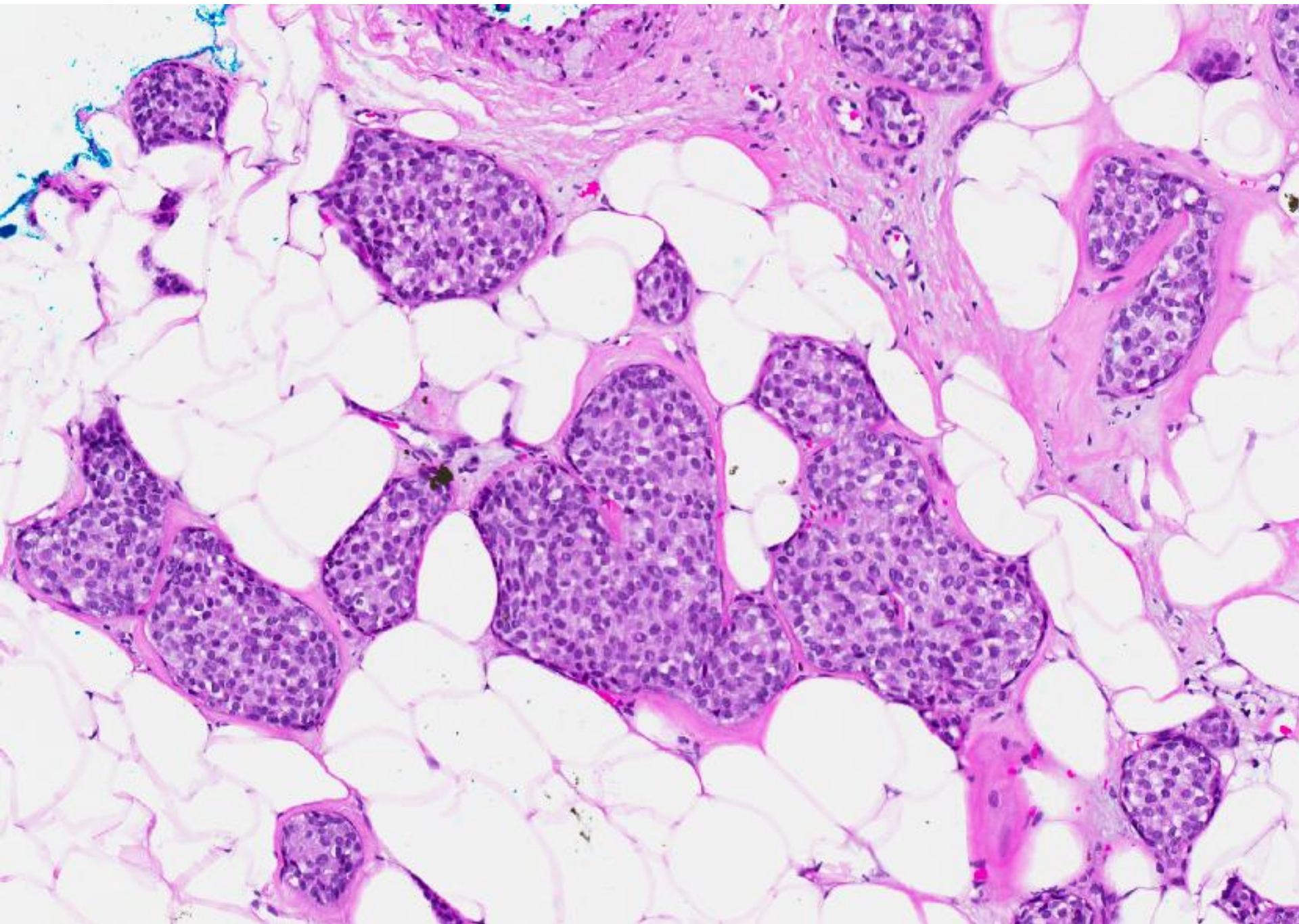
77 year old Chinese lady.

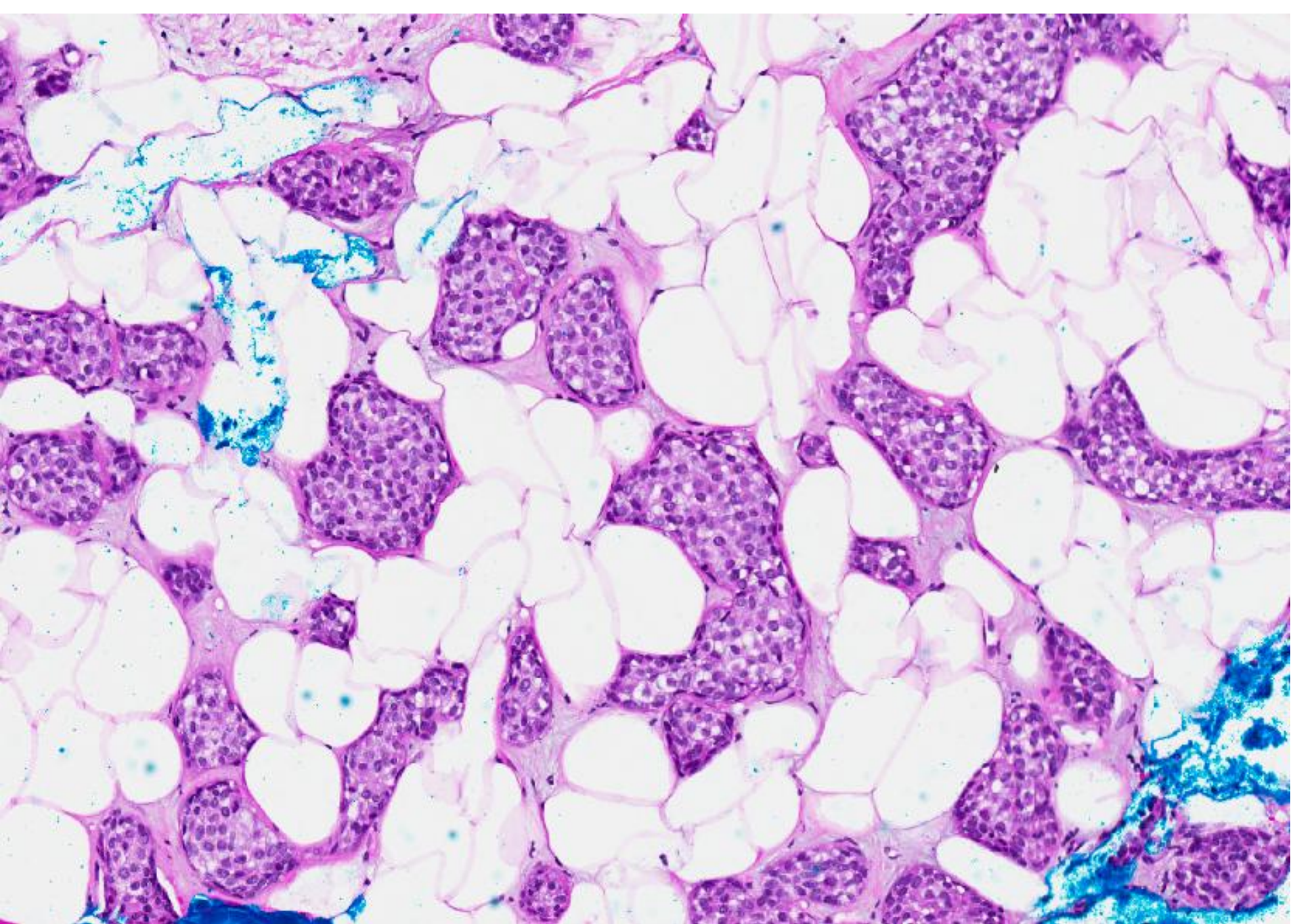
Discovered to have a left breast nodule at  
12:30 position.

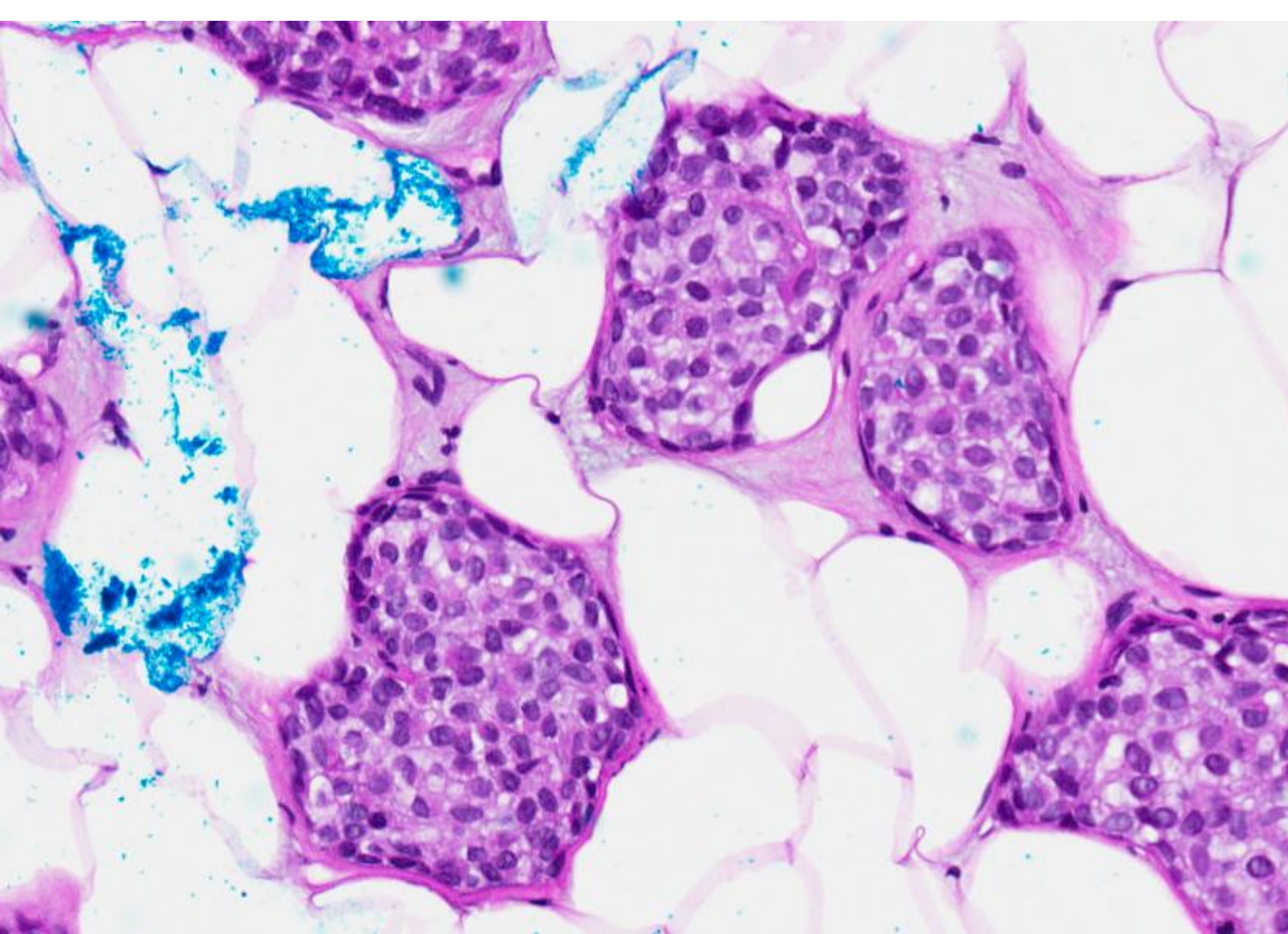
An ultrasound guided trucut biopsy was  
performed.

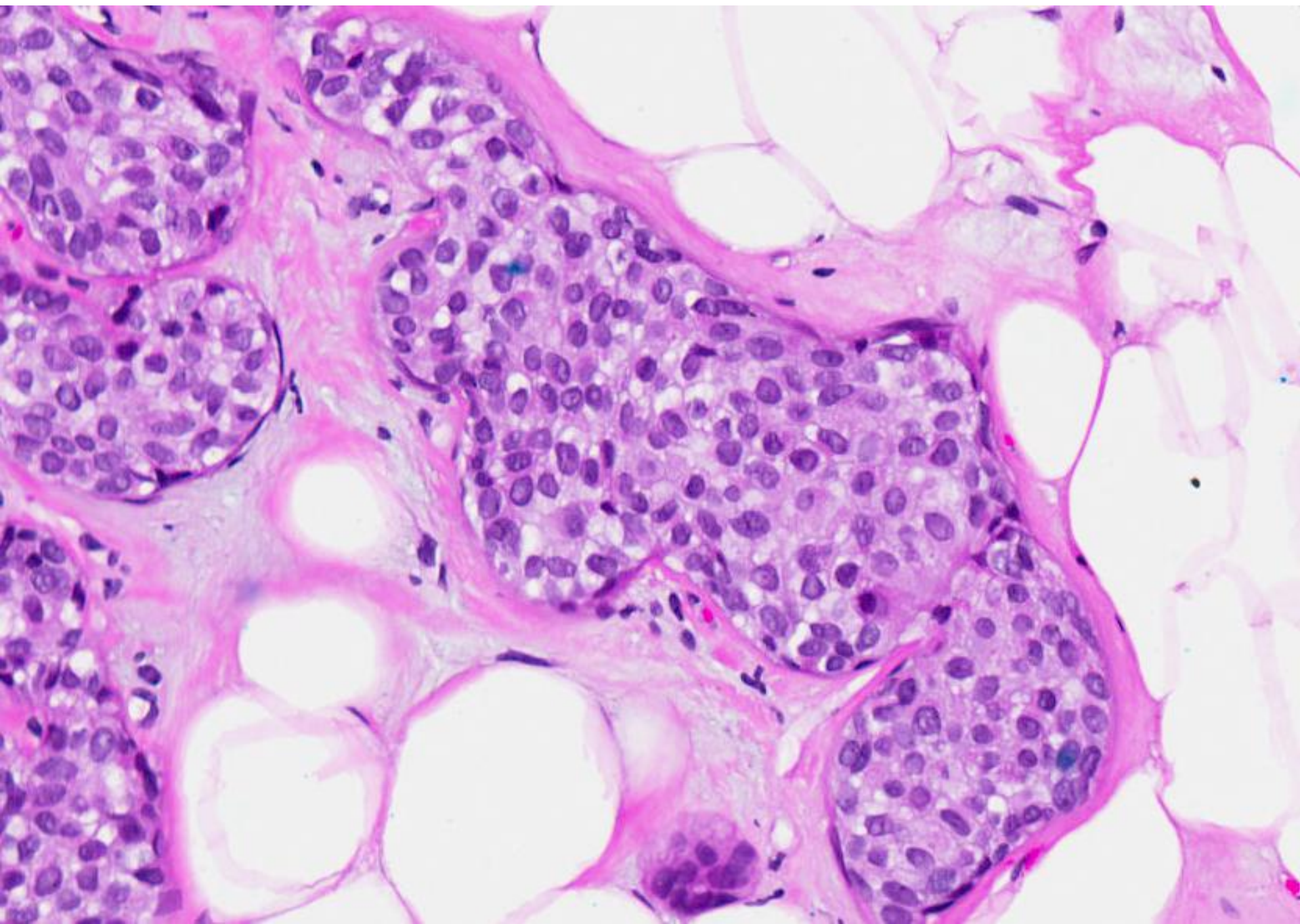


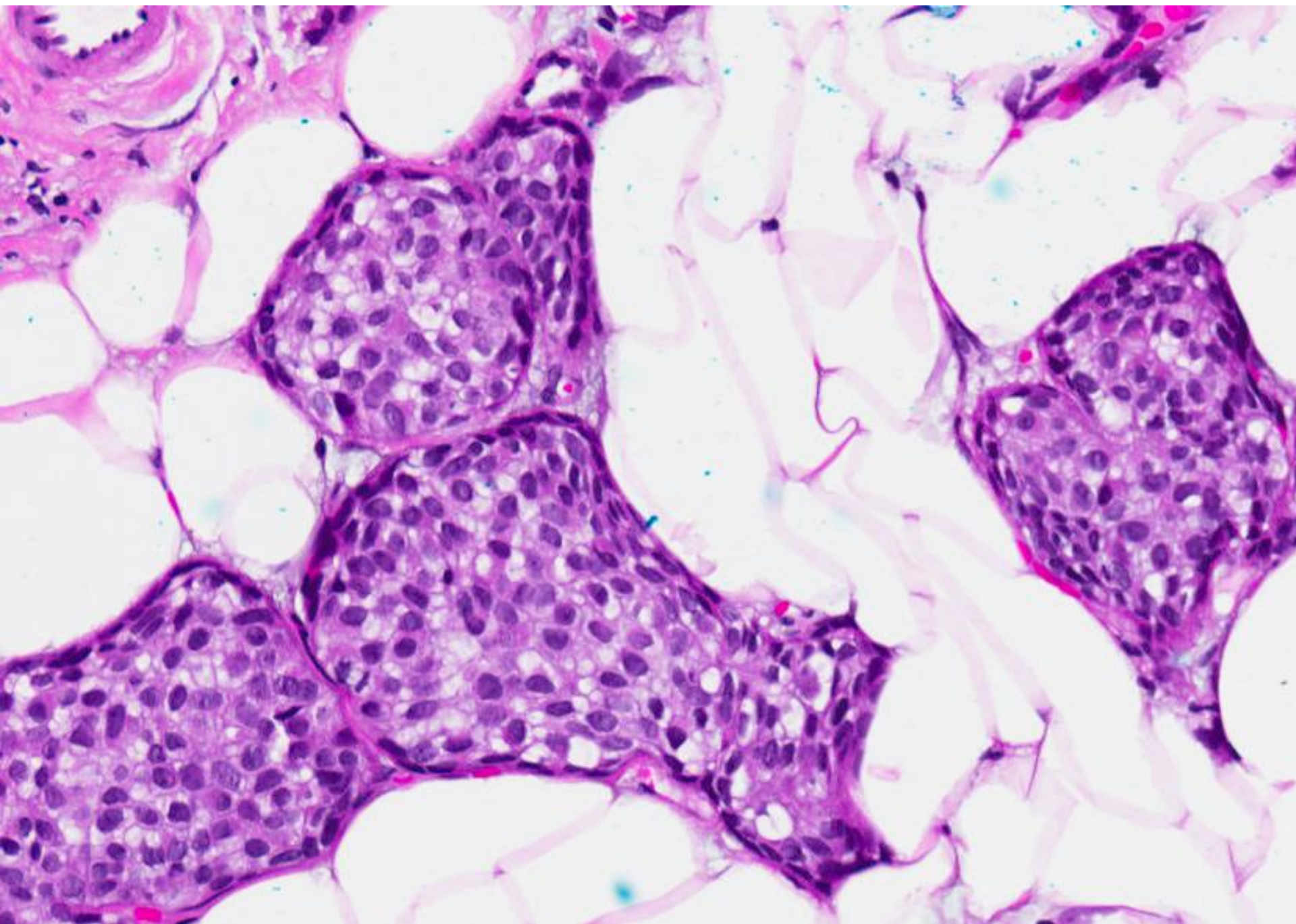




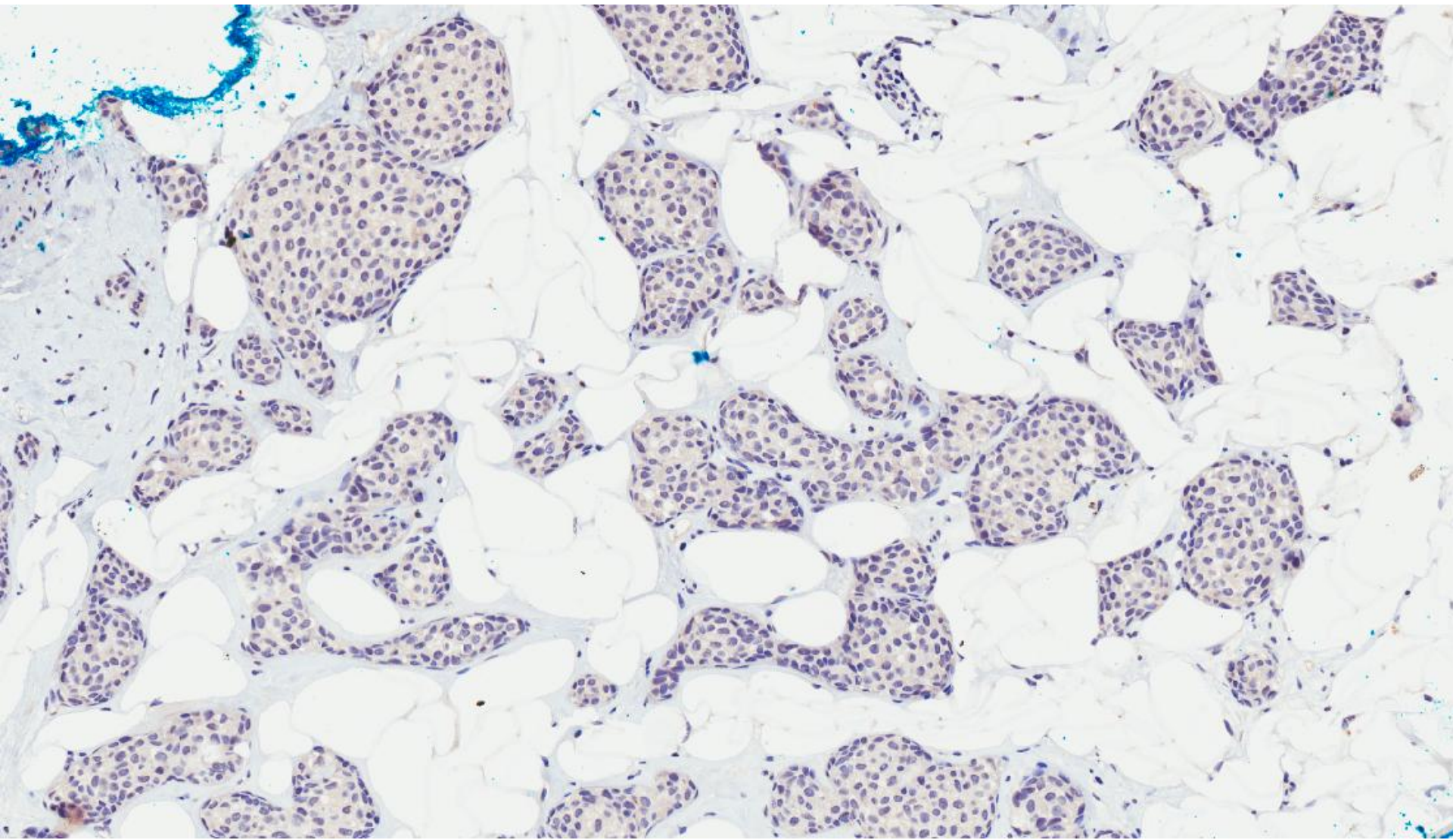




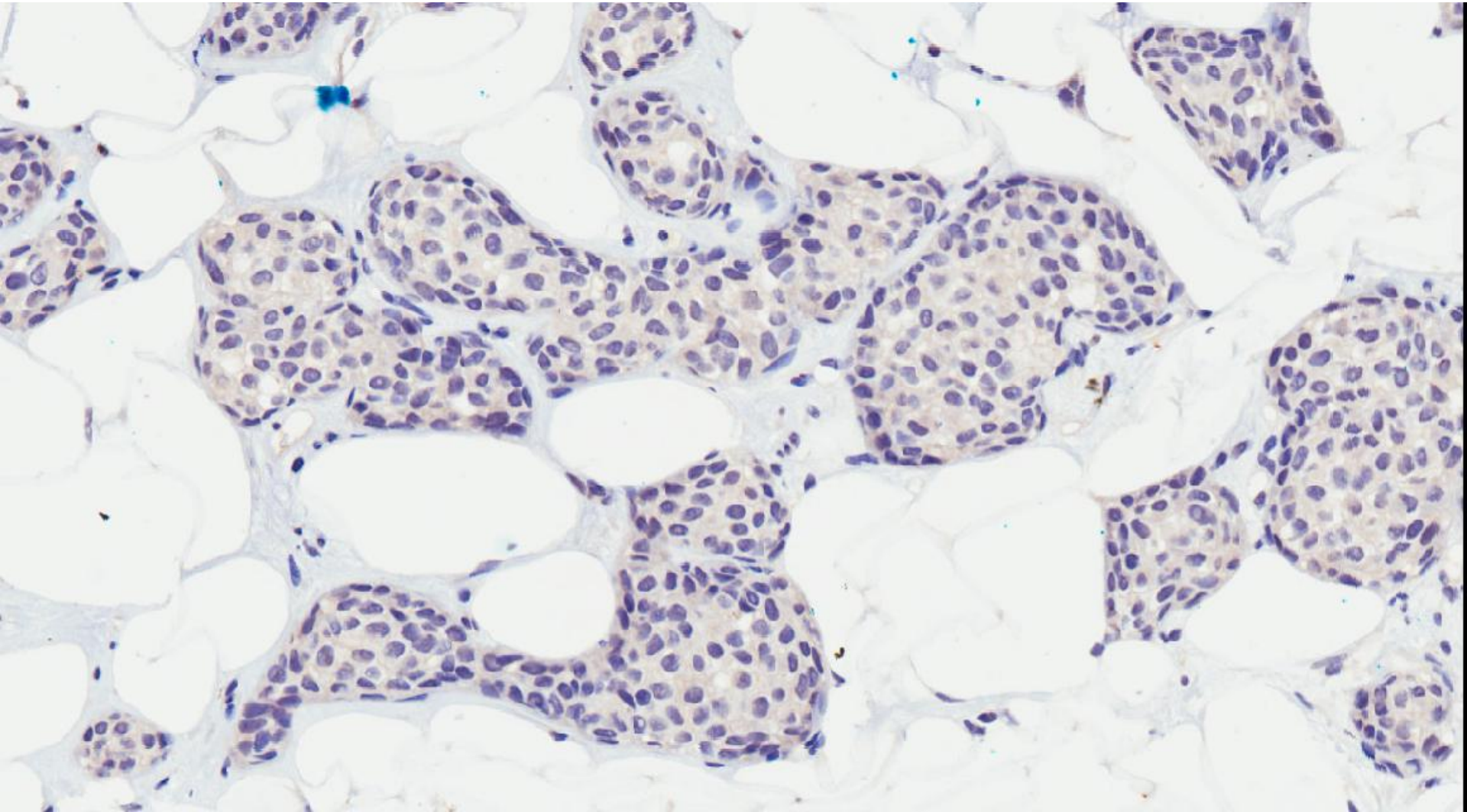








p63



p63

# Diagnosis

- Invasive carcinoma with ductal features.
- ER positive, PR positive, cerbB2 negative.

- Unusual pattern of invasive carcinoma.
- Mimics in situ cancer because of rounded configuration.
- Immunohistochemistry can be used to confirm the invasive nature.